

## Homocysteinemia and schizophrenia as a case of methylation deficiency

### *Case report*

B. Regland<sup>1</sup>, B. V. Johansson<sup>2</sup>, and C.-G. Gottfries<sup>1</sup>

<sup>1</sup> Department of Clinical Neuroscience, Mölndal Hospital, University of Göteborg, and

<sup>2</sup> Department of Psychiatry, Uddevalla Hospital, Uddevalla, Sweden

Accepted July 5, 1994

**Summary.** A 27-year-old woman is described whose disorder meets the DSM-III-R criteria for a diagnosis of schizophrenia and who was found to have a significantly increased serum level of homocysteine. Repeatedly, she improved on frequent cobalamin injections and deteriorated in periods without treatment. The effects of prolonged weekly treatment appeared to diminish as time went on, suggesting that the abnormality was not wholly cobalamin-dependent. It was found that methylenetetrahydrofolate reductase (MR) activity in cultured skin fibroblasts was reduced to a magnitude that is found among people with heterozygous deficiency. A defect in MR activity indicates a deficiency in methyltetrahydrofolate (MTHF), with a consequent reduction of the remethylation of homocysteine to methionine. Thus, reduced methylation may explain the increased levels of homocysteine and the transient effects of cobalamin treatment in the patient. Theoretically, MTHF should be the optimal treatment for her. The case reported highlights the importance of assessing the serum homocysteine level in order to detect methylation deficiency in patients with schizophrenia.

**Keywords:** Schizophrenia, homocysteine, cobalamin, folate, methylenetetrahydrofolate reductase.

### Introduction

Schizophrenia appears to be a clinical entity of considerable heterogeneity with regard to natural prognosis, responsiveness to therapy and possible etiology. Structural and biochemic defects have been found in different subgroups and it is probable that at least some cases of schizophrenia are due to a metabolic abnormality.

The main neurochemical theory to explain schizophrenia is the dopamine

theory. It is based on the fact that neuroleptics, which are believed to block dopamine, have a powerful antipsychotic action. Another biochemical aspect, which might be associated with the dopamine theory, is the relationship between homocystinuria and schizophrenia. There is a higher incidence of schizophrenia in relatives of homocystinurics than in the general population (Spiro et al., 1965), although a later literature review (Bracken and Coll, 1985) revealed only three published reports on cases in which homocystinuria and schizophrenia coexisted.

Homocysteine results from demethylation of methionine (Fig. 1). Homocystinuria is an inborn error that is due to cystathionine beta-synthase (CBS) deficiency which leads to excess excretion of homocysteine in the blood and urine. However, increased levels of homocysteine in the blood are by no means specific to CBS deficiency. Several enzyme deficiencies have been observed in folate and cobalamin metabolism (Mudd et al., 1972; Cooper and Rosenblatt, 1987). They result in impaired homocysteine turnover and increased concentrations of homocysteine, mainly as protein-bound disulfides.

We describe a patient in whom mental symptoms developed when she was 19 years old and whose disorder later on was diagnosed as schizophrenia.

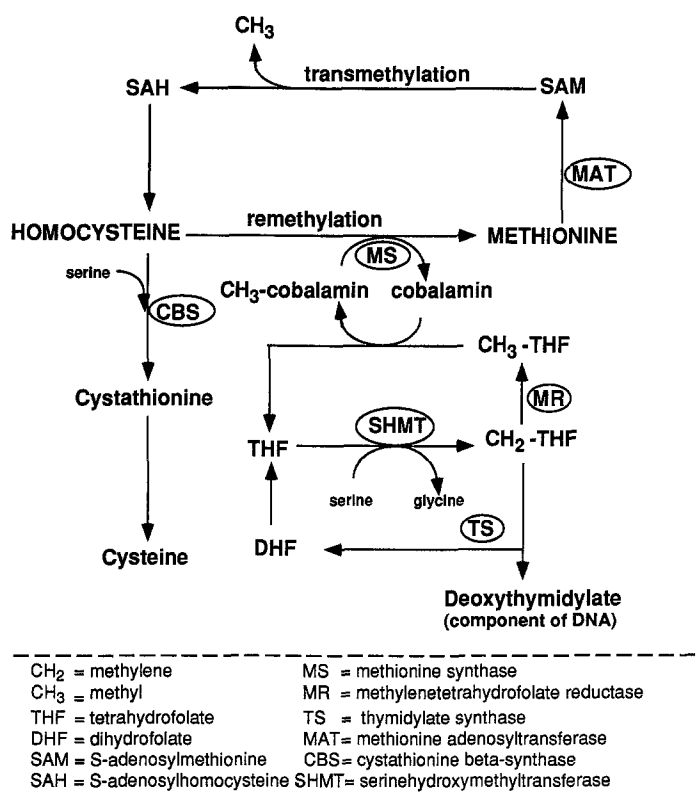


Fig. 1. Simplified scheme of enzyme systems controlling the methylation processes in the central nervous system. Enzymes are encircled

Because of moderate macrocytosis in the absence of low serum concentrations of folate or cobalamin, homocysteine was analysed, a laboratory procedure that by then had recently been introduced at the hospital. Significant homocysteinemia was found and the patient was successfully treated with frequent injections of cobalamin.

### Laboratory methods

Homocysteine in serum was determined using capillary gas chromatography-mass spectrometry, as described by Stabler et al. (1987). For analysis of methylmalonic acid in serum, anion-exchange extraction and purification were performed as described by Rasmussen (1989), and derivatization and chromatography were performed as described by Marcell et al. (1985).

In cultured fibroblasts, enzyme activities of two cobalamin-dependent enzymes, methylmalonyl-CoA-mutase and methionine synthase, and of N<sup>5,10</sup>-methylenetetrahydrofolate reductase (MR), were analysed, the latter as described by Mudd et al. (1972). Assessment of CBS was not available, for which reason a methionine loading test was performed by analysing the increase of the serum homocysteine level after administration of L-methionine (3.8 g/m<sup>2</sup> body surface area) orally in 200 ml of fruit juice.

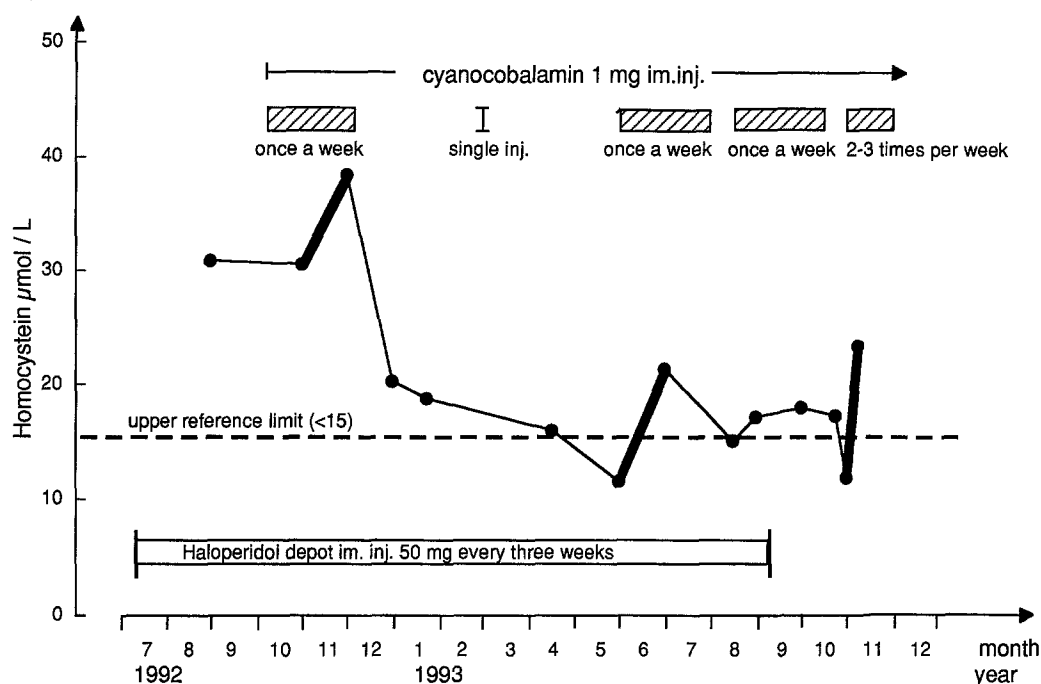
### Case report

The patient is a 27-year-old single woman. Her history reveals no heredity for psychiatric disorders. She was brought up by her biological parents as their only child. Somatically, she was a healthy child except for some migraine-like attacks at the age of puberty. She had an upper secondary education with good grades and then went to a school of economics for two years. She could not complete her economic studies because of her present illness. Instead, she tried several types of work and finally trained to become a child minder. In January 1992, she passed her exam, with some assistance. Between 1990 and 1992, continuous rehabilitation efforts were made, but she could not cope with full-time work and she never worked as a child minder. She tried to live by herself in a flat, but had to rely a great deal on her parents' support. She was lonely and had some difficulties in her relations with others.

In 1988, she was tested by a psychologist who found that she had normal intelligence and no signs of organic brain damage.

### *Present illness*

In 1988, at the age of 22, the patient contacted a psychiatric unit. For two years she had had difficulties in pursuing her studies and had failed in her examinations. Her relations with other people of both sexes were disturbed. She was ambivalent, had concentration difficulties, was very tired and often suffered from somatic complaints. She heard voices and had a feeling of being watched. She was treated with neuroleptics which had a good and almost immediate effect. Later, she had difficulties in complying with the treatment regimes (neuroleptics, psychological contact). In 1989, she became worse and broke all contacts with the psychiatric unit and with her place of work. Instead she contacted various somatic units in an unplanned manner. The next year, she had again auditory hallucinosis, displayed paranoid ideas and aggressive outbursts and always carried a knife in her handbag "to defend herself". In 1992, she was admitted to a psychiatric unit against her will, and she was again treated with neuroleptics, mainly haloperidol. From June 1992 until September 1993, she was treated with haloperidol depot injections every three weeks (Fig. 2). The antipsychotic effect was marginal and she still had hallucinosis, paranoid ideas and ag-



**Fig. 2.** Homocysteine levels from September 1992 until November 1993 in a patient with schizophrenia (●—●). Bold lines of the curve indicate the transient increases in homocysteine at times of intensified cobalamin treatment which also concurred with the periods of clinical improvement

gressive behaviour. She experienced the traditional side-effects of neuroleptics and, during treatment, she also described some attacks of blurred vision lasting for a few hours.

In 1989, during her first stay in hospital, the diagnosis was "hallucinosi", but in 1992 it was changed to "schizophrenia", as her disorder by then met the relevant DSM-III-R criteria. The sustained symptoms of hallucinosi described by the patient include disturbances of auditory and visual perception. She heard voices that continually commented on her doings. Her parents' faces were changed, her room took on an irregular shape, and her clothes looked too big. She was not considered delirious.

#### *Laboratory findings*

In 1989, the routine laboratory data were normal except the mean corpuscular volume (MCV) that was moderately increased (102 fl) in repeated samples. Blood hemoglobin (146 g/l), serum cobalamin (233 pmol/l) and serum folate (14.3 nmol/l) were all normal. In September 1992, the MCV was decreased to 98 fl. Blood hemoglobin (148 g/l), serum cobalamin (179 pmol/l) and serum folate (13.7 nmol/l) were still normal. Serum homocysteine (30.9 μmol/l) was highly increased (upper reference limit < 15) in repeated samples. In June 1993, the MCV had normalized (92 fl). Methylmalonic acid was only analysed after cobalamin treatment had been initiated and then showed normal values twice (0.26–0.10 μmol/l; ref. < 0.37) at times when the homocysteine levels were still increased (17.2–23.4 μmol/l). At the time of the methionine loading test, serum homocysteine had decreased to 18.8 μmol/l. After methionine loading, the serum homocysteine level rose to 29.1 μmol/l, which is a low and normal increase contradicting a CBS deficiency. In September 1993, a

skin biopsy was taken to assess various enzyme activities in the cultured skin fibroblasts. The activities of methylmalonyl-CoA-mutase and methionine synthase were normal.

MR activity was 2.9 nmol/mg protein/hour. The mean activity was 6.1 nmol/mg protein/hour (range 4.2–9.4) in 15 controls and 3.1 nmol/mg protein/hour in two controls with heterozygous MR deficiency.

In April 1993, the patient was examined by a neurologist. CT-scan and repeated EEG were normal and the neurologist found no support for a temporal-lobe dysfunction.

Serum levels of homocysteine (14.0 and 13.7  $\mu$ mol/l), methylmalonic acid, cobalamin and folate, as well as the levels of blood hemoglobin and MCV, were found to be normal in the patient's parents.

### *Cobalamin treatment*

Because of the hyperhomocysteinemic level in serum, cobalamin (Betolvex®; cyanocobalamin bound to tanninaluminostearate) treatment was started and the homocysteine level was frequently checked (Fig. 2). For two months, 1 mg per week was administered intramuscularly. After 4–5 weeks, the patient had obviously improved. As reported by herself, as well as her parents and the occupational therapist, she had become more concentrated and alert and was less tired. The hallucinosis was less disturbing. Although present all the time, the commenting voices were no longer so conspicuous but more like a murmur in the background. Moreover, at the time when the cobalamin treatment started, the patient had regular contact with a psychologist who was almost unaware of the patient's pharmacological treatment. The psychologist's record contains a significant description of how the patient improved concurrently with the cobalamin treatment. However, it could not be excluded that the improvement was a result of changes in her rehabilitation situation, and to test this, she was allowed to stop cobalamin treatment after 8 weeks. She herself insisted on stopping, because she disliked the intramuscular injections. Two weeks after the last cobalamin injection, she had deteriorated to the level at which she was before the initiation of cobalamin treatment. She suffered from fatigue and headache, and the grossly disturbing type of hallucinosis was there again. She did not accept to start another intensive cobalamin treatment, but accepted 1 ml intramuscularly every three months.

Six months later (June 1993; Fig. 2), she was still in bad shape, with tiredness and very disturbing hallucinosis. Now she accepted to receive cobalamin injections of 1 ml per week for another 8 weeks. After 2 weeks, there was improvement which remained until the end of the treatment period (Fig. 2). The patient reported that during this treatment period tiredness and headache had disappeared and that, except during one week, the commenting voices had turned into a low, unobtrusive murmur. Three weeks after the last injection, she worsened again and cobalamin treatment with 1 ml per week was restarted for yet another period. Within 2 weeks, she was again feeling better. At that time, however, she also exhibited severe extrapyramidal side-effects and the haloperidol depot injections were discontinued (Fig. 2). From then on, the effect of cobalamin treatment was less evident; in spite of continuous weekly treatment, she actually deteriorated. Two months later, tiredness and perceptual disturbances were so severe that admission to a psychiatric unit was planned in order to recommence neuroleptic treatment. While waiting for admission to the hospital, she received three injections of 1 ml cobalamin in one week. There was again dramatic improvement which still remained after 2 months of frequent cobalamin injections, and further treatment with neuroleptics was judged unnecessary.

### **Discussion**

The case reported fulfils the DSM-III-R criteria for the diagnosis of schizophrenia of undifferentiated type.

As the increased homocysteine level was reproducible before treatment, the subsequent reduction was apparently a significant effect of cobalamin treatment (Fig. 2). However, the effect of prolonged weekly treatment with cobalamin appeared to diminish as time went on. This tendency suggests that the treatment we had chosen was not the optimal treatment for the patient, and that the metabolic abnormality was not wholly cobalamin-dependent.

Homocysteinemia *per se* is presumably not causally related to psychotic symptoms, since among the several hundred known patients with homocystinuria due to CBS deficiency, only a scattered few have been reported to be psychotic. Homocysteinemia may, however, be linked to the excitatory amino acid hypothesis of neuropsychiatric disorders (Olney, 1993) because the related homocysteic acid is regarded to exert potent excitatory and toxic effects.

In our patient, the improvement on cobalamin treatment, the result of the methionine loading test, and the apparent lack of disease-related heredity, exclude CBS deficiency as the cause of homocysteinemia. However, measurements in cultured skin fibroblasts revealed a reduction in MR of a magnitude that is found among people with heterozygous deficiency. MR deficiency is an inborn error leading to moderate homocysteinemia compared with the severe type normally found in people with homozygous CBS deficiency. The clinical findings in the more than two dozen known patients with MR deficiency range from death in infancy to asymptomatic homocystinuria in adulthood, and the clinical heterogeneity of this disorder is well documented (Haworth et al., 1993). The usual clinical manifestations consist of delayed psychomotor development in infancy, severe mental retardation, and psychiatric symptoms. Recently, a new variant of MR deficiency was discovered (Kang et al., 1988, 1991). In homozygotes with this variant, certain activity was reduced by approximately 50% in lymphocytes compared with normal activity and MR was typically thermolabile, with residual activity of less than 20% after heat inactivation. In another study, it appeared that the presence of a thermolabile reductase was associated with a later clinical presentation (Rosenblatt et al., 1992). Thermolability was not tested in our patient.

Reduced MR activity prevents the formation of sufficient methyltetrahydrofolate (MTHF) to carry out the important remethylation of homocysteine. As a result, homocysteine accumulates to a level that exceeds the capacity of CBS to form cystathionine. The "trapped" metabolite is methylenetetrahydrofolate (methylene-THF) which is drained off by thymidylate synthase (Fig. 1) which forms DNA in sufficient amounts to prevent megaloblastic anaemia. Megaloblastic anaemia is infrequent in people with MR deficiency (Rosenblatt et al., 1992). Our patient was not anaemic and only moderately megaloblastic (macrocytotic).

The late onset of disease and the "heterozygous level" of enzyme activity make our patient atypical with regard to the MR deficiency. Obligate heterozygotic individuals, i.e., parents of homozygotic patients, are usually asymptomatic. However, homocysteinemia may be caused by a number of different

genetic and nongenetic errors in cobalamin and/or folate metabolism, and our patient may have a heterozygous MR deficiency in combination with any one of the defects that produce moderate homocysteinemia. Her normal levels of serum methylmalonic acid and normal activity of methylmalonyl-CoA-mutase are consistent with the idea that she had no primary cobalamin deficiency, although she must have had a lack of methylcobalamin that was secondary to the MR deficiency and the subsequent lack of MTHF.

In the human brain, there is no alternative pathway for the remethylation of homocysteine. Betaine homocysteine-methyltransferase (BHMT) catalyses a reaction in which a methyl group is transferred to homocysteine to form methionine in several extracerebral tissues, but there is no such enzyme activity in the human brain (McKeever et al., 1991). The absence of BHMT in the brain increases the demand for cobalamin/folate-dependent remethylation. This may be one reason for the apparent discrepancy between the homocysteine levels (Fig. 2) and the alleviation of symptoms in our patient. The homocysteine level normalized during a long period of infrequent injective therapy when there was no alleviation of psychiatric symptoms. Furthermore, the homocysteine level rose transiently when the patient improved psychiatrically during the series of frequent injections.

We think this apparent discrepancy can be interpreted in the following way: At the start of the treatment with cyanocobalamin in October 1992, the tissues were loaded with cobalamin which reacted avidly with all MTHF that was still available. Subsequently, more homocysteine was remethylated and the homocysteine level in serum decreased. However, possibly because of the absence of BHMT in the brain, the demand for remethylation by cobalamin was greater in the brain than in peripheral tissues, and to maintain the patient's mental status, very frequent injections of cobalamin were needed, way beyond what was required to reduce the serum homocysteine level and the MCV. It seems plausible that serum homocysteine levels mainly reflect the remethylation capacity of extracerebral tissues and that they are only marginally influenced by the remethylation in the brain.

MR deficiency, in a figurative sense, may be thought of as something that makes the remethylation system somewhat sluggish, which may explain the transient increase and the delayed reduction in the serum homocysteine level after initiation or intensification of the cobalamin treatment (Fig. 2). The transient increase in homocysteine levels at times of intensified treatment presumably reflected an increase in the synthesis of S-adenosylmethionine (SAM), which serves as the most important methyl donor to a number of biogenic amines, such as dopamine, norepinephrine, serotonin, and histamine. As a result, more homocysteine is being formed. In summary, the findings in our patient probably reflected a remethylation deficiency and the importance of methyl group transfer in the brain.

In schizophrenic patients, direct measures of SAM have been carried out by Andreoli and Maffei (1975). They reported a 50% reduction in acute schizo-

phrenics compared with normal controls. In the case reported, the MCV actually started to decrease before the cobalamin supplementation was initiated and while the patient was treated with neuroleptics only. This might indicate that neuroleptics have a stimulating effect on SAM production, as increased MCV is known to be corrected by SAM treatment (Turpini et al., 1987). Such a notion would also be in agreement with reports that neuroleptics appear to normalize the reduced activity of methionine adenosyltransferase (MAT) in many schizophrenic patients (Morere et al., 1986; Smythies et al., 1986). This enzyme is activating methionine to form SAM (Fig. 1).

From a theoretical point of view, our patient should be supplemented with MTHF as the drug of choice. MTHF is the form of folate that is taken up by cells. Supplementation of folate without a methyl group would only enhance the accumulation of methylene-THF, which might be harmful. It has previously been postulated that accumulated methylene-THF may dissociate into formaldehyde which condenses with biogenic amines forming psychotogenic compounds (Fekkes et al., 1991). It is of great interest that MTHF supplementation significantly improved clinical and social recovery among both depressed and schizophrenic patients in a double-blind, placebo-controlled trial (Godfrey et al., 1990). If pharmacologically available to the brain, treatment with methylcobalamin or SAM should also be of benefit for our patient. In practice, betaine has proved useful in the treatment of children with MR deficiency (Berlow et al., 1989; Holme et al., 1989). Efforts are being made to get hold of the drugs described above in order to test new treatment strategies.

MR deficiency has once before been associated with schizophrenia. A mildly retarded adolescent girl with MR deficiency was reported to have recurrent episodes of folate-responsive schizophrenia-like behaviour (Freeman et al., 1975). Later, by assessment of platelet MR activity, it was shown that MR deficiency is not a general feature of schizophrenia (Berger et al., 1977; Carl et al., 1978). However, the latter study found significant differences between normals and schizophrenics in the activities of serinehydroxymethyltransferase (SHMT) and MAT. These findings support the hypothesis (Mudd and Freeman, 1974; Levi and Waxmann, 1975; Smythies, 1984) that schizophrenia is characterized by a methylation deficiency, considering that the concept of methylation deficiency may cover various abnormalities that yield the same result.

Preliminary results, yet unpublished, show that the combination of homocysteinemia and a psychotic disorder is not unique to the patient reported in this paper. Although the specific deficiency of MR obviously characterizes only a small subgroup of patients with a schizophrenic syndrome, methyl group deficiency in the brain may be a biochemical abnormality that underlies the mental disturbances in a significant proportion of patients with schizophrenia, and perhaps also of those with other psychotic syndromes.

### Acknowledgements

The authors wish to thank the Department of Clinical Chemistry, Uddevalla Hospital, for the assessments of homocysteine and methylmalonic acid, and the Department of Clinical



Chemistry, Sahlgren's Hospital, Göteborg, for the assessments of enzyme activities in cultured fibroblasts. We also wish to thank Mrs. I. Larsson for improving the English text.

## References

- Andreoli VM, Maffei T (1975) Blood levels of S-adenosylmethionine in schizophrenia. *Lancet* ii: 922
- Berger PA, Elliott GR, Erdelyi E, Watson SJ, Wyatt RJ, Barchas JD (1977) Platelet methylene reductase activity in schizophrenia. *Arch Gen Psychiatry* 34: 808–809
- Berlow S, Bachman RP, Berry GT, Donnell GN, Grix A, Levitsky LL, Hoganson G, Levy HL (1989) Betaine therapy in homocysteinemia. *Brain Dysfunct* 2: 10–24
- Bracken P, Coll P (1985) Homocystinuria and schizophrenia. Literature review and case report. *J Nerv Ment Dis* 173: 51–55
- Carl GF, Crews EL, Carmichael SM, Benesh FC, Smythies JR (1978) Four enzymes of one-carbon metabolism in blood cells of schizophrenics. *Biol Psychiatry* 13: 773–776
- Cooper BA, Rosenblatt DS (1987) Inherited defects of vitamin B<sub>12</sub> metabolism. *Ann Rev Nutr* 7: 291–320
- Fekkes D, Peppinkhuizen L, Bruinvels J (1991) Changes in serine metabolism by a serum factor present in a group of episodic psychotic patients. *Biol Psychiatry* 30: 966–972
- Freeman JM, Finkelstein JD, Mudd SH (1975) Folate-responsive homocystinuria and "schizophrenia". *N Engl J Med* 292: 491–496
- Godfrey PSA, Toone BK, Carney MWP, Flynn TG, Bottiglieri T, Laundry M, Chanarin I, Reynolds EH (1990) Enhancement of recovery from psychiatric illness by methylfolate. *Lancet* 336: 392–395
- Haworth JC, Dilling LA, Surtees RAH, Seargeant LE, Lue-Shing H, Cooper BA, Rosenblatt DS (1993) Symptomatic and asymptomatic methylenetetrahydrofolate reductase deficiency in two adult brothers. *Am J Med Genet* 45: 572–576
- Holme E, Kjellman B, Ronge E (1989) Betaine for treatment of homocystinuria caused by methylenetetrahydrofolate reductase deficiency. *Arch Dis Child* 64: 1061–1064
- Kang SS, Zhou J, Wong PW, Kowalisyn J, Strokosch G (1988) Intermediate homocysteinemia: a thermolabile variant of methylenetetrahydrofolate reductase. *Am J Hum Genet* 43: 414–421
- Kang SS, Wong PW, Bock HGO, Horwitz A, Grix A (1991) Intermediate hyperhomocysteinemia resulting from compound heterozygosity of methylenetetrahydrofolate reductase mutations. *Am J Hum Genet* 48: 546–551
- Levi RN, Waxman S (1975) Schizophrenia, epilepsy, cancer, methionine and folate metabolism. Pathogenesis of schizophrenia. *Lancet* ii: 11–13
- Marcell PD, Stabler SP, Podell ER, Allen RH (1985) Quantitation of methylmalonic acid and other dicarboxylic acids in normal serum and urine using capillary gas chromatography-mass spectrometry. *Anal Biochem* 150: 58–66
- McKeever MP, Weir DG, Molloy A, Scott JM (1991) Betaine-homocysteine methyltransferase: organ distribution in man, pig, and rat and subcellular distribution in the rat. *Clin Sci* 81: 551–556
- Morere DA, Alarcon RD, Monti JA, Walter-Ryan WG, Bancroft AJ, Smythies JR, Tolbert LC (1986) Medication effects on one-carbon metabolism in schizophrenia, mania, and major depression. *J Clin Psychopharmacol* 6: 155–161
- Mudd SH, Freeman JM (1974) N<sup>5,10</sup>-methylenetetrahydrofolate reductase deficiency and schizophrenia: a working hypothesis. *J Psychiat Res* 11: 259–262
- Mudd SH, Uhlenendorf BW, Freeman JM, Finkelstein JD, Shih VE (1972) Homocystinuria associated with decreased methylenetetrahydrofolate reductase activity. *Biochem Biophys Res Commun* 46: 905–912

- Olney JW (1993) Role of excitotoxins in developmental neuropathology. *APMIS* [Suppl 40] 101: 103–112
- Rasmussen K (1989) Solid-phase sample extraction for rapid determination of methylmalonic acid in serum and urine by a stable-isotope-dilution method. *Clin Chem* 35: 260–264
- Rosenblatt DS, Lue-Shing H, Arzoumanian A, Low-Nang L, Matiaszuk N (1992) Methylentetrahydrofolate reductase (MR) deficiency: thermolability of residual MR activity, methionine synthase activity, and methylcobalamin levels in cultured fibroblasts. *Biochem Med Metabol Biol* 47: 221–225
- Smythies JR (1984) The transmethylation hypotheses of schizophrenia re-evaluated. *Trends Neurosci*: 45–47
- Smythies JR, Alarcon RD, Morere D, Monti JA, Steele M, Tolbert LC, Walter-Ryan WG (1986) Abnormalities of one-carbon metabolism in psychiatric disorders: study of methionine adenosyltransferase kinetics and lipid composition of erythrocyte membranes. *Biol Psychiatry* 21: 1391–1398
- Spiro HR, Schimke RN, Welch JP (1965) Schizophrenia in a patient with a defect in methionine metabolism. *J Nerv Ment Dis* 141: 285–290
- Stabler SP, Marcell PD, Podell ER, Allen RH (1987) Quantitation of total homocysteine, total cysteine, and methionine in normal serum and urine using capillary gas chromatography-mass spectrometry. *Anal Biochem* 162: 185–196
- Turpini R, Albergati M, Gili C (1987) Macrocytosis in chronic alcoholism: a tentative correction with vitamin B 12, 5-methyltetrahydrofolate, and S-adenosylmethionine. *Curr Ther Res* 41: 38–46

Authors' address: Dr. B. Regland, Department of Clinical Neuroscience, Mölndal Hospital, S-431 80 Mölndal, Sweden.

Received March 25, 1994