

Methotrexate-Associated Alterations of the Folate and Methyl-Transfer Pathway in the CSF of ALL Patients With and Without Symptoms of Neurotoxicity

Sandra Vezmar, PhD,¹ Patrick Schüsseler, MSc,¹ Achim Becker, PhD,¹ Udo Bode, MD,² and Ulrich Jaehde, PhD^{1*}

Background. Severe neurotoxicity has been observed after systemic high-dose and intrathecal methotrexate (MTX) treatment. The role of biochemical MTX-induced alterations of the folate and methyl-transfer pathway in the development of neurotoxic symptoms is not yet fully elucidated. **Procedure.** MTX, 5-methyltetrahydrofolate, calcium folinate, S-adenosylmethionine, and S-adenosylhomocysteine were measured in the cerebrospinal fluid (CSF) of 29 patients with acute lymphoblastic leukemia (ALL) who were treated with high-dose MTX (5 g/m²) followed by calcium folinate rescue (3 × 15 mg/m²) and/or intrathecal (8–12 mg) MTX. Two patients developed subacute MTX-associated neurotoxicity. CSF was obtained by lumbar puncture 1–3 weeks after administration of MTX and shortly after the occurrence of neurotoxicity. The analytes were measured using HPLC assays with UV and/or fluorescence detection. **Results.** In non-toxic patients, CSF concentrations of 5-methyltetrahydrofolate and S-adenosylmethionine were

in the normal range 2 weeks after administration of high-dose and intrathecal MTX followed by rescue. In contrast, when these patients received intrathecal MTX without rescue, 5-methyltetrahydrofolate concentrations were significantly decreased 12 days after the first MTX administration. S-adenosylmethionine concentrations were significantly decreased up to 45 days. The two patients suffering from neurotoxicity had decreased levels of 5-methyltetrahydrofolate and S-adenosylmethionine during or following toxicity. S-adenosylhomocysteine was determined in all samples of neurotoxic patients but was below the limit of quantification in most samples of non-toxic patients. Calcium folinate was not detected; MTX was present only in samples obtained during its infusion. **Conclusion.** Intrathecal MTX without folinate rescue as well as MTX-associated neurotoxicity are likely to be associated with specific alterations of the folate and methyl-transfer pathway. *Pediatr Blood Cancer* 2009;52:26–32.

© 2008 Wiley-Liss, Inc.

Key words: CSF; methotrexate; neurotoxicity; S-adenosylmethionine; 5-methyltetrahydrofolate

INTRODUCTION

Methotrexate (MTX), a widely used antifolate has been associated with severe neurotoxicity after administration of high-doses (> 1 g/m²) and/or intrathecal MTX in patients with acute lymphoblastic leukemia (ALL) and osteosarcoma [1–3]. According to the time of occurrence, MTX-associated neurotoxicity is classified as acute, subacute, or chronic [4–6].

Acute toxicity appears during or within hours following MTX administration. Symptoms such as somnolence, confusion, fatigue, and seizures may follow systemic high-dose MTX. Intrathecal administration was associated with the so-called acute arachnoiditis characterized by headache, nausea, and dizziness [4]. Acute toxicity is usually reversible but a fatal outcome was also reported [7].

Subacute neurotoxicity is usually observed days to weeks following MTX administration. After high-dose MTX a stroke-like syndrome characterized by hemiparesis, seizures, and speech disorder has been reported [1,8]. Intrathecal administration was associated with myelopathy and symptoms such as pain in the legs, sensory changes, and bladder dysfunction [9]. Subacute toxicity can be severe but it is usually reversible.

Chronic neurotoxicity may occur after months to years and is usually associated with leukoencephalopathy, which can be transient and nonsymptomatic or severe, characterized by personality changes, progressive dementia, focal seizures, spastic quadriparesis, and stupor [2,10,11]. Severe leukoencephalopathy was associated with demyelination [2]. Moreover, children treated with MTX may develop learning disabilities and a decreased intelligence quotient [12–14].

The pathogenic mechanisms of MTX-associated neurotoxicity remain unclear but there are indications that drug-induced biochemical alterations may play an important role [5,6]. MTX as well as its polyglutamated forms inhibit the enzyme dihydrofolate reductase (DHFR, see Fig. 1) [15,16] decreasing the level of the

main folate form 5-methyl-tetrahydrofolate (5-methyl-THF). Repletion of the pool of reduced folates is possible by administration of calcium folinate, which is rapidly transformed into 5-methyl-THF (rescue). As a further consequence of MTX action, homocysteine and excitatory amino acids, its main catabolism products, accumulate [17]. Moreover, the lack of methionine supply affects the methyl-transfer pathway. The formation of the methyl donor S-adenosylmethionine (SAM) is reduced which results in decreased synthesis of the neuronal myelin sheath [18] and increased levels of the methyl-transferase inhibitor S-adenosylhomocysteine (SAH) [19,20]. MTX also affects the adenosine and bipterin pathway inducing elevated levels of adenosine and its monophosphate [21,22] and decreased synthesis of serotonin and dopamine [23].

Biochemical alterations in the CSF have already been associated with neurologic sequelae in clinical studies. CSF depletion of 5-methyl-THF has been associated with administration of high-dose or intraventricular MTX [24–26]. Clinical signs such as behavioral changes, psychomotor retardation, cerebellar ataxia, and occasional seizures were described in pediatric patients with low CSF 5-methyl-THF due to congenital errors of folate metabolism [27]. Decreased SAM levels in the CSF were associated with demyelination reported in patients with MTX-related subclinical and clinical leukoencephalopathy [28,29]. Moreover, SAM/SAH ratio

¹Department of Clinical Pharmacy, Institute of Pharmacy, University of Bonn, Bonn, Germany; ²Department of Paediatric Haematology and Oncology, Children's Hospital, University of Bonn, Bonn, Germany

Grant sponsor: German Academic Exchange Service (DAAD).

*Correspondence to: Ulrich Jaehde, PhD, Institute of Pharmacy, Department of Clinical Pharmacy, University of Bonn, An der Immenburg 4, D-53121 Bonn, Germany.

E-mail: u.jaehde@uni-bonn.de

Received 21 March 2008; Accepted 22 September 2008

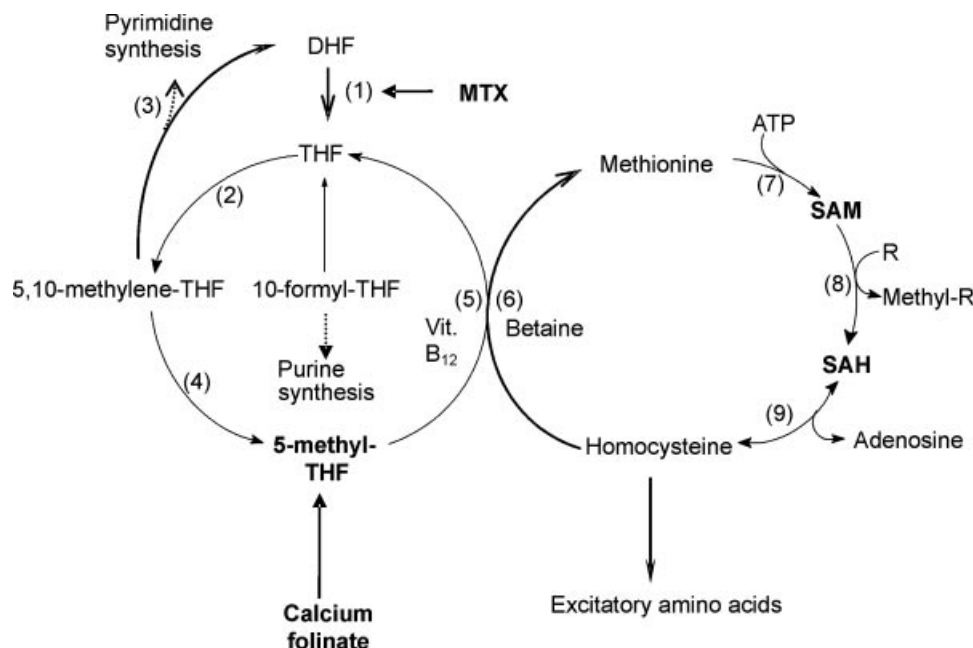


Fig. 1. Scheme of the folate and methyl-transfer pathway. ATP: adenosine triphosphate; DHF: dihydrofolate; SAH: S-adenosylhomocysteine; SAM: S-adenosylmethionine; THF: tetrahydrofolate (1) dihydrofolate reductase; (2) serine-hydroxymethyltransferase; (3) thymidylate synthase; (4) 5,10-methylenetetrahydrofolate reductase; (5) methionine synthase; (6) betaine-homocysteine methyltransferase; (7) methionine adenosyltransferase; (8) R-methyltransferase; (9) SAH hydrolase.

was suggested as a possibly better marker for leukoencephalopathy [30].

This work aimed at investigating the biochemical changes of the folate and methyl-transfer pathway following high-dose and/or intrathecal MTX administration in the CNS of pediatric patients treated for ALL. For this purpose, CSF levels of MTX, 5-methyl-THF, calcium folinate, SAM, and SAH were investigated.

METHODS

Patients and Treatment

Prior to study begin an approval of the local ethics committee was obtained for collection of CSF samples. Samples were obtained during lumbar puncture for diagnostic or treatment purposes.

All patients who presented in our hospital with the diagnosis of ALL and received treatment according to ALL BFM 2000 in the period of 2000–2004 were included in the study. In total, 29 patients with a median patient age of 4 years (2–17 years), classified as standard or middle-risk, were included. Two patients developed signs of subacute neurotoxicity.

ALL BFM 2000 consisted of three protocols (I, M, and II/III), which were successively administered to all patients in this study. Treatment was initiated with protocol I when the patients received intrathecal MTX (8–12 mg, age-related) on day 1, 12, and 33. Thereafter, patients entered protocol M and received 5 g/m² MTX over 24 hr and an injection of intrathecal MTX 1 hr after start of infusion on day 8, 22, 36, and 50. Calcium folinate (15 mg/m², i.v.) was administered 42, 48, and 54 hr after beginning of MTX infusion. After completing protocol M, patients were randomized into protocol II or III. In this study, protocols II and III were evaluated together since patients received in both protocols intrathecal MTX

twice with an 8-day time-period in between. As in protocol I no concomitant folinate rescue was administered in protocols II and III.

CSF Sampling

During treatment, CSF samples were obtained by lumbar puncture just prior to intrathecal MTX administration if appropriate. The first milliliter of CSF was discarded and the rest was divided into vials containing ascorbic or perchloric acid. In total, 74 samples for the determination of reduced folates and MTX and 81 samples for the determination of SAM and SAH were obtained from the 27 patients without signs of neurotoxicity.

In addition, CSF samples were drawn in the two patients exhibiting subacute neurotoxicity. Case 1, a 15-year-old boy treated according to ALL BFM 2000 presented with two episodes of subacute neurotoxicity during protocol M. The second toxicity episode was evaluated using common toxicity criteria (CTC) and MRI of the brain. CSF samples were obtained during protocol I, 3 days after the second toxicity episode and 1 month after neurotoxicity. Case 2, a 13-year-old boy treated according to ALL BFM 2000 also developed two episodes of subacute neurotoxicity during protocol M. The second toxicity episode was evaluated using CTC and MRI. One CSF sample was obtained during protocol I, the second sample was obtained 1 day after resolution of symptoms of the second toxicity episode. Moreover, two samples were obtained 7 and 17 days after toxicity, respectively.

Analysis of MTX and Reduced Folates

In order to measure MTX, 5-methyl-THF and calcium folinate in the CSF a method from Belz et al. [31] based on reversed-phase HPLC with simultaneous UV and fluorescence detection was

modified. In brief, the stationary phase was a SupelcosilTM column (15 cm × 0.46 cm, 3 μm) and SupelguardTM precolumn (2 cm × 0.46 cm, 5 μm) both from Supelco (Bellefonte, PA). The HPLC system was from Thermo Separation Products, Inc (Egelsbach, Germany). Fifty microliter samples were injected onto the HPLC system and separated by gradient elution, which consisted of methanol and phosphate buffer (10 mM, pH 2.1). 5-methyl-THF was determined by fluorescence detection (294/356 nm), MTX and calcium folinate by UV detection (310 nm). Flow rate was 1 ml/min. The method was validated according to the FDA Guideline for Bioanalytical Method Validation [32]. Due to the instability of reduced folates, CSF samples were collected in vials containing ascorbic acid solution (5 mg/ml), centrifuged and frozen at −20°C. Calibration was always performed in pooled CSF. The limit of detection (LOD), estimated as signal-to-noise ratio 3:1, was 2 nM for 5-methyl-THF, 5 nM for MTX, and 20 nM for calcium folinate, the lower limit of quantification (LLOQ) was 10, 20, and 100 nM, respectively.

Analysis of SAM and SAH

Determination of SAM and SAH in the CSF was performed using HPLC with fluorescence detection. The stationary phase was an EclipseTM AAA column (15 cm × 0.46 cm, 5 μm) from Agilent Technologies Inc., (Palo Alto, CA), and a NucleosilTM precolumn (2 cm × 0.46 cm, 5 μm) from Supelco. Fluorescence detection of SAM and SAH was enabled by derivatization with 5.5 M chloroacetaldehyde at pH 3.5–4.0, 39°C for 16 hr as described by Wagner et al. [33]. The mobile phase consisted of acetonitrile and a buffer (pH 4.5) containing 40 mM of potassium dihydrogen phosphate and 8 mM of the ion-pair reagent 1-heptanesulfonic acid. Analytes were separated by gradient elution. The injection volume was 100 μl, the flow rate 1 ml/min and detection was performed at 270/410 nm. Perchloric acid 1.2 M was used to ensure sufficient stability of the analytes. Samples were centrifuged and frozen at −20°C. The method was validated according to the FDA Guideline for Bioanalytical Method Validation [32]. Pooled CSF was always used for calibration. LOD was 5 nM for SAM and 1 nM for SAH. LLOQ was 25 and 5 nM for SAM and SAH, respectively.

Statistical Analysis

Statistics was performed with SPSSTM 12.0 using appropriate nonparametric tests. The level of significance was set to $P < 0.05$.

RESULTS

Due to different treatment modalities of ALL BFM 2000 protocols it was possible to distinguish between treatment with intrathecal MTX without calcium folinate rescue (protocols I, II, and III) and high-dose/intrathecal MTX followed by rescue (protocol M). The sample obtained on day 1 of protocol I was considered as reference since patients had not received MTX before (pretreatment sample).

Concentration of Reduced Folates and MTX in Non-Toxic Patients

CSF concentrations of 5-methyl-THF in non-toxic patients are depicted in Figure 2. In protocol I, the concentrations of 5-methyl-THF were significantly lower ($P = 0.002$, Mann–

Whitney *U*-test) only on day 12 after beginning treatment but not subsequently. In protocols II and III, a large interindividual variability was observed and CSF 5-methyl-THF concentrations were not significantly different to the pretreatment values. MTX was not detected.

In protocol M, samples were obtained during the high-dose MTX infusion (1 hr after start) just prior to intrathecal MTX. The concentration of MTX varied from 0.09–1.6 μM (median 0.5 μM). The Kruskal–Wallis test did not reveal significant differences neither among the concentrations of 5-methyl-THF within protocol M ($P = 0.285$) nor compared to the pretreatment values ($P = 0.132$). Calcium folinate was not detected in any sample.

Concentration of SAM and SAH in Non-Toxic Patients

CSF concentrations of SAM in non-toxic patients are presented in Figure 3. The concentrations of SAM were significantly lower in protocol I on day 12, 33, and 45 compared to the pretreatment values (Mann–Whitney *U*-test, $P = 0.012$, $P = 0.031$, and $P = 0.033$, respectively). In addition, a matched-pair comparison performed in seven patients on day 1 and 12 confirmed the difference (Wilcoxon test, $P = 0.018$). During protocols II and III, concentrations of SAM were also significantly lower compared to the reference (Mann–Whitney *U*-test, $P < 0.001$ and $P = 0.012$, respectively). In protocol M, there was no significant difference among the CSF SAM concentrations and compared to the reference samples (Kruskal–Wallis test, $P = 0.380$ and $P = 0.501$, respectively). SAH was detected in all samples but quantified only in 19 (5.0–11.4 nM).

Cases With Subacute Neurotoxicity

CTC evaluation of neurotoxic symptoms is presented in Table I. The concentrations of 5-methyl-THF and SAM in neurotoxic patients are shown in Figure 4. Case 1 developed subacute neurotoxicity 10 days after his third high-dose MTX infusion (protocol M). The patient complained of headache and dizziness, was agitated and irritable. Hemiparesis was present on the right body side and left facial side. Symptoms resolved completely within a few days and treatment was continued. Ten days after the next high-dose MTX infusion neurotoxicity reoccurred. This time hemiparesis presented in the left body-half and the right facial side. At this time-point MRI of the brain revealed ischemic lesions in the white matter characterized as supraventricular infarctions. Signs of toxicity persisted for 24 hr then resolved abruptly and completely. The concentration of 5-methyl-THF in the first CSF sample (taken prior to any toxicity) was comparable to the median reference concentration. Following neurotoxicity the concentration of the reduced folate decreased but was again in the normal range 1 month later. In contrast, the concentration of SAM was considerably lower in all three samples than the median reference value. SAH was determined in all three samples (6.7, 8.6, and 6.4 nM chronologically).

Case 2 developed signs of subacute neurotoxicity 1 week after his first high-dose MTX infusion (protocol M). The patient exhibited paresis in the right hand, which lasted about 36 hr. After the second high-dose MTX the same symptoms occurred in the left hand and leg and the patient suffered from a transient speech disorder. At this time-point neurotoxicity evaluation was performed according to CTC (see Table I). MRI revealed demyelination but

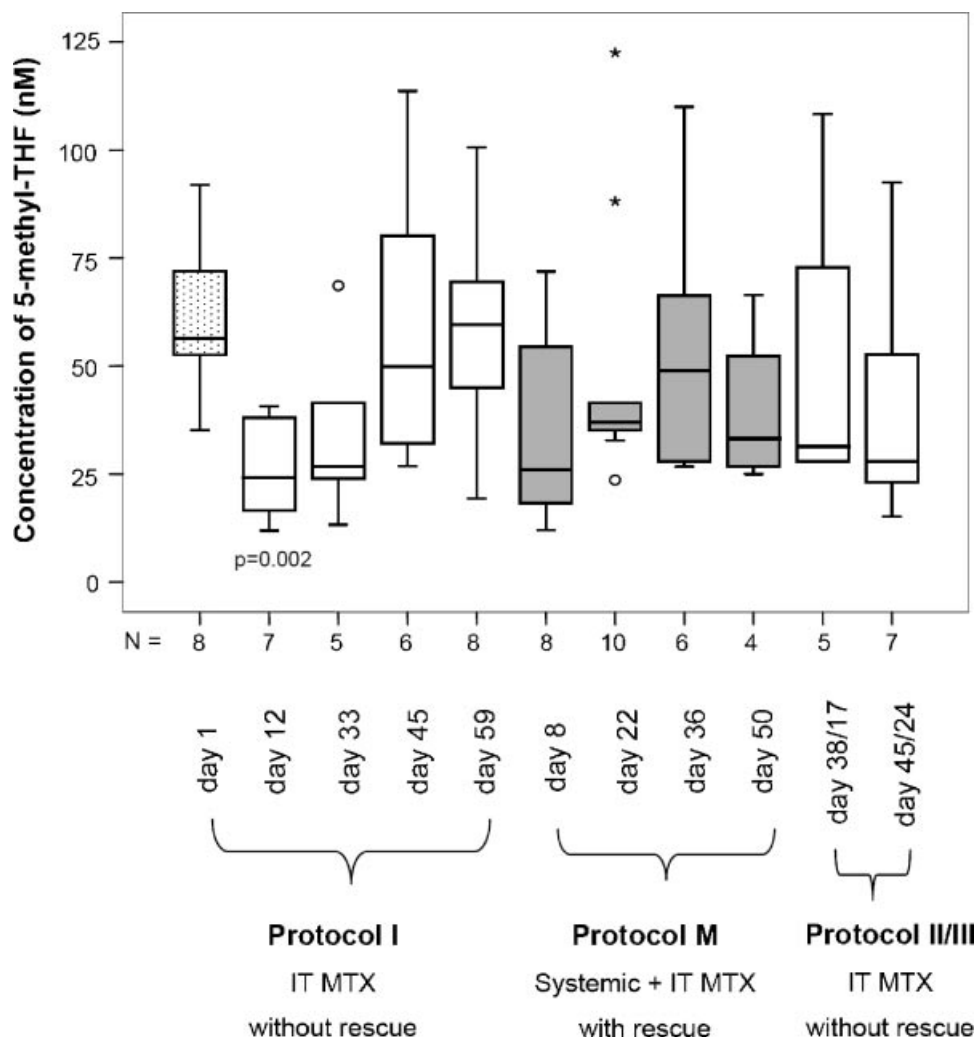


Fig. 2. CSF concentrations of 5-methyl-THF during the protocols of ALL BFM 2000 in patients without signs of neurotoxicity. Dotted box: prior to MTX therapy; white boxes: protocols with intrathecal (IT) MTX without rescue; gray boxes: protocols with systemic high-dose and IT MTX and rescue. * and ° represent outliers.

neither ischemic lesions nor overt disease were observed. Within 72 hr the clinical symptoms resolved with the exception of an intention tremor and altered reflex activity. This patient exhibited a lower CSF concentration of 5-methyl-THF in all samples compared to the reference of ALL population. SAM concentration was considerably decreased shortly after the second toxic episode compared to the sample obtained during protocol I prior to toxicity episodes. Later on the concentration of SAM increased again but was still lower than the median reference concentration. The concentration of SAH ranged from 5.8 to 12.6 nM.

DISCUSSION

This study was conducted to describe MTX-associated alterations in the folate/methyl-transfer pathway by measuring selected metabolites in the CSF. Our data indicate that calcium folinate rescue is of major importance for a rapid normalization of CSF concentrations of reduced folates and S-adenosylmethionine (SAM). After systemic administration of MTX followed by rescue CSF 5-methyl-THF concentrations were not significantly different

from pretreatment samples. Such finding was expected since it was shown that administration of calcium folinate leads to an increase of CSF 5-methyl-THF concentrations [34]. However, CSF 5-methyl-THF concentrations were significantly lower after the first intrathecal MTX administration without concomitant rescue. Surtees and Hyland also reported decreased CSF 5-methyl-THF concentrations after the initial intrathecal MTX administration in a pediatric ALL population [35]. At later times during treatment, the reduced folate levels were not significantly different compared to the pretreatment value.

Calcium folinate was not detected in the CSF of our patients. This could be expected since systemic calcium folinate poorly passes the blood–brain barrier due to its rapid peripheral conversion into 5-methyl-THF [34,36,37].

The CSF SAM concentrations were not significantly different from the pretreatment values 2 weeks after high-dose MTX administration followed by rescue. In contrast, SAM concentrations were decreased continuously during the application of protocols in which patients received intrathecal therapy without rescue. Surtees and Hyland reported similar findings [35]. In contrast, Kishi et al.

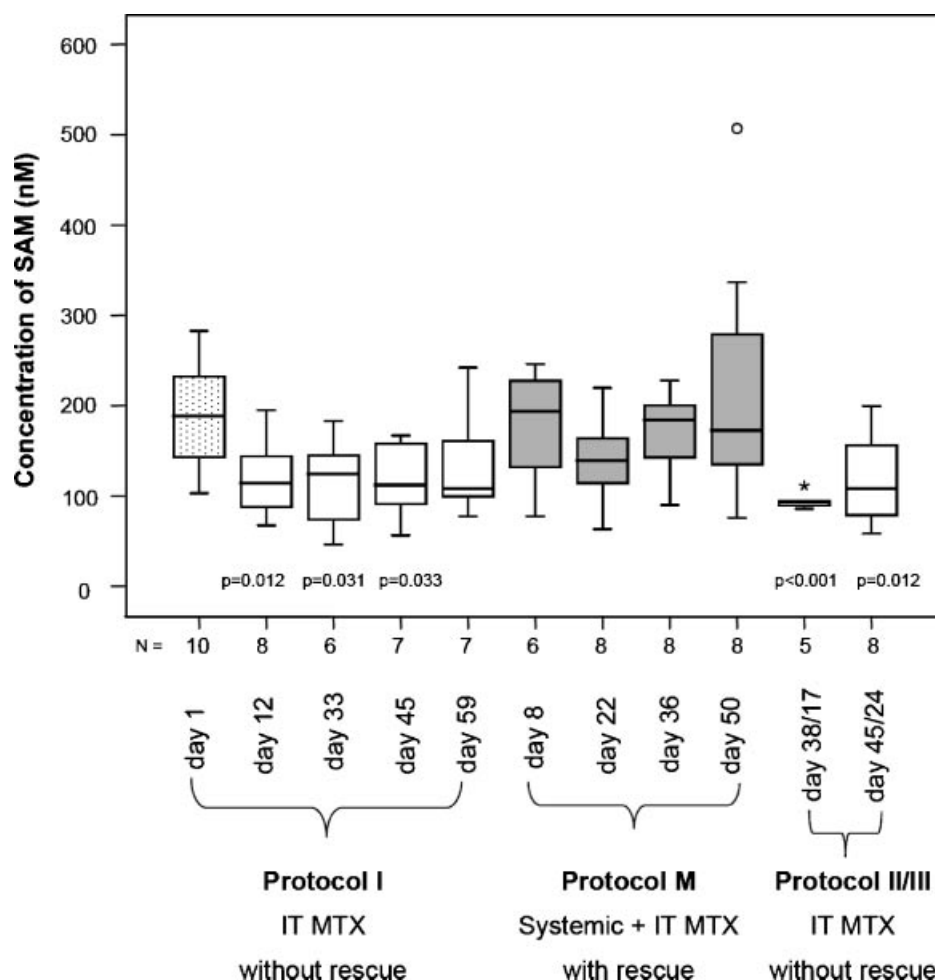


Fig. 3. CSF concentrations of SAM during the protocols of ALL BFM 2000 in patients without signs of neurotoxicity. Dotted box: prior to MTX therapy; white boxes: protocols with intrathecal (IT) MTX without rescue; gray boxes: protocols with systemic high-dose and IT MTX and rescue. * and ° represent outliers.

[30] observed decreased CSF SAM concentrations 10 days after high-dose and intrathecal MTX administration followed by rescue. However, these patients had also been irradiated and it is unclear to which extent it could have influenced the biochemical alterations in the CNS.

Our results suggest that decreased CSF 5-methyl-THF concentrations may persist when MTX administration is not followed by rescue and induce the decrease of CSF SAM concentrations. This could explain why 1–3 weeks after intrathecal MTX administration without rescue CSF SAM concentrations were low whereas at the

TABLE I. CTC Evaluation of Neurotoxicity Symptoms in Case 1 and 2

Symptom	Grade	Description of severity according to CTC
Case 1		
Headache	2	Moderate pain
Ataxia	2	Mild symptoms interfering with function, but not interfering with activities of daily living
Dizziness	3	Interfering with activities of daily living
Irritability	1	Mild, easily consolable
Mood alteration	1	Mild mood alteration not interfering with function
Cranial neuropathy	3	Present, interfering with activities of daily living
Motor neuropathy	4	Paralysis
Pyramidal tract function	4	Bedridden or disabling; paralysis
CNS cerebrovascular ischemia	2	Not described
Case 2		
Motor neuropathy	3	Objective weakness, interfering with activities of daily living
Speech impairment	3	Receptive or expressive dysphasia, impairing ability to communicate

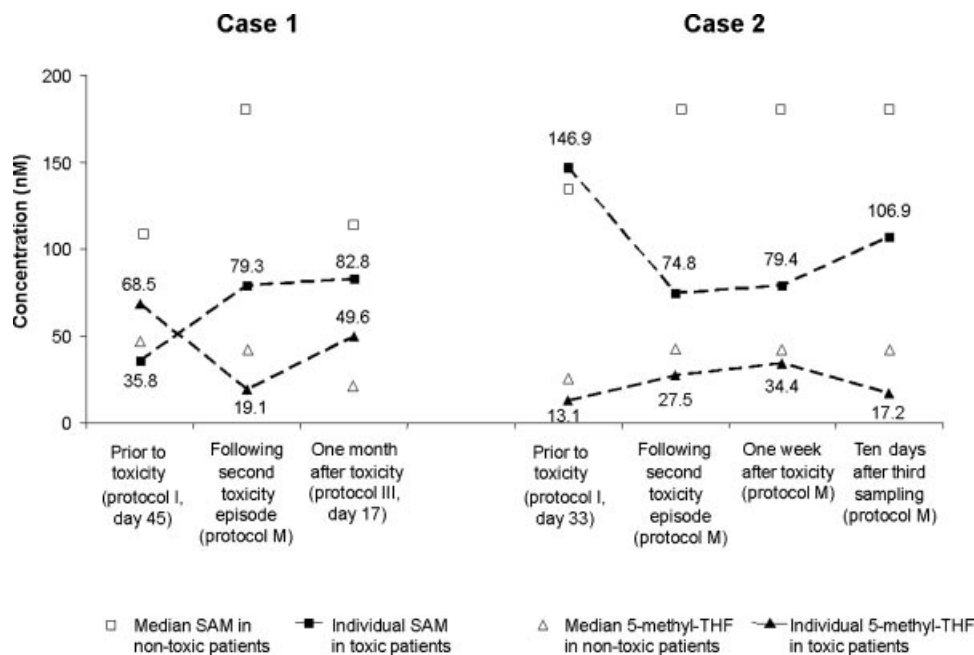


Fig. 4. CSF 5-methyl-THF and SAM concentrations prior to and after the second neurotoxicity episode in case 1 and 2 (filled symbols) compared to non-toxic patients at comparable time-points (open symbols). Metabolite levels in samples during or shortly after toxicity were compared to median values of the non-toxic population during protocol M since toxicity episodes in both patients occurred during this protocol.

same time 5-methyl-THF concentrations were possibly in repletion and therefore not significantly different of the pretreatment values.

Although SAH was detected in all samples it could only be quantified in 23% of them. In general, we found slightly lower CSF SAH concentrations compared to literature data. Concentrations ranged from about 1 to 12.6 nM compared to 8.9–14.1 nM in the study of Struys et al. [38]. Nevertheless, in all samples of both patients with neurotoxicity, SAH concentrations were higher than the LLOQ (5 nM) suggesting that it may play a role in the genesis of toxicity [30,39].

Two patients developed signs of subacute MTX-related neurotoxicity after administration of high-dose and intrathecal MTX followed by rescue. Neurotoxicity was confirmed by MRI, which has been shown to reflect subacute neurotoxicity and transient leukoencephalopathy [40,41]. Both patients had low 5-methyl-THF and considerably decreased SAM concentrations shortly after toxicity episodes indicating that these patients exhibited biochemical disorders possibly related to MTX administration. Decreased CSF 5-methyl-THF or SAM levels similar to our patients were also reported in other cases of subacute neurotoxicity [30,42].

In conclusion, our results show that biochemical alterations in both folate and methyl-transfer pathway occur after intrathecal MTX administration without concomitant rescue. Patients with neurotoxicity had a more pronounced decrease of 5-methyl-THF and SAM concentrations during or shortly after toxicity compared to non-toxic patients. Furthermore, both neurotoxic patients exhibited changes in the white matter. If biochemical alterations of the folate and methyl-transfer pathway are common in the ALL population treated with MTX and severe alterations may induce toxicity then monitoring of 5-methyl-THF and particularly SAM concentrations in the CSF of patients with ALL may help predict patients at risk of developing signs of chronic neurotoxicity.

Certainly, the possible role of the described alterations in the pathogenesis of MTX-associated neurotoxicity deserves further investigation.

ACKNOWLEDGMENT

This work was supported by a grant of the German Academic Exchange Service (DAAD) for Sandra Vezmar. Their help and collaboration is very much appreciated.

REFERENCES

- Allen JC, Rosen G. Transient cerebral dysfunction following chemotherapy for osteogenic sarcoma. *Ann Neurol* 1978;3:441–444.
- Allen JC, Rosen G, Mehta BM, Horten B. Leukoencephalopathy following high-dose iv methotrexate chemotherapy with leucovorin rescue. *Cancer Treat Rep* 1980;64:1261–1273.
- Colamaria V, Caraballo R, Borgna-Pignatti C, et al. Transient focal leukoencephalopathy following intraventricular methotrexate and cytarabine. A complication of the Ommaya reservoir: Case report and review of the literature. *Childs Nerv Syst* 1990;6:231–235.
- Bleyer WA. Neurologic sequelae of methotrexate and ionizing radiation: A new classification. *Cancer Treat Rep* 1981;65: Suppl 1 89–98.
- Quinn CT, Kamen BA. A biochemical perspective of methotrexate neurotoxicity with insight on nonfolate rescue modalities. *J Investig Med* 1996;44:522–530.
- Vezmar S, Becker A, Bode U, Jaehde U. Biochemical and clinical aspects of methotrexate neurotoxicity. *Chemotherapy* 2003;49: 92–104.
- Brock S, Jennings HR. Fatal acute encephalomyelitis after a single dose of intrathecal methotrexate. *Pharmacotherapy* 2004;24:673–676.

8. Walker RW, Allen JC, Rosen G, Caparros B. Transient cerebral dysfunction secondary to high-dose methotrexate. *J Clin Oncol* 1986;4:1845–1850.
9. Yim YS, Mahoney DH, Jr., Oshman DG. Hemiparesis and ischemic changes of the white matter after intrathecal therapy for children with acute lymphocytic leukemia. *Cancer* 1991;67:2058–2061.
10. Asato R, Akiyama Y, Ito M, et al. Nuclear magnetic resonance abnormalities of the cerebral white matter in children with acute lymphoblastic leukemia and malignant lymphoma during and after central nervous system prophylactic treatment with intrathecal methotrexate. *Cancer* 1992;70:1997–2004.
11. Packer RJ, Grossman RI, Belasco JB. High dose systemic methotrexate-associated acute neurologic dysfunction. *Med Pediatr Oncol* 1983;11:159–161.
12. Colosimo C, Di Lella GM, Petrone AM, et al. CNS radio-chemoprophylaxis in children with acute lymphoblastic leukemia. Neurotoxicity and diagnostic imaging. *Rays* 1994;19:511–526.
13. Ochs J, Mulhern R, Fairclough D, et al. Comparison of neuro-psychologic functioning and clinical indicators of neurotoxicity in long-term survivors of childhood leukemia given cranial radiation or parenteral methotrexate: A prospective study. *J Clin Oncol* 1991; 9:145–151.
14. Paakko E, Harila-Saari A, Vanionpaa L, et al. White matter changes on MRI during treatment in children with acute lymphoblastic leukemia: Correlation with neuropsychological findings. *Med Pediatr Oncol* 2000;35:456–461.
15. Jacobs SA, Adamson RH, Chabner BA, et al. Stoichiometric inhibition of mammalian dihydrofolate reductase by the gamma-glutamyl metabolite of methotrexate, 4-amino-4-deoxy-N-10-methylpteroylglutamyl-gamma-glutamate. *Biochem Biophys Res Commun* 1975;63:692–698.
16. Jolivet J, Chabner BA. Intracellular pharmacokinetics of methotrexate polyglutamates in human breast cancer cells. Selective retention and less dissociable binding of 4-NH₂-10-CH₃-pteroylglutamate4 and 4-NH₂-10-CH₃-pteroylglutamate5 to dihydrofolate reductase. *J Clin Invest* 1983;72:773–778.
17. Cantoni GL. Biological methylation: Selected aspects. *Annu Rev Biochem* 1975;44:435–451.
18. Hirata F, Axelrod J. Phospholipid methylation and biological signal transmission. *Science* 1980;209:1082–1090.
19. Barber JR, Clarke S. Inhibition of protein carboxyl methylation by S-adenosyl-L-homocysteine in intact erythrocytes. *J Biol Chem* 1984;259:7115–7122.
20. Zappia V, Zydek-Cwick CR, Schlenk F. The specificity of S-adenosylmethionine derivatives in methyltransfer reactions. *J Biol Chem* 1969;244:4499–4505.
21. Allegra CJ, Fine RL, Drake JC, Chabner BA. The effect of methotrexate on intracellular folate pools in human MCF-7 breast cancer cells. Evidence for direct inhibition of purine synthesis. *J Biol Chem* 1986;261:6478–6485.
22. Allegra CJ, Hoang K, Yeh GC, et al. Evidence for direct inhibition of de novo purine synthesis in human MCF-7 breast cancer cells as a principal mode of metabolic inhibition by methotrexate. *J Biol Chem* 1987;262:13520–13526.
23. Abelson HT. Methotrexate and central nervous system toxicity. *Cancer Treat Rep* 1978;62:1999–2001.
24. Quinn CT, Griener JC, Bottiglieri T, et al. Elevation of homocysteine and excitatory amino acid neurotransmitters in the CSF of children who receive methotrexate for the treatment of cancer. *J Clin Oncol* 1997;15:2800–2806.
25. Quinn CT, Griener JC, Bottiglieri T, Kamen BA. Methotrexate, homocysteine, and seizures. *J Clin Oncol* 1998;16:393–394.
26. Quinn CT, Griener JC, Bottiglieri T, et al. Effects of intraventricular methotrexate on folate, adenosine, and homocysteine metabolism in cerebrospinal fluid. *J Pediatr Hematol Oncol* 2004;26:386–388.
27. Ramaekers VT, Häusler M, Opladen T, et al. Psychomotor retardation, spastic paraplegia, cerebellar ataxia, and dyskinesia associated with low 5-methyltetrahydrofolate in cerebrospinal fluid: A novel neurometabolic condition responding to folinic acid substitution. *Neuropediatrics* 2002;33:301–308.
28. Hyland K, Smith I, Bottiglieri T, et al. Demyelination and decreased S-adenosylmethionine in 5,10-methylenetetrahydrofolate reductase deficiency. *Neurology* 1988;38:459–462.
29. Surtees R, Leonard J, Austin S. Association of demyelination with deficiency of cerebrospinal-fluid S-adenosylmethionine in inborn errors of methyl-transfer pathway. *Lancet* 1991;338:1550–1554.
30. Kishi T, Tanaka Y, Ueda K. Evidence for hypomethylation in two children with acute lymphoblastic leukemia and leukoencephalopathy. *Cancer* 2000;89:925–931.
31. Belz S, Frickel C, Wolf from C, et al. High-performance liquid chromatographic determination of methotrexate, 7-hydroxymethotrexate, 5-methyltetrahydrofolic acid and folinic acid in serum and cerebrospinal fluid. *J Chromatogr B* 1994;661:109–118.
32. US Department of Health and Human Services, and Food and Drug Administration. Guidance for industry: Bioanalytical method validation, 2001.
33. Wagner J, Hirth Y, Claverie N, Danzin CA. Sensitive high-performance liquid chromatographic procedure with fluorometric detection for the analysis of decarboxylated S-adenosylmethionine and analogs in urine samples. *Anal Biochem* 1986;154:604–617.
34. Thyss A, Milano G, Etienne MC, et al. Evidence for CSF accumulation of 5-methyltetrahydrofolate during repeated courses of methotrexate plus folinic acid rescue. *Br J Cancer* 1989;59:627–630.
35. Surtees R, Hyland K. Cerebrospinal fluid concentrations of S-adenosylmethionine, methionine, and 5-methyltetrahydrofolate in a reference population: Cerebrospinal fluid S-adenosylmethionine declines with age in humans. *Biochem Med Metab Biol* 1990;44: 192–199.
36. Mehta BM, Glass JP, Shapiro WR. Serum and cerebrospinal fluid distribution of 5-methyltetrahydrofolate after intravenous calcium leucovorin and intra-Ommaya methotrexate administration in patients with meningeal carcinomatosis. *Cancer Res* 1983;43: 435–438.
37. Reggev A, Djerassi I. Rescue from high-dose methotrexate with 5-methyltetrahydrofolate. *Cancer Treat Rep* 1986;70:251–253.
38. Struys EA, Jansen EEW, de Meer K, Jakobs C. Determination of S-adenosylmethionine and S-adenosylhomocysteine in plasma and cerebrospinal fluid by stable-isotope dilution tandem mass spectrometry. *Clin Chem* 2002;46:1650–1661.
39. Weir DG, Molloy AM, Keating JN, et al. Correlation of the ratio of S-adenosyl-L-methionine to S-adenosyl-L-homocysteine in the brain and cerebrospinal fluid of the pig: Implications for the determination of this methylation ratio in human brain. *Clin Sci (Lond)* 1992;82:93–97.
40. Haykin M, Gorman M, van Hoff J, et al. Diffusion-weighted MRI correlates of subacute methotrexate-related neurotoxicity. *J Neuro-oncol* 2006;76:153–157.
41. Kuker W, Bader P, Herrlinger U, et al. Transient encephalopathy after intrathecal methotrexate chemotherapy: Diffusion-weighted MRI. *J Neurooncol* 2005;73:47–49.
42. Surtees R, Clelland J, Hann I. Demyelination and single-carbon transfer pathway metabolites during the treatment of acute lymphoblastic leukemia: CSF studies. *J Clin Oncol* 1998;16: 1505–1511.