

This Special Report
is supported by
a grant from



DISCLAIMER:

This monograph is designed to be a summary of information. While it is detailed, it is not an exhaustive clinical review. McMahon Publishing, Pamlab, and the author neither affirm nor deny the accuracy of the information contained herein. No liability will be assumed for the use of this educational review, and the absence of typographical errors is not guaranteed. Readers are strongly urged to consult any relevant primary literature. Copyright © 2009, McMahon Publishing, 545 West 45th Street, New York, NY 10036. Printed in the USA. All rights reserved, including the right of reproduction, in whole or in part, in any form.

Distributed by
McMahon Publishing



BROUGHT TO YOU BY

American Psychiatry
NEWS

PRIMARY CARE
QUARTERLY

PAIN MEDICINE

Special REPORT

MONTH 2009

Case Studies: *Novel Agent Slows Cognitive Decline in Patients With Age-Associated Memory Impairment*

Introduction, Case 1, and Case 2
authored by

Bennett Machanic, MD, FAAN

*Associate Clinical Professor of Neurology
University of Colorado
Denver, Colorado*

Case 3 and Case 4
authored by

Eugene Dagon, MD

*Clinical Associate Professor of Psychiatry
University of South Florida
Tampa, Florida*

Introduction

Normal aging includes changes in cognitive function but age-associated memory loss, memory impairment, and cognitive decline may indicate other conditions. Early Alzheimer's disease (AD) pathology has been shown to be associated with plaque deposition following abnormal cleavage of amyloid precursor protein by β - and γ -secretase. The plaque itself, or soluble amyloid, is believed to cause toxicity secondary to increased intracellular calcium and oxidative stress. When

serum homocysteine (Hcy) levels are elevated, this toxicity may be accentuated.¹

The Framingham Study demonstrated that elevated serum Hcy levels significantly increased the risk for the development of AD.² Furthermore, aging patients often experience a steady decline in cerebrospinal fluid (CSF) folate levels which may contribute to decreased methylation of homocysteine.³ Because both L-methylfolate (the bioactive form of folic acid) and methyl-B12 act as cofactors in the transformation of homocysteine to methionine, low CSF levels of folate and B12

MERCK EXHIBIT 2177

**Gnosis v Merck & Cie
IPR2013-00117**

MERCK ITC 02 00171518

may contribute to decreased acetylcholine synthesis.⁴ Finally, low levels of L-methylfolate and methyl-B12 are associated with increased risk for cognitive impairment.⁵

Current prescription medications for AD have been disappointing and many are considered only modestly effective.⁶ Among patients treated with cholinesterase inhibitors, potential treatment failure may be explained by low CSF levels of acetylcholine secondary to the above events.

High-dose folate supplementation has been shown to reduce serum Hcy levels and enhance cognitive performance.⁷ In patients with normal levels of vitamin B₁₂, high-dose folate supplementation may offer a protective effect and is associated with a 50% decreased risk of cognitive impairment.⁸ Supplementation with *N*-acetylcysteine (NAC) provides potent antioxidant protection by stimulating glutathione in the CSF which enhances free radical scavenging. NAC can also mitigate the toxic effects of β -amyloid caused by oxidative stress.⁹

Considering these concepts, it seems logical to consider using a medical food, L-methylfolate-methylcobalamin-NAC (CerefolinNAC®), to assist in slowing cognitive decline in older patients. Evidence is mounting regarding the potential benefits of nutraceuticals and vitamins.⁹ The combination of L-methylfolate, vitamin B₁₂, and NAC may help to reduce elevated Hcy levels, decrease oxidative stress, enhance the synthesis of acetylcholine, and increase CSF folate levels. Because CerefolinNAC contains the methylated form of folate (L-methylfolate) and vitamin B₁₂, it can easily pass through the blood-brain barrier, which may be difficult in at least 50% of patients due to genetic variations.¹⁰ As illustrated in the following case reports, many patients with age-associated memory impairment or cognitive decline stabilize after starting CerefolinNAC.

Bennett Machanic, MD, FAAN

Associate Clinical Professor of Neurology
University of Colorado
Denver, Colorado

Case 1: Elderly Patient With Progressive Memory Loss

Presentation

K.M. is a 70-year-old right-handed white woman who was referred for neurologic consultation to evaluate progressive memory loss during a 6-month period. She arrived at the office accompanied by her husband, who provided most of the history. The patient is a retired homemaker living with her husband in a detached, single-family dwelling. K.M. is the mother of 2 children and grandmother of 3.

Medical History

Past medical history revealed tonsillectomy and adenoidectomy, cervical carcinoma treated by hysterectomy without

evidence of metastasis, and bilateral carpal tunnel release surgery. She had chronic low back and leg pain and underwent lumbar laminectomy at L5-S1. The patient also had a history of asthma, allergic seasonal rhinitis, and degenerative arthritis of the right hip, and recently, she was given a diagnosis of fibromyalgia. Her migraine headaches have been in remission since menopause. Family medical history revealed a maternal uncle and a maternal grandmother with AD.

Current medications included 81 mg of aspirin daily, simvastatin for hyperlipidemia, furosemide for pedal edema, trazodone for insomnia, naproxen for arthritis pain, oxycodone for more severe pain, gabapentin for fibromyalgia, tiotropium (Spiriva) and fluticasone (Advair) inhalers as needed, fluticasone (Flo-nase) as needed for rhinitis, and over-the-counter famotidine (Pepcid), FiberCon, supplemental potassium (Klor-Con), and multivitamins.

Three years ago, K.M. had a severe viral infection that manifested as pneumonia, acute renal failure, transient uremia, and hyperammonemia, with secondary coma but negative spinal fluid studies. She fully recovered in 4 months but had some difficulties with speech and orientation during the recovery process.

Six months ago, K.M. began to lose objects and get lost while driving. She often seemed to have difficulty remembering recipes and moving clothes from the washing machine to the dryer. On occasion, she would use a mop for vacuuming. Her husband took over writing checks and managing the family business activities.

Before the office visit, the patient underwent computed axial tomography of the brain, which showed "mild atrophy consistent with age." Blood studies showed normal chemical and hematologic profiles with the exception of an elevated low-density lipoprotein cholesterol level of 135 mg/dL and a high-density lipoprotein cholesterol level of 32 mg/dL. K.M. also underwent a carotid duplex scan, which was unremarkable; thyroid studies and vitamin B₁₂ and methylmalonic acid levels were normal.

Clinical examination revealed an alert, responsive, well-dressed and well-groomed woman with appropriate behavior and manners. K.M. was talkative and pleasant. She exhibited occasional dysnomia and constructional apraxia during interlocking hand mimicry. She also was incapable of performing repetitive alternating hand gestures. However, she was able to incorporate 4 out of 4 items after 5 trials and retrieved all 4 items at 3 minutes. She had difficulty with abstractions and failed reverse spelling of words with more than 5 letters.

K.M. received a score of 25 on the Mini-Mental State Examination (MMSE)¹¹, a score of 3 (highest possible score, 4) on the clock drawing test,¹² and a score of 14 (normal, >18) on the Milner Verbal Fluency test.¹³ She demonstrated decreased range of motion in the lumbar spine, diminished pin sensation in the left L5 dermatome, minimal weakness of the left extensor hallucis longus, and absence of jerk reflex in the left ankle. Results of the remainder of the neurologic examination were normal.

K.M. underwent subsequent studies, including electroencephalography (EEG), which showed a slow rhythm of 7 to 8 Hz; single-photon emission computed tomography (SPECT), which was consistent with decreased perfusion over the parietal and temporal areas; and magnetic resonance imaging (MRI), which showed multiple white matter intensities on T2-weighted imaging without infarcts and associated diffuse atrophy. Hcy studies

revealed a level of 14.5 $\mu\text{mol/L}$ (normal, 5.4-10.4 $\mu\text{mol/L}$), and fibrinogen studies revealed a level of 461 mg/dL (normal, <435 mg/dL). Mild AD was diagnosed.

Treatment

Initially, K.M. was placed on 5 mg of donepezil hydrochloride daily. However, severe diarrhea and florid nightmares developed, and the medication was discontinued after 8 days. A trial of rivastigmine tartrate caused severe nausea, and her husband declined any further trials with cholinesterase inhibitors.

CerefolinNAC once daily was initiated.

Outcome

At the 10-week follow-up, K.M. exhibited a dramatic change. Her husband felt that "a miracle had occurred." He described improvements in attention span, organization, interaction, and efficiency. He felt her conversations were more appropriate. During the follow-up examination, she achieved scores of 28 on the MMSE,¹¹ 3 on clock drawing,¹² and 16 on the Milner Verbal Fluency test.¹³ However, the dysnomia persisted, and the hand apraxia was unchanged.

At the 14-month follow-up, K.M. continued to maintain cognitive stability and showed minimal organizational dysfunction, with a subtle increase in periodic confusion and disorientation. Her husband said that she has remained stable with the ability to have a conversation and interact with others. Her MMSE¹¹ score was 24 and her Milner Verbal Fluency test¹³ score was 15. She recently started pregabalin for fibromyalgia and is no longer taking gabapentin.

Case 2: Middle-aged Patient With Signs of Memory Loss

Presentation

R.F., a 63-year-old right-handed black man, is a corporate executive who works full time. He was referred for neurologic consultation because of numbness in his feet during a 2-year period and subjective insidious memory loss during an 18-month period. R.F. is married and the father of 2 children.

Medical History

Previously, R.F. had been quite healthy. A fall from a tree at the age of 8 years caused a transient loss of consciousness. During high school, he sustained "2 or 3 concussions" while playing football, and at age 57, he sustained "closed head trauma" during a motor vehicle accident. Other than for an emergency appendectomy at age 12, he never required hospitalization.

R.F. had a history of mild glucose intolerance that was successfully managed with dietary restrictions and a history of gastroesophageal reflux disease, for which he was not taking medication. He had experienced "mild depression" for 4 years and felt it was controlled with 10 mg of escitalopram oxalate daily. Periodic anxiety was managed with 1 mg of lorazepam at bedtime 2 or 3 times weekly. His elevated levels of cholesterol appeared to respond well to dietary modifications. R.F. rarely drank alcohol and usually supplemented his diet with vitamins. His family medical history included a father with diabetes who died of a stroke, and he vaguely remembered a maternal aunt and a paternal cousin with memory loss.

R.F. began noticing foot pain after standing at group business functions for several hours. He later noted increased pain while hiking with his children. He experienced numbness in the soles of his feet about 2 years ago, but subsequently the foot pain seemed to lessen. A podiatrist diagnosed plantar fasciitis and provided orthotics, which were helpful. An evaluation for diabetes was performed at the time and showed slight hyperglycemia. Results of electromyography (EMG) were consistent with mild tarsal tunnel syndrome. During the 3 months before his office visit, R.F.'s numbness and pain seemed to worsen.

Clinical examination revealed decreased pinprick sensation on the soles of both feet, and Tinel's sign was present bilaterally on palpation of the flexor retinaculum. The patient's deep tendon reflexes were absent in both lower extremities, but strength was full throughout. His MMSE¹¹ score was 29, and his Milner Verbal Fluency test¹³ score was 18 (normal, >18). R.F. was able to incorporate 4 difficult memory items after 2 trials and correctly retrieved all 4 items at 3 minutes. Very subtle dysnomia was noted. He was not notably anxious or depressed.

A series of diagnostic studies included the following: EEG, results of which were normal; MRI of the brain, which showed mild atrophy; and measurements of blood levels of vitamin B₁₂, methylmalonic acid, and thyroid-stimulating hormone, which were normal. Results of a rapid plasma reagin test and testing for HIV were negative. SPECT demonstrated decreased perfusion over the bilateral parietal area, and positron emission tomography (PET) confirmed decreased metabolism bilaterally in the parietal and temporal areas. The patient was heterozygous for the apolipoprotein E type 4 allele.

Clinical results indicated mild cognitive impairment, but results of the imaging studies were quite consistent with AD, and the mild dysnomia suggested early dementia.

Treatment

R.F. was resistant to starting medications of any kind because he was concerned about adverse effects. He finally agreed to try CerefolinNAC once daily.

Outcome

At follow-up visits during the 12 months after the initiation of treatment, no cognitive changes were noted clinically. His MMSE¹¹ score remained stable at about 30. His Milner Verbal Fluency test¹³ score stayed constant at 18. His speech patterns did not change. PET at the 1-year follow-up showed no change and demonstrated metabolic alterations similar to those seen at his initial visit. Recent EEG shows modest slowing (7-8 Hz) compared with prior tracing (background of 9-10 Hz).

R.F. is now retired and spends much of his time working for a local charity with his wife. She reports having to occasionally assist him with organizational skills but that he generally remains quite capable. He has undergone tarsal tunnel release surgery and has experienced excellent relief from his foot symptomatology. Recently, R.F. was given a diagnosis of type II diabetes and was started on an oral agent. He continues to resist starting a cholinesterase inhibitor and prefers to continue taking CerefolinNAC, which he feels is helpful.

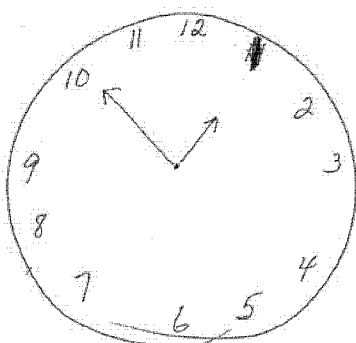


Figure 1

Clock-drawing test by J.O. on May 31, 2005 shows improper sequencing; patient was instructed to draw 11:10, but drew 12:50.¹²

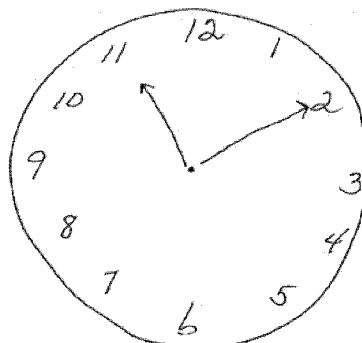


Figure 2

Clock-drawing test by J.O. on April 10, 2007; patient was instructed to place hands at 11:10.¹²

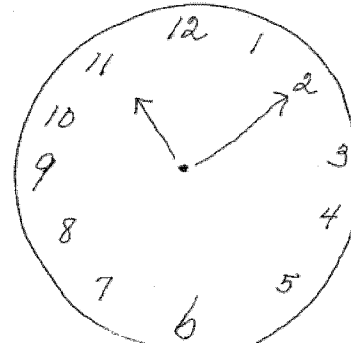


Figure 3

Clock-drawing test by J.O.; patient was instructed to place hands at 11:10; J.O.'s score fell to 1 out of 3.¹²

Eugene Dagon, MD

Psychiatrist
Tampa, Florida

Case 3: Mature Adult With Mild Cognitive Impairment

Presentation

J.O. is a 71-year-old white married woman who was referred for psychiatric consultation. Her chief complaints were symptoms of mild cognitive impairment, recurrent severe depression, and general anxiety with occasional panic attacks. She had a lifetime history of recurrent major depressive episodes.

Medical History

The patient was given a diagnosis of diabetes 9 months ago and placed on metformin. She had a significant cardiovascular history and had a myocardial infarction after placement of a stent to the obtuse marginal artery in February 1999. A technetium ^{99m}Tc sestamibi (Cardiolite) stress perfusion study performed in April 2005 revealed normal perfusion and a normal ejection fraction. Echocardiography in May 2006 showed mild global hypokinesis, mildly reduced systolic function (left ventricular ejection fraction, 45%), and mild mitral regurgitation. J.O. was taking 50 mg of captopril twice daily, metoprolol succinate, and 81 mg of enteric-coated aspirin. Her blood pressure was 130/80 mm Hg. She had hyperlipidemia that was being treated with colessevelam hydrochloride and fenofibrate. She also had hypothyroidism and was receiving 125 mcg of replacement levothyroxine daily, resulting in a normal thyroid function test. Her ophthalmologist had diagnosed early macular degeneration and prescribed vitamins E, B₆, and B₁₂.

Psychiatric evaluation revealed severe depression, indicated by a score of 25 out of 30 on the geriatric depression

scale (GDS).¹⁴ Her score on the Sheehan Patient-Rated Anxiety Scale¹⁵ was 49, and her score on the Generalized Anxiety Disorder Scale¹⁶ was slightly elevated. The depression began when J.O. was in her 20s with an episode of postpartum depression. A neurologist treated her with antidepressants. He did not diagnose dementia but noted ischemic brain changes and the possibility of early Parkinson's disease.

Further psychiatric history disclosed a woman with repeated depressive episodes. J.O. raised 3 children, did housework, decorated her home, and painted ceramics as a hobby. She was successful despite 20 lifetime episodes of major depression. She enjoyed spending time with her grandchildren, occasionally going out to dinner, and playing cards with friends. Sadly, these things were no longer giving her any pleasure and she became a recluse in her home. J.O. had frequent thoughts of death and had suicidal ideation without a plan. She felt hopeless and worthless, she experienced frequent crying spells, and she avoided any social gatherings, including those with her family.

Diagnosis

J.O. had a score of 28 on the MMSE.¹¹ She was oriented to time and place, with scores of 5 out of 5 on both sections of the examination. She could recall 3 out of 3 items on the recent memory portion of the test. She was able to spell "world" backward and made 1 error on the 3-stage command. On the clock-drawing test,¹² the patient showed improper sequencing; she started the clock backward, with the 11 in the 1-o'clock position. This was quickly scratched over and replaced with a 1. The spacing was also impaired. The patient was instructed to place the hands of the clock at 10 minutes past 11 o'clock, but she placed them at 10 minutes to 1 o'clock (Figure 1). Her score on the clock-drawing test¹² was 0 out of 3 for clock sequence and spacing—a significant cognitive impairment that was not evident on the MMSE.¹¹

As a starting point to managing J.O.'s clinical problems, I requested a second opinion by the senior neuroradiologist.

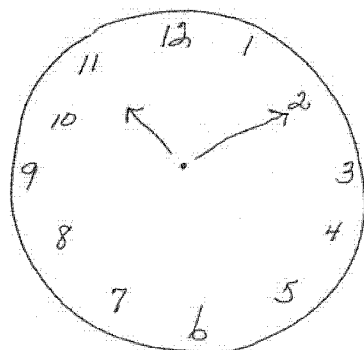


Figure 4

Clock-drawing test by J.O.; patient was instructed to place hands at 11:10; J.O.'s score returned to 3 out of 3.¹²

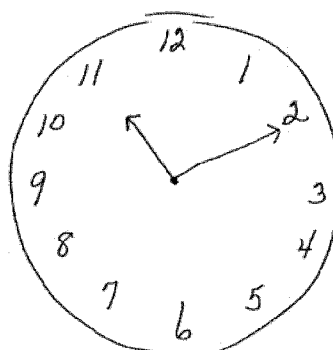


Figure 5

Clock-drawing test by J.O.; patient was instructed to place hands at 11:10; J.O.'s score remained constant.¹²

He reread the MRI scans obtained from January to June 2005, noting appreciable white matter vascular disease and mild amygdalar-hippocampal atrophy that was 1+4 greater on the right than on the left. The neuroradiologist felt that this finding could support a clinical diagnosis of AD and noted that there was no ischemic disease or iron deposition in the basal ganglia to suggest the presence of a parkinsonian abnormality.

Although the MRI ruled out Parkinson's disease, it was unclear whether the loss of hippocampal volume was indicative of AD or chronic depression. Serum levels of Hcy, folic acid, and vitamin B₁₂ were measured. The results were as follows: Hcy, 19.5 µmol/L; folate, 19.3 ng/mL; and vitamin B₁₂, 917 pg/mL.

Treatment

J.O. began taking CerefolinNAC in May 2005.

She also received a combination of antidepressants including escitalopram oxalate and mirtazepine. When this did not produce a robust response, escitalopram oxalate was discontinued and replaced with venlafaxine hydrochloride, which was titrated from 75 to 150 and then to 225 mg. Although she had considerable heartburn, this was relieved with esomeprazole magnesium, and her blood pressure remained stable. J.O.'s Hcy level decreased to 10.4 µmol/L within a few months. However, the level was still in the upper quadrant and posed a significant risk to the patient.

Outcome

J.O. remained well, with GDS¹⁴ scores ranging from 4 to 9, an MMSE¹¹ score of 30, and clock-drawing test¹² scores of 3 out of 3 over a 2-year period (Figure 2). A recurrence of her depressive symptoms in June 2007 was relieved by increasing the dose of venlafaxine hydrochloride. New stresses included traveling to her granddaughter's wedding and making plans to accompany her husband on a trip to China. Her score on the GDS¹⁴ increased to 15, but her MMSE¹¹ score remained

at 30 and her clock-drawing test¹² score remained at 3 out of 3. After her trip to China, J.O.'s GDS¹⁴ score was 6 and her MMSE¹¹ score remained at 30, but her clock-drawing test score fell to 1 out of 3 (Figure 3). The patient agreed to a trial of the rivastigmine transdermal system. She had a score of 8 on the Beck Depression Inventory¹⁷ and her MMSE¹¹ score remained at 30, but her clock-drawing test¹² score returned to 3 out of 3 (Figure 4).

By August 2008, her Hcy level had increased to 12.1 µmol/L, her folate level was above 24 ng/mL, and her vitamin B₁₂ level was above 2,000 pg/mL. Although her mood remained upbeat and her MMSE and clock-drawing scores remained constant (Figure 5), a new test, the Montreal Cognitive Assessment (MoCA)¹⁸ detected deficits in visuospatial and executive functioning that the clock test² missed (Figure 6). The patient scored 4 out of 5 on the MoCA¹⁸ Delayed Memory Scale.

Two years depression-free with no apparent cognitive impairments, 74-year-old J.O.'s joie de vivre returned, and she had enough energy to travel to her granddaughter's wedding and an adventure in China.

Discussion

The addition of CerefolinNAC to J.O.'s treatment regimen provided a significant improvement for this patient. In conclusion, the earlier the intervention, the greater the opportunity for disease modification with CerefolinNAC.

In my experience, the MMSE¹¹ has not been as useful in diagnosing age-associated mental impairment or mild cognitive impairment as the clock-drawing test. The clock-drawing test may be particularly useful to identify visuospatial problems and to assess premotor frontal lobe planning and sequencing. However, the test must be performed correctly. Frequently, patients draw a 25- or 50-cent-size circle, which may indicate micrographia (a possible clue for Parkinson's disease) but invariably masks visuospatial impairment. Better information is obtained from having the patient draw larger circles of 3 to 4 in.

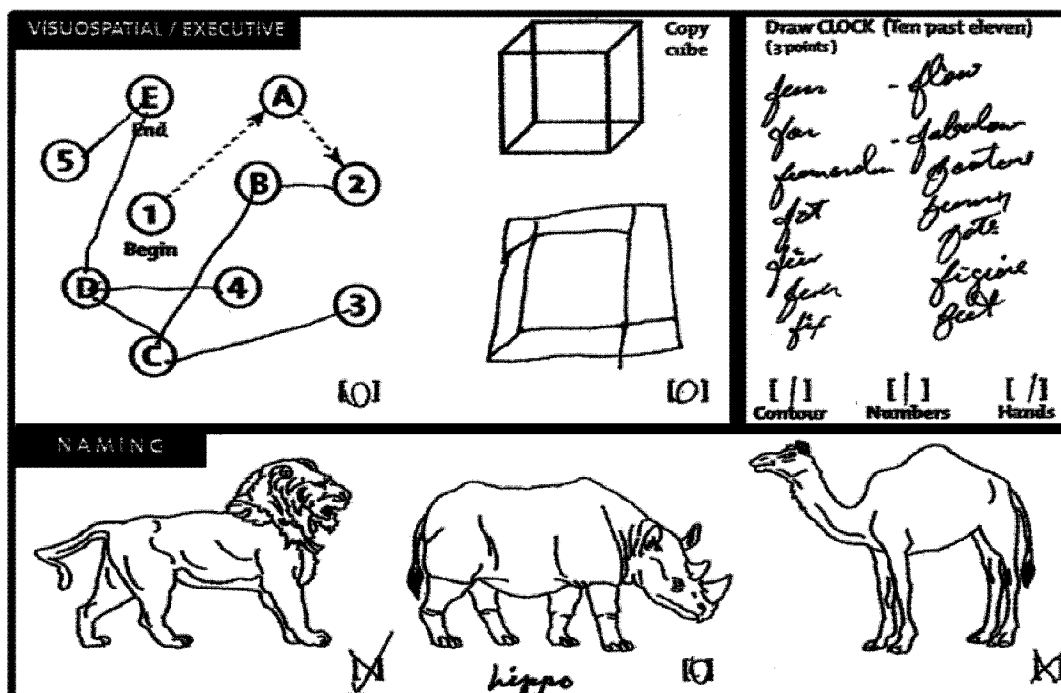


Figure 6

J.O. scored a 4 out of 5 on the Montreal Cognitive Assessment (MoCA) Delayed Memory Scale in August 2008.¹⁸ Her score returned to normal within 2 months after treatment.

MoCA test is reproduced with permission. Copyright Z Nasreddine MD. Available at www.mocatest.org

The practitioner should then ask the patient to place the number 12 in the correct position on the face of the clock and a dot in the exact center of the clock, and then instruct the patient to draw the hour and minute hands at the positions indicating 10 minutes after 11 o'clock.

In terms of treatment with supplementation, it is optimal to take a multivitamin without folate. A recent study published in *JAMA: The Journal of the American Medical Association*¹⁹ reported insufficient evidence to warrant the use of high-dose supplements of folic acid and vitamins B₆ and B₁₂. However, the study used unmetabolized folic acid, which is unable to cross the blood-brain barrier and may become bound to membrane receptors, so that the absorption of L-methylenetetrahydrofolate (L-MTHF) is blocked and the amount able to cross into the CSF is reduced.²⁰ Studies also have shown that because of the MTHF reductase genetic polymorphism C677T, the ability to transport L-methylfolate to the brain is compromised in half of the general population and two-thirds of patients with vascular dementia.²¹ If levels of L-MTHF in the brain are inadequate, the synthesis of dopamine, serotonin, and norepinephrine is increased, levels of toxic central nervous system proteins (phospho-tau and β -amyloid) are increased, and the synthesis of acetylcholine is decreased.²²

Case 4: Elderly Patient With Age-Associated Memory Impairment

Presentation

M.Z., a 69-year-old widow, first came in for a consultation in November 1998. Her husband of 25 years had succumbed to a lingering death from cancer 2.5 years earlier. She was depressed and still grieving at the loss of her husband.

Medical History

M.Z. had previously seen a psychiatrist, who prescribed a selective serotonin reuptake inhibitor (paroxetine hydrochloride). This helped very little, so she was switched to venlafaxine and received therapy to explore her attachments to her deceased husband and her family of origin. Her father had been a Polish immigrant who had difficulty finding work and learning English. He drank heavily. When he died, his wife and 3 young children had to go on welfare; M.Z. was the youngest of the 3 children. Her elder sister had 2 children and experienced several mental breakdowns that caused her to be in and out of hospitals. The elder brother had been dysfunctional and involved with drugs, and he had committed suicide at age 31.

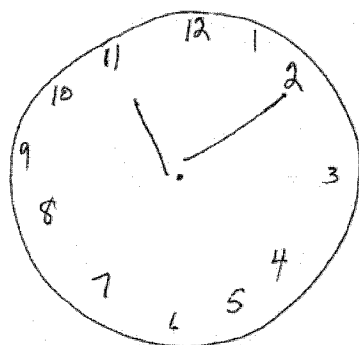


Figure 7

Clock-drawing test by M.Z. on January 8, 2008 shows impairment; patient was instructed to draw 11:10.¹²

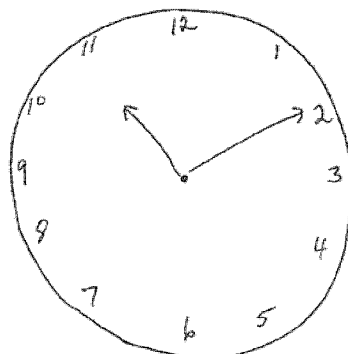


Figure 8

Clock-drawing test by M.Z. on July 3, 2008; patient was instructed to draw 11:10; M.Z. scores a 3 out of 3.¹²

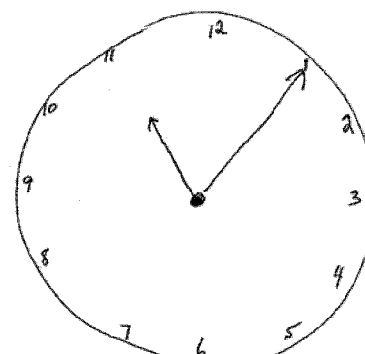


Figure 9

Clock-drawing test by M.Z. on November 6, 2008 shows normal functioning.¹²

M.Z. was helping to support her family at age 16. At 21 years of age, she became a secretary at a television network. Her organizational skills were rewarded with promotions, and she became an executive assistant. She lived at home with her mother and often cared for her sister's children when her sister was hospitalized. Her mother died when M.Z. was 41. She met and married her husband. After marriage, she retired from her television studio work. Her husband was 10 years older and a recovering alcoholic. He attended Alcoholics Anonymous and she attended Al-Anon. Her husband worked as an engineer and abstained from alcohol during the 20 years of his married life. The couple decided not to have children. They were companionable, with a good sex life.

However, because of her husband's prolonged ill health, M.Z. neglected her physical exercise, and she found herself socially isolated during his long illness. After his death, M.Z. experienced a significant sense of loss and solitude. It was suggested that she consider increasing her social activities, including performing volunteer work or doing something in which she could use her former organizational skills. M.Z. became involved in the widows' tennis league, mahjong club, book club, and theater club. She managed to keep busy, which helped her survive a normative crisis of aging for the better part of a decade. In her mid-70s, M.Z.'s participation in these activities slowed as she sprained her wrists and ankles and experienced falls on the tennis court. Reluctantly, she gave up tennis and some other activities.

M.Z. became frightened at age 78 when she became aware of problems with memory and had trouble concentrating on her book reading. She came in for another office visit at that time because she was worried about the development of dementia. She had a score of 30 on the MMSE¹¹ and did not appear depressed, with a score of 3 on the GDS.¹⁴ However, her score on the MoCA¹⁸ was 24. She could remember 2 of 5 items in the memory section. Furthermore, her clock drawing¹² was

impaired (Figure 7). It showed cognitive visuospatial errors, but not sequencing or hand errors. Measurement of her Hcy, folate, and vitamin B₁₂ levels revealed the following values: Hcy, 6.5 umol/L; folate, above 24 ng/mL vitamin B₁₂, 950 pg/mL. MRI showed mild cortical atrophy, moderate changes in the periventricular white matter, and mild ischemic changes in the basal ganglia bilaterally and in the brainstem, but no remarkable hippocampal or amygdalar atrophy.

Treatment

Based on the strength of her MoCA¹⁸ memory score and visuospatial deficits as indicated on the clock-drawing test,¹² the patient was started on CerefolinNAC. Within 1 month, she noted improved reading and memory skills. When she returned in July, her MoCA¹⁸ score had increased to 26, she remembered 3 out of 5 items on the memory portion of the test, her clock drawing also had improved (Figure 8), and she reported improved reading skills and renewed interest in reading. M.Z. returned for a visit in November 2008, at which time her MoCA¹⁸ score had increased to 28. She remembered 4 out of 5 items in the memory portion, and her clock drawing appeared normal (Figure 9). After 3 months, M.Z.'s love of reading returned and she joined the book club and mahjong group. Her love of literature and CerefolinNAC had helped her cope with another normative crisis of aging.

Outcome

In conclusion, did M.Z. have a diagnosis of age-associated memory impairment, mild cognitive impairment, or early AD? M.Z.'s case most closely mirrors that of a patient with early amnesic mild cognitive impairment. She warrants close observation in the future, given the 15% risk for conversion to dementia. Yearly MRI is recommended to follow potential changes in hippocampal volume. In addition, cholinergic therapy is recommended in case cognitive decline recurs.

References

1. Ho PI, Collins SC, Dhitavat S, Ortiz D, Ashline D, et al. Homocysteine potentiates beta-amyloid neurotoxicity: role of oxidative stress. *J Neurochem* 2001;78(2):249-253.
2. Seshadri S, Beiser A, Selhub J, Jacques PF, Rosenberg IH, et al. Plasma homocysteine as a risk factor for dementia and Alzheimer's disease. *N Engl J Med*. 2002;346(7):476-483.
3. Serot JM, Christmann D, Dubost T, Bene MC, Faure GC. CSF-folate levels are decreased in late-onset AD patients. *J Neural Transm* 2001;108(1):93-99.
4. Niculescu MD, Yamamuro Y, Ziesel SH. Choline availability modulates human neuroblastoma cell proliferation and alters the methylation of the promoter region of the cyclin-dependent kinase inhibitor 3 gene. *J Neurochem*. 2004;89(5):1252-1259.
5. Morris MS, Jacques PF, Rosenberg IH, Selhub J. Folate and vitamin B-12 status in relation to anemia, macrocytosis, and cognitive impairment in older Americans in the age of folic acid fortification. *Am J Clin Nutr*. 2007;85(1):193-200.
6. Doody RS, Stevens JC, Beck C, Dubinsky RM, Kaye JA, et al. Practice parameter: management of dementia (an evidence-based review). Report of the quality standards subcommittee of the American academy of neurology. *Neurology*. 2001;56(9):1154-1166.
7. Durga J, van Boxtel MP, Schouten EG, Kok FJ, Jolles J et al. Effect of 3-year folic acid supplementation on cognitive function in older adults in the FACIT trial: a randomised, double blind, controlled trial. *Lancet*. 2007;369(9557):208-216.
8. Ho PI, Collins SC, Dhitavat S, Ortiz D, Ashline D, Rogers E, Shea TB. Homocysteine potentiates beta-amyloid neurotoxicity: role of oxidative stress. *J Neurochem*. 2001;78(2):249-253.
9. Chan A, Paskavitz J, Remington R, Rasmussen S, Shea TB. Efficacy of a vitamin/nutriceutical formulation for early-stage Alzheimer's disease: A 1-year, open-label pilot study with a 16-month extension. *Am J Alzheimers Dis Other Dement*. 2008;23(6):571-585.
10. Reynolds EH. Benefits and risks of folic acid to the nervous system. *J Neurol Neurosurg Psychiatry* 2002;72(5):567-571.
11. Folstein MF, Robins LN, Helzer JE. The mini-mental state examination. *Arch Gen Psychiatry*. 1983;40(7):12.
12. Sunderland T, Hill JL, Mellow AM, et al. Clock drawing in Alzheimer's disease. A novel measure of dementia severity. *J Am Geriatr Soc*. 1989;37(8):725-729.
13. Mitrushina MN, Boone KB, D'Elia LF. Handbook of Normative Data for Neuropsychological Assessment. New York: Oxford University Press; 1999:298-311.
14. Yesavage JA. Geriatric depression scale. *Psychopharmacol Bull*. 1988;24(4):709-711.
15. Sheehan DV. The diagnosis and drug treatment of anxiety disorders. *Prog Neuropsychopharmacol Biol Psychiatry*. 1983;7(4-6):599-603.
16. Andreeescu C, Belnap BH, Rollman, et al. Generalized anxiety disorder severity scale validation in older adults. *Am J Geriatr Psychiatry*. 2008;16(10):813-818.
17. Beck AT, Ward CH, Mendelson, M, Mock J, Erbaugh J. An inventory for measuring depression. *Arch Gen Psychiatry*. 1961;4:561-571.
18. Nasreddine ZS, Phillips NA, Bedirian V, et al. The Montreal cognitive assessment, MoCA: A brief screening tool for mild cognitive impairment. *J Am Geriatr Soc*. 2005;53(4):695-699.
19. Aisen PS, Schneider LS, Sano M, Diaz-Arrastia R, van Dyck CH, Weiner MF, et al. High-dose B vitamin supplementation and cognitive decline in Alzheimer disease: a randomized controlled trial. *JAMA*. 2008;300(15):1774-1783.
20. Reynolds EH. Benefits and risks of folic acid to the nervous system. *J Neurol Neurosurg Psychiatry*. 2002;72(5):567-571.
21. Yoo J, Choi GD, Kang SS. Pathogenicity of thermolabile methyltetrahydrofolate reductase for vascular dementia. *Arterioscler Thromb Vasc Biol*. 2000;20(8):1921-1925.
22. Michoulon D, Raab MF. The role of folate in depression and dementia. *J Clin Psychiatry*. 2007;68(suppl 10):28-33.