

## Computer Assisted Knee Replacement

*Scott L. Delp, PhD\*; S. David Stulberg, MD\*\*; Brian Davies, PhD†; Frederic Picard, MD††; and Francois Leitner, PhD||*

Accurate alignment of knee implants is essential for the success of total knee replacement. Although mechanical alignment guides have been designed to improve alignment accuracy, there are several fundamental limitations of this technology that will inhibit additional improvements. Various computer assisted techniques have been developed to examine the potential to install knee implants more accurately and consistently than can be done with mechanical guides. For example, computer integrated instrumentation incorporates highly accurate measurement devices to locate joint centers, track surgical tools, and align prosthetic components. Image guided knee replacement provides a three-dimensional preoperative plan that guides the placement of the cutting blocks and prosthetic components. Robot assisted knee

replacement allows one to machine bones accurately without the use of standard cutting blocks. The rationale for the development of computer assisted knee replacement systems is presented, the operation of several different systems is described, the advantages and disadvantages of different approaches are discussed, and areas for future research are suggested.

Total knee replacement is widely used to relieve pain and improve function in patients with degenerative joint disease. Although total knee replacement is generally successful, failures from component loosening, instability, dislocation, fracture, or infection occur in approximately 5% to 8% of cases.<sup>1,17,20</sup> Less severe complications, such as patellofemoral pain or limited flexion, also contribute to sub-optimal outcomes in 20% to 40% of cases.<sup>2,9,13</sup>

The success of total knee replacement depends on several factors, including patient selection, prosthesis design, soft tissue balancing, and alignment of the limb. Proper rotational and translational alignment of the prosthetic components and of the limb are important factors that influence the outcome of knee replacement.<sup>3</sup> Incorrect positioning or orientation of implants can lead to accelerated wear, component loosening, and degraded functional performance.<sup>14,21</sup>

An error in alignment of the components in any of the anatomic planes can have a detrimental effect. Abnormal varus or valgus alignment has been reported to be a major cause of implant loosening.<sup>14</sup> Rotation of the femoral and tibial components has a strong influence on patellar tracking, and malrotation

From the \*Departments of Biomedical Engineering and Physical Medicine and Rehabilitation, Northwestern University, Chicago, IL; \*Rehabilitation Institute of Chicago, Chicago, IL; \*\*Department of Orthopaedic Surgery, Northwestern University Medical School, Chicago, IL; †Department of Mechanical Engineering, Imperial College, London, United Kingdom; ††Department of Orthopaedic Surgery, Grenoble South Hospital, Grenoble, France; and ||PRAXIM Company, Imaging, Modeling and Cognition Techniques Laboratory, University of Grenoble, Grenoble, France.

Funding for the project on computer integrated instrumentation was provided by the European Community, within the IGOS (Image Guided Orthopaedic Surgery) project and by the Aesculap Co; Funding for the project on image guided knee replacement was provided by Computer-Assisted Surgical Technologies, Inc, Implex Corporation, and MusculoGraphics Inc; and funding for the project on robot assisted knee replacement was provided by the Department of Health in the United Kingdom as part of a DTI Link funding.

Reprint requests to Scott L. Delp, PhD, Rehabilitation Institute of Chicago, Room 1406, 345 East Superior Street, Chicago, IL 60611.

of the components can lead to patellofemoral complications.<sup>3</sup> Alteration of the joint line has been associated with degraded postoperative function.<sup>9</sup> Even a small (2.5 mm) anteroposterior displacement of the femoral component has been shown to alter knee range of motion (ROM) as much as 20°.<sup>10</sup> Posterior tilting of the tibial component also can affect knee ROM and tibiofemoral kinematics.<sup>7,15,19</sup>

Mechanical alignment guides have improved the precision with which implants can be installed and are now one of the most important features that differentiates implant systems. As a result, major investments have been made in the development of new mechanical instruments during the last 2 decades. Although mechanical alignment systems have been refined, errors in surgical alignment still occur. Teter et al<sup>18</sup> reported that 8% of tibial cuts were malaligned by more than 4° in the coronal plane when an extramedullary alignment guide was used. Even when using state of the art intramedullary alignment systems, surgeons find that it is difficult to install knee implants within 2° to 3° varus or valgus alignment.<sup>16</sup> Other degrees of freedom, such as rotation of the femoral or tibial components, are even less repeatable than varus or valgus alignment.

There are fundamental limitations of mechanical alignment systems that inhibit additional improvements. For example, in most mechanical alignment systems some degrees of freedom, such as rotation of the femoral and tibial components, and positioning of the patellar component, are aligned by visual inspection. Other degrees of freedom are referenced to external jigs, which are difficult to position consistently relative to the bones. In general, alignment guides are designed based on standardized bone geometry; optimal placement of the components may not be achieved when the patient's bones differ from the bone geometry that was assumed by the instrument designer.

Three types of computer based systems recently have been developed to overcome the problems with mechanical alignment systems. The first type, computer integrated

instruments, augments mechanical instruments through the addition of measurement probes that can be used to locate joint centers, track surgical tools, and align prosthetic components. The second type, image guided knee replacement, provides a three-dimensional preoperative plan that guides the placement of the components. The third type, which uses active robotic devices, allows one to make highly accurate resections without the use of standard cutting guides.

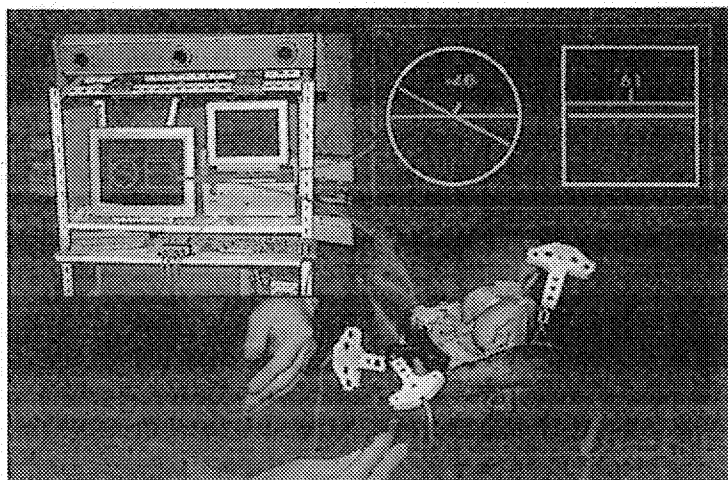
Most computer assisted knee replacement systems exist as laboratory prototypes, although some have been tested in the operating room. These initial tests suggest that computer assisted knee replacement will play an important role in the evolution of knee arthroplasty. The purpose of this article is to describe a range of alternatives to mechanical instruments, discuss the potential advantages and disadvantages of computer integrated systems, and suggest areas for future research and development.

## COMPUTER INTEGRATED INSTRUMENTS FOR KNEE REPLACEMENT

The capabilities of mechanical instruments can be enhanced by integrating them with highly accurate measurement equipment. To determine the advantages of this approach, computer software was developed that uses measurements from an optical localizer (Optotrack, Northern Digital, Waterloo, Ontario, Canada) to guide the placement of the cutting guides for Aesculap knee implants (Fig 1). The localizer measures the three-dimensional coordinates of light emitting diodes with an accuracy of 0.1 mm. Sets of four to six light emitting diodes were mounted into fixtures to create reference frames. These reference frames can be attached to the bones and to the surgical instruments to track the positions and orientations of each surgical tool relative to the bones.

The use of computer integrated instruments introduces two novel stages to the sur-

**Fig 1.** An optical localizer (left frame) is used to monitor the position and orientation of arrays of light emitting diodes fixed to the femur, tibia, and cutting guides (lower frame). The computer provides visual feedback (right frame) so that the user can position and orient the tibial cutting guide. A computer is controlled by a foot switch.



gical procedure. The first stage determines the mechanical axes of the femur and tibia. Reference frames are fixed to the iliac crest, the distal femur, the proximal tibia, and the foot with custom designed screws. The hip is rotated through a ROM, and the position and orientation of the reference frames fixed to the pelvis and femur are used to locate the hip center. In a similar procedure, the knee and ankle are manipulated to locate the average centers of these joints. The mechanical axis of the femur is calculated as the axis from the hip center to the knee center. The mechanical axis of the tibia is calculated as the axis from the ankle center to the knee center.

In the second stage of the procedure the surgeon secures reference frames to the cutting blocks. The computer workstation displays the position of the cutting block relative to the desired position (that is, orthogonal to the mechanical axis of the bone). Once a jig is oriented properly it is secured in position and the cuts are made with a standard oscillating saw.

Knee implants were installed in seven cadavers to test this system. These initial experiments showed that the system was easy to use, required minimal preoperative imaging, and did not extend the time of operation. Radiographic measurements taken after the installation of the implants showed that the angle between the mechanical axis of the femur and the distal plane of the femoral im-

plant was  $90^\circ$  in five cases,  $88^\circ$  in one case, and  $87^\circ$  in one case. The angle between the mechanical axis of the tibia and the tibial component was  $90^\circ$  in all cases.

From January to May 1997 the system was used to install implants in four patients. There were no complications and the average tourniquet time and postoperative bleeding were less than for standard knee replacement. Analysis of postoperative radiographs also were encouraging (Table 1). The system described in this section was developed at the PRAXIM Company, Grenoble, France, and the Department of Orthopaedic Surgery, Grenoble South Hospital, Grenoble, France.

## IMAGE GUIDED KNEE REPLACEMENT

Image guided knee replacement begins with preoperative planning. To create the preoperative plan, three-dimensional computer models of the patient's femur and tibia are constructed from computed tomographic (CT) data. Once the computer models of the bones have been created, planning software orients the tibial and femoral components and calculates bone resections that align the mechanical axis of the limb and produce the intended implant contact. An intraoperative system determines the position and orientation of the patient's femur and tibia and guides the placement of the cut-

**TABLE 1. Comparison Between Computer Assisted Technique and Conventional Surgery**

Measured Parameter	Computer Assisted Technique (n = 4)	Conventional Surgery (n = 65)
Tourniquet time (minutes)	96	109
Postoperative bleeding (mL)	365 (240-590)	618 (25-1440)
Tibiofemoral angle* (degrees)	181 (173-181-183-184)	Varus (65%) 183 Valgus (26%) 177 Normal (9%) 180
Femoral angle** (degrees)	88.2 (86-88-89-90)	Varus (50%) 92 Valgus (26%) 88 Normal (24%) 90
Tibial angle† (degrees)	91.5 (90-90-91-93)	Varus (63%) 92 Valgus (25%) 88 Normal (12%) 90

\* Tibiofemoral angle is defined as the angle between the epicondylar axis and the tibial implant plateau.

\*\* Femoral angle is the angle between the femoral mechanical axis and the epicondylar axis.

† Tibial angle is the angle between the tibial mechanical axis and the tibial implant plateau.

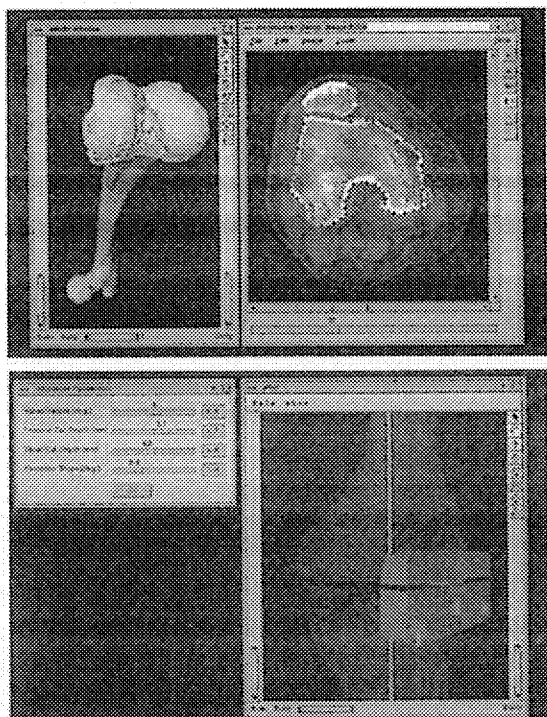
ting jigs onto the bones so that the resections determined in the preoperative plan can be made. At the end of the operation, the difference between the preoperative plan and the actual surgery can be measured.

An imaging protocol was developed in which 10 images in the transverse plane, spaced 5 mm apart, are taken at the hip and ankle. Approximately 100 images, spaced at 1 mm, are taken to define the articular surfaces of the knee. Surgical planning software uses a Canny edge filter<sup>5</sup> to locate the bone boundaries in the planar CT images. Three-dimensional models of the articular surfaces of the knee are then created (Fig 2). The centers of the hip, knee, and ankle are located in the CT images to determine the mechanical axis of the limb. The epicondylar axis of the femur and other key points also are located in the image data. Based on these measurements, the planning software calculates the implant size, the implant positions, and the bone resections that align the limb and produce the intended implant contact. The implant size, position, and orientation also can be changed by the user.

The intraoperative system consists of a graphics workstation, a coordinate measurement probe, and a set of cutting blocks that

have been modified to attach to the measurement probe, similar to the system shown in Figure 1. The intraoperative system is used to determine the position and orientation of the patient's femur and tibia and to guide the surgeon in the placement of the cutting jigs so that the resections specified in the preoperative plan can be made.

One of the key steps in the operation is registration. Registration is the process of determining the geometric correspondence between the surgical plan and the patient's bones. Registration is accomplished by a two-step procedure. In the first step, the computer displays a suggested position and orientation of the measurement probe with respect to the femur or tibia. The user attempts to align the measurement probe as displayed. The system assumes that the user has aligned the probe exactly as displayed and computes the geometric transformation for this initial registration. The initial registration then is refined in a second registration phase. In this phase, the user samples a set of 20 to 25 points distributed over the surface of the bone with the measurement probe. Given this set of sampled points ( $S_i$ ), an iterative closest point algorithm<sup>4</sup> finds the rotation ( $R$ ) and the translation ( $T$ ) that minimizes the mean squared distance between the sampled



**Fig 2.** Preoperative plan for image guided knee replacement. Computed tomographic data is used to create a three-dimensional model of the femur (upper frame), which then is used to plan the placement of the implants and the cutting blocks (lower frame).

points and the set of closest points on the computer model of the bone surface ( $M_i$ ). That is,  $R$  and  $T$  are determined that minimize the function:

$$f(R, T) = \frac{1}{N_s} \sum_{i=1}^{N_s} \| M_i - (RS_i + T) \|^2$$

where  $N_s$  is the number of sampled points.

Tests were conducted to quantify the angular error introduced by the registration process. After implanting markers into the bones of a cadaver, CT images were acquired according to the protocol defined above. The markers were ceramic spheres with a diameter of 1 cm, which were mounted on delrin posts. The centroids of the markers were located in the image data along with the surfaces of the bones.

The spheric markers were located in the laboratory with a measurement probe by sam-

pling 15 to 20 points on the surface of each sphere. A registration between the computer model and the bones was determined from the locations of the spheres; this was considered to be the true registration. A registration then was performed according to the two-step procedure that uses 20 to 25 points sampled from the surface of each bone.

These tests showed that the average error introduced by the registration was less than  $1^\circ$  for all angles, except tibial rotation (Table 2). The maximum error in 20 trials was  $5.8^\circ$  in one instance for tibial rotation. This occurred because the set of points sampled from the tibial surface did not adequately define tibial rotation.

An evaluation with 10 surgeons analyzed the planning software, the intraoperative guidance system, and the customized cutting blocks. Nine of the 10 surgeons reported that they thought that the system was easy to use and was capable of improving their accuracy.

The system described in this section was developed by Peter Loan, MS, Craig Robinson, BS, and Arthur Wong, MS, of MusculoGraphics Inc, Evanston, IL, in collaboration with Scott Delp, PhD, and David Stulberg, MD.

## ROBOT ASSISTED KNEE REPLACEMENT

Several groups have implemented prototypes using industrial robots to improve the accuracy and precision of bone resections. Matsen

**TABLE 2.** Registration Errors in Image Guided Knee Replacement

Angle	Average Error ( $^\circ$ )	Maximum* Error ( $^\circ$ )
Femur		
Varus or valgus	0.4	0.8
Flexion or extension	0.7	2.8
Rotation	0.7	2.8
Tibia		
Varus or valgus	0.4	1.9
Flexion or extension	0.9	2.0
Rotation	2.7	5.8


\* Maximum in the 20 trials.

et al<sup>12</sup> implemented a system for distal femoral arthroplasty and compared the accuracy of their laboratory prototype with conventional techniques. Their tests on plastic bone models showed that 14 of 30 cuts made with mechanical alignment guides had errors greater than 2°. Only six of 30 cuts made with robotic assistance deviated from the desired values by more than 2°. Kienzle et al<sup>11</sup> developed surgical planning software and a robotic procedure to drill the alignment holes for conventional cutting blocks for femoral and tibial implants.

Robot assistance also provides the capability to machine bone surfaces to avoid malalignment implicit in the cement mantle and to promote bone ingrowth attributable to a larger contact area between the prosthesis and the bone. Fadda et al<sup>8</sup> have linked a sophisticated preoperative planning system to a standard industrial robot to allow placement of cutting blocks and machining of the bones.

These prototypes have used standard industrial robots, typically a Puma robot (Unimation Inc, Pittsburgh, PA). Although the tests of systems that incorporate industrial robots have showed some possible advantages, these robotic devices were not designed for use in the operating room.

Davies et al<sup>6</sup> have designed a special purpose robot for knee surgery (Fig 3). Laboratory studies of the robot performance in cutting animal bones show the overall accuracy of the imaging, modeling, registration, and robot cutting to be approximately 1.3 mm. This active constraint robot (ACROBOT) uses a force controlled lever near the tip of the robot. The surgeon can hold the lever and move the robot under servoassistance within a programmed region permitted by the robot. Access to regions that include ligaments, nerves, and vasculature is prevented by the robot. The robot also can provide a virtual cutting block that constrains a rotary cutter to cut various shapes, such as a series of planes suitable for mounting the implant. If the user attempts to machine beyond the permitted plane, the robot transitions into a high gain position servo, resisting the surgeon's attempts to move into



**Fig 3.** Photograph of the ACROBOT system.

forbidden regions. Thus, the robot can provide accuracy and constraint while the surgeon can feel the forces exerted on the bone and use his or her judgment to slow down or take a lighter cut when a hard region of bone is encountered. This synergy between the robot and surgeon keeps the surgeon in control of the procedure.

To smoothly and accurately back drive the ACROBOT, while being able to feel the forces applied to the cutter, low and equal impedance is required from the robot. The ACROBOT therefore has been designed to provide pitch and yaw motions, and linear motions, which all have an equal and a low impedance. It is hoped that these features will produce a synergy between the machine and the surgeon and enhance the acceptance of robotic systems in the future.

The system described in this section was developed by the Mechatronics in Medicine Group in the Department of Mechanical Engineering at Imperial College, London, United Kingdom.



## DISCUSSION

Computer integrated instruments that combine standard cutting guides with highly accurate measurement equipment are a natural extension of current techniques and offer several potential advantages. The computer integrated instruments described here showed the potential to reduce surgical errors and ensure rapid, precise positioning of the cutting guides. This system also eliminates the need for intramedullary and extramedullary alignment guides. Although there are new elements of the surgical procedure, several complex alignment steps are eliminated. This system achieves these advantages without additional imaging or preoperative planning.

However, there are several shortcomings of this system. First, the current method of locating the hip center requires the installation of a screw into the iliac crest. Second, the system requires a computer and an optical tracking device, which are more expensive than mechanical alignment guides. Finally, although the computation of the mechanical axes of the femur and tibia can improve alignment accuracy, not all of the degrees of freedom are controlled by the current alignment procedure.

Image guided knee replacement is a greater departure from current practice, but has some additional capabilities when compared with computer integrated instruments that do not include preoperative planning. For example, analysis of the three-dimensional image data allows one to determine the size of the implant preoperatively, potentially reducing inventory. This system also provides guidance for all 6 degrees freedom of the implant. Image guided knee replacement allows one to measure actual placement of the implants relative to the planned placement. This provides the possibility to perform studies that compare the accuracy of mechanical instruments to computer based instruments. It also provides the possibility to study the effects of alignment on implant wear and patient outcomes. Because the placement of the implants is guided by highly

accurate tracking devices, image guided knee replacement potentially provides more accurate, reproducible installation of prosthetic components. Additional work is needed to test this hypothesis.

The advantages of image guided knee replacement do not come without a cost. For example, this approach requires a preoperative CT scan, which is not a standard part of knee replacement. Image guided surgery also requires the construction of a preoperative plan, which takes approximately 3 hours with the current system. Finally, all image guided surgery involves registration to determine the geometric correspondence between the surgical plan and the patient. Registration can introduce errors and is the least reliable element of most image guided surgery systems.

Similar to image guided knee replacement, robot assisted knee replacement has the advantages (and disadvantages) of preoperative imaging, modeling, and planning. A robot, however, provides the capability to create a physical constraint, unlike a surgeon holding an image guided surgical tool. In addition, the machining capability of a robot may provide a more accurate fit between the prosthesis and the bone, making the use of cement unnecessary in some cases. In addition to these general benefits of robot assisted surgery, the AC-ROBOT concept provides a synergy in which the robot provides accuracy and constraint and allows the surgeon to use his or her sense of touch to control the procedure.

The cost associated with the use of a robot in the operating room is currently a major limitation of this technology. Current orthopaedic robotic systems cost approximately \$500,000. Until the cost can be reduced dramatically, robotic systems are unlikely to be used in a large number of hospitals. This has motivated the development of special purpose surgical robots with the goal of providing a tool that is simple and cost effective.

The systems described here are in the preliminary stage of development, and the limitations of these systems suggest areas for future

research. For example, although soft tissue balancing is one of the key factors that influences the success of total knee replacement, none of the current systems include a biomechanical analysis of the soft tissues in the surgical planning process. Analysis of the interplay between implant design, surgical alignment, soft tissue tensions, and joint function should be included in future surgical planning software.

Although some surgeons see the use of preoperative CT scans and imaging as an advantage, others see this as an extra and costly requirement. Future research aimed at reducing the reliance of the image guided and robotic techniques on preoperative CT scans may increase the acceptance of these approaches.

Additional research is needed to test the efficacy of computer assisted knee replacement systems. The measurement equipment incorporated into these systems should be used to quantify the accuracy of current mechanical instruments (in all anatomic planes) and to compare this with the accuracy of computer based systems. It is essential to determine whether improvements in alignment accuracy improve functional outcomes, reduce loosening, and decrease the need for revisions. If the accuracy and outcomes are improved with computer assisted techniques, then the introduction of new computer assisted procedures, including unicompartmental knee replacement and high tibial osteotomy, would be warranted.

## References

1. Aglietti P, Buzzi R: Posterior stabilized total condylar knee replacement. Three to eight year follow-up of 85 knees. *J Bone Joint Surg* 70B:211-216, 1988.
2. Aglietti P, Buzzi R, Gaudenzi A: Patellofemoral functional results and complications with the posterior stabilized total condylar knee prosthesis. *J Arthroplasty* 3:17-25, 1988.
3. Berger RA, Rubash HE, Seel MJ, Thompson WH, Crossett LS: Determining the rotational alignment of the femoral component in total knee arthroplasty using the epicondylar axis. *Clin Orthop* 286:40-47, 1993.
4. Besl PJ, McKay ND: A method for registration of 3D shapes. *IEEE Transactions on Pattern Analysis and Machine Intelligence* 14:239-256, 1992.
5. Canny JA: Computational approach to edge detection. *IEEE Transactions on Pattern Analysis and Machine Intelligence PAMI* 8:679-698, 1986.
6. Davies BL, Harris SJ, Lin WJ, Hibberd RD, Cobb JC: Active compliance in robotic surgery—The use of force control as a dynamic constraint. *J Eng Med Proc H IMechE* 211:H4, 1997.
7. Dorr LD, Boiaro RA: Technical considerations in total knee arthroplasty. *Clin Orthop* 205:5-11, 1986.
8. Fadda M, Bertelli D, Martelli S, et al: Computer assisted planning for total knee arthroplasty. *Proceedings of the First Joint Conference on Computer Vision, Virtual Reality and Robotics in Medicine and Medical Robotics and Computer Assisted Surgery*, Grenoble, France, 619-628, Springer, 1997.
9. Figgie HE, Goldberg VM, Heiple KG, Moller HS, Gordon NH: The influence of tibial-patellofemoral location on function of the knee in patients with posterior stabilized condylar knee prosthesis. *J Bone Joint Surg* 68A:1035-1040, 1986.
10. Garg A, Walker PS: Prediction of total knee motion using a three-dimensional computer-graphics model. *J Biomech* 23:45-58, 1990.
11. Kienzie TC, Stulberg SD, Peshkin M, et al: A Computer-Assisted Total Knee Replacement Surgical System Using a Calibrated Robot. In Taylor RH, Lavallée S, Burdea GC, Mösges R (ed). *Computer-Integrated Surgery: Technology and Applications*, Cambridge, The MIT Press 409-416, 1996.
12. Matsen III FA, Garbini JL, Sidles JA, et al: Robotic assistance in orthopaedic surgery: A proof of principle using distal femoral arthroplasty. *Clin Orthop* 296:178-186, 1993.
13. Merkow RL, Soudry M, Insall JN: Patellar dislocation following total knee replacement. *J Bone Joint Surg* 67A:1321-1327, 1985.
14. Oswald MH, Jakob RP, Schneider E, Hoogewoud H: Radiological analysis of normal axial alignment of femur and tibia in view of total knee arthroplasty. *J Arthroplasty* 8:419-426, 1993.
15. Piazza SJ, Delp SL, Stulberg SD, Stern SH: Posterior tilting of the tibial component decreases femoral rollback in posterior-substituting knee replacement. *J Orthop Res* 16:264-270, 1998.
16. Ritter MA, Faris PM, Keating EM, Meding JB: Postoperative alignment of total knee replacement: Its effect on survival. *Clin Orthop* 299:153-156, 1994.
17. Stern SH, Insall JN: Posterior stabilized prosthesis: Results after follow-up of 9-12 years. *J Bone Joint Surg* 74A:980-986, 1992.
18. Teter KE, Bergman D, Colwell CW: Accuracy of intramedullary versus extramedullary tibial alignment cutting systems in total knee arthroplasty. *Clin Orthop* 321:106-110, 1995.
19. Townley CD: The Anatomic Total Knee: Instrumentation and Alignment Technique. *The Knee: Papers of the First Scientific Meeting of the Knee Society*. Baltimore, University Press 39-54, 1985.
20. Vince KG, Insall JN, Kelly MA: The total condylar prosthesis: 10 to 12 year results of a cemented knee replacement. *J Bone Joint Surg* 71B:793-797, 1989.
21. Wasielewski RC, Galante JO, Leighty R, Natarajan RN, Rosenberg AG: Wear patterns on retrieved polyethylene tibial inserts and their relationship to technical considerations during total knee arthroplasty. *Clin Orthop* 299:31-43, 1994.