

COMPUTER-ASSISTED TOTAL KNEE REPLACEMENT ARTHROPLASTY

S. DAVID STULBERG, MD, FREDERIC PICARD, MD,
and DOMINIQUE SARAGAGLIA, MD

The reliability of techniques to position a total knee replacement (TKR) is still limited by the relative inaccuracy of the instrumentation. The main obstacle encountered by mechanical instrumentation systems is the inconsistency of the reference points. These reference points are the centers of joint articulation that will allow the establishment of the mechanical axis for the lower limb. These references guide the placement of the bone-cutting guides. At present, it is impossible to accurately locate these articular centers preoperatively. This handicaps the accuracy of the mechanical instruments and limits their accuracy. The goal of the total knee instrumentation procedure is to achieve cuts that are perpendicular to the mechanical axes of the femur and the tibia. The longevity of total knee arthroplasty is closely related to its intraoperative positioning. The computer-assisted procedure offers an effective and novel positioning method that improves the accuracy of the surgical technique of the TKR. We have chosen to present the steps of the computer-assisted TKR technique next to the corresponding steps of a currently available, mechanically based technique that is representative of many that are presently in use.

KEY WORDS: TKR, surgical technique, computer-assisted surgery

The success of total knee replacement (TKR) surgery depends on several factors, including proper patient selection, appropriate implant design, correct surgical technique, and effective perioperative care. The outcome of TKR surgery is particularly sensitive to variations in surgical technique.¹⁻⁶ Incorrect positioning or orientation of implants and improper alignment of the limb can lead to accelerated implant wear and loosening and suboptimal functional performance. A number of studies have suggested that alignment errors of greater than 3° are associated with more rapid failure and less satisfactory functional results of total knee arthroplasties.⁷⁻¹¹

Mechanical alignment guides have improved the accuracy with which implants can be inserted. Although mechanical alignment systems are continually being refined, errors in implant and limb alignment continue to occur. It has been estimated that errors in tibial and femoral alignment of more than 3° occur in at least 10% of total knee arthroplasties, even when performed by experienced surgeons using mechanical alignment systems of modern design.^{1,2} Mechanical alignment systems have fundamental limitations that limit their ultimate accuracy. The accuracy of preoperative planning is limited by the errors inherent to standard radiographs. With standard instrumentation, the correct location of crucial alignment landmarks (eg, the center of the femoral head, the center of the ankle) is limited during the performance of a TKR. Moreover,

mechanical alignment and sizing devices presume a standardized bone geometry that may not apply to a specific patient. Even the most elaborate mechanical instrumentation systems rely on visual inspection to confirm the accuracy of the limb and implant alignment.

Computer-based alignment systems have been developed to address the problems inherent in mechanical total knee instrumentation. Although a number of computer-assisted TKR approaches are currently being developed,¹²⁻¹⁷ we have chosen to describe in detail a technique that

- Incorporates the use of a currently available and clinically validated state-of-the-art mechanical instrumentation system
- Uses commonly available, relatively inexpensive computer equipment (eg, a desktop computer, low-end optical localizer)
- Is currently available for clinical use
- Has available preliminary multicenter results comparing the use of the system with a mechanical system. These results confirm that the system is safe, that limb and implant alignment is superior to that achieved with the mechanical system, and that initial function is equivalent to that obtained with the mechanical system.¹⁷⁻²¹

We have chosen to present the steps of the computer-assisted TKR technique next to the corresponding steps of a currently available, mechanically based technique, representative of many that are presently in use. Because a computer-based surgical technique introduces concepts and equipment not currently familiar to surgeons who perform TKR surgery, we hope that the juxtaposition of the 2 techniques will allow surgeons to more readily understand the rationale and the function of these new tools. Moreover, by juxtaposing the 2 techniques, we wanted to

From the Section of Joint Reconstruction and Implant Surgery, Northwestern University, Chicago, IL; and the University Department of Orthopaedic Surgery, Grenoble, France.

Address reprint requests to S. David Stulberg, MD, Professor Clinical Orthopaedic Surgery, Director Section of Joint Reconstruction and Implant Surgery, 680 N. Lake Shore Drive, Suite 1206 A, Chicago, IL 60611.

Copyright © 2000 by W.B. Saunders Company
1048-6666/00/1001-0005\$10.00/0




Fig 1. Positioning of the patient for surgery.

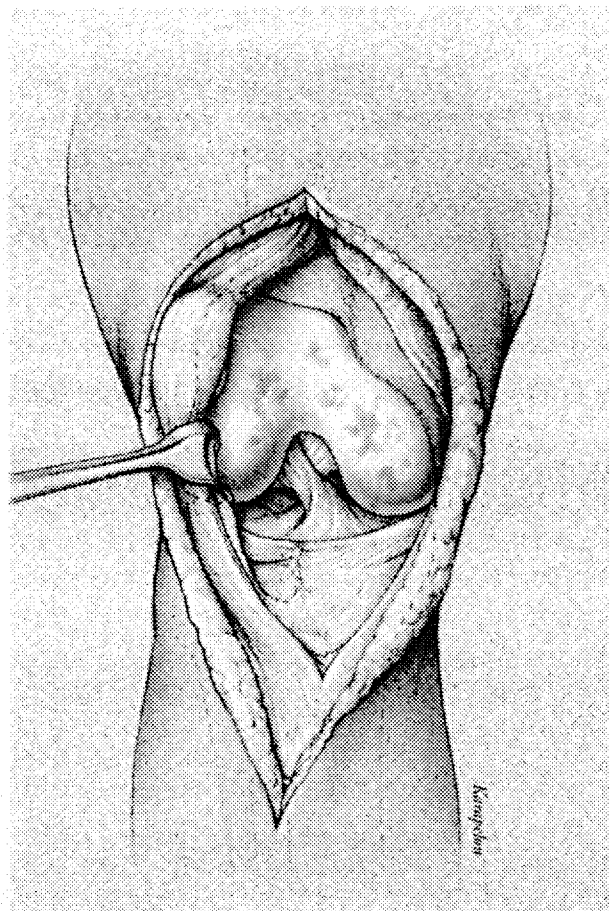


Fig 2. Incision and exposure.

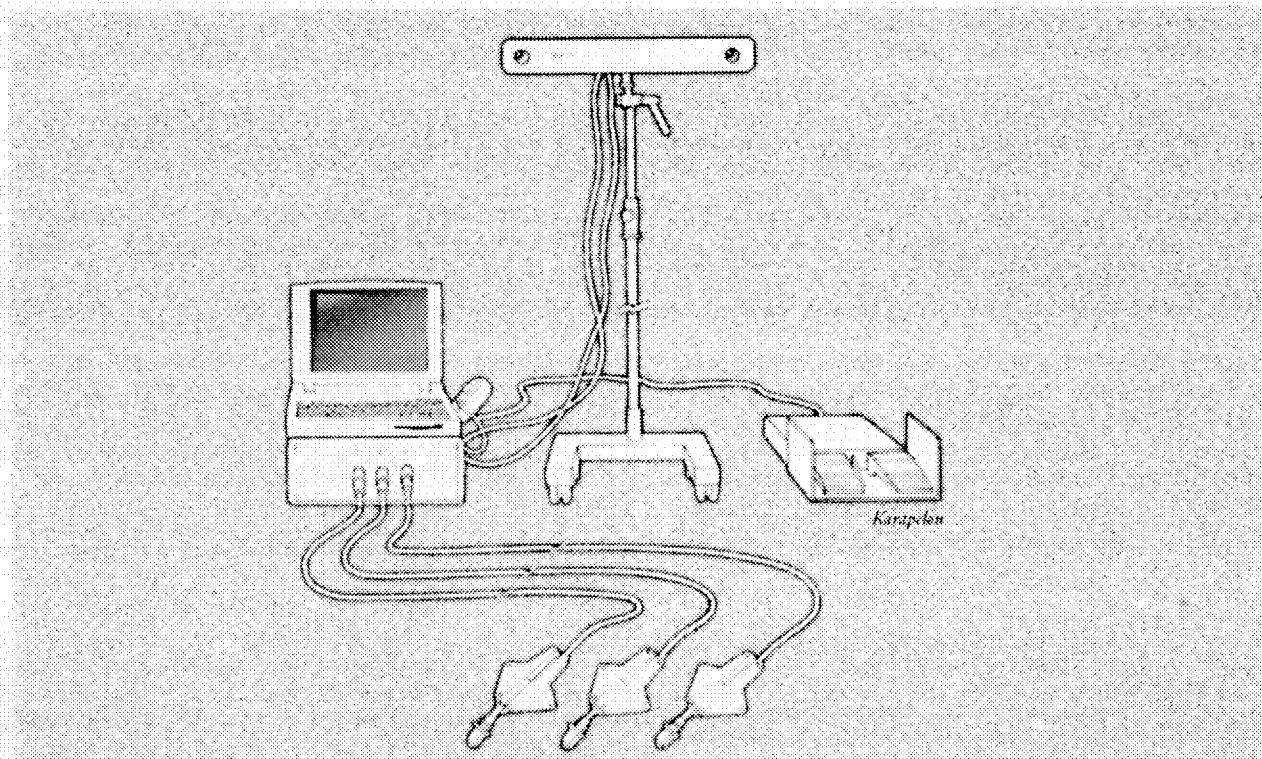


Fig 3. Computer system set up: localizer, laptop or desktop, footpedal control.

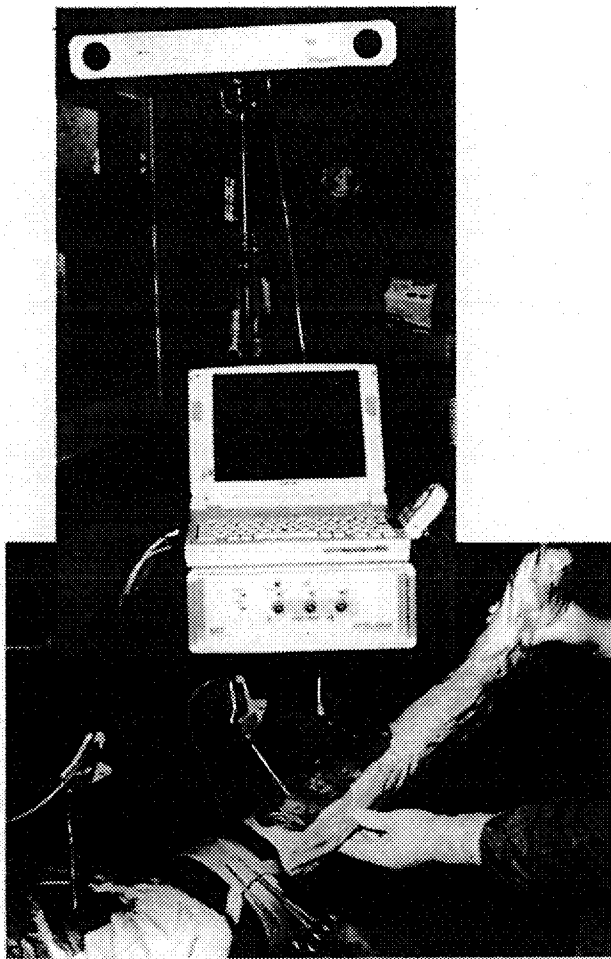


Fig 4. Computer system in the operating room.

emphasize that the alignment objectives of the 2 techniques are identical. The goal of the computer-assisted system is to increase the accuracy and reproducibility with which the objectives of a mechanical alignment system are achieved.

SURGICAL TECHNIQUE

PREOPERATIVE PLANNING

Although the 2 techniques have very similar approaches to preoperative planning, they do differ in one significant respect. Both approaches require that the surgeon determine the desired anatomic alignment (femoral-tibial angle) on a full-length (including hip and ankle joint), standing anterior-posterior (AP) radiograph. Some surgeons may also wish to determine the desired posterior slope of the tibial cut by using a lateral radiograph. This measurement can be used during either procedure. Many surgeons also find it helpful to estimate the desired size of the femoral and tibial implants by holding scaled templates of these implants against AP and lateral radiographs of the knee. The computer-assisted technique eliminates the need for this preoperative step because measurements are made during the procedure to determine the most appropriate implant size.

PATIENT POSITIONING AND SURGICAL EXPOSURE

The mechanical alignment and computer-assisted surgical techniques use similar approaches for patient positioning and surgical exposure (Fig 1). Leg holders and pneumatic tourniquets, routinely used with mechanical instrumentation, can also be used for the computer-assisted technique. The computer-assisted technique requires that the ipsilateral iliac crest be sterilely washed and draped to allow placement of a screw to hold one of the rigid bodies.

No alterations in the surgical incision usually used for TKR surgery need to be made for the computer-assisted technique. Although this procedure will require the placement of rigid body holding screws in the proximal tibia and distal femur, the sites for these screws can be reached through a conventional incision and exposure (Fig 2).

We prefer a straight midline skin incision and a medial para patellar exposure of the knee. This exposure extends distally along the medial-most edge of the quadriceps tendon and patella to a point just medial and distal to the patellar tendon insertion on the tibial tubercle. The superficial and deep medial collateral ligament is elevated around the anterior medial half of the tibia, and the infrapatellar fat pad. The ligamentum mucosum and anterior lateral capsule are elevated from the anterior-lateral surface of the tibia. The patellar is everted laterally, and the knee is placed in 90° of flexion. The anterior cruciate ligament is resected, the osteophytes are removed, and the fat pad trimmed to allow adequate exposure of the tibia.

LOCATING THE CENTERS OF THE HIP, KNEE, AND ANKLE JOINTS

The mechanical surgical technique uses jigs and alignment rods to locate the centers of the hip, knee, and ankle joints. These determinations are made during the surgical procedure. The computer-assisted technique requires that the centers of these joints be determined before the positioning of the rods and jigs. To determine these joint centers, equipment unique to computer-assisted surgery must be used. This equipment is also used to guide the positioning of the cutting blocks during knee replacement.

The equipment includes: (1) an optical localizer; (2) rigid bodies containing diodes; (3) 3.5-mm stainless steel bicortical screws specifically designed to hold one of the rigid bodies on the bone; (4) a metal plate to hold a rigid body to the foot; and (5) a computer, a monitor, and a foot control. The localizer consists of cameras that detect the infrared radiation emitted by the diodes contained in the rigid bodies (Fig 3). The rigid bodies are securely affixed to the bones by using the bicortical screws so that they do not move relative to the bones when the leg is flexed, extended, and rotated. The localizer is connected to the computer and the monitor. The position of the leg and bones can be seen on the computer screen when the surgeon activates the foot control. To correctly determine the centers of the hip, knee, and ankle joints, it is necessary to place rigid bodies on the pelvis, femur, and tibia. The presence of the rigid body on the pelvis assures that any pelvic motion that occurs when the leg is moved is monitored. The position of the leg relative to the pelvis, therefore, is always known. When this combination of rigid bodies is used, it is possible for

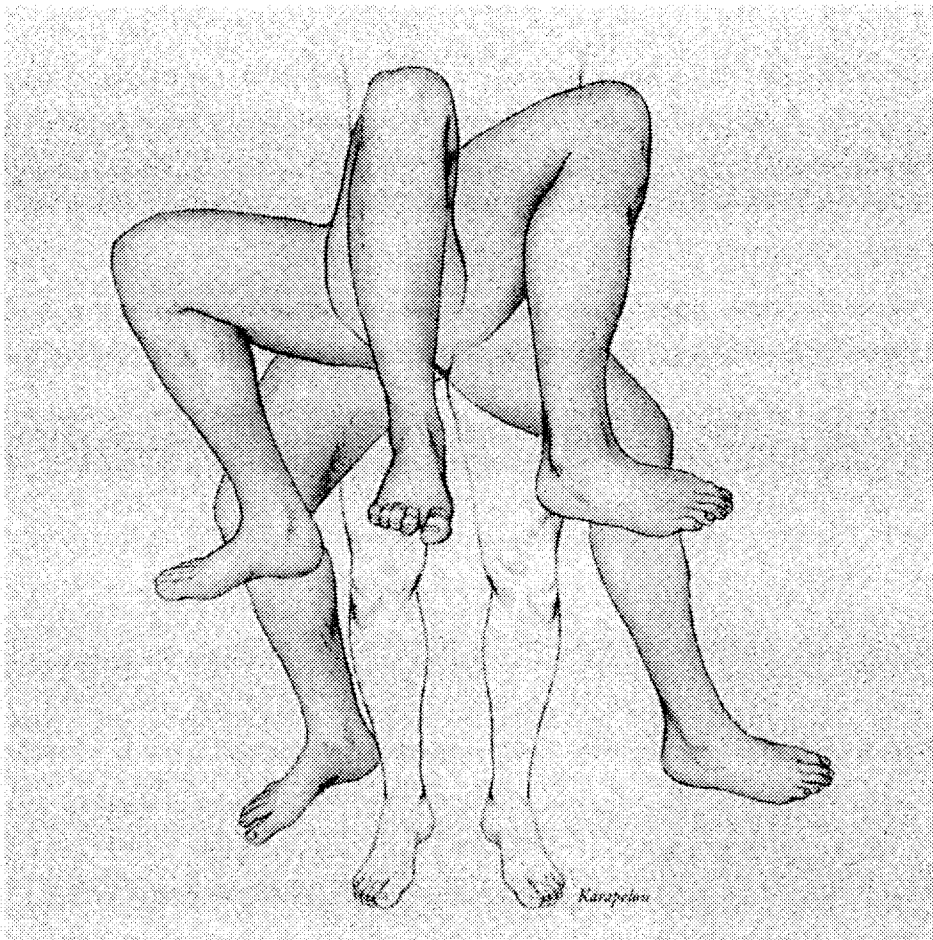


Fig 5. Rotational technique to determine the center of the femoral head.

the localizer to determine the center of the joints to within 1 mm (Fig 4).

The screws that hold the rigid bodies are inserted at the beginning of the surgical procedure. The pelvic screw is placed in the ipsilateral iliac crest through a small stab incision. The femoral and tibial screws are placed immediately after making the skin incision and exposing the knee joint. The femoral screw is inserted into the medial cortex just proximal to the medial femoral condyle at a 45° angle to the long frontal axis. The tibial screw is inserted into the anterior-medial cortex approximately 5 mm below the tibial plateau. The heads of these screws have been specially designed to hold the rigid bodies.

The center of the femoral head is determined by securing rigid bodies to the pelvic and femoral screws. The femur is then flexed, extended, abducted, adducted, and rotated. This movement generates a cloud of points on a sphere. The center of the sphere (ie, the femoral head) that created this array of points can then be imputed (Fig 5).

The center of the knee joint is determined by securing rigid bodies to the femur and tibia (Fig 6). The knee joint is then flexed and extended and internally and externally rotated in 90° of flexion. This movement allows the center of rotation of the knee joint to be calculated (Fig 7). A surface registration technique is then used to confirm the center of knee joint rotation. The surgeon selects a series of points with the registration probe on the posterior medial and lateral femoral surfaces, and the anterior distal femo-

ral cortex. The rotational center of the distal femur can then be calculated and compared with the location determined by flexing, extending, and rotating the tibia on the femur.

The surface registration step also provides the surgeon with information to be used later in the procedure. The optimal size of the femoral component, which is the size that most closely corresponds to the AP dimensions of the femur as measured by palpating the posterior surfaces of the femoral condyles and the anterior femoral cortex, is automatically calculated. The frontal plane of the femur can also be defined when the location and orientation of the posterior femoral condylar surfaces are determined. The size of the femoral component and the frontal plane of the femur are stored in the computer and provided to the surgeon during the preparation of the distal femur.

The center of the ankle joint is determined by attaching a metal plate and an elastic band to the sole of the foot. A rigid body is attached to this plate. A second rigid body is placed in the tibial screw. The ankle joint is then flexed and extended. This movement allows the center of rotation of the ankle joint to be calculated (Fig 8). A surface registration technique is used to confirm this center of ankle rotation. The middle of the medial and lateral malleoli and the center of the talus are palpated with the registration probe. These points allow the center of the ankle joint to be calculated. This center is compared with the location determined by flexing and extending the joint (Fig 9). The surface registration of the ankle also provides the surgeon

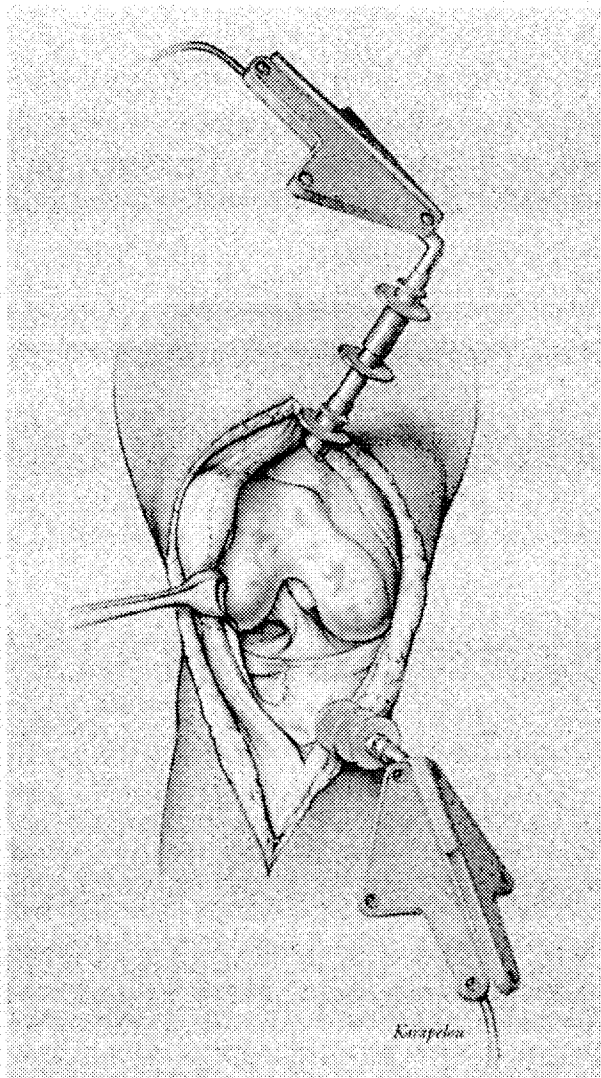


Fig 6. Rigid bodies secured to the femur and tibia.

with information that will be used later in the procedure. The location of the midpoints of the malleoli and the center of the ankle joint allow the sagittal and frontal planes of the tibia to be calculated. This information is stored and provided to the surgeon during the preparation of the proximal tibia. Once the centers of the hip, knee and, ankle joints are determined, the femur and tibia can be accurately prepared.

PREPARATION OF THE TIBIA AND FEMUR

The sequence of preparation is the same for the mechanical and computer-assisted techniques.

Tibial Preparation

Mechanical technique. An intramedullary or extramedullary alignment device is placed into or on the tibia. The medial-lateral midpoint of the tibial plateau is determined. The center of the tibial spine is often selected to represent this point. The proximal portion of the tibial instrumenta-

tion system is placed in such a way that the intramedullary or extramedullary rod intersects the proximal medial-lateral midpoint of the tibial plateau. An ankle clamp helps position the distal portion of an extramedullary rod over the midportion of the talus. This point represents the medial-lateral midpoint of the ankle joint. An intramedullary rod completely inserted into the tibia also rests over the midpoint of the talus (Fig 10).

If an extramedullary alignment system is used, the device is placed in a position that brings the rod parallel in the sagittal plane to the long axis of the tibial shaft (Fig 11). If an intramedullary alignment device is used, the completely inserted rod will be parallel to the long axis of the tibia in the sagittal plane.

A proximal tibial cutting block attached to either the intramedullary or extramedullary alignment rod is placed along the anterior surface of the tibia proximal to the tibial tubercle. A stylus attached to the cutting block allows the surgeon to determine the desired level of the tibial resection. The posterior slope of the proximal tibial cut is determined by selecting a block with or without a predetermined posterior slope (eg, 5°).

The rotation of the proximal tibial cut is made by placing the entire tibial device (rod and cutting block) so that it is directed along the AP line of the spine of the tibial plateau or, alternatively, so that it is directed toward the medial one third of the tibial tubercle. The cutting block is secured to the tibia with pins. The proximal tibial cut is then made.

Computer-assisted technique. The tibial alignment guide used in the computer-assisted technique is virtually identical to that used in the extramedullary mechanical alignment technique described previously. This guide is positioned against the leg and secured at the ankle with clamps and at the knee with 2 threaded pins inserted through holes on the cutting block (Fig 12). Once the alignment device is positioned, the computer technique is used to determine the orientation of the frontal and sagittal cuts and the depth of the resection. Rigid bodies are attached to the screw in the proximal tibia and to the cutting block. The position of the cutting block relative to the tibia can, therefore, be calculated and depicted on the monitor.

The location of the cutting block on the tibia is depicted on the screen of the monitor as a red line. A green line represents the desired orientation of the cutting block, (ie, perpendicular to the mechanical axes in the frontal and sagittal planes). A series of wheels on the alignment guide allow the surgeon to tilt the cutting block until the red and green lines overlap (Fig 13). The block is then locked to the alignment guide in this position. The surgeon uses a probe to palpate and record the level of the medial or lateral plateau. The surgeon uses this information to determine the level of the tibial resection (eg, 2 mm below the most involved side). The cutting block can then be positioned, by using the wheels and the graphical depiction on the monitor, at this desired level. Once the position of the cutting block is determined, the device is fixed to the proximal tibia with 4 threaded wires. A standard tibial cut is made with an oscillating saw (Fig 14).

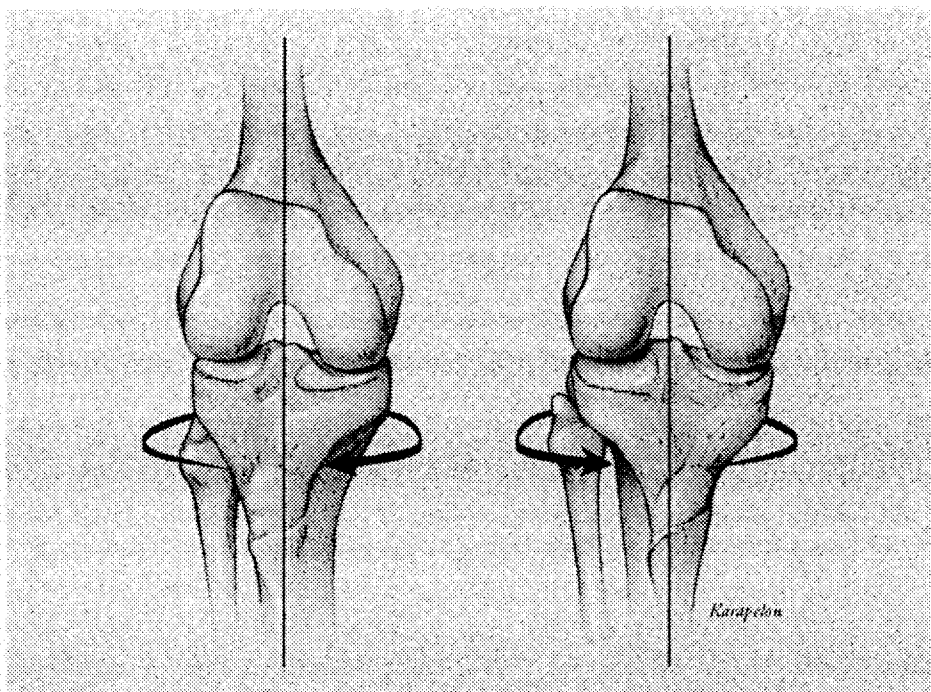


Fig 7. Rotational technique to determine the rotational center of the knee.

Femoral Preparation

Distal femoral cut. Mechanical technique. An intramedullary rod is introduced into the femoral canal. The distal femoral cutting block device is placed onto the rod with the desired femoral-tibial angle (determined during the preoperative planning). The device is placed against the distal femur, and the distal femoral cutting block is secured to the femur with pins (Fig 15). The cutting device determines the depth of the distal femoral cut (ie, distance of cut from distal end of the femur). If a surgeon wishes to resect more (or less) of the distal femur, the cutting block can be repositioned on the pins.

Distal femoral cut. Computer-assisted technique. The femoral cutting guide must be placed in the center of the distal femur at the level of the knee joint before the orientation and depth of the femoral resections can be determined. Rigid bodies are attached to the screw on the distal femur and to the distal femoral cutting jig. The surgeon can then track on the monitor the position of the cutting block relative to the distal femur. Once the jig is centered over the distal femur, it is secured to the femur with a 5-mm threaded wire.

The desired sagittal orientation of the femoral alignment device is then determined. A dashed green line within a square box on the monitor represents the ideal sagittal position of the device, which is perpendicular to the femoral mechanical sagittal axis. A red line in the box on the monitor represents the sagittal position of the device. The surgeon manually positions the alignment device until the 2 lines overlap. When this device is correctly positioned, it is secured to the femur. This establishes the sagittal orientation of the distal femoral cutting block (Fig 16A and B).

Two keels are secured to the femoral alignment device. The distal femoral cutting block is then attached to the

device. The frontal orientation of the cutting block is then established. A green line within a circle on the monitor represents the ideal frontal position within the circle represents the cutting block. A wheel system on the femoral alignment system allows the surgeon to change the position of the cutting block. When the 2 lines overlap, the cutting block is then secured firmly to the alignment device. The desired depth of the femoral resection was calculated by the system when the rotational center of the knee joint was determined. The location of the green line takes this depth into account. Therefore, once the 2 lines overlap, the correct depth of the distal femoral cut is fixed

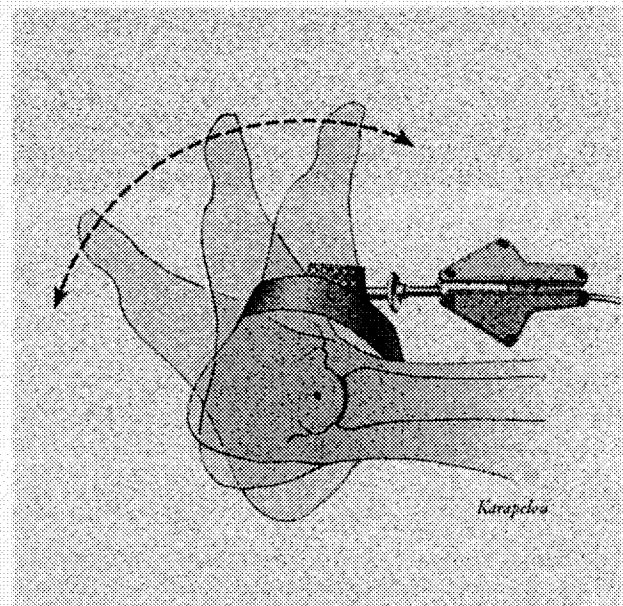
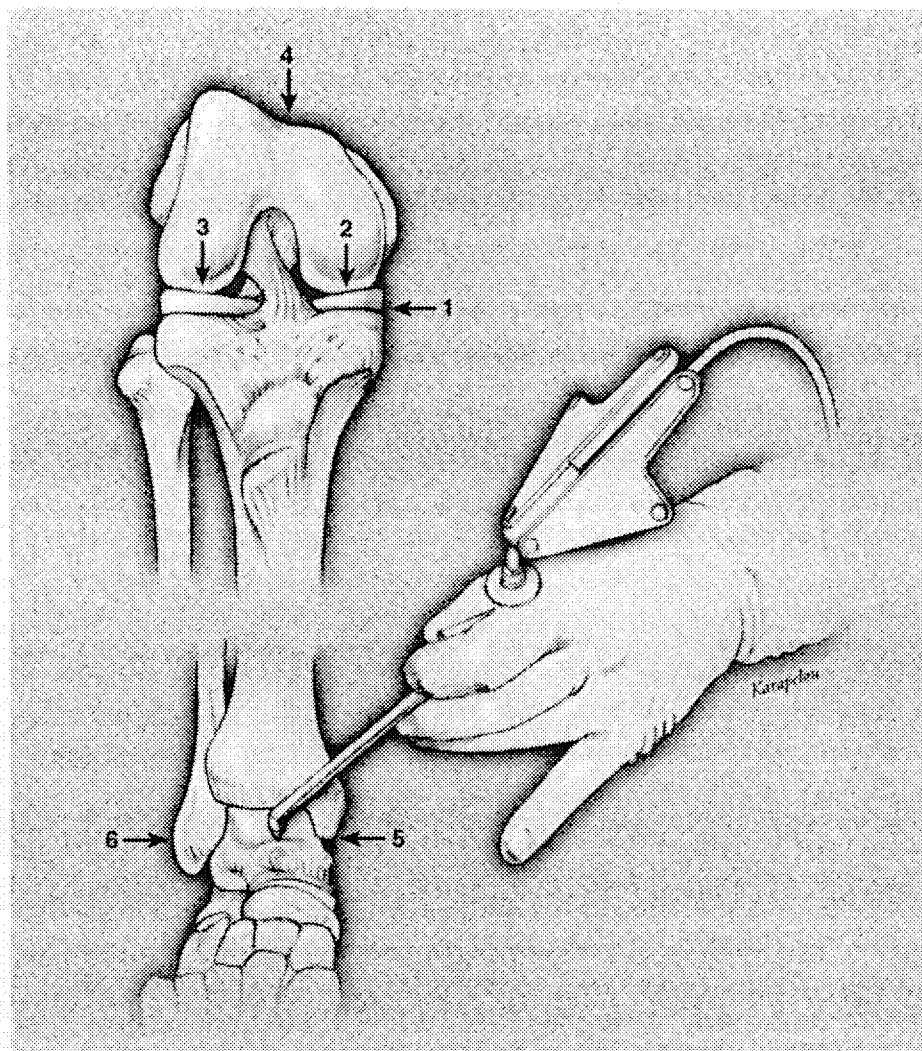


Fig 8. Rotational technique to determine the rotational center of the ankle.

Fig 9. Surface registration step.



(Fig 17A and B). The distal femur is then resected. The distal cutting block is then removed from the femoral alignment device.

Establishing Femoral Component Rotation

Mechanical system. Most systems place the femoral component so that its medial-lateral axis is parallel to the epicondylar axis. If the posterior femoral condyles are not deformed, a jig with projections that rest against the posterior condyles of the femur can be used to establish the rotation of the component. The epicondylar axis is externally rotated 3° from the line connecting the posterior surfaces of the medial and lateral condyles. Mechanical systems incorporate this relationship into the jig with projections that rest against the posterior condyles. Once the desired position of the jig is established, the holes for the pegs of the AP cutting block are made with pins or a drill (Fig 18A and B).

Computer-assisted system. The locations of the medial and lateral femoral epicondyles as well as the location of the posterior surfaces of the medial and lateral femoral condyles were determined during the surface registration

step of the procedure. This information is now used to establish the desired rotation of the femoral component. The femoral alignment device that was previously secured to the distal femur can be rotated by using the wheel system. A circle is displayed on the monitor with a green line representing the ideal rotational alignment of the femoral component and a red line representing the rotation of the alignment device. The wheel system is used to exactly overlap these 2 lines. The device is then locked in this position (Fig 19A).

Establishing the Size of the Femoral Component

Mechanical system. Most systems use referencing guides off the posterior femoral condyles and/or anterior femoral cortex to establish the size of the femoral component. A posterior-based referencing system uses a jig with projections that rest against the posterior condyles of the femur. This jig is placed against the resected distal femur. A stylus placed into the anterior surface of the jig is then used to select the appropriate femoral component size.

Computer-assisted system. The optimum size of the femoral component was calculated at the time that the rota-

tional center of the knee joint was determined. This information is now provided by the system to the surgeon (Fig 19A).

Anterior-Posterior Femoral Resection

Mechanical system. The cutting block corresponding to the femoral component of desired size is placed into the holes on the distal femur. The anterior, posterior, and chamfer cuts are then made (Fig 19B).

Computer-assisted system. The cutting block corresponding to the femoral component of correct size is attached to the distal femoral alignment system. The correct rotational and frontal position of this device has been previously

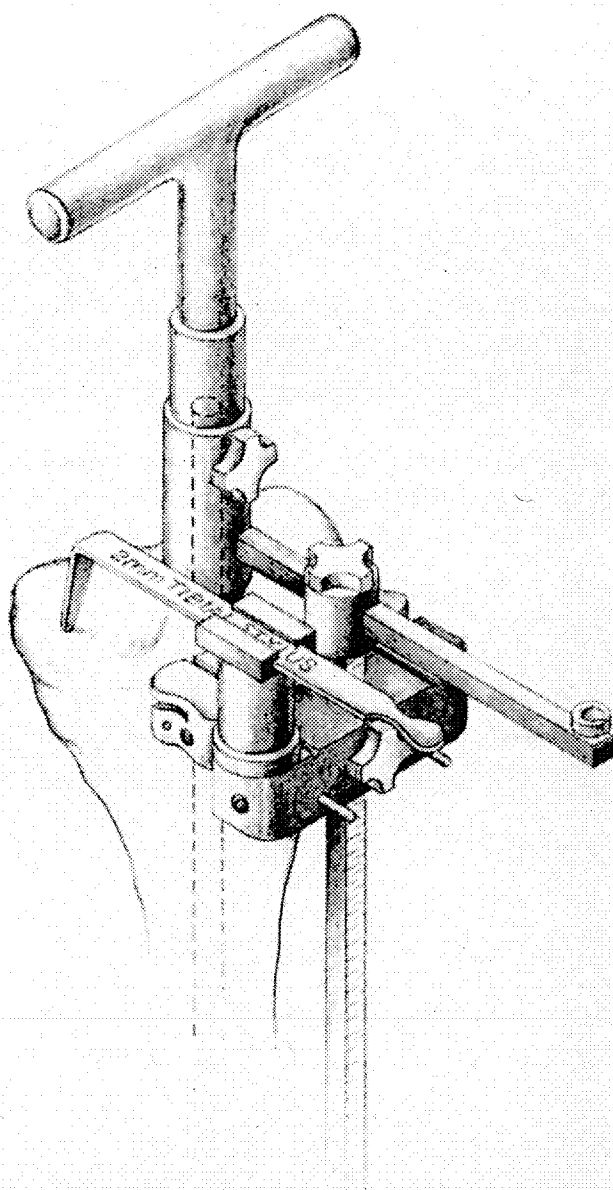


Fig 10. An intramedullary alignment device is placed into the tibia during the mechanical technique.

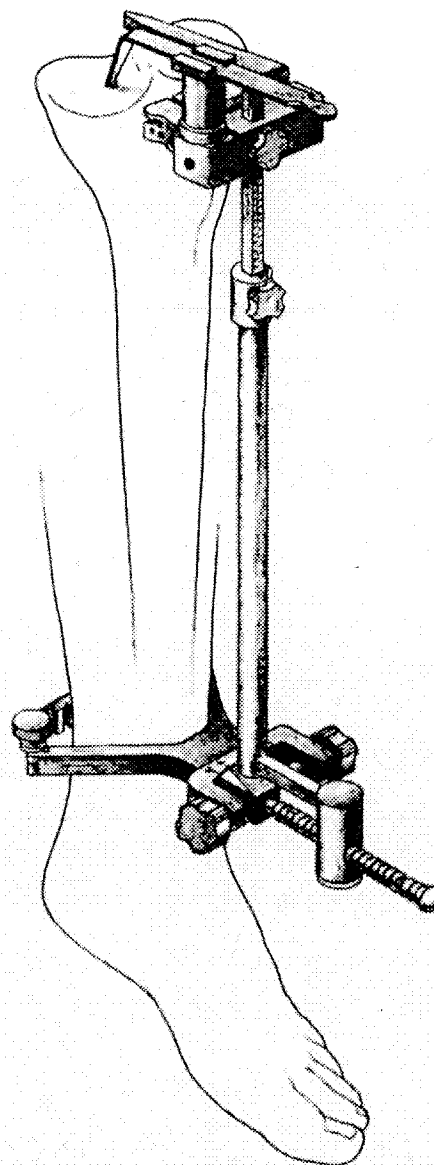


Fig 11. Extramedullary alignment system used in the mechanical technique.

determined. The anterior, posterior, and chamfer cuts are then made.

Trial Reduction

Mechanical and computer-assisted systems. The tibial trial base plate that most accurately fits the resected proximal tibial surface is selected and placed on the top of the tibia. A polyethylene insert is placed onto the base plate. The femoral trial is placed on the distal femur. The knee is flexed and extended and stressed medially and laterally. Correct soft tissue balance is achieved through a combination of soft tissue releases and alterations of polyethylene thickness.

The computer-assisted systems allow the alignment of the knee to be checked at this point in the procedure. The rigid bodies are fixed on the femur and the tibia and the final alignment of the limb can be determined (Fig 20).

PRELIMINARY CLINICAL RESULTS

We tested this system on a series of 30 patients with primary osteoarthritis of the knee. 15 patients received the computer-assisted procedure (group 2) and fifteen patients received the classical procedure (group 1). The trial was a prospective, randomized parallel study performed in Grenoble, France from January 13, 1998, to December 1, 1998.

PATIENTS

Thirty patients between 55 and 89 years of age (mean age, 69) were included. There were 14 right knees and 16 left knees that were surgically treated in the study after checking eligibility (e.g., inclusion and exclusion criteria, signing the consent form).

METHOD

The same surgeon treated the 30 patients, using either the classical procedure or the computer-assisted system (OrthoPilot; Aesculap AG, Tuttlingen, Germany). Two independent surgeons followed-up the patients 6 weeks after surgery. The review criteria included radiological criteria (the main criterion was the femoral tibia mechanical angle on the long-leg radiograph), complications, and

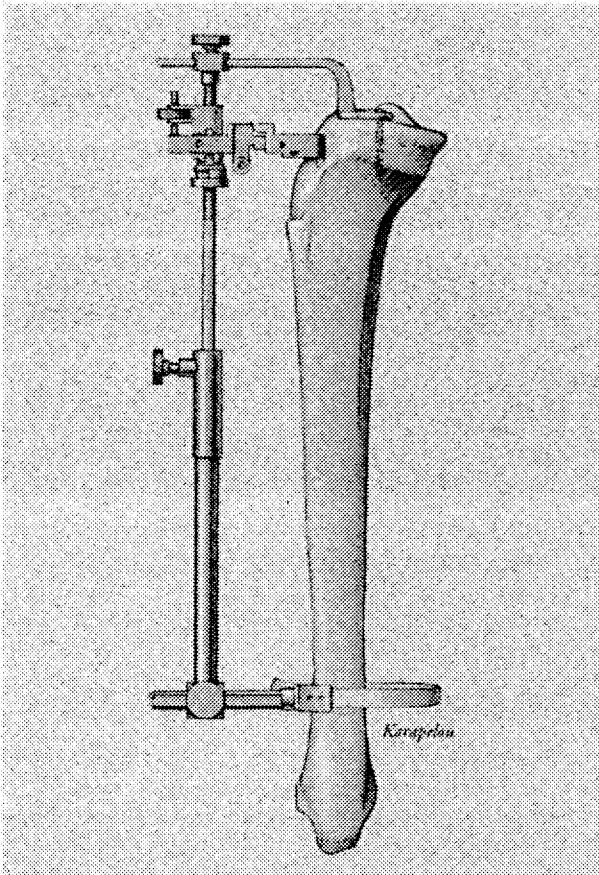


Fig 12. An extramedullary alignment device for the tibial cut used during the computer-assisted technique. The screen displays the jig position relative to the knee center.

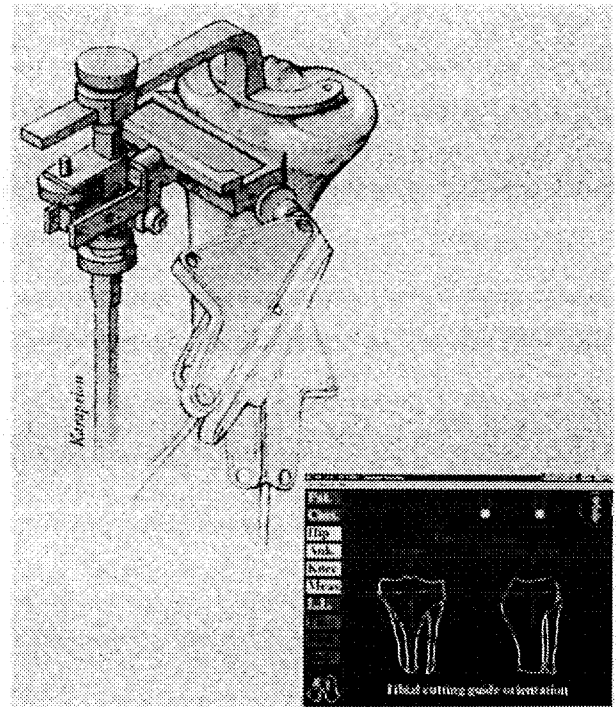


Fig 13. The cutting block is secured after checking the correct position by using the graphical interface depicted on the screen. The dashed line representing ideal cut: The full line indicates the jig position. 1, frontal plane; 2, sagittal plane; 3, cutting height.

surgical criteria, such as duration of the procedure and postoperative bleeding.

RESULTS

Radiographs were evaluated to determine what percentage of patients had (1) femoral-tibia angles between 3° of varus and 3° of valgus (group 1 = 100%, group 2 = 66.6%); (2) a femoral implant angle of 90° to the coronal mechanical axis (group 1 = 46.6%, group 2 = 0.06%); and (3) a tibia resection angle within 2° of varus or valgus (group 1 = 100%, group 2 = 86.6%).

The average duration of the procedures was 101 minutes in group 1 and 74 minutes in group 2. The average blood loss of the 2 groups was the same. There were no complications in group 1 and 3 complications in group 2 (2 patients had deep venous thrombosis, one patient had stiffness).

CONCLUSION

An overview of a computer-assisted TKR surgical technique has been presented to illustrate the principles of this new technology. The system that has been described is now in clinical use. Preliminary results with the system indicate that the alignment results that have been achieved are more accurate and reproducible than the mechanical system used to insert identical implants. The system is simple to understand and the computer hardware used is relatively inexpensive. The system uses currently available mechanical total knee instruments. The surgeon can use these instruments in the conventional way at any point in

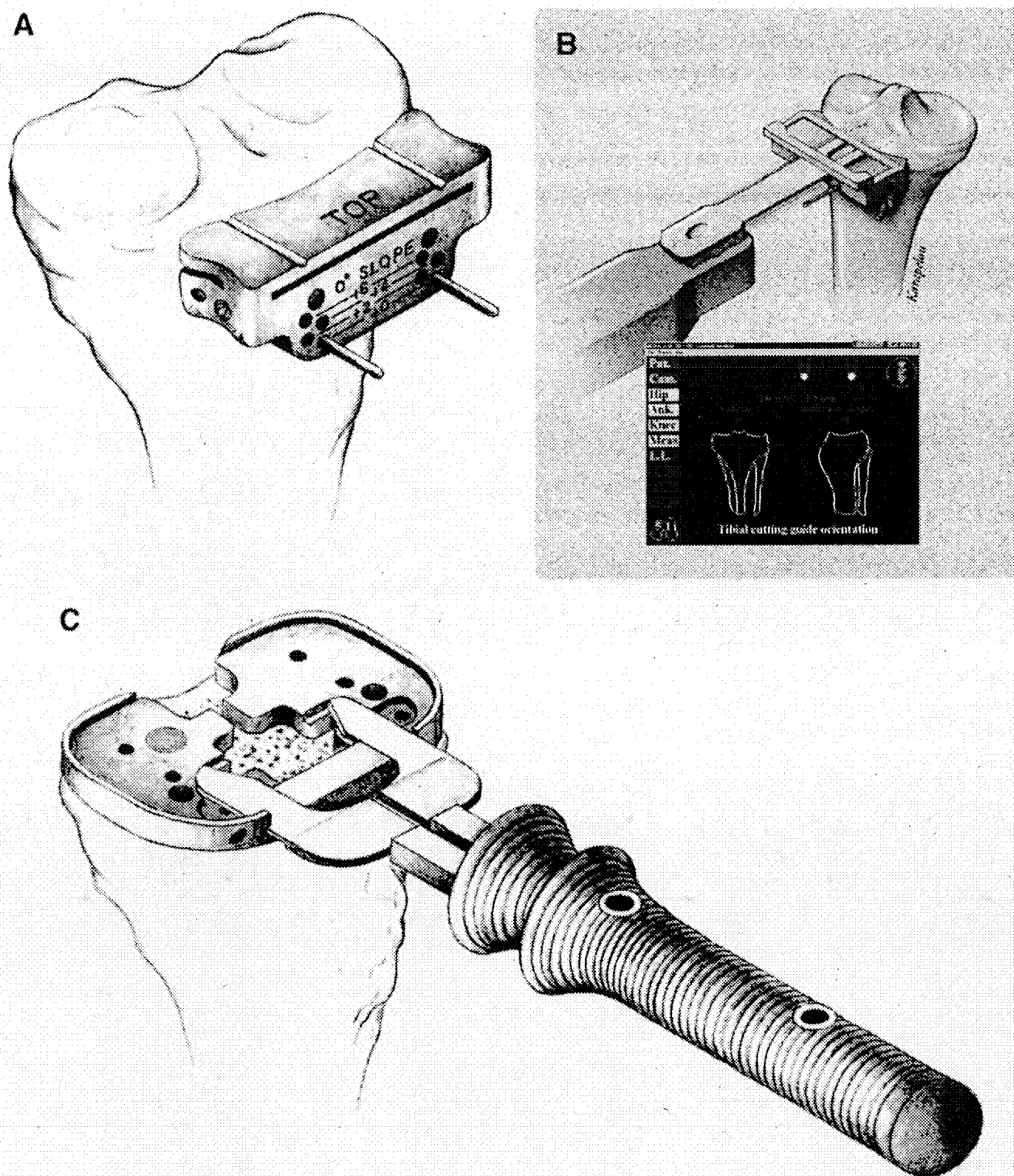


Fig 14. The cutting block can then be positioned. (A) Mechanical technique. (B) Computer-assisted technique. (C) Positioning of the tibial keel.

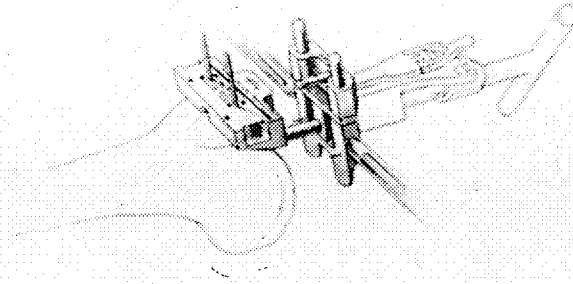


Fig 15. An intramedullary rod is introduced into the femoral canal, the distal femoral cutting block device is then placed, and the distal cut is made in the mechanical technique.

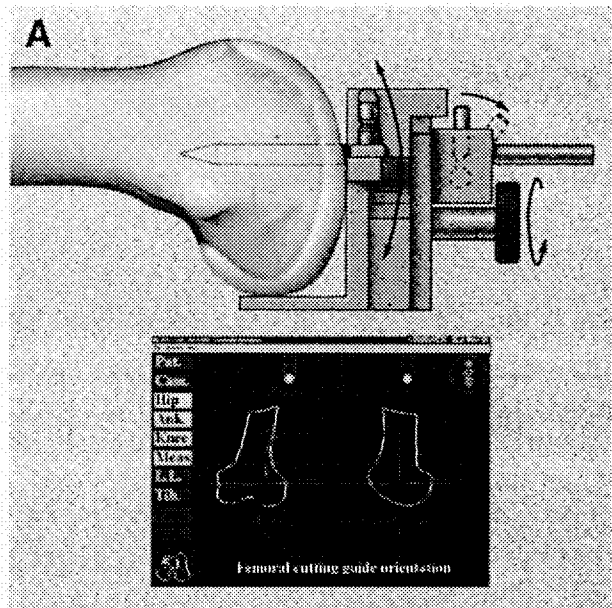
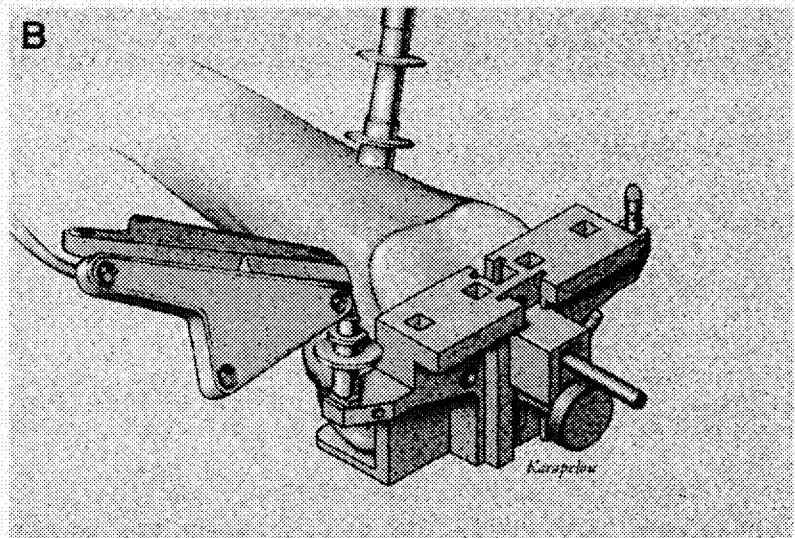


Fig 16. The distal femoral cutting block device is placed in the sagittal plane during the computer-assisted technique. The dashed line represents the ideal cut. The full line indicates jig sagittal position. 1-, 2-, 3- indicate steps to secure the distal femoral cutting block device. (A) Coronal view. (B) Sagittal view.



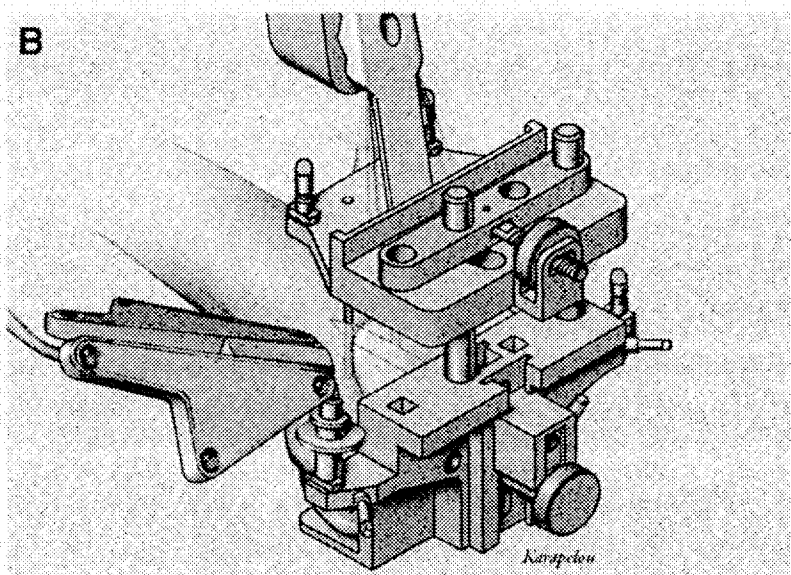
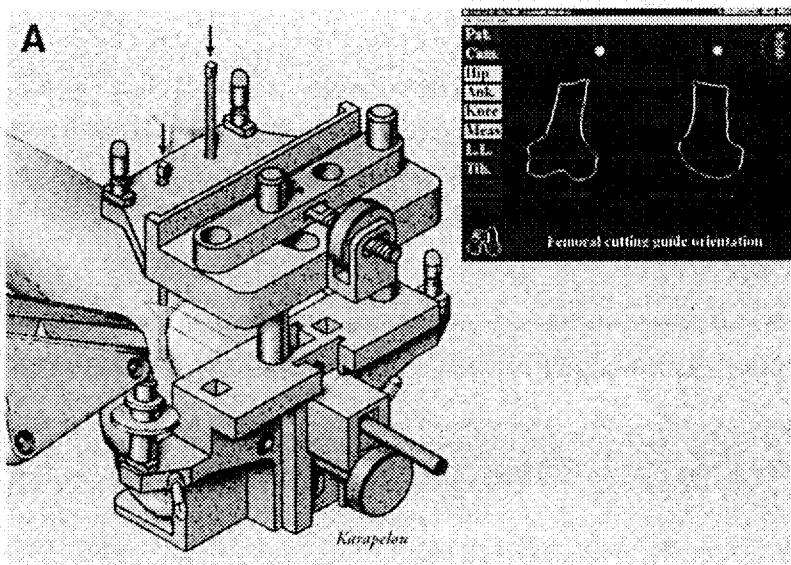


Fig 17. (A and B). The distal femoral cutting block device is placed in the frontal plane during the computer-assisted technique. The tibial cut is then made. The dashed line indicates ideal cut. The full line indicates the jig frontal position.

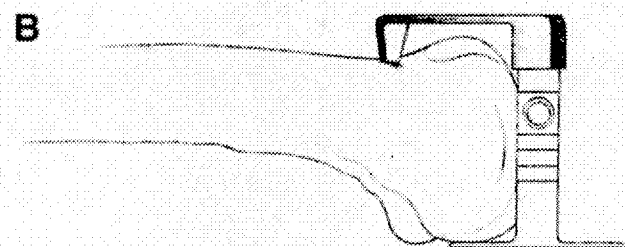
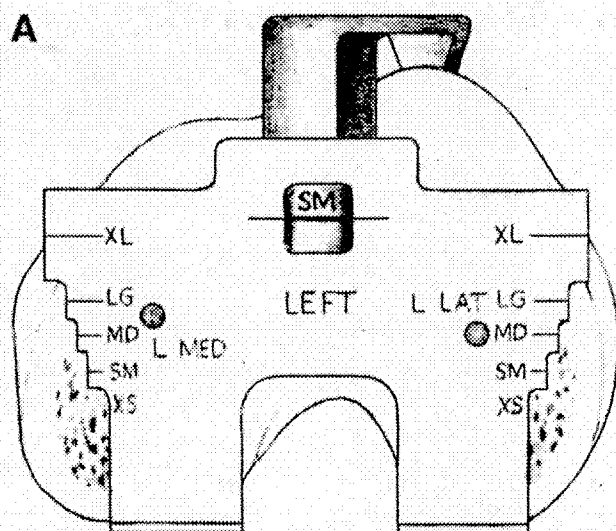
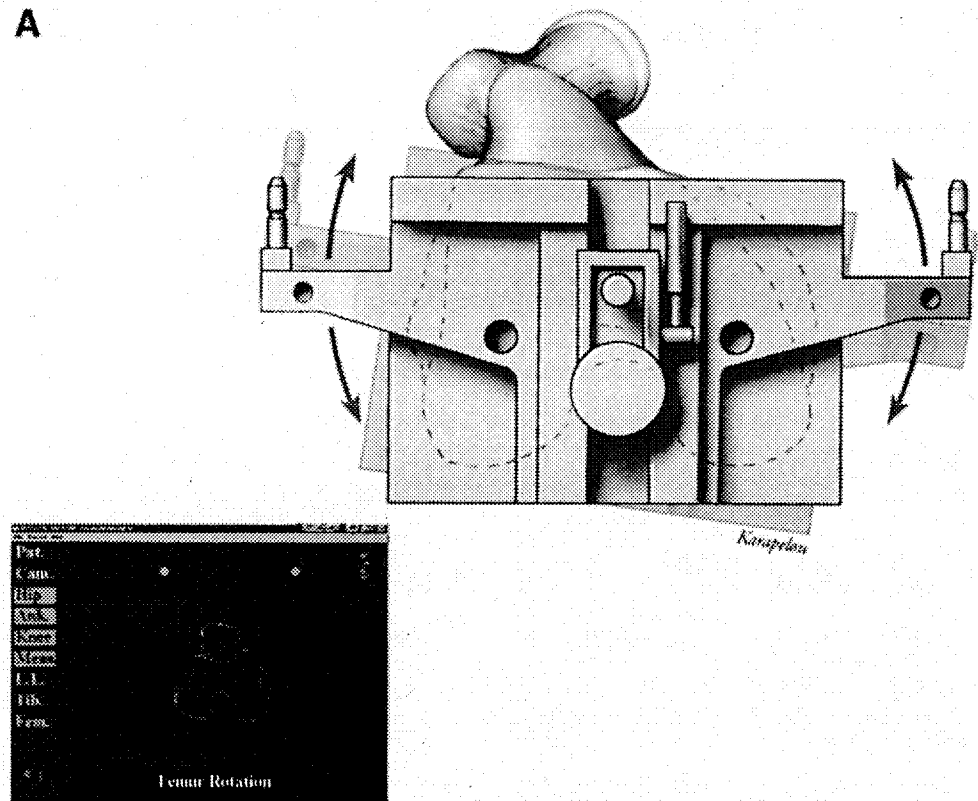


Fig 18. (A and B). Sizing of the femoral implant and establishing femoral component rotation during the mechanical technique.

A



B

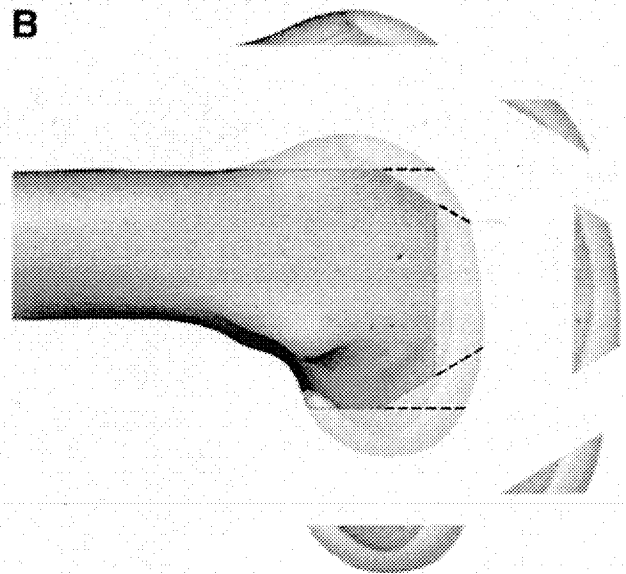


Fig 19. (A) Sizing of the femoral implant and establishing femoral component rotation during the computer-assisted technique. The dashed line indicates the reference line. The full line indicates the jig frontal position. (B) Chamfer cuts.

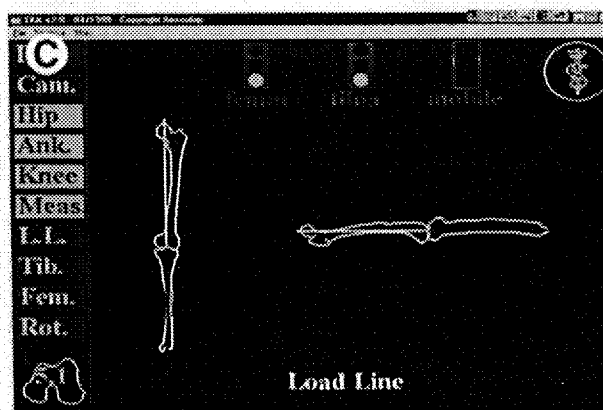
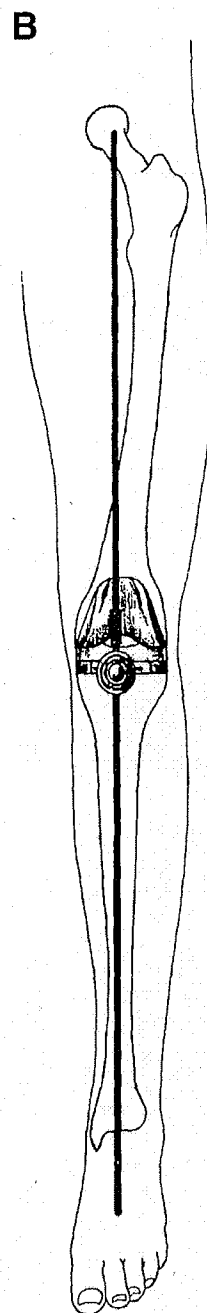
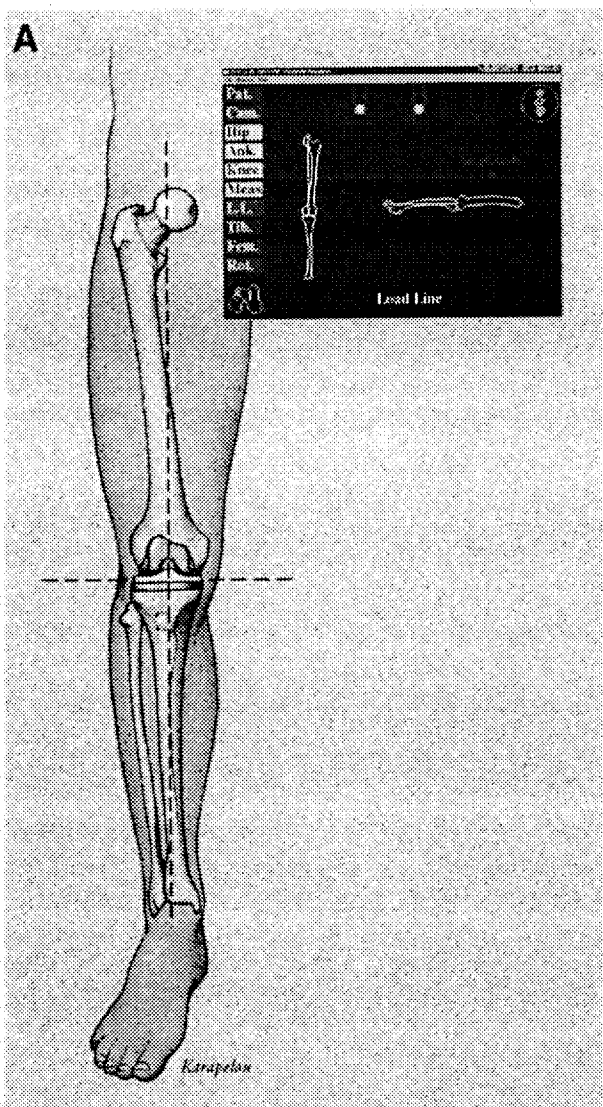


Fig 20. (A) Trial reduction with the use of the computer-assisted surgery technique. (B) Graphical interface displayed simultaneously with computer-assisted surgery technique. (C) Trial reduction with the use of mechanical surgery technique.

the surgical procedure if the guidance provided by the computer-assisted devices is considered inappropriate.

If systems such as the one described here are to be truly useful, they must be safe, accurate, easy to use, and cost-efficient. If these goals can be achieved, such systems are likely to be widely accepted by surgeons who perform TKR surgery.

REFERENCES

1. Freeman MAR, Todd RC, Bamert P, et al: ICLH-Arthroplasty of the knee: 1968-1977. *J Bone Joint Surg* 60B:339-344, 1978
2. Insall JN, Binazzi R, Soudry M, et al: Total knee arthroplasty. *Clin Orthop* 192:13-22, 1985
3. Insall JN, Ranawat CS, Aglietti P, et al: A comparison of four models of total knee-replacement prostheses. *J Bone Joint Surg Am* 58:754-765, 1976
4. Insall J, Scott WN, Ranawat CS: The total Condylar prosthesis. A report of the hundred cases. *J Bone Joint Surg Am* 61:173-179, 1979
5. Goodfellow JW, O'Connor JJ: Clinical results of the Oxford knee. *Clin Orthop* 205:21-42, 1986
6. Ranawat CS, Adjei OB: Survivorship analysis and results of total condylar knee arthroplasty. *Clin Orthop* 226:6-13, 1988
7. Feng EL, Stulberg SD, Wixson RL: Progressive subluxation and polyethylene wear in total knee replacements with flat articular surfaces. *Clin Orthop* 229:60-71, 1994
8. Ecker ML, Lotke PA, Windsor RE, et al: Long-term results after Total Condylar knee arthroplasty. Significance of radiolucent lines. *Clin Orthop* 216:151-158, 1987
9. Ritter MA, Herbst SA, Keating EM, et al: Radiolucency at the bone-cement interface in total knee replacement. *J Bone Joint Surg Am* 76:60-65, 1994
10. Laskin RS: Total Condylar knee replacement in patients who have rheumatoid arthritis. A ten-year follow-up study. *J Bone Joint Surg Am* 72:529-535, 1990
11. Jeffery RS, Morris RW, Denham RA: Coronal alignment after total knee replacement. *J Bone Joint Surg Br* 73:709-714, 1991
12. Matsen FA, Garbini JL, Sidles JA, et al: Robotic assistance in orthopaedic surgery: (A proof of principle using distal femoral arthroplasty). *Clin Orthop* 296:178-186, 1993
13. Kienzle TC, Stulberg SD, Peshkin M, et al: A computer assisted total knee replacement surgical system using a calibrated robot, in Taylor RH, et al (eds): *Computer Integrated Surgery*. Cambridge, MA, MIT Press, 1995
14. Fadda M, Bertelli D, Martelli S, et al: Computer assisted planning for total knee arthroplasty, in *First Joint Conference of Computer Vision Virtual Reality and Robotics in Medicine and Medical Robotics and Computer Assisted Surgery*, 1997. Grenoble, France, Springer, 1997, pp 619-628
15. Glozman D, Shoham M, Fischer A: Efficient registration of 3-D objects in robotic-assisted surgery proceedings. *Comput Aided Surg* (in press), 1999 (abstr)
16. Davies BL, Harriss J, Lin WJ, et al: Active compliance in robotic surgery—The use of force control as a dynamic constraint. *J Eng Med* 211: H4, 1997
17. Delp SL, Stulberg SD, Davies B, et al: Computer assisted knee replacement. *Clin Orthop* 354:49-56, 1998
18. Picard F, Leitner F, Raoult O, et al: Clinical evaluation of computer assisted total knee arthroplasty. *Comput Aided Surg* (in press), 1999 (abstr)
19. Picard F, Leitner F, Raoult O, et al: Early clinical results with the Orthopilot System. *Comput Aided Surg* (in press), 1999 (abstr)
20. Stulberg SD, Picard F: The rationale, surgical technique and preliminary results of a computer assisted total knee replacement system. *Comput Aided Surg* (in press), 1999 (abstr)
21. Leitner F, Picard F, Minfelde R, et al: Computer assisted knee surgical total replacement, in *First Joint Conference of Computer Vision Reality and Robotics in Medicine and Medical Robotics and Computer Assisted Surgery*, 1997. Grenoble, France, Springer Verlag, 1997, pp 630-638