

Computer Assisted Orthopaedic Surgery With Image Based Individual Templates

Klaus Radermacher, Dipl-Ing; Frank Portheine, Dipl-Ing*;
Marc Anton, Dipl-Ing**; Andreas Zimolong, Dipl-Ing*;
Günther Kaspers, MD**; Günter Rau, PhD*;
and Hans-Walter Staudte, MD***

Recent developments in computer assisted surgery offer promising solutions for the translation of the high accuracy of the preoperative imaging and planning into precise intraoperative surgery. Broad clinical application is hindered by high costs, additional time during intervention, problems of intraoperative man and machine interaction, and the spatially constrained arrangement of additional equipment within the operating theater. An alternative technique for computerized tomographic image based preoperative three-dimensional planning and precise surgery on bone structures using individual templates has been developed. For the preoperative customization of these mechanical tool guides, a desktop computer controlled milling device is used as a three-dimensional printer to mold the shape of small reference areas of the bone surface automatically into the body of the template. Thus, the planned position and orientation of the tool guide in spatial relation to bone is stored in a structural way and can be reproduced intraoperatively by adjusting the

position of the customized contact faces of the template until the location of exact fit to the bone is found. No additional computerized equipment or time is needed during surgery. The feasibility of this approach has been shown in spine, hip, and knee surgery, and it has been applied clinically for pelvic repositioning osteotomies in acetabular dysplasia therapy.

Recent research activities in the area of computer assisted surgery have concentrated on the introduction of additional sensor and robot based guiding systems into the operating theater to enable adequate computer assisted transferral of the high accuracy of preoperative imaging and planning to precise surgery. Different promising solutions have been developed concerning the related problems of multimodal information processing and registration, safety and sensor concepts, and adequate control strategies.^{5,19,22} Nevertheless, problems still remain such as the time needed intraoperatively for the interaction with additional technical system components, for the additional intraoperative registration of bone structures, the spatial arrangement of displays, sensors and robot systems within the operating room, the overall costs of the sensor or robot based systems, and mismatches regarding ergonomic design aspects of cognition and manual control.¹⁷ An exact medical, technical, and ergonomic analysis is neces-

From the *Helmholtz Institute for Biomedical Engineering, Aachen University of Technology, Aachen, Germany; and **Department for Orthopedic Surgery, District Hospital Marienhöhe, Würselen, Germany.

Supported in part by the European Commission in the framework of the Telematics Applications Program (TAP) project IGOS (Image Guided Orthopedic Surgery) project number HC1026HC.

Reprints requests to Klaus Radermacher, Dipl-Ing, Helmholtz Institut für Biomedizinische Engineering, Aachen University of Technology, Pauwelsstrasse 20, D-52074 Aachen, Germany.

sary to identify during which phases and sequences of intraoperative work additional guiding systems or even robotic assistance contributing a specific complementary function would be required.

In this context, the task sequences of different conventional orthopaedic interventions were investigated,^{12,16} such as total hip and total knee replacement surgery being typical applications for computer assisted surgery systems.^{9,19} One result of these investigations was that observable activities of direct orientation⁶ only took approximately 2% to 4% of the overall operating time. If all activities are taken into account that have some connection with exact three-dimensional positioning, their share of total intervention time is approximately 10% to 15%.^{12,16} Hence, the potential to shorten operating time and the related time slot for the introduction of computer assisted guiding systems seems to be limited. Prolongation of the operating time by additional intraoperative tasks and interactions with additional intraoperative equipment can be tolerated only to a limited degree because of medical, organizational, and economic reasons. In every case, it would have to be justified by significant enhancement of the therapeutic outcome. Moreover, the costs of additional equipment must be balanced against the requirement to deliver higher quality treatment to a larger number of patients.

The goal of the work described here was to develop a relatively simple, low cost solution that facilitates exact, safe, and fast implementation of planned surgery on bone structures, eliminates the need for continual radiographic monitoring, and avoids overburdening surgery with complex equipment and time consuming procedures.

PRINCIPLE OF INDIVIDUAL TEMPLATES

In orthopaedic surgery standard template systems are familiar technical means to guide drills and saws in total knee replacement.

However, the design of these tool guides is based on averaged anatomic geometries. The positioning of the template on the bone bears no precise relationship to the position defined by individual preoperative planning.

Essentially, the missing information is the precise spatial correspondence between the individual bone structure in situ and the intended position of the tool guides.

The authors investigated a means of adding this missing information to the classic templates by providing shape based physical matching between the reference surface of the individual bone and the reference surface of the computer based model. This information is incorporated into an individual template.¹²⁻¹⁶

Individual templates are customized on the basis of three-dimensional reconstructions of the bone structures extracted from computerized tomographic (CT) image data in accordance with individual preoperative surgical planning. For preoperative customization, a low cost desktop milling machine is used as a three-dimensional printer to mold the shape of a small reference area on the individual bone automatically into the template. By this means the planned position and orientation of the tool guide in spatial relation to the bone is stored in a structural way and can be reproduced in situ adjusting the position of the contact faces of the template until they fit exactly on the bone (Fig 1). Neither iterative time consuming work under radiographic control or registration procedures, nor any additional computerized equipment is needed intraoperatively. Mechanical guides for drills, saws, chisels, or milling tools are adaptable or integrated into these individual templates in predefined positions for different types of interventions. Moreover, individual templates also can be used for fixation of a reference base for standard tool guides or other devices in a defined position on bone. The individual templates can be autoclaved and delivered to the operating room with the conventional instrument sets. The feasibility and adaptability of this approach has been shown on anatomic models and in cadaver tests

A PRINCIPLE OF INDIVIDUAL TEMPLATES

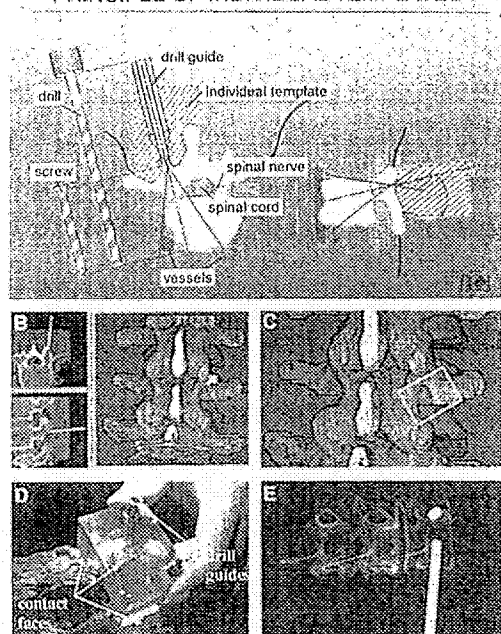


Fig 1. Pedicle screw placement: (A) the principle of individual templates based on preoperative CT imaging and computer based planning; (B) computer assisted planning of a pedicle screw placement with the DISOS planning system; (C) interactive specification of the reference contact face; (D) formclosed intraoperative fitting of the template; and (E) radiographic control of the placement of 5-mm rods in the pedicles without any perforation in situ.

for various applications.^{10,14,16} Results of in vitro studies on accuracy have been reported in previous publications.^{12,16}

Among the applications of this technique are pedicle screw placement (especially in scoliosis therapy; Fig 2); repositioning osteotomies in spine surgery; puncture of a cystic cavity in the femoral head; intertrochanteric repositioning osteotomy; initial reference osteotomies for total knee replacement (especially in the case of pathologic deformations); periacetabular repositioning osteotomies; open door decompression in the cervical spine; transcorporeal decompression in the cervical spine; and decompression in the lumbar spine.

To depict the spectrum and potential of various implementations of the principle of individual templates, four typical examples will be described in more detail, with emphasis on the clinical application of triple repositioning osteotomies for the treatment of acetabular dysplasia.^{12,14,18,20,22}

PEDICLE SCREW PLACEMENT

The selection of a pedicle screw of the appropriate length and caliber and its accurate fixation in the cortical bone of the pedicles and the vertebral body is essential for good anchoring. Perforations are the major specific complication of pedicle screw placements, implying a high risk of bone weakening or lesions of the spinal cord, nerve roots, or blood vessels.^{3,7} To monitor the placement of the piloting Kirschner wire and finally the screw, as many as four to five radiographs in different planes are recommended per screw placement.³ The authors selected this application for their initial investigations of the principle of individual templates^{12,13} (Fig 1). Human anatomic specimens of lumbar spines were scanned with CT (slices 2-mm thick and 2-mm apart). The image data were transferred to the personal computer based DISOS planning workstation (Gemetec mbH, Aachen, Germany). Based on three-dimensional reconstructions automatically provided by the system, the surgeon selects an appropriate screw and defines its optimal placement (Fig 1B). The position and orientation of the related drill guide then is specified and can be incorporated into the individual template. To provide shape based intraoperative matching, small reference contact faces to the vertebral bone have to be specified on the display in the vicinity of the transverse process, the arch, or the spinous process. To this end, the surgeon interactively selects and positions an appropriate template within the three-dimensional view of the vertebral bone structure (Fig 1C). The surgeon is supported by the system, which automatically constrains the positioning to the direction of the defined bore axis and evaluates the quality of the contact

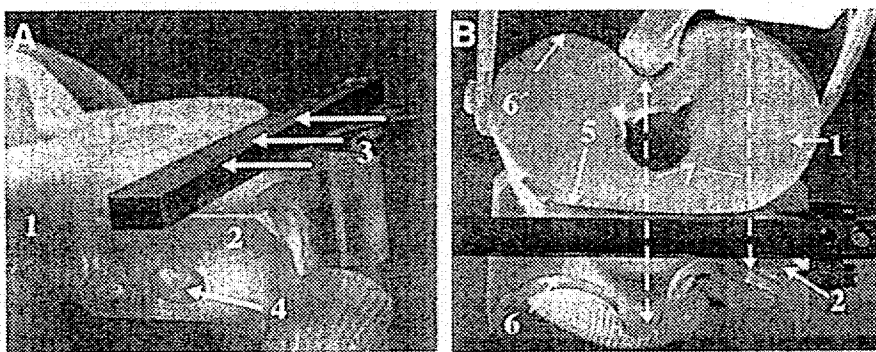


Fig 2A-B. Total knee arthroplasty: (A) laboratory investigation on a plastic bone model (1); individual template guiding the reference osteotomy (3) in tibial bone, optional fixation with a bone pin (4); (B) customized reference contact face (5) and copying profile (6) limiting cutting depth (7) to the dorsal contour (6) of tibial bone.

face. Afterward, the system automatically generates the manufacturing program and customizes the semifinished template with its integrated drilling guides. Intraoperatively, the defined position of the bore is reproduced by placing the self locating template where it fits exactly on the bone. Additionally, an optional radiographic control of the position of the stainless steel drilling guide is possible, because the plastic material of the template body is radiolucent. In two cadaver studies, in which one macerated specimen and one specimen with soft tissue were used, 5-mm bores have been reproduced exactly according to the preoperative planning without any perforation in situ.

TOTAL KNEE ARTHROPLASTY

In total knee arthroplasty accurate placement of implant components with respect to the individual mechanical axis of the leg is essential. Conventionally, modular mechanical devices corresponding to the intrinsic shape of the implant components are used to guide the osteotomies and bores for the preparation of the implant's seat. By mounting these conventional tool guide systems on an individual template as a basic customized reference, it is possible to reproduce the preoperatively planned position exactly even in the

case of severely deformed bone. Moreover, for preservation of the posterior cruciate ligaments and the nerves and vessels in the hollow of the knee, not only the reference surface of the bone but also a copying surface limiting the cutting depth to the dorsal contour of the tibia can be molded into the template (Fig 2B). The geometry of the saw has to be known and a calibrated copying cam has to be mounted on the conventional saw.

Figure 2 shows a feasibility study with a CT image based individual template for the reference tibial cut for total knee replacement on a plastic bone model.¹⁵ The geometry of the cut with its position, orientation, and limitations was planned on the basis of CT images (slices 2-mm thick and 2-mm apart). In addition, topograms could be used to identify the bone axis. A conventional saw guide can be mounted on the individual template, which serves as a reference base for subsequent work on the bone. The template has been customized in the areas of the reference surface and the individual copying profile corresponding to the dorsal contour of the tibial bone within the cut plane. The accuracy of the reproduction was measured directly on the bone model using a conventional precision goniometer and a caliper gauge. The predefined cut plane and the position of the copying profile limiting the cutting depth were repro-

duced with an accuracy better than 1 mm in all directions and 1° inclination in the sagittal and transverse planes.

OPEN DOOR DECOMPRESSION IN CERVICAL SPINE

The authors investigated the possibility of applying this principle to open door decompression in the cervical spine, which involves even more delicate constraints on the required accuracy of imaging, planning, and implementation.^{14,15} The task is to mill away one side of the lamina completely and to preserve the anterior cortical layer on the other side, which acts as a hinge for the dorsal open door laminoplasty. Figure 3 shows a corresponding design of an individual template and the planning and intraoperative implementation in the framework of a cadaver study.^{13,14} Applying the principle of copying profiles, a miniaturized copying cam corresponding to the geometry of the milling tool was mounted on a standard micromilling machine, with a sliding jig plate to guide the micromill perpendicular to the template. A bore with a defined depth was provided in the template for a final on site calibration of the length of the milling tool with respect to the copying cam. Then, both laminotomies were performed within less than 10 minutes, subsequently removing several layers of bone to less than 1 mm on the left side and approximately 1 mm on the right side. The micromilling tool was guided by the copying profile, leaving the anterior cortical hinge of the right lamina intact. It perforated only slightly at two points on the left side without damaging the dura (Fig 3E-F).

TRIPLE OSTEOTOMY OF PELVIC BONE FOR THE TREATMENT OF A DYSPLASTIC HIP JOINT

Periacetabular triple osteotomy for the treatment of hip dysplasia was chosen as the first exemplary clinical application of individual templates.^{14,16,18} In acetabular dysplasia the task is to enlarge the weightbearing part of the

acetabulum covering the femoral head to reduce the pressure on this area to physiologic limits. The major therapeutic goals are relief from pain and prevention of premature osteoarthritis.

Using the operative procedure reported by Tönnis²⁰ and Tönnis and coworkers,²¹ the acetabulum has to be mobilized by three osteotomies, which have to be performed in a defined position and orientation in relation to the acetabulum. If the distance from the acetabulum is too short there is a higher risk of avascular necrosis, and if the acetabular fragment becomes too large its free rotation may be impeded.²¹ Moreover, the inclination of the cut planes influences the ability to rotate the fragment freely in a specific direction. Conventionally, the three osteotomies have to be performed under repeated radiographic control. The ischial osteotomy has to meet the obturator foramen and preserve the sciatic nerve and the sacral ligaments. Although the pubic osteotomy is less critical, it is directly adjacent to the femoral vein. For the manipulation and repositioning of the acetabulum, a Schanz screw has to be fixed on the acetabular fragment. The final iliac osteotomy has to meet the distal part of the incisura ischiadica. This is the longest and most difficult osteotomy and has the greatest influence on the mobility of the acetabular fragment and the initial stability of the fixation.

For the repositioning of the acetabulum, empiric standard values still are based on biplanar xray projections in the anteroposterior (AP) and faux profile planes. According to Tönnis et al²¹ lateral center edge and anterior center edge angles of approximately 30° to 35° should be achieved. Additionally, three-dimensional CT imaging is recommended for diagnosis and surgical planning to achieve more accurate and reliable assessment of the individual anatomic and biomechanical conditions in the weightbearing area of the hip.^{1,2,4,8,10} Nevertheless, the authors know of no validated standards based on three-dimensional imaging, comparable with the empiric data provided by Tönnis et

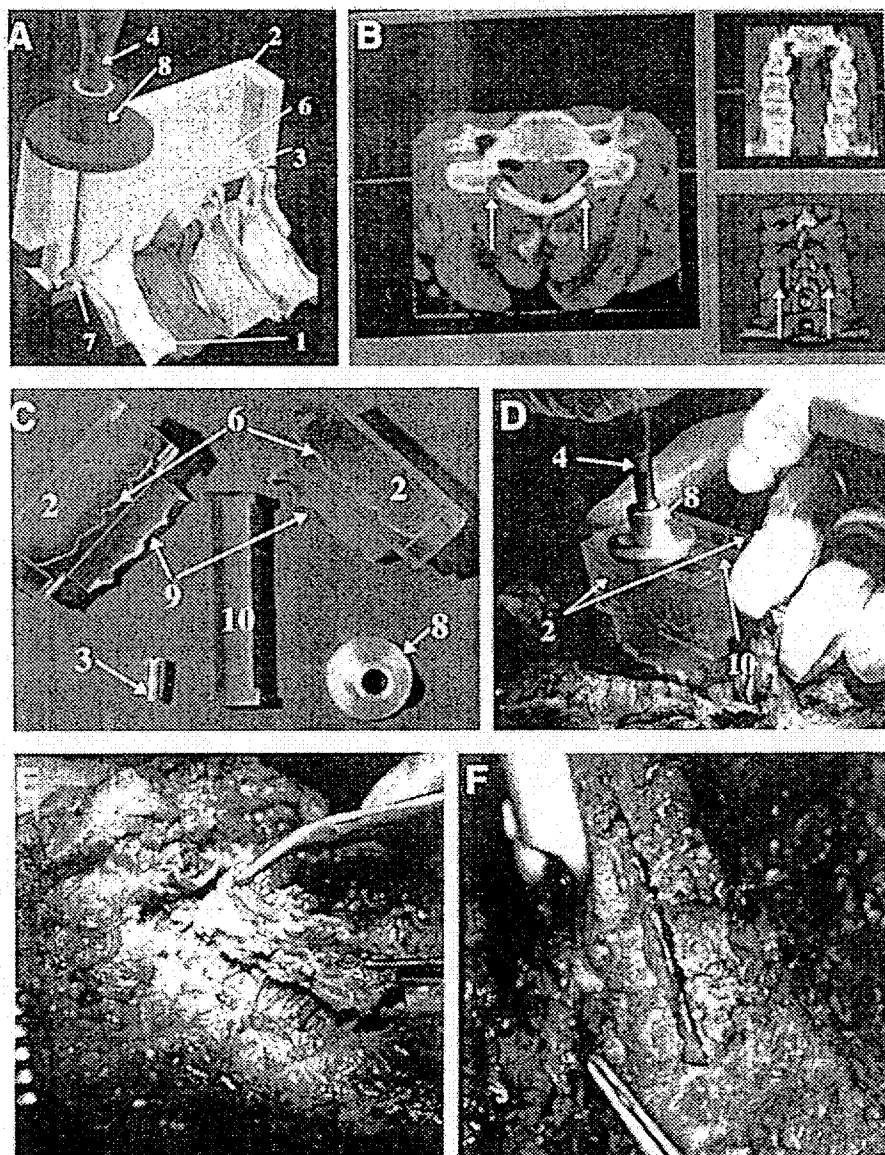


Fig 3. Open door decompression in the cervical spine: (A) design of an individual template (2) with a copying profile (6) limiting cutting depth of the milling head (7) to the anterior cortical layer of the lamina (1); a micromilling machine (4) is equipped with a sliding jig plate (8); (B) planning of the milling work on bone, arrows indicating the specified area of bone to be removed; (C) the reference to the bone structure is provided by an individual contact face (9); the two individual parts of the template are connected by a simple adapter (10); (D) intraoperative execution in the framework of a cadaver study; (E) result on the left side showing the intact dura; and (F) result on the right side with the intact cortical hinge.

al.²¹ Therefore, in addition to the conventional technique, the authors use a combination of anterior center edge and lateral center edge angle measurements in AP and faux profile xray projections reconstructed from CT data, automatic measurements of the anterior center edge and lateral center edge angles on the reconstructed three-dimensional bone model, and an analysis of the surface coverage of the femoral head in the weight-bearing zone. Comparison and evaluation of these different assessment methods are subjects of ongoing research.

Computed tomographic scans of the patients normally are done at 3- to 4-mm slice distances with 30 to 40 images including one AP topogram. The data are transmitted to the DISOS planning system with which a non-technical user can generate individual templates autonomously. The entire computer based surgical planning session of approximately 5 to 10 minutes is subdivided into sections for three-dimensional diagnosis, planning of osteotomies, simulation and biomechanical analysis of the repositioning, and the specification of appropriate reference contact faces of the template on bone.¹¹ At the beginning of the planning session the surgeon selects the type of intervention and the specific surgical technique. After this selection he or she is guided along the subsequent steps of surgical planning according to established guidelines and handbooks.

To plan an osteotomy, the surgeon defines a margin of safety of 14 to 20 mm of all cuts from the acetabulum. The system automatically generates a corresponding periacetabular safety sphere and automatically constrains the specification of all three osteotomies to be tangential to this sphere (Fig 4A). Thus, the interactive manipulation and definition of the osteotomies is facilitated significantly because only the inclination of the cut planes has to be adjusted interactively in the sagittal and transverse planes, and optimal mobility of the acetabular fragment is guaranteed. After the virtual implementation of the osteotomies and automatic segmentation of the

acetabulum and the femoral bone, the acetabular fragment can be manipulated directly by the surgeon in the transverse and sagittal planes, just as it would be done during surgery (Fig 4B). For each position, the system automatically calculates the resulting anterior center edge and lateral center edge angles from the three-dimensional model and enables three-dimensional analysis of the coverage of the femoral head. Moreover, the mobility of the acetabular fragment can be analyzed to become aware of potential collisions with the surrounding bone structures, and the possibilities of fixating the fragment can be assessed. The entire planning session is documented by the system, and printouts of all relevant planning stages and parameters, including the exact angles of the correction in the sagittal and transverse planes necessary to achieve the planned lateral center edge and anterior center edge angles, can be provided automatically.

After this planning step, the surgeon decides for which osteotomies he or she wants to use a customized tool guide. The pubic cut is not critical and does not require an individual template. Clinical trials also have shown that the ischial osteotomy is facilitated sufficiently by the preoperative planning step and the intraoperative identification of the appropriate anatomic landmarks. Nevertheless, individual templates for the ischial osteotomy can be manufactured if desired and have been used in some clinical cases.¹⁴ In contrast, an individual template always is used for the most critical iliac osteotomy. As the positioning of the template already is defined partially after planning of the osteotomy, the surgeon can be guided by the system in an efficient and intuitive way. He or she uses the three-dimensional view to specify the direction of his or her surgical approach and the desired position of the template on the bone. The final step involves the automatic milling of the template. Then, after 5 to 10 minutes of interactive surgical planning and 10 to 20 minutes automatic desktop customization (Fig 4C), the individual templates can be labeled, packed, and steril-

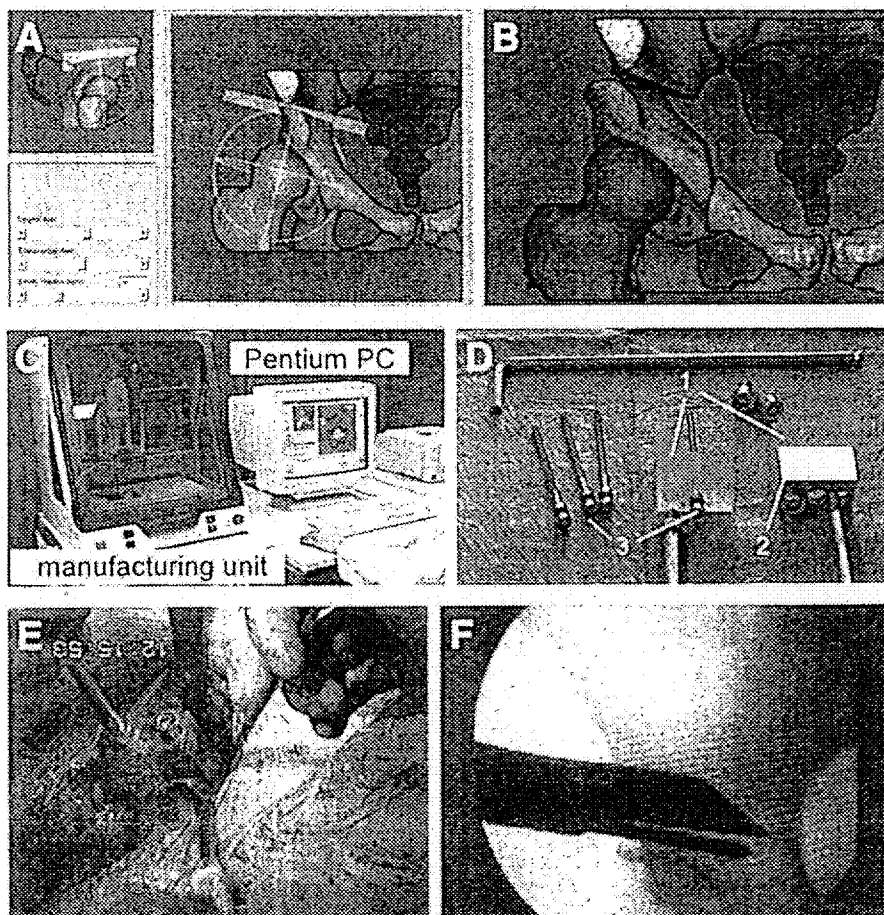


Fig 4. Triple pelvic osteotomy: (A) planning of the ilium osteotomy; (B) simulation of the repositioning; (C) DISOS planning station with a desktop manufacturing unit; (D) the intraoperative toolset with different individual templates (1), adaptable stainless steel tool guides (2), and optional bone pins (3); (E) intraoperative use; and (F) radiographic control. PC = personal computer.

ized by conventional steam. Because the templates can be autoclaved to 135°C, they can be ready for surgery within less than 1 hour after the transmission of the CT image data.

Data on 24 triple osteotomies collected between March 1996 and March 1998 are shown in Table 1. In this group, 11 interventions have been done in the conventional manner and 13 interventions have been done using individual templates. In four cases the templates could not be positioned exactly. Because of very strong soft tissue, the contact

face between the template and bone that had been specified during planning the intervention was not accessible without additional resection of soft tissue. This problem has been overcome by a new design of the templates and the tool guide. Positioning of the reference contact face of the iliac template on the anterior superior iliac spine medial and cranial to the cut plane allows the best access to the bone surface through a less invasive surgical approach. After these modifications the templates could be positioned appropriately.

TABLE 1. Triple Osteotomy Interventions March 1996 to March 1998

Year	Number of Interventions	Number of Interventions Without Individual Templates	Number of Interventions With Individual Templates	Optimal Positioning of Template and Cut*	Failed Positioning of Templates
1996	10	7	3	1	2
1997	10	3	1 + 6**	5	2
1998	4	1	3**	3	0*
Total	24	11	13	9	4

*Subjectively assessed by means of radiographs.

**With the new integrated DISOS planning and manufacturing system.

Intraoperatively the main benefit of preoperative planning of individual templates is avoiding an iterative search of the optimal cut planes and correction angles under repeated radiographic control, better mobility of the acetabulum, and a shorter time of intervention. The template can be fixed optionally by a bone pin or held by the assistant using a flexible handle (Fig 4D-E). A single radiograph is used to confirm the position of the tool guide, after which the osteotomy can be performed with an oscillating saw and optionally finished with a chisel (Fig 4F).

In addition to redesigning templates for a more medial approach to the iliac wing, numerous other changes have been made in the course of developing the approach described in this paper. These include modified patient positioning (lateral and supine as described by Tönnis et al²¹) and the use of a new type of saw (jigsaw). Only data from interventions that were done under comparable conditions have been considered for additional analysis. All templates were planned and manufactured using the new integrated DISOS station, and all patients have been operated on by the same surgeon, who had more than 12 years experience with this type of intervention.

In a first analysis of data from 10 interventions of this type collected during an ongoing comparative study between January 1997 and March 1998 (Table 2), the mean effective time of intraoperative xray monitoring was reduced by more than 75%, and the

mean time of intervention was reduced by 25% compared with the conventional procedures without individual templates. The exact positioning of the osteotomies resulted in optimal mobility of the acetabulum, which could be repositioned according to the planned values. No additional soft tissue had to be removed and the periosteum was preserved in every case.

DISCUSSION

Although the number of cases has been too small to derive reliable statistical data, the preliminary results are promising. The individual template approach represents a relatively simple, low cost, and easy to use solution that facilitates precise preoperative planning and appropriate intraoperative implementation. The conventional intraoperative procedure is preserved and no additional intraoperative registration steps, computerized equipment, space, or personnel are needed. Continual fluoroscopic monitoring can be avoided, fewer radiographs are needed, and the duration of intervention is reduced.

The position of best fit for positioning the template can be found easily by hand, because no significant free motion of the template should occur while pressing the template slightly against the bone. Because of the structured surface of the templates' contact faces and the redundancy of the surface based matching, the templates are sufficiently robust against preparation artifacts

TABLE 2. Preliminary Results of the Comparative Clinical Evaluation

January 1997 to March 1998	10 Interventions With Standardized Technique and Boundary Conditions	
	Five Interventions With Individual Templates	Five Interventions Without Individual Templates
Time of intervention (minutes)	105-130	105-185
Average (minutes)	118	157
Median (minutes)	120	170
Intraoperative radiograph time (minutes)	0.06-0.34	0.08-1.45
Average (minutes)	0.15	0.65
Median (minutes)	0.07	0.23

(such as small quantities of remaining soft tissue or small defects in the modeled surface). The periosteum can be preserved.

One main drawback of the approach is that it depends on preoperative CT imaging. Moreover, no percutaneous applications are possible (except in dental or maxillofacial surgery). Lamellar contact faces (with ribs or arrays of pins) could be manufactured to compensate to a limited extent for remaining soft tissue.¹⁵ But as in most sensor based surface registration techniques, the accuracy and reliability of this technique depends on the accessibility and appropriate intraoperative identification of the rigid reference structures segmented and modeled in the preoperative image data.

Future research will be dedicated to the ongoing clinical evaluation of the demonstrator system for pelvic surgery in cooperation with additional clinical centers. The benefit for less experienced surgeons and the influence on the intervention specific learning curve will be investigated in more detail. Because postoperative CT scanning of patients does not seem justifiable, additional cadaver studies will be conducted to obtain more quantitative data on the overall accuracy of the technique. It is planned to integrate additional tools into the system (in particular for hip, knee, and spine surgery), magnetic resonance image processing mod-

ules and enhanced models for efficient biomechanical analysis.

References

1. Abel MF, Sutherland DH, Wenger DR, et al: Evaluation of CT scans and 3-D reformatted images for quantitative assessment of the hip. *J Pediatr Orthop* 14:48-53, 1994.
2. Azuma H, Taneda H, Igarashi H: Evaluation of acetabular coverage: Three-dimensional CT imaging and modified pelvic inlet view. *J Pediatr Orthop* 11:765-769, 1991.
3. Bauer R, Kerschbaumer F, Poisel S: *Orthopädische Operationslehre*. Stuttgart, Thieme-Verlag 1994.
4. Brunner R, Robb J: Inaccuracy of the migration percentage and center-edge angle in predicting femoral head displacement in cerebral palsy. *J Pediatr Orthop* 5:239-241, 1996.
5. Cinquin P, Bainville E, Barbe C, et al: Computer assisted medical interventions. *IEEE Eng Med Biol* 14:254-263, 1995.
6. Faccaoru C, Frieling E: Verfahren zur Ermittlung informatorischer Belastungen. *Z Arbeitswissenschaft* 39:65-72, 1985.
7. Jerosch J, Malms J, Castro WHM, Wagner R, Wiesner L: Lagekontrolle von Pedikelschrauben nach instrumentierter dorsaler Fusion der Lendenwirbelsäule. *Z Orthop* 130:479-483, 1992.
8. Klauke K, Wallin A, Ganz R: CT evaluation of coverage and congruency of the hip prior to osteotomy. *Clin Orthop* 232:15-25, 1988.
9. Matsen III FA, Garbini JL, Sidles JA, et al: Robotic assistance in orthopaedic surgery: A proof of principle using distal femoral arthroplasty. *Clin Orthop* 296:178-186, 1993.
10. Millis MB, Murphy SB: Use of computed tomographic reconstruction in planning osteotomies of the hip. *Clin Orthop* 274:154-159, 1992.
11. Portheine F, Radermacher K, Zimolong A, et al: Development of a Clinical Demonstrator for

- Computer Assisted Orthopedic Surgery with CT Image Based Individual Templates. In Lemke HU, Vannier MW, Inamura K (eds). *Computer Assisted Radiology and Surgery*. Amsterdam, Elsevier 944-949, 1997.
12. Radermacher K, Protheine F, Zimolong A, et al: Image Guided Orthopedic Surgery Using Individual Templates—Experimental Results and Aspects of the Development of a Demonstrator for Pelvis Surgery. In Troccaz J, Grimson E, Mösges R (eds). *Computer Vision, Virtual Reality and Robotics in Medicine and Medical Robotics and Computer Assisted Surgery, Lecture Notes in Computer Science*. Berlin, Springer-Verlag 606-616, 1997.
 13. Radermacher K, Rau G, Staudte HW: Computer Integrated Orthopedic Surgery—Connection of Planning and Execution in Surgical Interventions. In Taylor R, Lavallée S, Burdea G, Mösges R (eds). *Computer Integrated Surgery*. Cambridge, MIT Press 451-463, 1996.
 14. Radermacher K, Staudte HW, Rau G: Computer Assisted Orthopedic Surgery by Means of Individual Templates—Aspects and Analysis of Potential Applications. In DiGioia A (ed). *Proceedings of the First International Symposium on Medical Robotics and Computer Assisted Surgery*. Pittsburgh, Carnegie Mellon University 42-48, 1994.
 15. Radermacher K, Staudte HW, Rau G: Technique for Better Execution of CT Scan Planned Orthopedic Surgery on Bone Structures. In Lemke HU, Inamura K, Jaffe CC, Vannier MW (eds). *Computer Assisted Radiology*. Berlin, Springer 933-938, 1995.
 16. Radermacher K, Staudte HW, Rau G: CT Image Based Planning and Execution of Interventions in Orthopedic Surgery Using Individual Templates—Experimental Results and Aspects of Clinical Applications. In Nolte LP, Ganz R (eds). *CAOS—Computer Assisted Orthopaedic Surgery*. Bern, Hans Huber (In Press) 1998.
 17. Rau G, Radermacher K, Thull B, et al: Aspects of an Ergonomic System Design of a Medical Worksystem. In Taylor R, Lavallée S, Burdea G, Mösges R (eds). *Computer Integrated Surgery*. Cambridge, MIT Press 203-221, 1996.
 18. Staudte HW, Radermacher K, Rau G: CT-abgeleitete Operationsschablone am Beispiel der Tripel-Osteotomie nach Tönnis. In Wessinghage D (ed). *Praktische Orthopädie*. Vol 27. Stuttgart, Thieme 165-171, 1997.
 19. Taylor RH, Lavallée S, Burdea G, Mösges R (eds): *Computer Integrated Surgery*. Cambridge, MIT Press 1996.
 20. Tönnis D: Die angeborene Hüftdysplasie und Hüftluxation im Kindes- und Erwachsenenalter. Berlin, Springer-Verlag 1984.
 21. Tönnis D, Arning A, Bloch M, et al: Triple pelvic osteotomy. *J Pediatr Orthop* 3:54-67, 1994.
 22. Troccaz J, Grimson E, Mösges R (eds): *Computer Vision, Virtual Reality and Robotics in Medicine and Medical Robotics and Computer Assisted Surgery, Lecture Notes in Computer Science*. Berlin, Springer-Verlag 1997.