

SURGICAL TECHNIQUES IN THE PERFORMANCE OF UNICOMPARTMENTAL ARTHROPLASTIES

PETER A. KEBLISH, JR, MD

The technical principles of unicompartmental knee arthroplasty (UKA) are similar to but subtly different from total knee arthroplasty (TKA). Reestablishing the joint line of the diseased compartment and restoring the altered anterior cruciate ligament, posterior cruciate ligament, and collateral (medial and lateral) kinematics are the goals of surgery. When proper indications exist, normal knee function is possible. Instrumentation systems plus surgical expertise must provide for accurate compartment resurfacing of the femoral condyle and tibial plateau. Technical errors of malposition (rotational, varus-valgus, flexion-extension) and gap imbalance (depth of resection) will negatively affect stability, mobility, wear, and fixation with less than satisfactory clinical outcomes. Because few UKAs are performed, even by so-called experts, more attention to detail is required. Excellent long-term results can be appreciated when patient selection, prosthetic design, and surgical technique are optimal. This section addresses the key technical aspects of UKA that will affect clinical results.

KEY WORDS: arthroplasty, knee prosthesis, prosthesis design

Unicompartmental knee arthroplasty (UKA) provides an alternative to high tibial osteotomy (HTO) and total knee arthroplasty (TKA) for angular knee deformity. Criteria and selection factors in the literature to date have been conservative.¹⁻⁴ The procedure is usually recommended for relatively inactive, elderly patients. An increasing number of patients, however, are more youthful, more active, will live longer, and desire to maintain an active lifestyle, including recreational athletics, such as tennis, skiing, and so on. These patients may be too young for TKA and may not meet the treatment criteria for HTO or newer approaches, such as autologous cartilage autotransplantation and allograft (bone, cartilage, meniscal) transplantation.⁵ Improvement in prosthetic design, materials, instrumentation, and surgical technique have renewed interest in UKA for this patient group.

The philosophy of UKA is to realign minimal, correctable angular deformity while preserving normal kinematics. The procedure entails a resurfacing to reestablish the normal ligament environment (cruciates and collaterals) and the mechanical axis to the premorbid alignment, which is dictated by collateral ligament tension. Flexion-extension balancing must be accomplished without lengthening releases, subtle elevation of the joint line, overloading the opposite compartment, overcorrection, or creating patellofemoral impingement.

Patient selection remains the most important factor if early failures are to be avoided. All investigators have stressed that UKA patient selection is most important,

including proper diagnosis, age, activity level, weight, and appropriate imaging studies (magnetic resonance imaging, computed tomography scans) to confirm noninflammatory single compartment disease. Most agree that the patient should have a correctable deformity, an intact anterior cruciate ligament (ACL), no or minimal opposite compartment, or no patellofemoral involvement (Fig 1). The patient should be well motivated with a good understanding of the philosophy of the procedure. Many patients have had previous arthroscopic surgery with well-documented compartment pathology and overall joint assessment. However, conversion to TKA at surgery, if indicated, must be agreed upon by the patient because more extensive disease may be present than had been anticipated.

Prosthetic design, the second major factor in successful UKA, must allow for unconstrained motion without mechanical (translational or rotational) blocks.⁶ Designs that have attempted to introduce increased stability without allowing for mobility have resulted in premature mechanical failures,^{7,8} whereas designs with high contact stress have led to failures secondary to polyethylene wear.⁸⁻¹¹ The two basic designs that have stood the test of time (Fig 2) are round-on-flat fixed bearing and meniscal bearing with more congruent geometry. Fixed-bearing designs include all polyethylene tibial components (Marmor prototype; Richards, Memphis, TN) or metallic-backed polyethylene tibial components (Brigham prototype; Johnson and Johnson, New Brunswick, NJ), which have been modified to allow for cementless fixation and modularity. Meniscal-bearing designs include the Oxford (Biomet, Warsaw, IN) (Goodfellow-O'Connor) cemented straight track constant radius and the low contact stress (LCS; De Puy, Leeds, UK) radial track with decreasing radius of curvature. The LCS provides the option of cementless fixation. Fixed and meniscal-bearing knees have been used successfully for over 20 years and provide options for the orthopaedic

From the Division of Orthopaedic Surgery, Lehigh Valley Hospital, Allentown, PA; and the Penn State University College of Medicine, Hershey, PA.

Address reprint requests to Peter KEBLISH, MD, 1243 S. Cedar Crest Blvd, Suite 2500, Allentown, PA 18103.

Copyright © 1998 by W.B. Saunders Company

1048-6666/98/0803-0002\$08.00/0

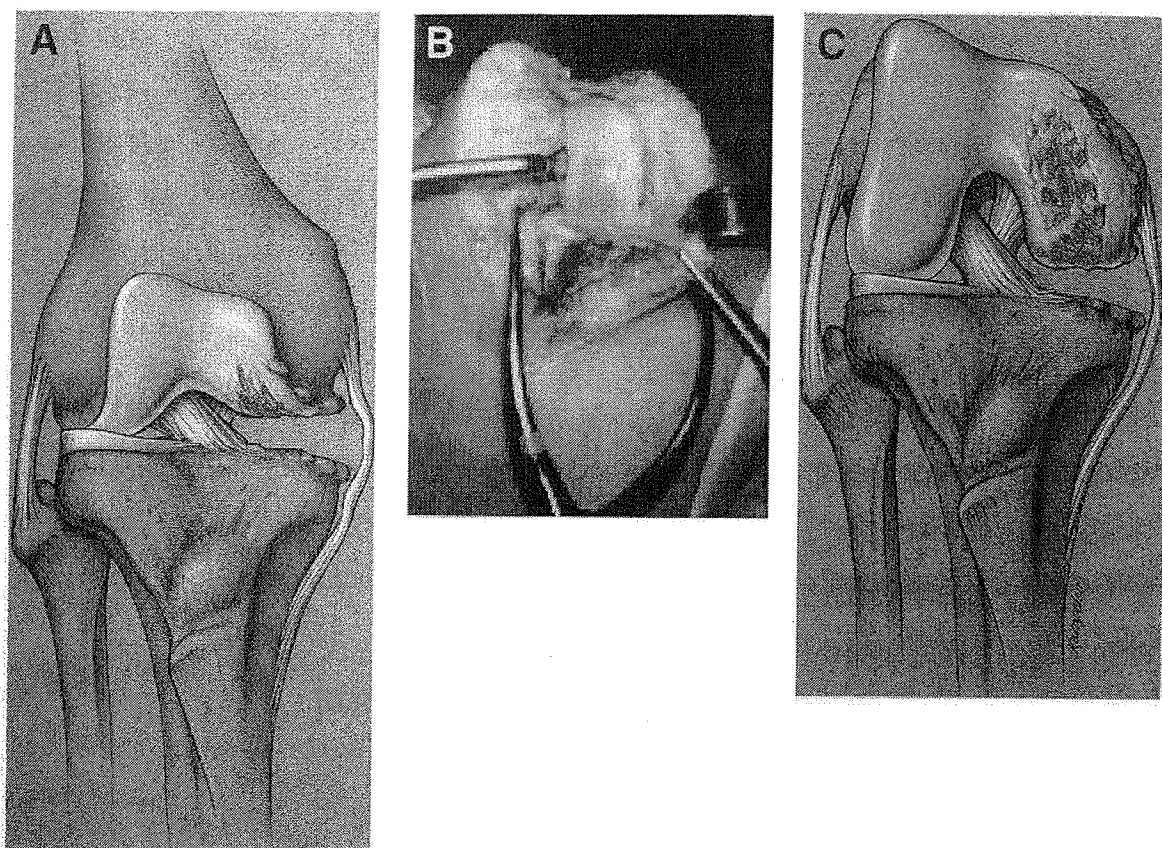


Fig 1. Ideal candidate for UKA. Typical medial compartment arthrosis with correctable deformity and intact ACL (cartilage loss instability). Illustrations (A) in extension and (C) in flexion. (B) Intraoperative view in flexion.

surgeon who believes in the concept of UKA. Both fixed and meniscal-bearing knees present the surgeon with the challenge of proper implantation. Basic surgical principles apply to all design systems but variations exist.

More precise instrumentation and improved prosthetic design have enhanced the surgeon's ability to achieve a better outcome. The initial technique was principally an "eyeballing," which has proven to be less than satisfactory and is reflected in literature reports.¹² Surgical technique and principles of accurate surgical alignment in UKA are important factors that are basic to satisfactory outcomes. The technique of UKA is more challenging, and experience with operative techniques is frequently limited in residencies and/or fellowships. This paper addresses the technical aspects of surgery required to achieve reproducible alignment while avoiding the multiple pitfalls inherent in the procedure.

SURGICAL APPROACH

Medial UKA

A midline anterior skin incision is preferred. The incision is angled distally to the medial side of the tibial tubercle. Minimal undermining is required. The arthrotomy incision can be performed through the standard parapatellar, subvastus, or the midvastus variation, which is the current approach of choice. The midvastus approach, popularized by Engh et al,¹³ splits the medial quadriceps and capsule

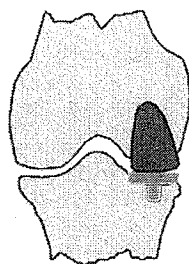
from the anteromedial attachment of the patella proximally along a natural cleavage plane. The distal retinaculum (with the vastus medialis obliquus) is grasped with a tenaculum and turned down, exposing the medial condyle. A limited medial sleeve release of the upper tibia enhances the exposure. The status of the lateral and patellar femoral compartments can be assessed without everting the patella. Patella eversion and extensive exposure are not required in UKA. However, if the surgeon is more comfortable with a more extensive exposure, it is easily accomplished with the midvastus approach. The advantages of patella translocation include minimizing the external tibial rotation and protecting the normal articular cartilage. Maintaining the bulk of the medial quadriceps to the central tendon allows for better patella control intraoperatively, less postoperative pain, and more rapid rehabilitation.

Lateral UKA

Lateral compartment replacement for valgus instability is best performed through the direct lateral approach,¹⁴⁻¹⁶ which accomplishes the lateral release with the exposure. The skin incision is proximal midline ending distally at a point between Gerdy's tubercle and the tibial tubercle. The arthrotomy incision splits the retinaculum (superficial layer) at the medial border of Gerdy's tubercle and extends proximally, 1 to 2 cm lateral to the patella. The deep capsular layer is released from the patellar rim. The

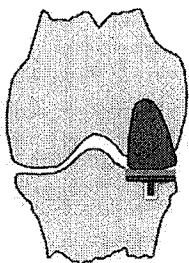
A Fixed Bearing

Tibia
All-Poly



Cement

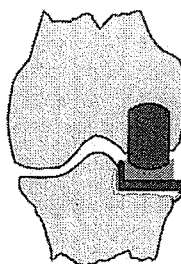
Tibia
Metal-Backed



Cement
or
Cementless

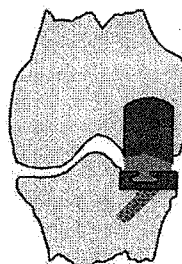
B Meniscal Bearing

Oxford



Cement

LCS



Cement
or
Cementless

Fig 2. UKA prototypes. (A) Fixed-bearing design, all polyethylene and metal-backed tibia, cemented or cementless. (B) Meniscal bearing design, Oxford (cemented) and LCS (cemented or cementless).

proximal arthrotomy can be completed by splitting the vastus lateralis or a limited lateral parapatellar incision made obliquely through the central tendon. The iliotibial band is released in sleeve fashion from the upper tibia (as required) to enhance exposure of the posterolateral corner. Closure in flexion allows for precise soft-tissue adjustment of the prepared layers.

The direct lateral approach allows for direct soft tissue release, adequate exposure without everting the patella, improved patellofemoral tracking, minimal soft tissue trauma, and rapid rehabilitation. The approach can be extended if TKA is required. The standard medial approach can be used but has many disadvantages in lateral UKA, including (1) a required extensive approach; (2) accentuated external tibial rotation, which may influence technique and instrumentation; (3) limited component visualization during trial reduction; and (4) less than optimal patella tracking, necessitating a lateral release.

BONE RESECTIONS

Position and Orientation Variables

Effective instrumentation should reliably establish the correct size, position, and orientation of the femoral and tibial components. The variables of axial rotation, varus-valgus tilt, flexion-extension orientation, anteroposterior (AP) position, and joint line level must be correctly defined by the surgeon by using instruments designed for these purposes. Proper flexion-extension gap balancing should allow for unimpeded motion with normal kinematic control. Bone resections are the key element in preparing implantation surfaces and dictate final positioning. The potential for malresection exists on both femoral and tibial sides (Fig 3) and will be described later in more detail.

Errors are compounded if instrument malposition (malresection) is made on both sides and are more common with anatomic variations, such as flared femoral condyles, which may be a contradiction to UKA.

Tibial first or femoral first approaches can be used, depending on the UKA system^{17,18} and instrumentation philosophy/rationale. Most implantation systems, however, have similar guidelines, including (1) referencing off the subchondral bone, which is more consistent, or a fixed point such as the ACL insertion; (2) correct tibial rotation to reproduce a perpendicular mediolateral plane with a 7° to 10° posterior slope; (3) extramedullary instrumentation for the tibial resection; and (4) mating the femoral resection to the tibial resection plane with appropriate resection blocks. Femoral orientation can include either extramedullary or intramedullary instrumentation. An intramedullary system requires a more extensive approach and violation of the femoral canal, both potential disadvantages.

The principles of bone resection are similar for fixed and mobile bearing systems. The following description is for the LCS mobile bearing UKA system, which I have used for the past 17 years. The approach is tibia first. Illustrations are for a medial compartment replacement (left), because medial compartment replacement represents 90% to 95% of UKAs.

Bone Surface Preparation

Exposure of the tibial plateau is enhanced by a sleeve elevation that is adequate enough to allow for exposure and removal of peripheral osteophytes to normal anatomy. Preservation of the outer meniscal rim is recommended to maintain the integrity of the medial sleeve, preserve optimal stability, and avoid geniculate vessels.

Tibial and femoral osteophytes are best removed with a

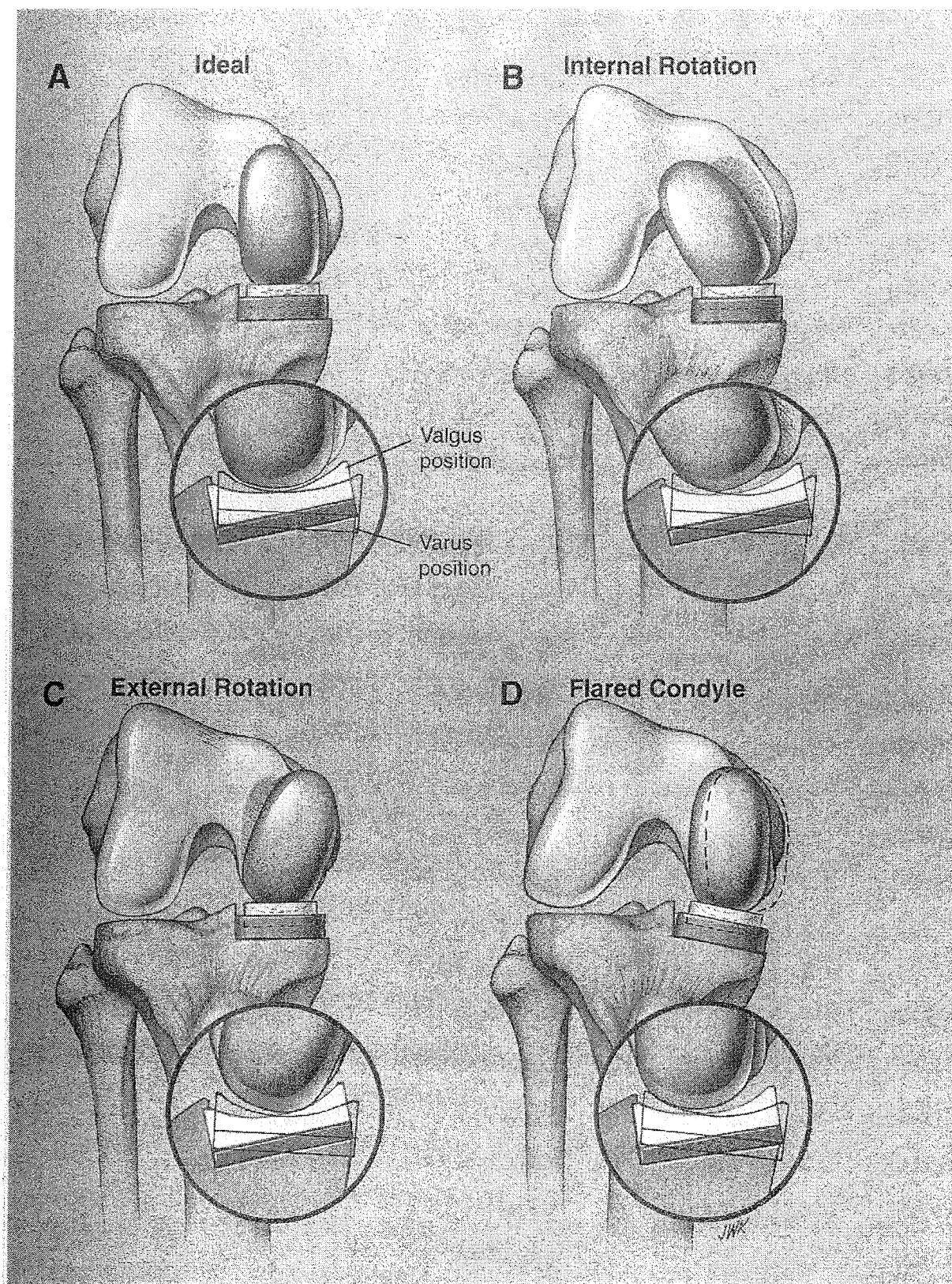


Fig 3. Bone resection (prosthetic position) variables in flexion. Malresections are compounded if AP or sagittal plane rotation cuts are less than ideal, if femoral geometry is atypical (ie, flared), or gaps unequal. (A) Ideal; (B) internal rotation of the femoral component; (C) external rotation of the femoral component; and (D) flared condyle with component position variables. Circular insets illustrate tibial varus-valgus malposition.

reciprocating saw and/or rongeurs to reestablish premorbid anatomy. External tibial rotation will improve access to the posterior corner. Loose bodies or remaining posterior osteophytes are removed. Anatomic variants, pathological erosions, the tibial slope, and bone quality are assessed. Articular (cartilage and bone) high points or irregularities should be removed to subchondral bone because referencing is more accurate and the bone surfaces are more accessible for instrumentation.

THE TIBIAL "L" RESECTION

General Principles

Accuracy of the tibial resection is critical and is determined by proper instrument positioning for variables of rotation (coronal plane), varus-valgus tilt, flexion extension (AP slope), horizontal limit (sizing), and depth of resection. Rotational orientation influences varus-valgus and the AP positions (posterior slope) and therefore should be established first. Malposition of the rotational setting can lead to subtle or obvious changes in the varus-valgus and AP slope cuts, which may lead to less than ideal resections. Malresections will result in higher contact stress at the articulating surface and increased torque forces at the bone (cement) prosthetic interface, especially in fixed bearings with round-on-flat or dished geometries.

Tibial Resection Guide Positioning

Extramedullary guide systems are the norm because ACL preservation is a requirement for UKA. Standard TKA alignment systems can be used, but extensive exposure is required. Lower profile UKA tibial resection guides, as used in the LCS system, allow for instrumentation with more limited compartment exposure as recommended. The resection guide should allow for small adjustments of the alignment rod to fine tune rotation and the varus-valgus and AP positions. The guide should allow for an adjustable resection block to accommodate the depth of resection changes (Fig 4).

Rotation Alignment

The sagittal plane of the "L" resection dictates the rotational orientation of the tibial component; therefore, this setting is primary. The alignment rod (with resection block) is fixed to the tibial spine proximally and to the ankle positioning clamp distally. The rod is set over the tibial crest or proximally at the medial border of the tibial tubercle, which are the most consistent rotational landmarks. More medial rod alignment will result in an internally rotated tibial component, whereas more lateral rod alignment will result in an externally rotated component. Both errors will result in rotational malalignment that will be accentuated with the knee in extension.

Varus-Valgus Alignment

The mediolateral resection should be made perpendicular to the anatomic (mechanical) axis of the tibia. The alignment rod is best referenced distally (ankle level) to the tibialis anterior tendon. The lateral border of the tibialis

anterior tendon is easily palpable and centers over the midpoint of the talus. This point is slightly medial to the midpoint of the malleus and centers over the second metatarsal when the foot is normal. Medial rod placement will result in a valgus position, and lateral rod placement, which is more common, will result in a varus position. An ideal (perpendicular) resection is critical, therefore the alignment rod should be rechecked before final resection.

Flexion-Extension (AP) Alignment

Reproducing the patient's normal posterior slope (5° to 10°) is the goal and is important for restoration of normal kinematics of the ACL/posterior cruciate ligament (PCL) and the so-called four-bar linkage. Alignment systems should allow for AP adjustment. The LCS resection block is set for a 7° posterior resection when the alignment rod is parallel to the tibial crest and/or fibular shaft as viewed from the lateral side. Anterior placement of the rod will increase the posterior slope whereas posterior rod alignment will decrease the posterior slope. Some "eyeballing" may be required if external landmarks are obscured. Remember that a neutral or decreased posterior slope will limit rollback and flexion, increase contact stress on the posterior bearing surface, increase polyethylene wear, and increase the potential for prosthetic lift off and prosthetic fixation failure.

Depth of Resection

The depth of resection is best determined after having confirmed the other variables. The goal is to resect enough bone to allow space for the "total tibial prosthetic thickness" without elevating the joint line (femoral-tibial articulating surface). The most consistent landmarks for establishing the proper depth of resection are the ACL insertion and the upper slope of the tibial spine. The final joint line (articulating interface) should be located at this level to allow for optimal kinematics. The tibial resection block is adjusted to a level that accommodates the prosthetic space requirement. The level is estimated with a stylus or, preferably, an accurately sized tibial drill guide/template (Fig 5). The minimal resection approach is frequently recommended and has resulted in failures secondary to overcorrection, joint line elevation, increased polyethylene wear, fixation, patella impingement, etc, and should be avoided. The space is more finite in UKA (ACL-PCL controlled) and relates most critically to the normal opposite compartment.

The "L" resection is completed after all of the variables have been checked and fine tuned. Minor malalignments can be acceptable, especially in round-on-flat, fixed-bearing systems that usually "trough out" the polyethylene along the rotational arc (from flexion to extension) over time.^{17,18} Final selection of the tibial component size is determined after the "L" resection. Optimal peripheral bony rim contact should be obtained with abutment of the sagittal tibial surface against the vertical arm of the "L" resection (Fig 6). Minor adjustments can be made if the depth of resection changes. The ACL insertion must be preserved and the final tibial articulating surface adjusted

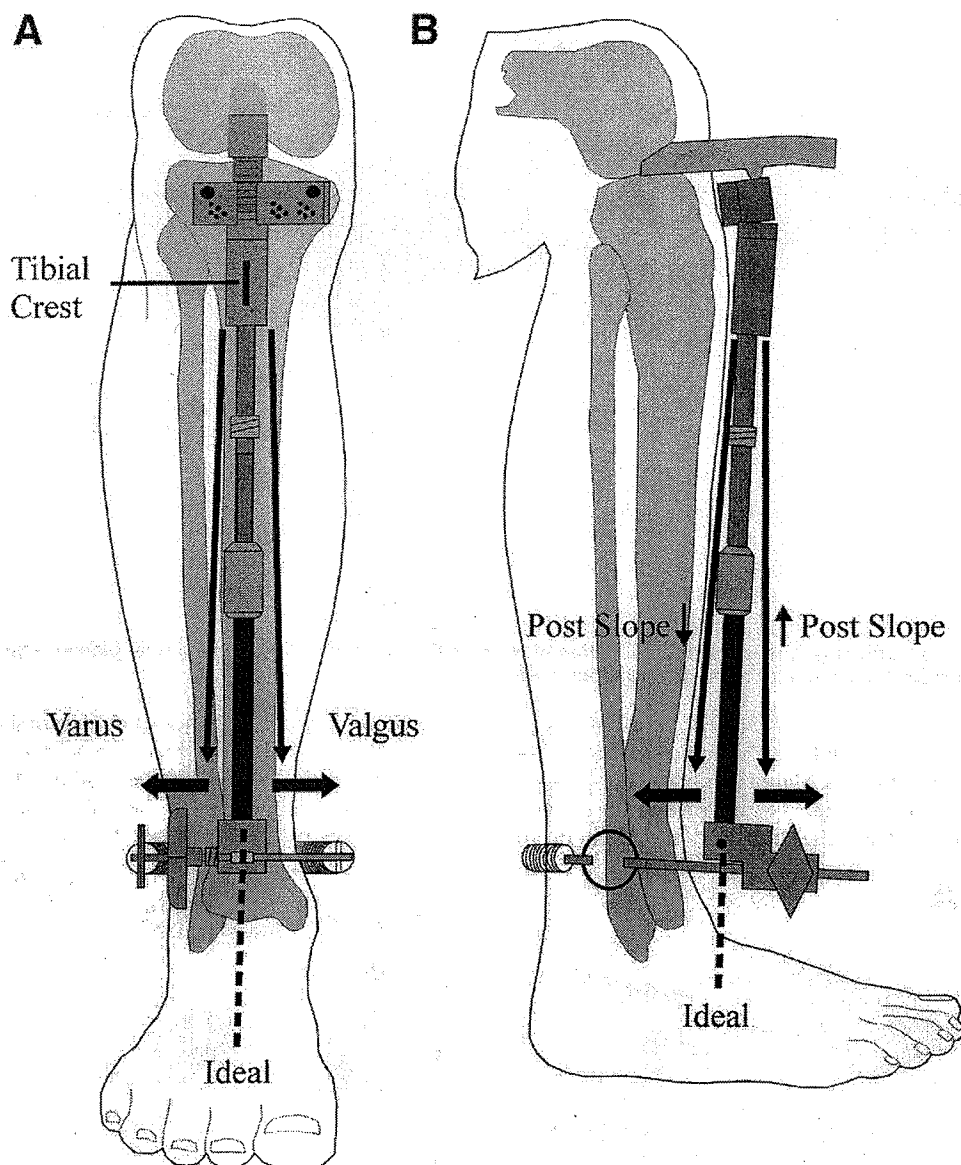


Fig 4. (A) Front and (B) side views of tibial plateau instrumentation; setting the tibial resection guide (block).

to the original tibial plateau surface. The spacer block of appropriate size and depth is inserted to check all tibial resection variables. A drop rod attached to the guide rechecks the varus-valgus and the AP slope (Fig 7). Ranging the knee from 90° to full extension rechecks the level and orientation of the tibial resection and maps the rotational tracking to the femoral surface before instrumentation of the femoral side. The tibial resection should be rechecked when the femoral resections are referenced from the tibia, and vice versa if a femoral first approach is used.

FEMORAL PREPARATION AND SIZE SELECTION

The femoral condyle is frequently irregular with bony and/or articular cartilage high spots. Referencing from the subchondral bone is more consistent and is recommended

with use of most instrument systems, whether a femoral first or tibial first approach is used. If not performed previously, removal of high spots, including the posterior femoral condyle, is now accomplished with use of an oscillating saw. Flattening of the subchondral surface allows for better seating of alignment shells or cutting jigs.

Femoral size selection, which best approximates the existing bony geometry, is initially estimated by use of an AP template and mediolateral sizing shells (Fig 8). The profile of each template and shell matches the geometry of the corresponding implant. It is important to keep in mind that it is the shape of the subchondral bone and not the articular cartilage which is to be reestablished. Rotational (coronal and sagittal) planes are checked. Care must be taken to avoid overcorrection and oversizing, which increases the risk of soft tissue and/or patella impingement. The medial and lateral prosthetic borders should lie within

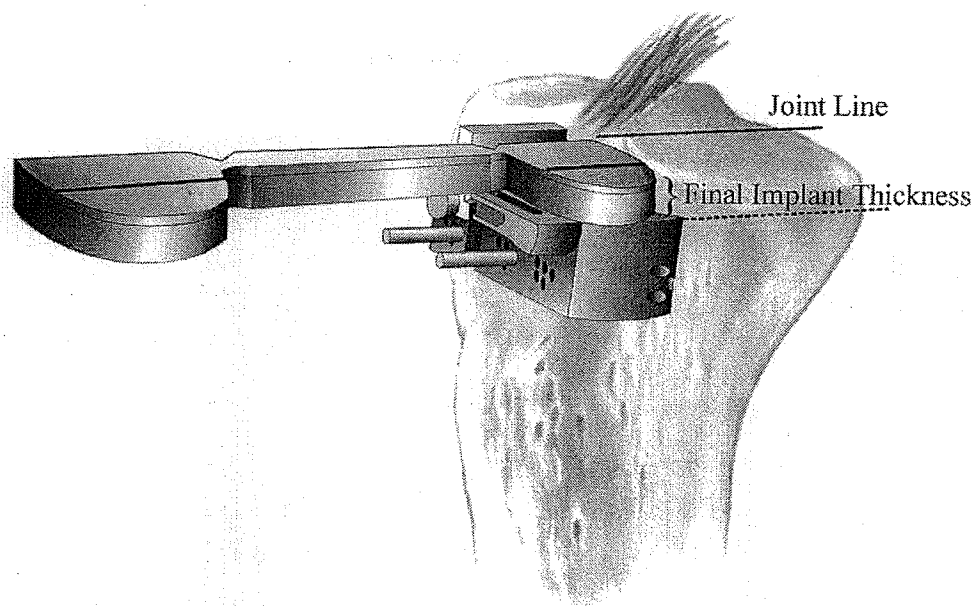


Fig 5. Final tibial positioning. The adjustable resection block sets the depth and AP and rotational planes. The ACL insertion approximates the joint line and is a consistent reference point.

the femoral condyles. The most superior medial edge is often flush with the condyle in the typical medial UKA. Overhang must be avoided. Flared condyles may present a problem. The anterior edge of the prosthesis must be placed at a point between the eburnated arthritic bone and

the normal articular cartilage of the femoral trochlea. This point can be marked with the knee held in full extension. Sizing shells, templates, and the final prosthesis must not encroach beyond this point because patellofemoral impingement may occur. Checking the position from flexion

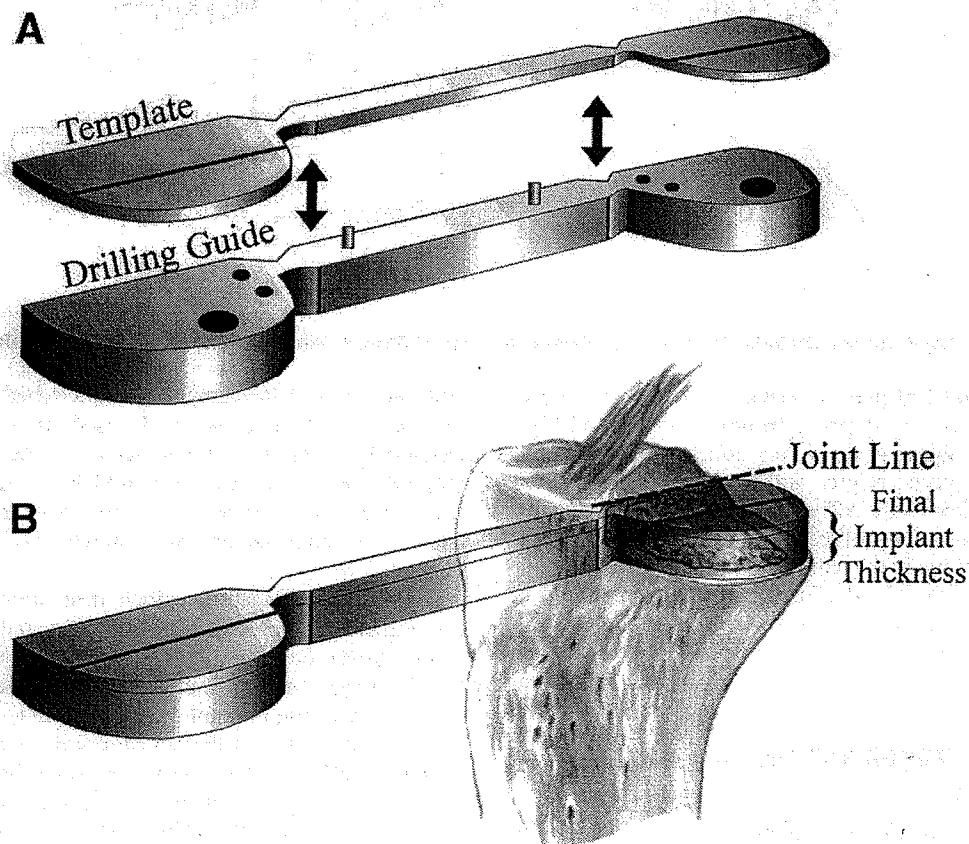
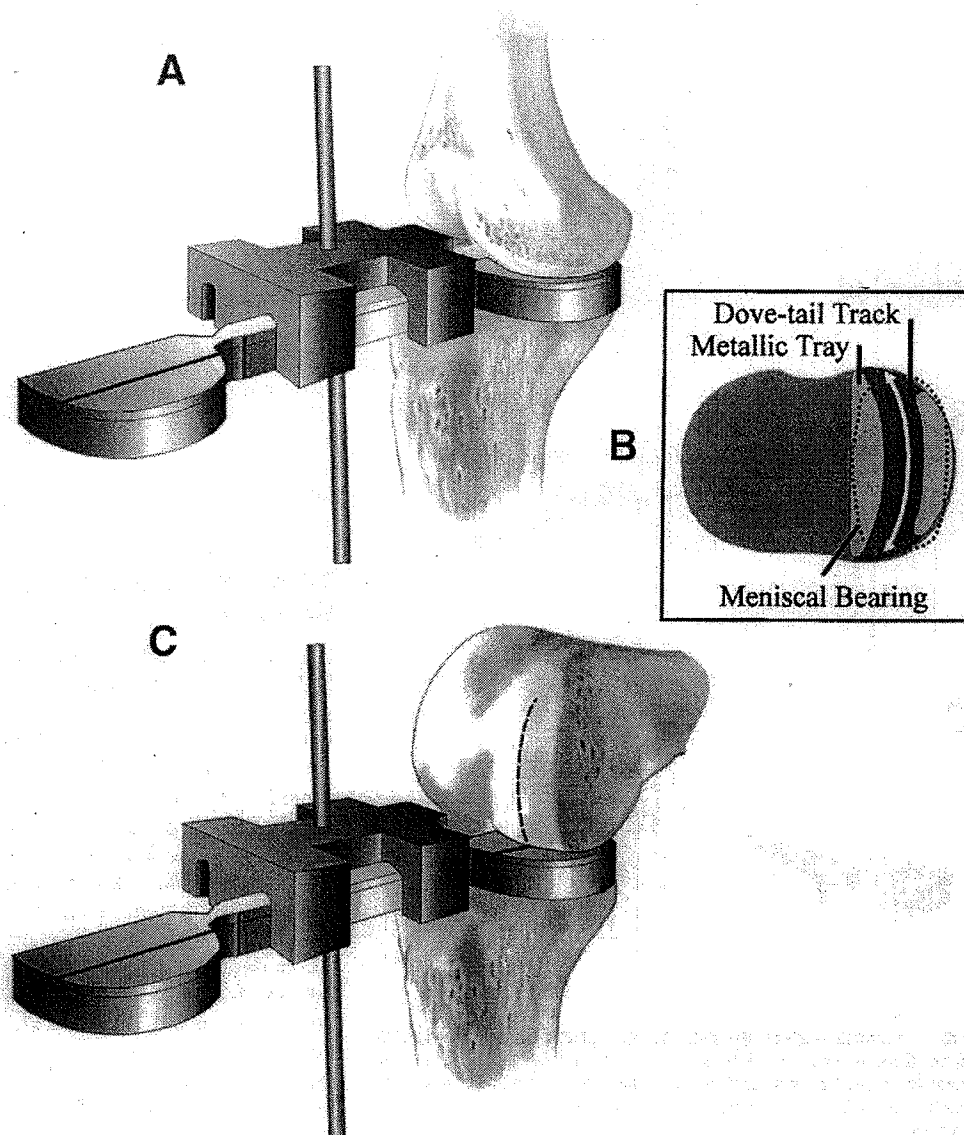


Fig 6. Completed tibial "L" resection. (A) Template/drill guide confirms positions and (B) joint line level.

Fig 7. After selection of tibia size and thickness, varus, valgus, and AP tibial slope are checked by using a drop rod in (A) extension and (C) flexion. Rotational mapping of the tibial trial spacer to the femoral condyle from (C) flexion to (A) extension, with patella reduced, (B) will confirm the proper orientation and tracking of the femoral component to the tibial bearing.



to extension will minimize the potential for anterior impingement problems.

FLEXION-EXTENSION GAP BALANCING

The AP femoral position (resection) dictates the flexion gap, and the distal position dictates the extension gap (Fig 9). Condylar resections (thickness) must accommodate the prosthetic mass. Checking the flexion and extension gap with a shell positioner assures that the proper amount of bone is resected. If the flexion gap is tight, the sizing template can be moved anteriorly to, but not beyond, the limiting point described previously. Downsizing the femoral component may be required if the flexion gap is too tight or there is anterior impingement. It is important to recognize this potential error before femoral resection, although it can be corrected after trial component placement. Reattachment of the resection block, however, may be less exact, the recuts may be less precise, and the final fit possibly compromised if previous fixation holes need to be redone.

FEMORAL ROTATION CONSIDERATIONS

The femoral component can be placed correctly, too far medially or laterally, internally or externally rotated (coronal plane), and flexed or extended (sagittal plane). Malrotation will be exacerbated if these resections are additive and/or combined with tibial malpositioning. As previously noted, these potential errors can be recognized by mapping the rotation plane from 90° to 0°. This will avoid the initial malresections as shown in Fig 3. Internal malrotation of the femoral component will result in (1) high-contact stress on the more central articulation, (2) increased torque on the prosthetic component, (3) flexion gap instability, and (4) rotational incongruence in extension. External malrotation will result in (1) high-contact stress on the peripheral articulating surface, (2) increased torque, (3) flexion gap instability, and (4) increased potential for soft-tissue impingement caused by proximal overhang of the prosthesis. Flexion positioning of the femoral component will result in bearing impingement anteriorly in extension. Conversely, extension positioning of the femoral

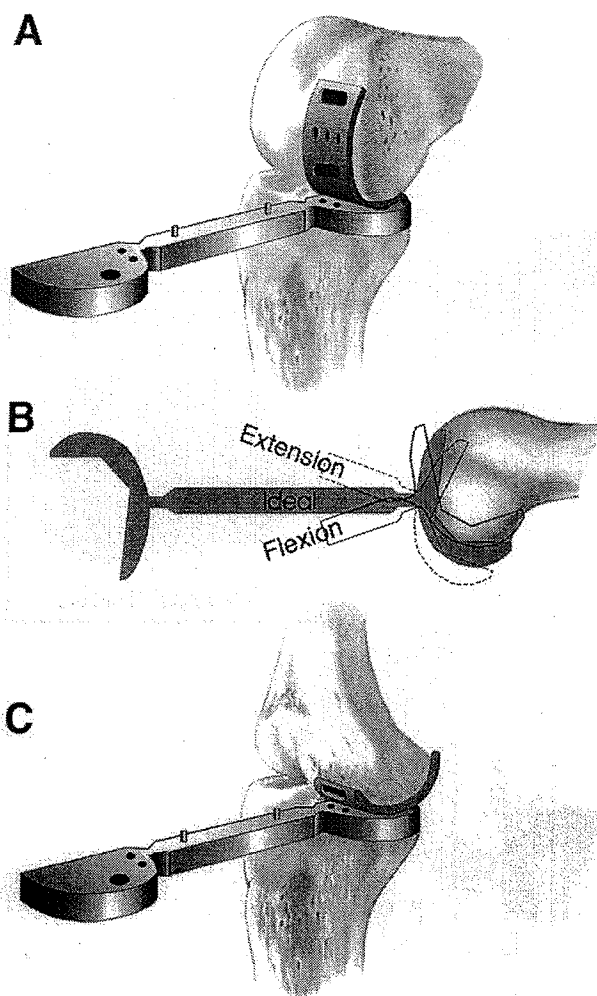


Fig 8. Femoral size is selected by using the appropriate dimension determined by the (A) ML and (B) AP position. The patella must be reduced before rotation check. Component positioning is reconfirmed by (A) taking the knee to (C) full extension.

component will result in bearing impingement posteriorly in flexion. Lateral (central) positioning will result in impingement on the tibial spine, whereas medial (peripheral) component positioning will result in medial tibial component overload. Both will increase the potential for patella and/or medial soft tissue impingement. These malrotations (malresections) may lead to increased wear and loosening, the primary cause of failure in UKA.

FEMORAL RESECTION

Coronal plane orientation or axial rotation of the femoral component must align to the tibial component in flexion and extension. Proper femoral shell placement correctly orients the femoral resection block and allows for accurate femoral cuts (Fig 10). The resection block should be oriented to the femoral axis and allow for proper flexion-extension position (referencing parallel to the anterior femoral cortex). Care should be taken to set the resection block flush to the subchondral bone. If the block is proud

(setting on high points), the distal resection will be inadequate and/or rotationally malaligned. These malpositions will result in a tight extension gap with overcorrection and overload of the opposite compartment and/or an abnormal articulation at the prosthetic interface. Final positioning of the femoral cutting block must be checked with the patella relocated to avoid malpositioning and malresection. The patella can be dislocated or translocated for improved exposure once the resection block setting has been confirmed. Resections are completed, and a drilling guide is impacted, oriented to the lined tibial template.

Femoral referencing is accomplished with the LCS resection block as an extramedullary approach. Systems that use an intramedullary approach also reference the anatomic femoral axis and the anterior femoral cortex. Both systems work. Understanding the principles is most important because anatomic variances may require fine adjustments, which are more technically subtle with UKA than TKA.

FINAL POSITIONING AND TRIAL REDUCTION

After resections (distal, posterior, and chamfer), a femoral drill guide (Fig 11) is impacted to ensure proper fit. The knee flexion is ranged from 90° flexion to 0° extension, and the final mediolateral and rotational positions are checked. The drill guides are set and fixation drill holes are completed on the femoral and tibial sides (Fig 12A). The trial tibial component should be inserted first, followed by the bearing and the femoral component. Final impaction will position the tibial component against the sagittal resection (Figure 12B). A stemmed unit, such as the LCS, may require rotational maneuvering. External rotation of the tibia will aid in exposure and insertion of the tibial component. The bearing is inserted by placing a valgus stress from flexion to extension and back to extension to clear the femoral condyle. The femoral component is then impacted, beginning at 100° and completed with the knee at 60° to 70° (Figure 12C). The patella is then reduced and the knee ranged from extension to maximum flexion. Normal, natural range of motion with meniscal bearing movement, anterior in extension and posterior in flexion, confirms normal kinematic control. There should be no patella impingement and no component liftoff from either tibial or

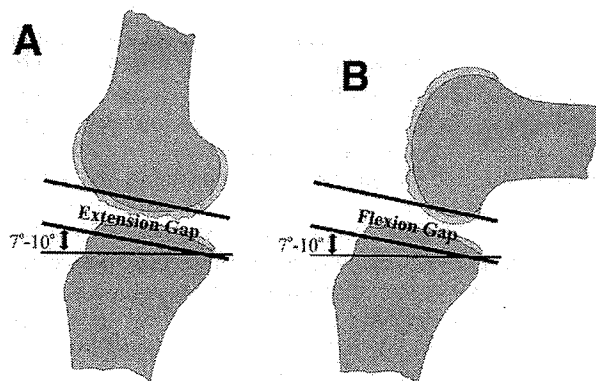
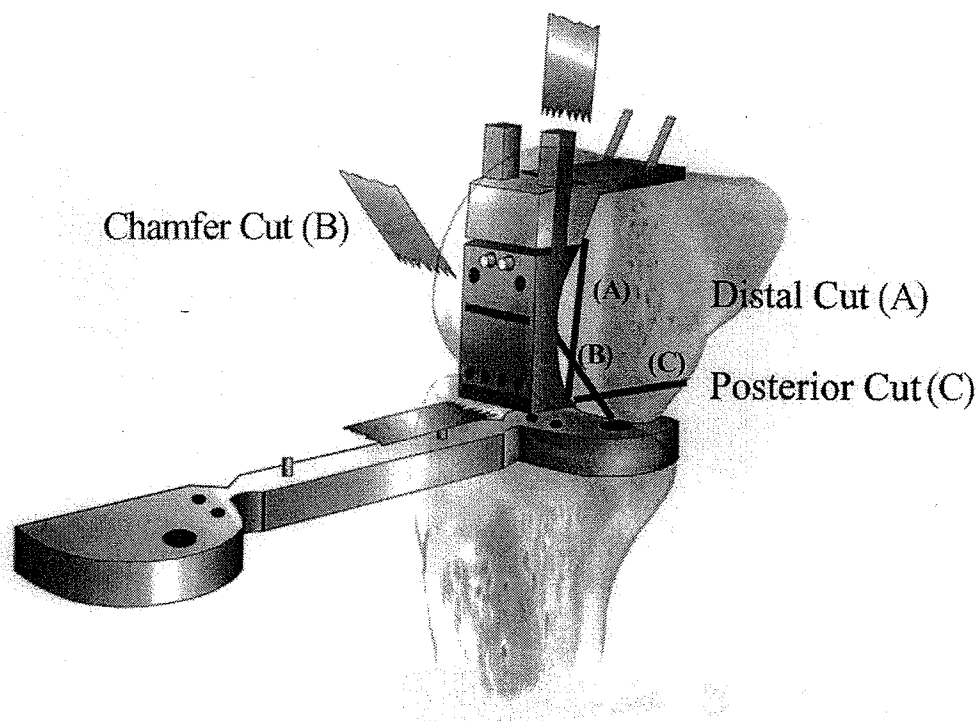


Fig 9. Flexion-extension gaps should be equal and parallel. (A) The distal position dictates the extension gap and (B) the AP femoral position dictates the flexion gap.

Fig 10. Femoral resection block set for (A) distal, (B) chamfer, and (C) posterior cuts with the patella relocated.



femoral sides with extremes of motion. The most common cause of liftoff or a tight flexion block is failure to slope the AP resection 7° to 10° as recommended. Fine tuning of any resection variables should be completed before permanent prosthetic placement.

PERMANENT COMPONENT PLACEMENT/CLOSURE

After trial component removal, final bone bed preparation is completed. If cementless fixation is used, the tourniquet is released. Hard, sclerotic zones should be drilled. Bone paste/slurry collected from drilling and saw cuts is ap-

plied to any tibial and/or femoral surface defects. The surface-coated (porous coat, hydroxyapatite) implants are impacted for an interference fit. If cement fixation is used, bone surfaces are thoroughly cleansed and dried before cementing. The patella is reduced after prosthetic insertion. Mobility and stability are rechecked and soft tissue closure accomplished anatomically, preferably in flexion, which allows optimum range of motion for the soft tissue sleeve. Use of suction drainage is preferred but less critical in UKA because bleeding is minimal. Range of motion from 0° to maximum (normal) flexion is checked after deep retinacular and skin closure. A bulky pressure dressing is applied to allow for early range of motion with or without

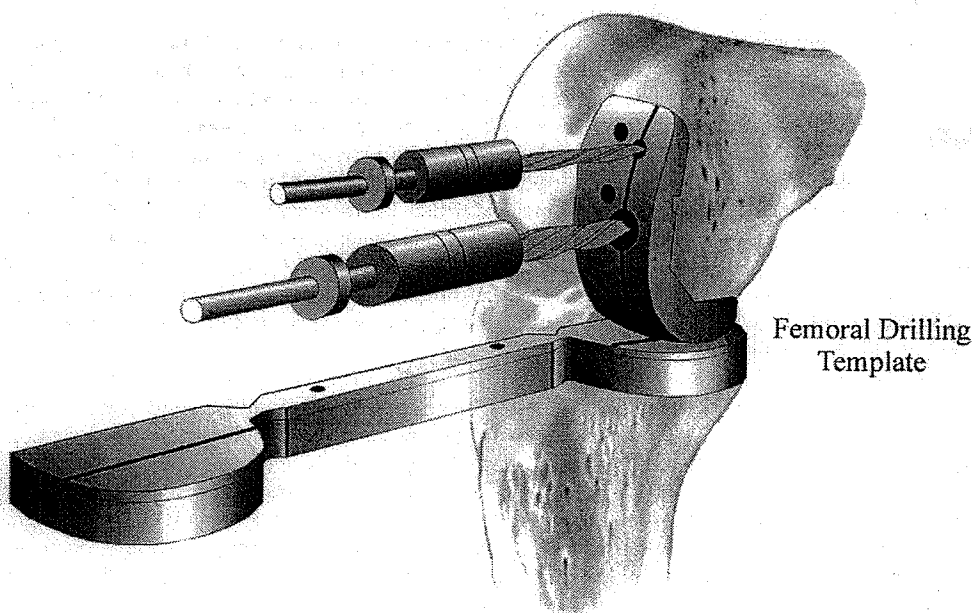


Fig 11. After resection femoral drill guide is impacted. Rotation is checked from 90° to 0° .

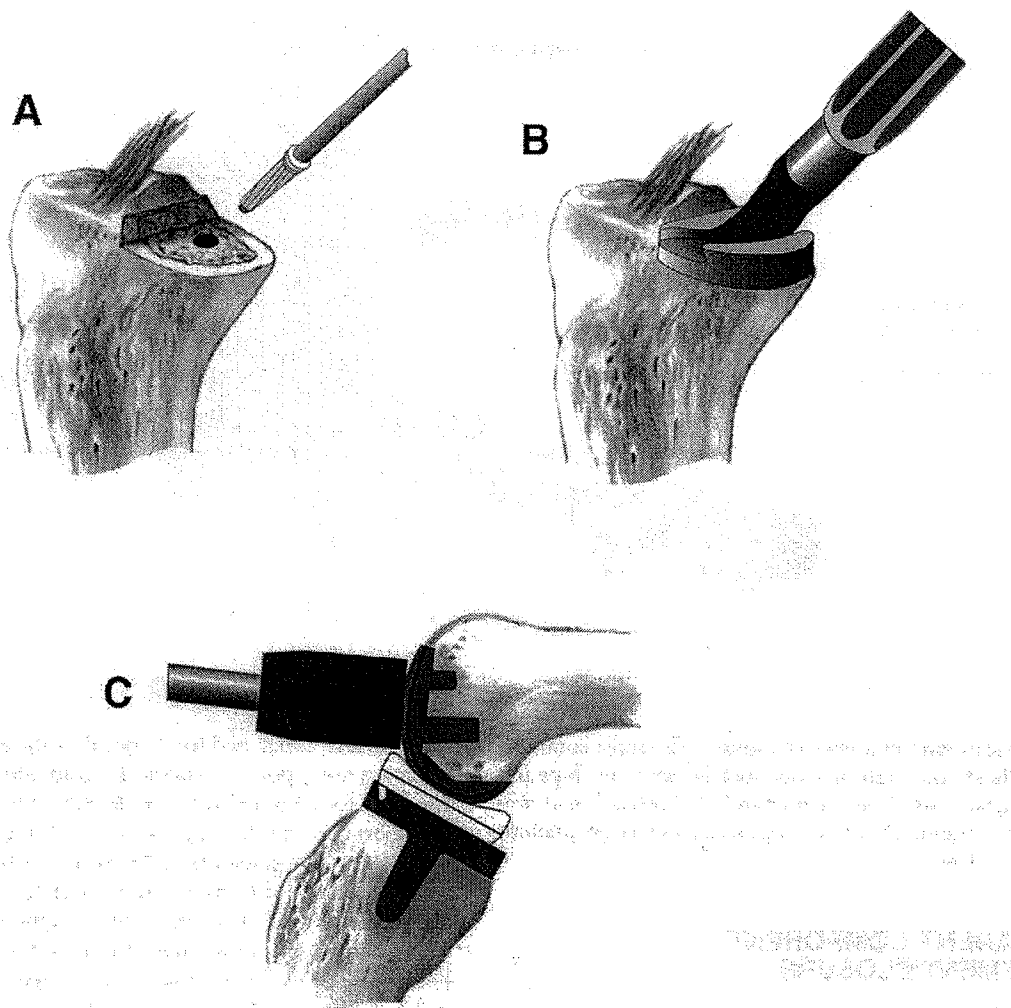


Fig 12. (A) After fixation holes have been drilled, **(B)** tibial trial reduction is completed. **(C)** The tibial bearing is inserted, followed by insertion of the trial femoral component.

continuous passive movement. Ambulation is on the first postoperative day and an expedited routine TKA protocol is followed with usual discharge by postoperative day three.

DISCUSSION/SUMMARY

UKA remains controversial and its application varies from country to country, region to region, and within orthopedic training centers. Literature reports have been variable, ranging from negative studies of Insall and Aglietti,¹² Laskin,¹⁹ and Swank et al,²⁰ to multiple positive studies.^{2-4,21-26} Advocates of UKA cite the multiple advantages which include (1) restoration of normal kinematics; (2) preservation of normal structures; (3) avoidance of major problems reported with TKA; (4) maintaining and/or improving functional range of motion, which is frequently decreased after TKA; (5) lower morbidity with no need for blood transfusions, less soft tissue damage, etc; and (6) lower prosthetic costs and shorter hospitalization. Nonadvocates of UKA cite higher failure rates, problems of selection and technique, and difficulty in revision to TKA. Conversion of UKA, however, is reported to be less

difficult than revision TKA,^{27,28} which is also my personal experience.

All authors agree that patient selection and prosthetic design can influence outcomes. Grelsamer and Cartier²⁹ stressed that UKA is not "half a total knee", with major differences mostly related to technical factors which have been discussed and illustrated. The Swedish knee study^{8,30} reported improved results of a large series of UKAs (1,969 cemented Marmor fixed-bearing UKAs) relative to the time of implant. Five-year cumulative revision rates were reduced from 11% (1975-1983 cases) to 5% (1983-1989 cases), suggesting that experience, patient selection, and surgical techniques are major determinants of clinical results.

Surgical technique of UKA is more demanding but should not be a deterrent to learning and offering this conservative option to patients who meet the selection criteria. A philosophy of the UKA concept, good judgement, and understanding of the surgical principles and instrumentation systems of a proven prosthetic design, along with exacting surgical technique, should decrease failures in UKA that are caused by surgeon-dependent technical factors (Fig 13).

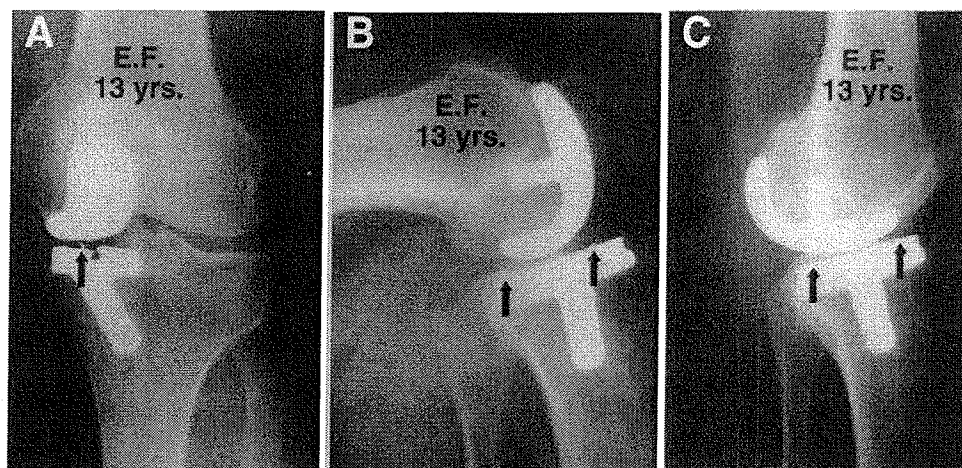


Fig 13. Thirteen-year follow-up of cementless LCS second generation (shorter tibial stem) medial UKA. (A) AP radiographs show maintenance of corrected position and preservation of lateral joint space. (B) Lateral flexion and extension views show meniscal bearing movement posterior in flexion and (C) anterior in extension. Arrows point to anterior and posterior metallic marker wires in polyethylene bearing.

REFERENCES

1. Heck DA, Marmor L, Gibson A, et al: Unicompartmental knee arthroplasty. A multicenter investigation with long-term follow-up evaluation. *Clin Orthop* 286:154-159, 1993
2. Marmor L: Marmor modular knee in unicompartmental disease. Minimum four-year follow-up. *J Bone Joint Surg Am* 61:347-353, 1979
3. Thornhill TS, Scott RD: Unicompartmental total knee arthroplasty. *Orthop Clin North Am* 20:245-256, 1989
4. Van Dalen J, Krause BL: Medial unicompartment knee replacement. Minimum five year follow-up. *Aust N Z J Surg* 61:497-500, 1991
5. Cameron JC, Saha S: Meniscal allograft transplantation for unicompartmental arthritis of the knee. *Clin Orthop* 337:164-171, 1997
6. Hodge WA, Chandler HP: Unicompartmental knee replacement: A comparison of constrained and unconstrained designs. *J Bone Joint Surg Am* 74:877-883, 1992
7. Knight JL, Atwater RD, Guo J: Early failure of the porous coated anatomic cemented unicompartmental knee arthroplasty. Aids to diagnosis and revision. *J Arthroplasty* 12:11-20, 1997
8. Lindstrand A, Stenstrom A, Lewold S: Multicenter study of unicompartmental knee revision. PCA, Marmor, and St Georg compared in 3,777 cases of arthrosis. *Acta Orthop Scand* 63:256-259, 1992
9. Blunn GW, Joshi AB, Lilley PA, et al: Polyethylene wear in unicompartmental knee prostheses. 106 retrieved Marmor, PCA, and St. Georg tibial components compared. *Acta Orthop Scand* 63:247-255, 1992
10. Engh GA, Dwyer KA, Hanes CK: Polyethylene wear of metal-backed tibial components in total and unicompartmental knee prostheses. *J Bone Joint Surg Br* 74:9-17, 1992
11. Lindstrand A, Stenstrom A: Polyethylene wear of the PCA unicompartmental knee. Prospective 5 (4-8) year study of 120 arthrosis knees. *Acta Orthop Scand* 63:260-262, 1992
12. Insall J, Aglietti P: A five to seven-year follow-up of unicompartmental arthroplasty. *J Bone Joint Surg Am* 62:1329-1337, 1980
13. Engh GA, Holt BT, Parks NL: A midvastus muscle-splitting approach for total knee arthroplasty. *J Arthroplasty* 12:322-331, 1997
14. Keblish PA: The lateral approach to the valgus knee. Surgical technique and analysis of 53 cases with over two-year follow-up evaluation. *Clin Orthop* 271:52-62, 1991
15. Insall JN, Scott WN, Keblish PA, et al: Total knee arthroplasty exposures and soft tissue balancing, in Insall JN, Scott WN (eds): *VideoBook of Knee Surgery*. Philadelphia, PA, Lippincott, 1994
16. Keblish PA: Surgical approaches: Lateral approach, in Scuderi GR, Tria AJ (eds): *Surgical Techniques in Total Knee Arthroplasty*. New York, NY, Springer-Verlag (in press)
17. Stulberg SD: Unicompartmental knee replacement. *Techniques in Orthopaedics* 5:1-74, 1990
18. Cartier P, Epinette JA, Deschamps G, et al (eds): *Unicompartmental Knee Arthroplasty*. Paris, France, Expansion Scientifique Française, 1997
19. Laskin RS: Modular total knee replacement arthroplasty. A review of eighty-nine patients. *J Bone Joint Surg Am* 58:766-773, 1976
20. Swank M, Stulberg SD, Jiganti J, et al: The natural history of unicompartmental arthroplasty. An eight-year follow-up study with survivorship analysis. *Clin Orthop* 286:130-142, 1993
21. Cohen M, Buechel F, Pappas MJ: Meniscal-bearing unicompartmental knee arthroplasty. An 11-year clinical study. *Orthop Rev* 20:443-448, 1991
22. Goodfellow JW, O'Connor J: Clinical results of the Oxford Knee. Surface arthroplasty of the tibiofemoral joint with a meniscal bearing prosthesis. *Clin Orthop* 205:21-42, 1986
23. Keblish PA: The case for unicompartmental knee arthroplasty. *Orthopedics* 17:853-855, 1994
24. Cartier P, Sanouiller JL, Grelsamer RP: Unicompartmental knee arthroplasty surgery. 10-year minimum follow-up period. *J Arthroplasty* 11:782-788, 1996
25. Sisto DJ, Blazina ME, Heskiaoff D, et al: Unicompartment arthroplasty for osteoarthritis of the knee. *Clin Orthop* 286:149-153, 1993
26. Kozinn SC, Marx C, Scott RD: Unicompartmental knee arthroplasty: A 4.5-6-year follow-up study with a metal-backed tibial component. *J Arthroplasty* 4:S1-S10, 1989 (suppl)
27. Levine WN, Ozuna RM, Scott RD, et al: Conversion of failed modern unicompartmental arthroplasty to total knee arthroplasty. *J Arthroplasty* 11:797-801, 1996
28. Otte KS, Larsen H, Jensen TT, et al: Cementless AGC revision of unicompartmental knee arthroplasty. *J Arthroplasty* 12:55-59, 1997
29. Grelsamer RP, Cartier P: A unicompartmental knee replacement is not "half a total knee": Five major differences. *Orthop Rev* 21:1350-1356, 1992
30. Lewold S, Knutson K, Lidgren L: Reduced failure rate in knee prosthetic surgery with improved implantation technique. *Clin Orthop* 287:94-97, 1993