


DOW CORNING WRIGHT

R
**LACEY
CONDYLAR
TOTAL KNEE
SYSTEM**



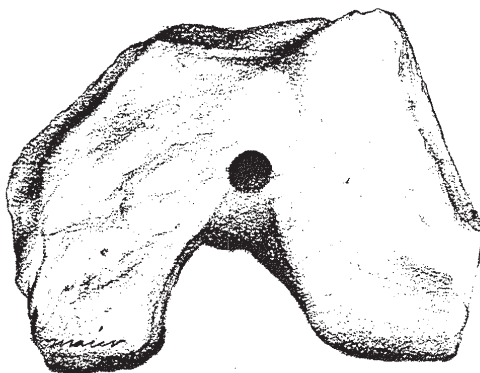
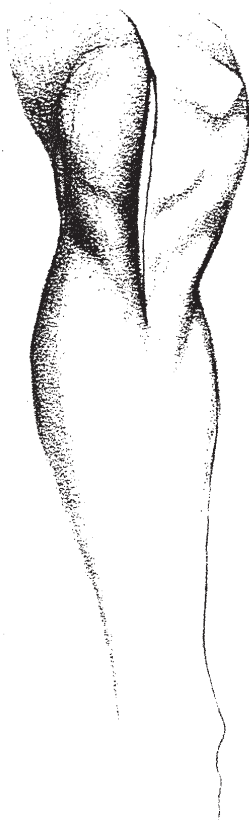
SURGICAL PROCEDURE



LACEY CONDYLAR TOTAL KNEE SURGICAL PROCEDURE

1. The extremity is prepped and draped in the usual manner. An anterior 5-6 inch midline incision is made with the knee flexed to 90 degrees. The knee is then placed in extension and dissection carried out in line with the skin incision down through the medial retinaculum. Subperiosteal flaps are developed medially and laterally about the metaphyseal flares. The patella is reflected laterally and the knee flexed to 90 degrees. The anterior portion of the menisci are excised and the anterior cruciate ligament incised.

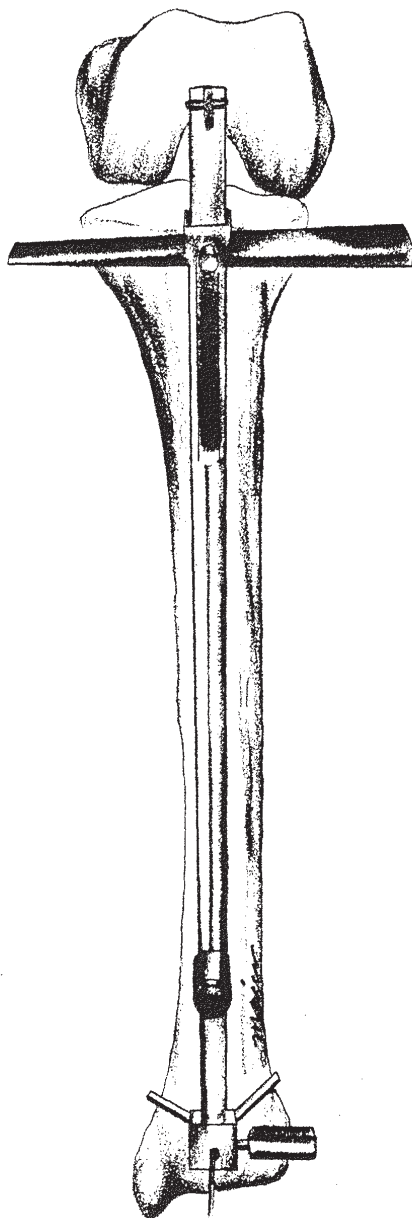
2. A drill hole is placed in the intercondylar region of the femur just above the interspinous eminence of the tibia. This is to anchor the proximal end of the tibial guide centered at the mid portion of the tibia.



DOW CORNING
DOW CORNING
WRIGHT

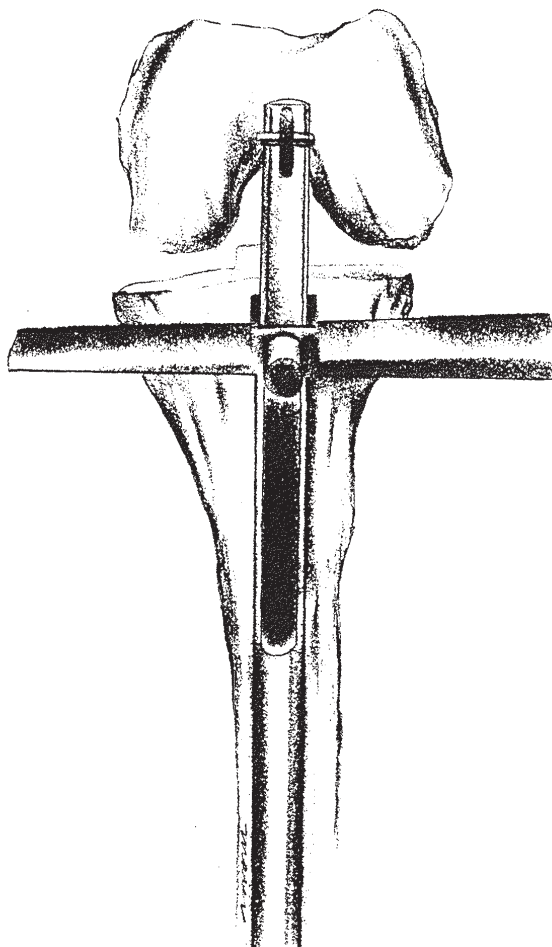
©DOW CORNING WRIGHT

Developed by:
J. Allen Lacey, M.D.
Jewett Orthopaedic Clinic
Winter Park, Florida

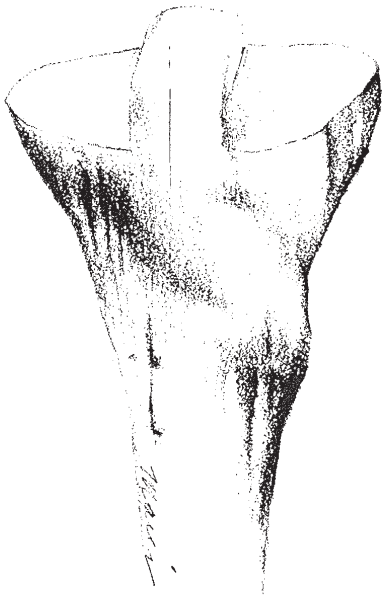


3. The tibial guide may be set at zero or three degrees of varus. The knee is placed at 80 to 90 degrees of flexion and the distal portion of the tibial guide centered with the "Y" portion placed just proximal to the malleoli. The set screws are secured. Visually the amount of tibial plateau to be removed is located with the transverse portion of the guide and the set screw secured. It is important at this point to maintain the degree of flexion of the knee or the depth of cut may change.

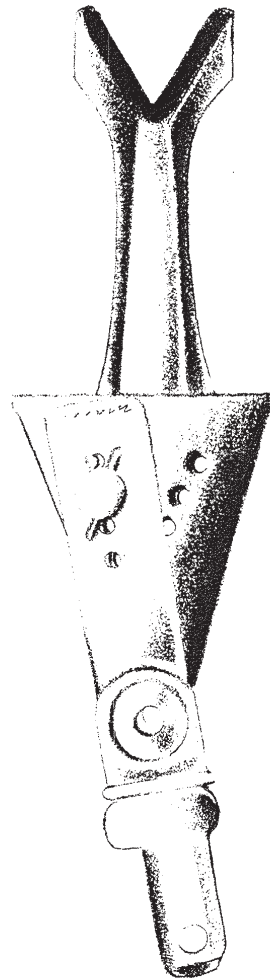
4. The tibial plateaus are osteotomized placing the oscillating saw flush against the transverse portion of the guide. The tibial cutting guide is removed. The osteotomies through the tibial plateaus are completed.



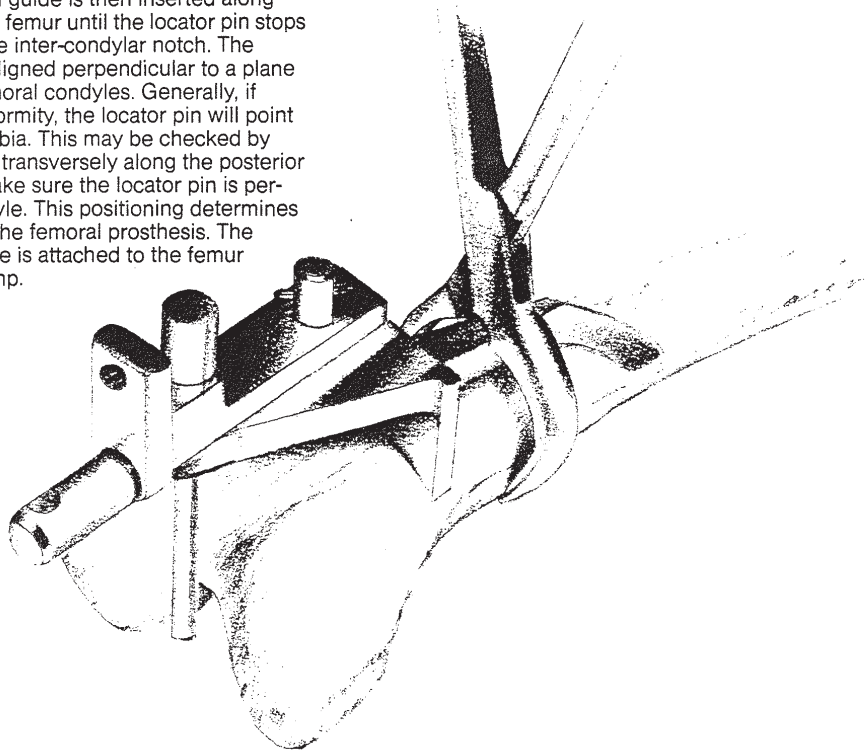
5. Two vertical cuts are made just medially and laterally to the interspinous eminence to protect the posterior cruciate ligament.



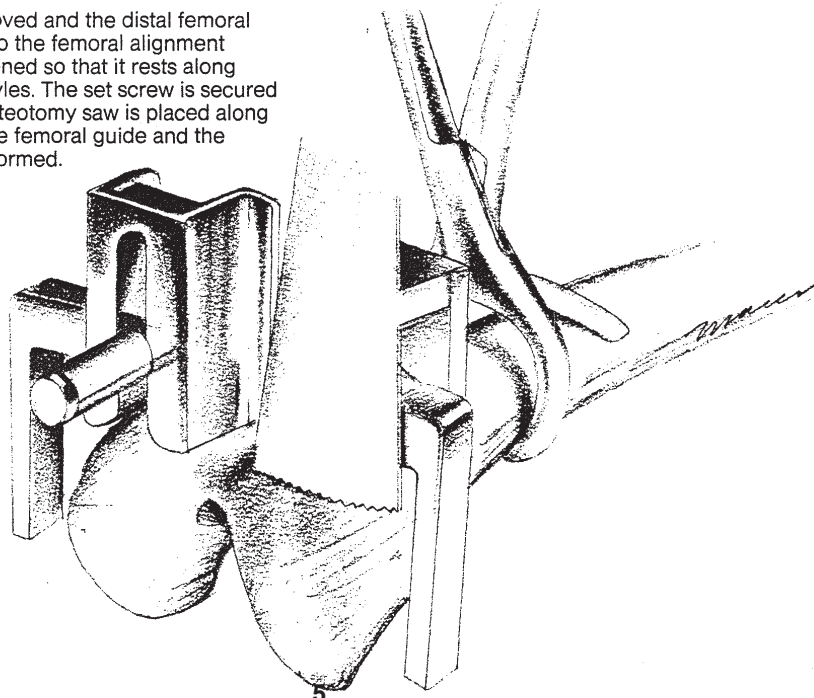
6. The knee is placed in extension and a "T" incision made in the synovial recess off the anterior femur. A plane is developed between the soft areolar tissue and the periosteum. Care should be taken not to strip the periosteum from the anterior portion of the femur. The desired amount of valgus is selected in the femoral guide. This can be either 5, 7, 9 or 11 degrees. Generally 9 degree is used. This guide may be used on either the right or left femur.



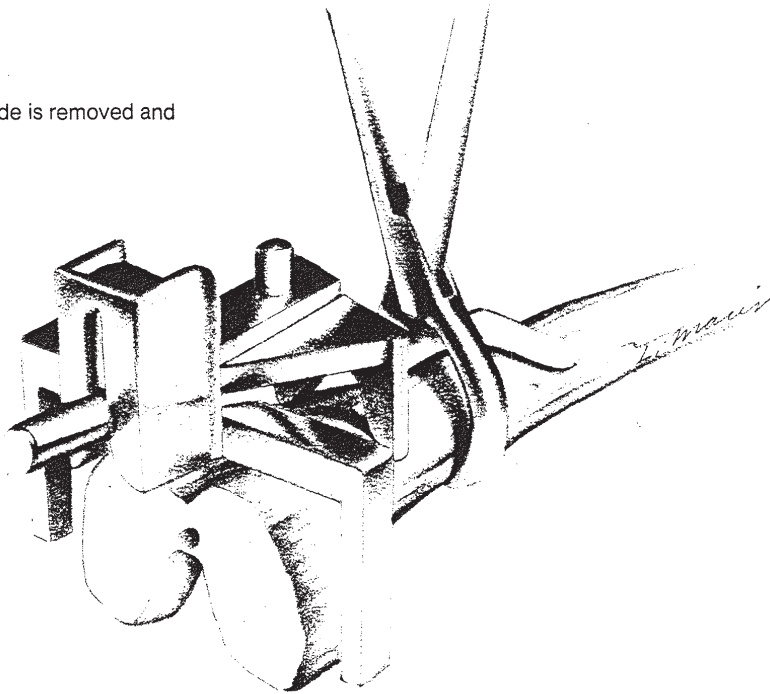
7. The locator pin is inserted into the distal end of the femoral alignment guide which determines the correct amount of bone removed with the transverse valgus cut. The femoral guide is then inserted along the anterior shaft of the femur until the locator pin stops the femoral guide in the inter-condylar notch. The locator pin should be aligned perpendicular to a plane along the posterior femoral condyles. Generally, if there is no angular deformity, the locator pin will point down the shaft of the tibia. This may be checked by placing a straight edge transversely along the posterior femoral condyles to make sure the locator pin is perpendicular to the condyle. This positioning determines the correct rotation of the femoral prosthesis. The femoral alignment guide is attached to the femur with the alignment clamp.



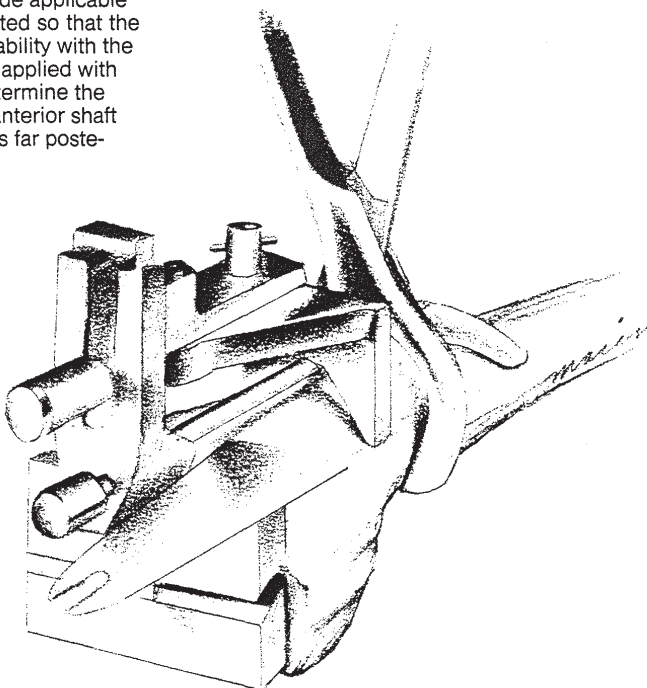
8. The locator pin is removed and the distal femoral cutting guide is attached to the femoral alignment guide. The guide is positioned so that it rests along the anterior femoral condyles. The set screw is secured with the locator pin. An osteotomy saw is placed along the superior margins of the femoral guide and the transverse cut is now performed.



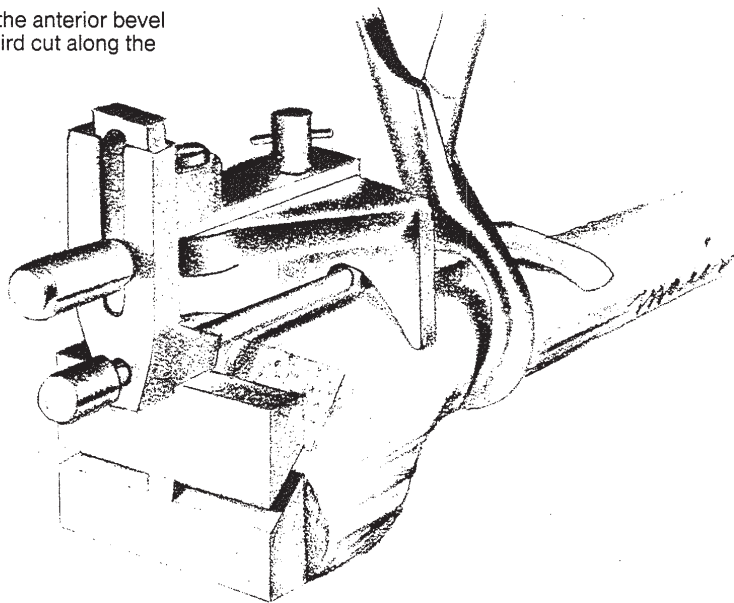
9. The distal femoral cutting guide is removed and the osteotomy is completed.



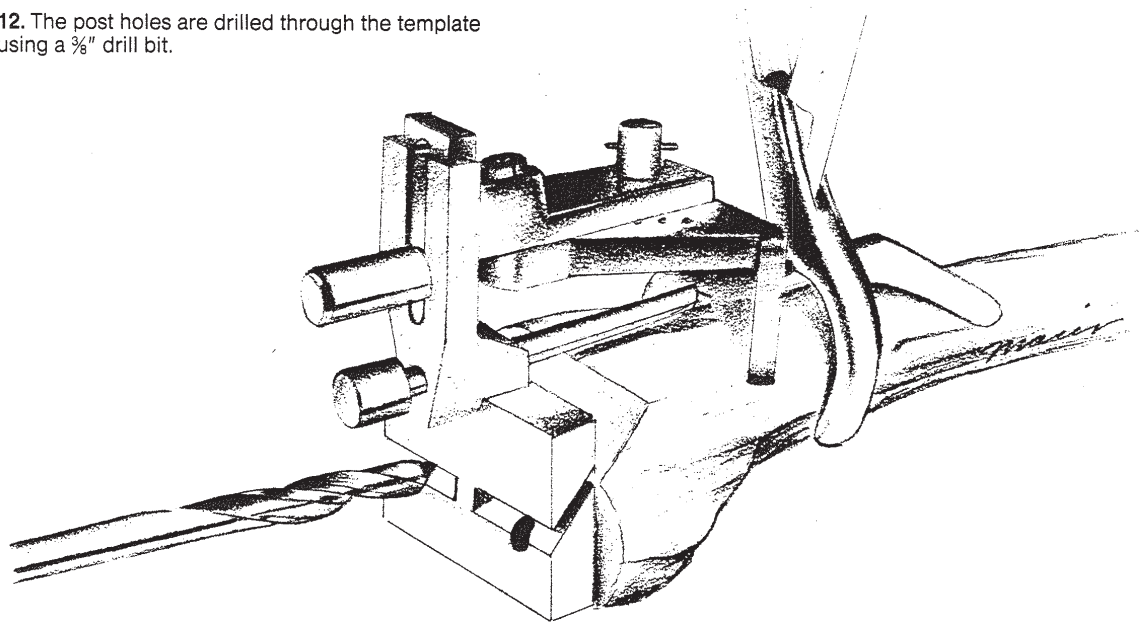
10. Generally, the largest A-P cutting guide applicable to the individual patient should be selected so that the corresponding prosthesis will provide stability with the knee in flexion. The A-P cutting guide is applied with the locator pin in the anterior hole to determine the first cut. This cut is made flush with the anterior shaft of the femur to displace the prosthesis as far posteriorly as possible.



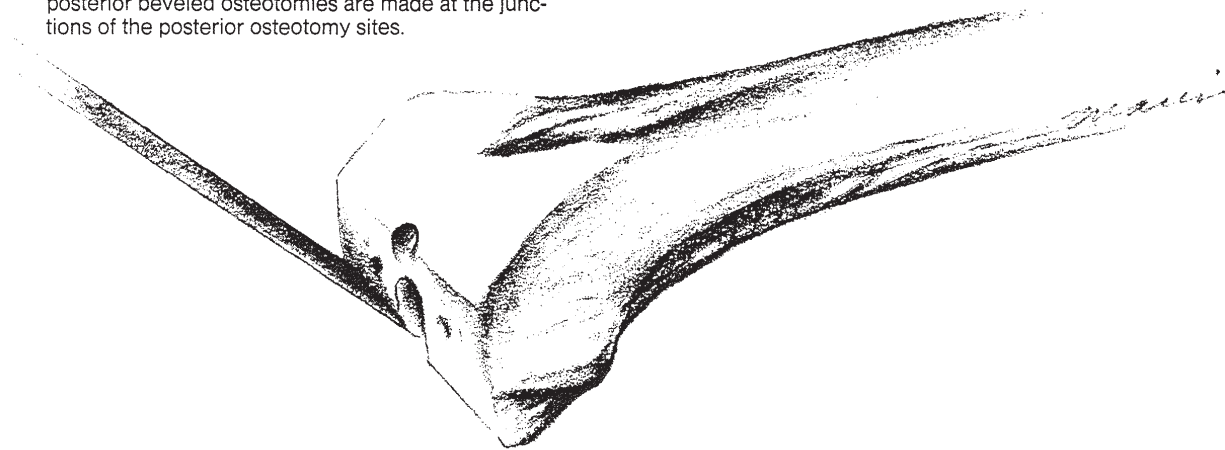
11. The second cut is made along the anterior bevel of the A-P cutting guide and the third cut along the posterior margin of the guide.



12. The post holes are drilled through the template using a $\frac{3}{8}$ " drill bit.



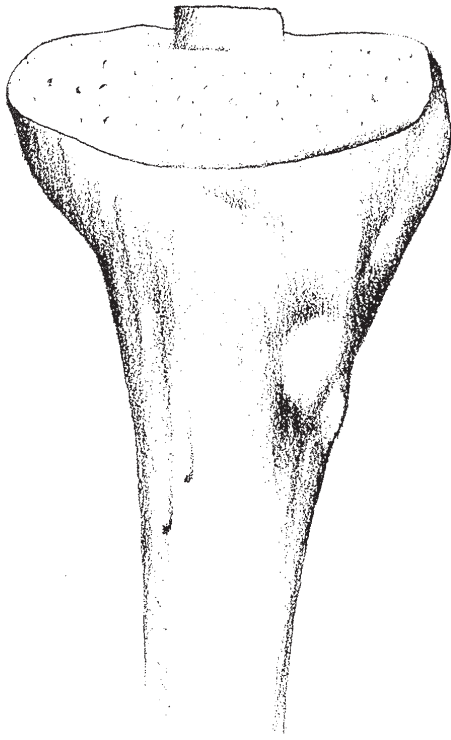
13. All the cuts using the femoral guide are now completed and the guide and clamp are removed. The 45° posterior beveled osteotomies are made at the junctions of the posterior osteotomy sites.



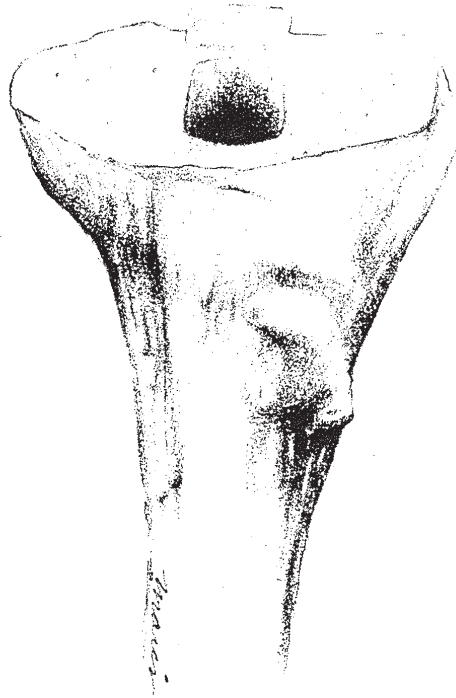
14. The patella is osteotomized with a thin cut passing through the medial and lateral facets. A $\frac{3}{8}$ " drill hole is placed in the center of the patella. The margins are slightly undercut with a small right angle curet.



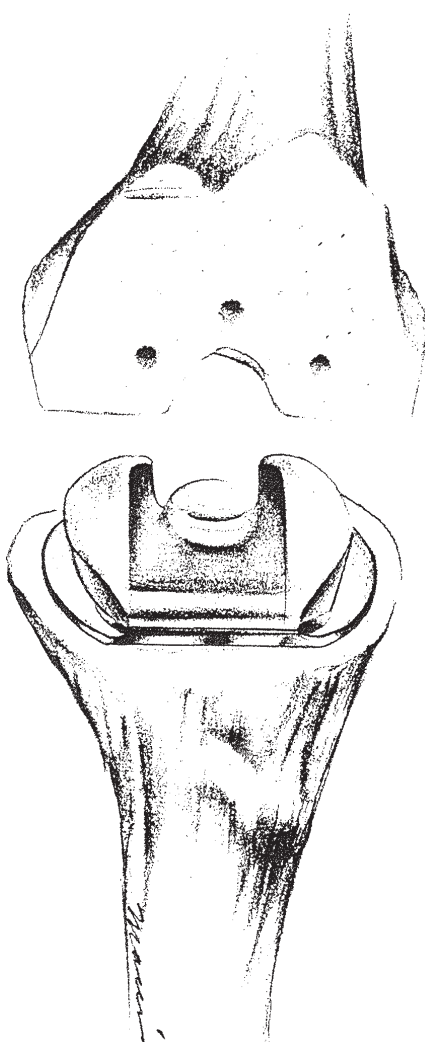
15. A Hohman retractor is placed posteriorly to the tibia and the proximal tibia displaced anteriorly. A Hohman retractor is also placed laterally to displace the extensor mechanism out of the wound. The remaining interspinous eminence is removed except for the portion remaining with the insertion of the posterior cruciate ligament. The margins of the remaining interspinous eminence are trimmed with rongeurs.



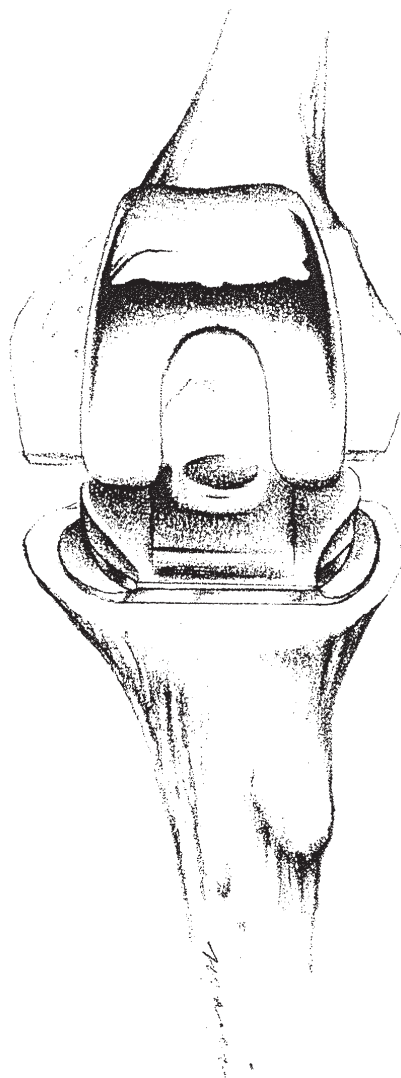
16. The anchor hole for the tibial stem is outlined with a small osteotomy saw and a punch used to impact the bone plug for better cement fixation.



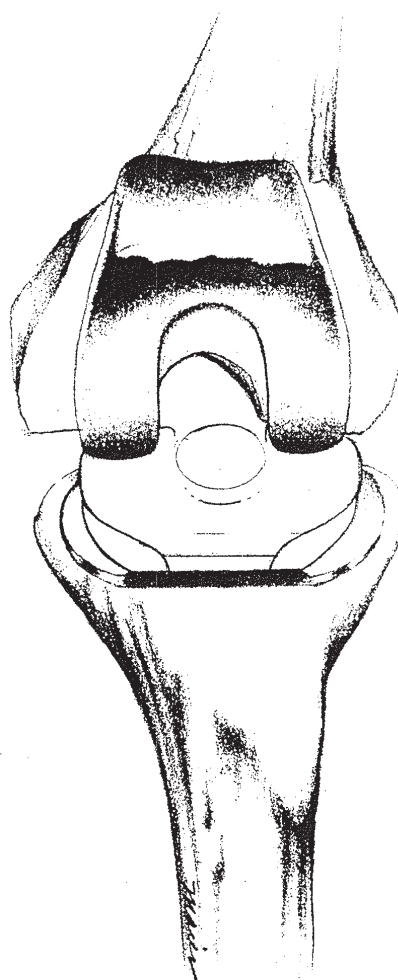
17. Hohman retractors are again placed posteriorly and laterally and the tibia displaced anteriorly. A tibial trial component is selected and inserted into the tibia. If there is any impingement, the trial is removed and the bone excised with rongeurs.



18. After good seating of the tibial trial is obtained, a Hohman retractor is used to elevate the femur over the dome of the tibial trial and the femoral trial inserted.



19. The trials are now removed and the knee thoroughly debrided and irrigated with pressure lavage. The knee is again exposed with the two Hohman retractors, one placed posterior to the tibia displacing it anteriorly and one laterally displacing the extensor mechanism. Additional lavage and debridement is performed. The anchor holes about the femur are pressure injected using a syringe as well as the cavity to receive the tibial stem of the prosthesis. Bone cement is applied and pressurized with finger pressure. The tibial component is inserted with manual pressure. Excess cement is removed from the periphery of the tibial component. After meticulous debridement, the tibial component is positioned under the femur using a Hohman retractor to elevate the femur. Cement is applied about the distal femur and digitally pressurized. The femoral component has cement applied to its inner surface and is inserted on the femur. Excess cement is removed from the margins of the femoral component and the leg brought into full extension with the foot to apply compressive pressure during cement curing. The cement is then applied about the patellar bed, the patellar prosthesis inserted and secured. Extruded cement about the periphery of the patellar prosthesis is removed. After curing of the cement, the tibia is displaced anteriorly using a Hohman retractor. This enables visualization of the entire top of the tibia and the complete periphery of the tibial prosthesis. Any additional cement which may have extruded around the tibial prosthesis during cement curing is removed. The same procedure is performed about the femoral component. The knee is then placed through a maximum range of motion, patellar tracking noted and if there is any tendency towards subluxation a lateral retinacular release is performed. It is important to check the posterior cruciate ligament to make sure that good stability remains. This may be visually checked without stressing the knee by observing the position of the femoral condyles during knee flexion. If the posterior cruciate ligament is intact, femoral roll-back will occur with the femoral condyles beginning in the middle of the tibial prosthesis in full extension and the articulation moving to the posterior third of the tibial component with maximum flexion. The wound is closed in the usual manner.



DOW CORNING
WRIGHT

5677 Airline Rd. Arlington, TN 38002
901-867-9971