

KNEE SURGERY

VOLUME TWO

EDITED BY

FREDDIE H. FU
CHRISTOPHER D. HARNER
KELLY G. VINCE



S&N EXHIBIT 1033
S&N v. BSI
IPR2013-00629

KNEE SURGERY

V O L U M E 2

FREDDIE H. FU, M.D.

Blue Cross of Western Pennsylvania Professor of Orthopaedic Surgery
Executive Vice Chairman
Department of Orthopaedic Surgery
Head Team Physician, Athletic Department
University of Pittsburgh
Pittsburgh, Pennsylvania

CHRISTOPHER D. HARNER, M.D.

Assistant Professor
Chief, Division of Sports Medicine
Department of Orthopaedic Surgery
Associate Medical Director
Center for Sports Medicine and Rehabilitation
University of Pittsburgh
Pittsburgh, Pennsylvania

KELLY G. VINCE, M.D., F.R.C.S. (C)

Assistant Clinical Professor
Department of Orthopaedic Surgery
University of California, Irvine
School of Medicine
Associate Surgeon
The Kerlan-Jobe Orthopaedic Clinic
Inglewood, California

ASSOCIATE EDITOR

MARK D. MILLER, M.D.

Clinical Assistant Professor of Surgery
Uniformed Services University of Health Sciences
F. Edward Herbert School of Medicine
Bethesda, Maryland
Department of Orthopaedic Surgery
United States Air Force Academy Hospital
Associate Team Physician
United States Air Force Academy
United States Air Force Academy, Colorado



Williams & Wilkins

BALTIMORE • PHILADELPHIA • HONG KONG
LONDON • MUNICH • SYDNEY • TOKYO

A WAVERLY COMPANY



Editor: Darlene Cooke, Timothy H. Grayson
Project Manager: Kathleen Courtney Millet
Copy Editor: Harriet Felscher, Kathleen L. Marks, Anne K. Schwartz
Designer: Norman W. Och
Illustration Planner: Wayne Hubbel

Copyright © 1994
Williams & Wilkins
428 East Preston Street
Baltimore, Maryland 21202, USA



All rights reserved. This book is protected by copyright. No part of this book may be reproduced in any form or by any means, including photocopying, or utilized by any information storage and retrieval system without written permission from the copyright owner.

Accurate indications, adverse reactions, and dosage schedules for drugs are provided in this book, but it is possible that they may change. The reader is urged to review the package information data of the manufacturers of the medications mentioned.

Printed in the United States of America

Library of Congress Cataloging in Publication Data

Knee surgery / edited by Freddie H. Fu, Christopher D. Harner, Kelly G. Vince.

p. cm.

ISBN 0-683-03389-1

1. Knee—Surgery. 2. Knee—Wounds and injuries. 3. Knee—Diseases.

I. Fu, Freddie H. II. Harner, Christopher D. III. Vince, Kelly G.

[DNLM: 1. Knee—surgery. WE 870 K68 1994]

RD561.K584 1994

617.5'82059—dc20

DNLM/DLC

for Library of Congress

93-28416

CIP

94 95 96 97 98
1 2 3 4 5 6 7 8 9 10

Reprints of chapter may be purchased from Williams & Wilkins in quantities of 100 or more. Call Isabella Wise in the Special Sales Department, (800) 358-3583.

Surgical Exposure in Total Knee Arthroplasty

Steven H. Stern

Introduction

Primary Procedures

Anterior Approach for Knee
Arthroplasty
Subvastus Approach for Knee
Arthroplasty

Trivector Retaining Arthrotomy Technique for Knee Arthroplasty

Lateral Approach for Knee
Arthroplasty

Exposure in Revision or Difficult Knees: General

Basic Techniques

Proximal Soft Tissue Techniques
Osteotomy of the Tibial Tubercle
Osteotomy and Transfer of the
Tibial Tubercle

Introduction

It has been a maxim handed down through generations of surgeons that excellent visualization of the operative region is a prerequisite to consistently achieving successful results. As with all surgical procedures, knee arthroplasty commences with exposure of the relevant anatomic structures. In addition, most surgical approaches are designed so that dissection is carried through regions where the chance of significant neurovascular injury is minimized. Knee surgery, specifically knee arthroplasty, is in no way an exception to these basic tenets. There are several unique aspects of knee arthroplasty that place extra emphasis on surgical exposure and handling of the soft tissues. First, the knee is a relatively superficial joint compared to the hip, which is the other anatomic structure most commonly involved in reconstruction. Thus, the knee's soft tissue envelope is not as extensive as that surrounding the hip. Second, the knee arthroplasty surgeon is faced with the twin goals of obtaining soft tissue healing and maximizing knee motion. Therefore, skin problems, especially skin necrosis, are a definite concern in knee surgery (2, 11, 12). This further raises the need for specific attention to surgical exposure and proper handling of soft tissues in knee arthroplasty.

The surgical approaches most commonly favored by implant surgeons are designed to allow easy access to the knee joint and surrounding tissues. Exposure needs to be accomplished while minimizing excess skin and soft tissue tension. As in all surgical exposures, several general principles apply. Generally, extensile exposures are favored so that dissection can be extended, as needed, either proximally or distally to enhance visualization. One long incision is preferred to several shorter incisions. However, it is widely accepted that prior transverse skin wounds can be successfully crossed at right angles by new longitudinal incision (2, 11, 26). If possible, previous vertical incisions should be incorpo-

rated into current skin incisions, and parallel incisions should be avoided. On occasion, prior vertical incisions are in areas that make inclusion of them in a current longitudinal approach impractical. In these cases, it may be necessary to make a second vertical incision, leaving as wide a soft tissue bridge between the two wounds as possible. Finally, the possible need for future surgical procedures should always be considered by the implant surgeon at the time of skin incision.

Primary Procedures

A standard midline anterior approach remains the most common method utilized to achieve exposure of the knee. However, there are certain circumstances that require, and certain surgeons who prefer, alternative methods of exposure in knee arthroplasty. In revision surgeries, or with ankylosed knees, it is often necessary to perform either proximal soft tissue releases or distal bone osteotomies in order to enhance visualization (1, 18, 20, 23, 25, 27, 29). There has also been recent interest in other methods of obtaining adequate knee exposure in index arthroplasty (3, 9). This is partially related to continued problems and concerns with the knee's extensor mechanism after total knee arthroplasty (4, 19, 21, 28). The standard anterior approach with a midline or medial parapatellar arthrotomy dissects directly through the extensor mechanism. Because of this disruption, some authors advocate either a "subvastus" or "trivector retaining" approach for total knee replacements (3, 17).

Anterior Approach for Knee Arthroplasty

The anterior approach is extensile, allowing access to both distal femur and proximal tibia. Patellar eversion permits excellent visualization of all compartments of the knee. An anterior knee approach can be used for fractures, arthroplasty, arthrodeses, and extensor mechanism procedures. Multiple procedures can be per-

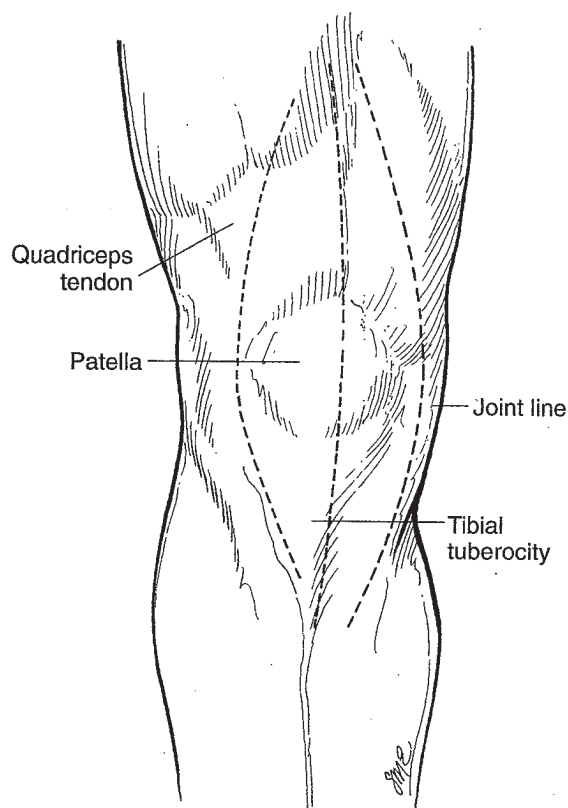


Figure 66.1. Skin incisions that can be utilized for the anterior approach to the knee.

formed through the same incision with excellent visualization of both medial and lateral structures and minimal neurovascular injury. While the basic philosophy behind all anterior exposures is similar, there are slight variations in technique. Skin incisions can be made directly midline, or with slight medial or lateral curves (Fig. 66.1). Some surgeons believe there is a theoretical benefit to wound healing with a curved medial parapatellar skin incision (12). Others favor a compromise with a straight or very gently curved incision, made slightly medial to midline. Lateral skin incisions associated with medial arthrotomies are normally not encouraged because of the extensive skin flaps they require.

Dissection is then carried down through the subcutaneous tissue in order to expose the quadriceps and patellar tendons. After adequate exposure of the extensor mechanism, most surgeons perform a medial retinacular arthrotomy. This allows eversion of the patellar laterally and exposure of the knee joint proper. Retinacular incisions can be curved or straight (Fig. 66.2). Insall advocates a straight medial retinacular exposure (10). This is carried along the medial aspect of the quadriceps tendon, over the medial aspect of the patellar, and distally onto the anterior tibial cortex. The quadriceps expansion including the periosteum is sharply dissected from the medial patella with less damage to the distal insertion of the vastus medialis. This is preferred over a curved retinacular incision, which transects the insertion of the vastus medialis into the patella (11). Insall

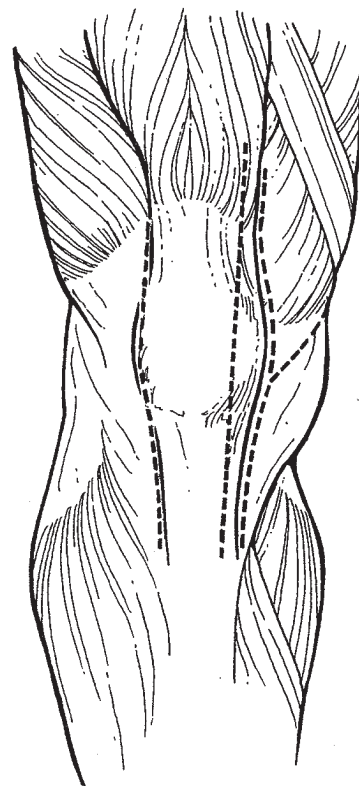


Figure 66.2. Various options for the retinacular capsular incision in knee arthroplasty. These include the subvastus medial parapatellar, midline, and lateral parapatellar incisions.

feels that repair of the extensor mechanism with this approach is not as strong as with a midline retinacular incision.

Others advocate a medial parapatellar retinacular incision (2, 15), where the retinacular incision is medial to the patellar through the anteromedial knee capsule. The incision then curves back to the medial aspect of the patellar tendon and distally along its medial margin. This allows for a thicker cuff of soft tissue for closure at the level of the patellar bone.

After the arthrotomy is performed, the knee is flexed and the patellar everted. This should be accomplished without placing excessive tension on the patellar tendon. In revision surgery or in obese patients, it may be necessary to extend the dissection further proximally to help facilitate patellar eversion. In rare cases, it may be impossible to evert the patella. However, in these instances it may still be possible to perform a knee arthroplasty by retracting the extensor mechanism and patellar laterally. The knee arthroplasty can then be carried out in the standard fashion, depending on the alignment of the knee and the types of components to be implanted.

During closure, great care is taken in positioning the initial sutures in order to minimize patellar baha, which is known to be associated with prior knee procedures (24). The author attempts to minimize the baha formation by placing the initial suture in a specifically angled manner (Fig. 66.3). The arthrotomy and subcutaneous

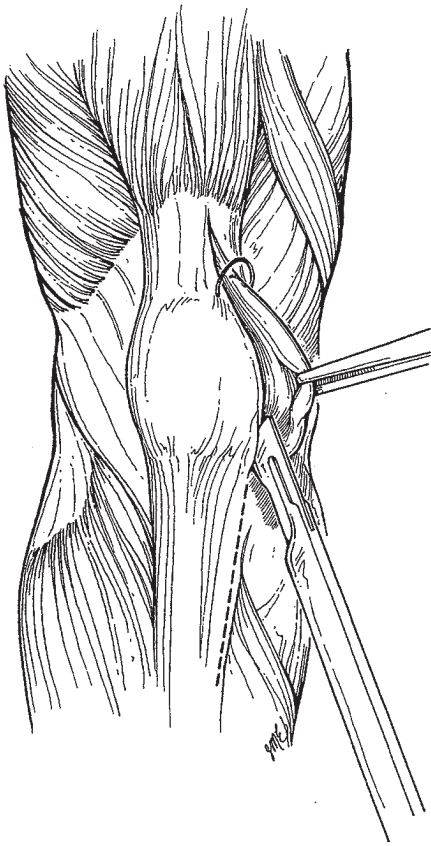


Figure 66.3. Placement of the initial retinacular suture during closure to minimize postoperative patella baha complications.

tissue can be approximated in a number of ways depending on individual surgeon's preference.

Subvastus Approach for Knee Arthroplasty

There has been a recent interest in the use of the subvastus knee approach for knee arthroplasty. This approach was first described by Erkes in 1929, but fell out of favor over the next several decades (7). One advantage of the subvastus technique is that it preserves an intact extensor mechanism (8). Advocates of this approach believe that it results in less postoperative pain and a stronger extensor mechanism. The procedure also preserves the vasculature to the patella and quadriceps expansion. It is now being used by surgeons for both unicompartamental replacements and total knee arthroplasties in selected individuals (8, 9, 14, 22) (Fig. 66.4). Theoretically, preservation of the extensor mechanism allows the surgeon to more accurately judge patellar tracking in knee arthroplasty. Also, the integrity of the soft tissue envelope decreases the chance of wound dehiscence.

Advocates of this approach stress its limitations (9). Specific relative contraindications include revision total knee arthroplasty or previous arthrotomy. In addition, obese patients, especially those weighing more than 200 pounds, represent a relative contraindication to this method, because of the difficulty in everting the patella.

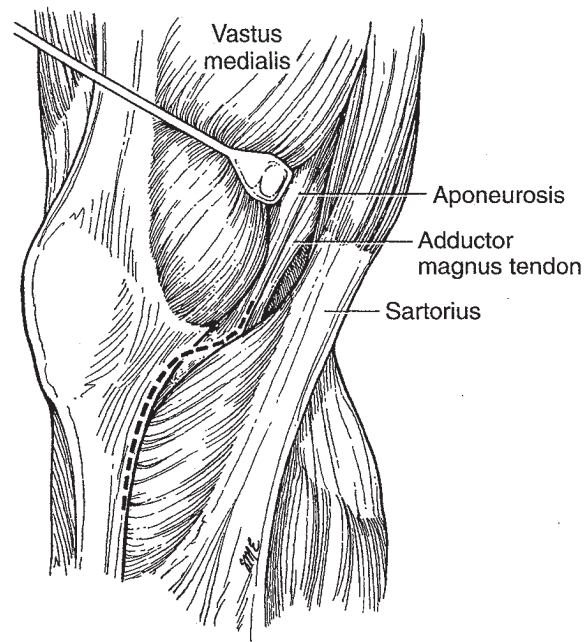


Figure 66.4. Subvastus technique. Note that with this technique the extensor mechanism is preserved. The approach proceeds below the inferior edge of the vastus medialis obliquus muscle belly.

Procedure

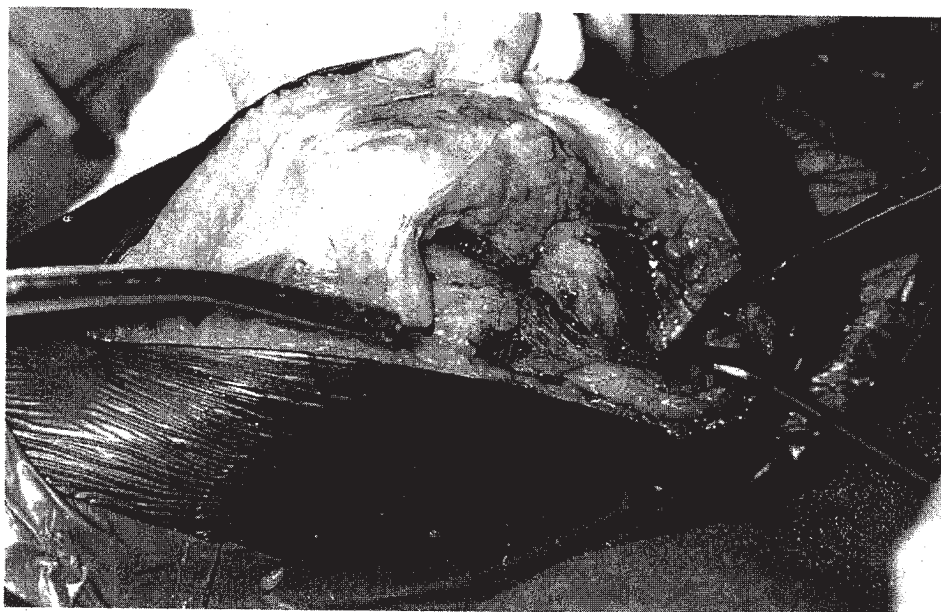
The patient is positioned in a standard supine fashion on the surgical table. The subvastus approach to the knee commences with the knee flexed to at least 90 degrees. A direct anterior skin incision is made. The anterior portion of the incision is made 4 finger-breadths above the patella and carried to a point 1 cm distal and slightly medial to the tibial tubercle. A slightly longer incision is made than with the standard midline approach. This is done in order to minimize skin tension. Dissection is carried through deeper levels until fascial layer 1 is identified proximally. It is incised in line with the skin incision down to the level of the patella. In the patella region, dissection is carried slightly medially. After incising the fascial layer, blunt dissection is used to raise this layer off the underlying vastus medialis. Dissection is meticulously carried down the fascial layer of the vastus medialis to its insertion site. This continues until the inferior edge of the vastus medialis is clearly identified. After identification of the inferior edge, the vastus medialis obliquus (VMO) muscle belly is bluntly dissected free of the periosteum and intramuscular septum. This dissection is carried for a distance approximately 10 cm proximal to the adductor tubercle. During this approach, blunt dissection minimizes risk to the underlying neurovascular structures.

The vastus medialis muscle is continually retracted anteriorly in order to clearly identify its musculotendinous insertion onto the medial capsule (Fig. 66.5). When dissection allows clear visualization, the insertion is transversely incised at the level of the midportion of

Figure 66.5. Anterior retraction of the VMO and blunt dissection allows identification of the region for the capsular incision. (Photo courtesy of William Brien, M.D., Los Angeles, California.)

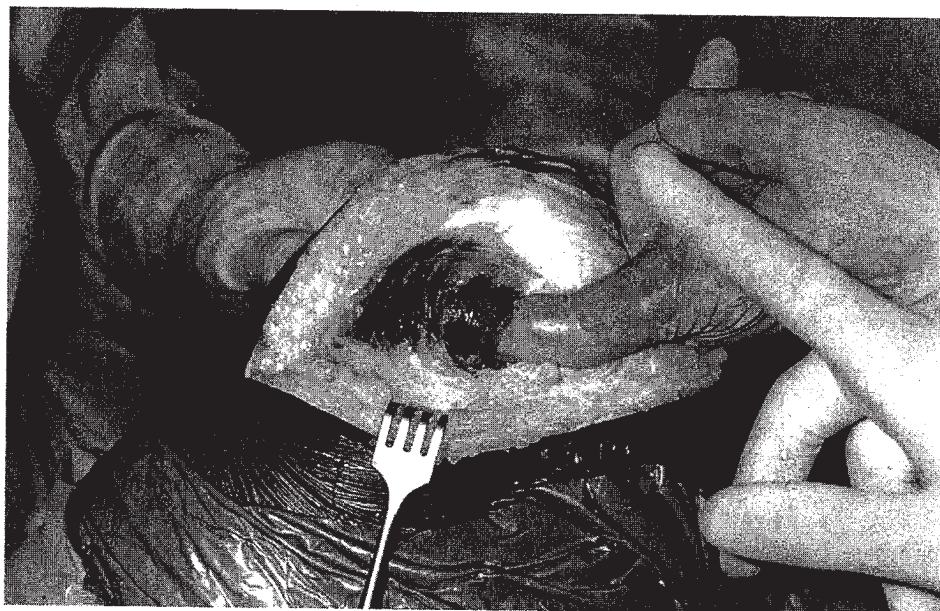

Figure 66.6. Knee arthrotomy performed with the subvastus technique. (Photo courtesy of William Brien, M.D., Los Angeles, California.)



patella (Fig. 66.6). The arthrotomy is continued distally in a curvilinear manner with the incision carried down, in a standard fashion, along the medial aspect of the patella and patella tendon to the region of the tibial tubercle. The patella is then everted and dislocated laterally (Fig. 66.7). The knee is slowly flexed with continued blunt dissection of the vastus medialis muscle belly off the intermuscular septum. In this approach, the bulk of the vastus medialis remains attached to the patella and quadriceps tendon.

At this point, adequate visualization of knee should allow placement of the knee components in a standard fashion. Patellar tracking is assessed through the arthrotomy. If the patellar does not track in an accept-

able manner, a lateral retinacular release is performed. This can be done in an outside to inside fashion with the knee in full flexion. In an attempt to minimize injury to the anterior tibial, as well as the lateral geniculate vessels, the release is made at least 1.5 cm lateral to the patella (13, 17).

After the surgery is finished, the wound is closed in a routine manner. The vertical limb of the incision, as well as the proximal horizontal limb, are closed with interrupted sutures. The distal arthrotomy is closed with interrupted sutures. No reattachment of the vastus muscle belly to the intermuscular septum is needed.

Kim described a slight modification of the subvastus technique in his report on a quadriceps dislocating me-

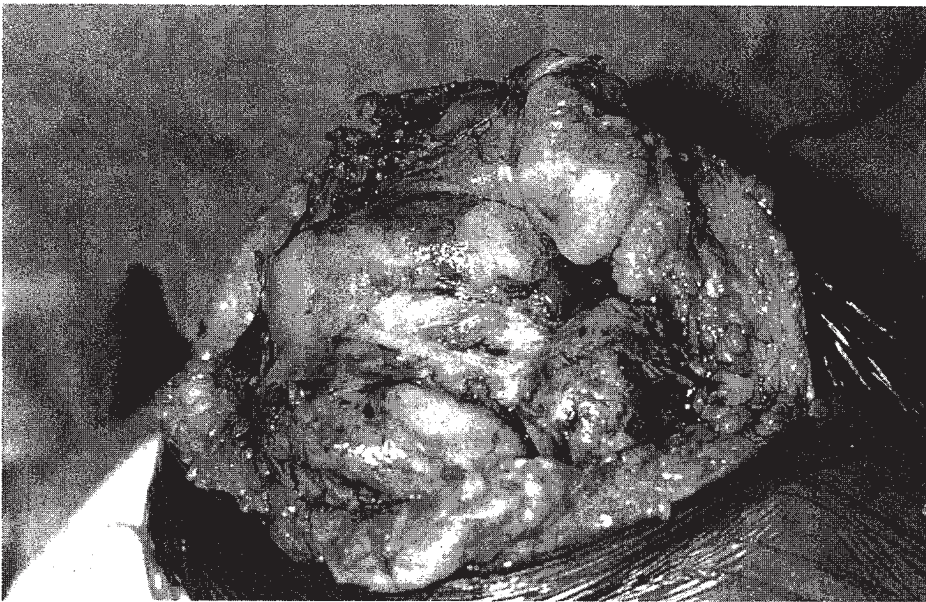


Figure 66.7. Patella eversion and satisfactory exposure achieved with the subvastus technique. (Photo courtesy of William Brien, M.D., Los Angeles, California.)

dial knee approach (14). This surgical approach is essentially a subvastus technique with some minor modifications. He advocates a straight longitudinal skin incision commencing from the medial lower third of the thigh running anteriorly and distally. The incision is carried to a level just distal to the tibial tubercle. Utilizing this superficial exposure, it is possible to make a straight incision through the underlying synovium, conjoined retinaculum, and medial capsule after retraction of the muscle. This results in a subvastus type approach with the retinacular incision in line with the skin wound.

Results with Subvastus Approach

Kim analyzed 200 knees undergoing total knee arthroplasty with different operative approaches (14). Eighty-one had a lateral capsular incision approach, 61, a medial capsular incision approach, and 58, a quadriceps dislocating medial approach (subvastus approach). Of the 142 patients with the medial or lateral capsular incisions, 6 developed skin sloughs. This is in contrast to no wound problems in the 58 patients in the quadriceps dislocating medial approach. ($p < .05$). Subluxation of the patella was noted in 13% with the medial approach, 1% with the lateral approach and 0% with the subvastus approach. The authors felt that traditional anterior skin incisions led to increased skin tension in flexion, which caused the higher incidence of skin sloughs with these methods. Conversely, with the quadriceps dislocating medial approach, they felt that skin tension was negligible, even in full flexion. This was because the skin incision was on the medial aspect of the joint. In addition, they felt that undermining of the skin was minimized with this approach.

Ritter, et al. compared results achieved with a vastus medialis-sparing approach to those found with a standard midline exposure (22). They examined 28 patients

undergoing simultaneous bilateral total knee arthroplasty. In each patient, one knee was randomly chosen for exposure utilizing the vastus medialis-sparing approach (study group), while the contralateral knee received a standard medial parapatellar arthrotomy (control group). All knees were implanted with Anatomic Graduated Components (AGC) (Biomet, Warsaw, IN). Lateral retinacular releases were required in 52% of the study group, and 48% of the control group. Postoperatively, all knees were evaluated by a physical therapist who was unaware of the surgical approach utilized. The authors felt that they encountered increased difficulty with dislocating and retracting the patella in the knees exposed with the subvastus technique. In this series, the average range of motion at discharge was from 4 to 82 degrees for both groups. At both 6 months and 1 year, the subvastus group had motion from 2 to 99 degrees. This was similar to the average motion of 2 to 101 degrees seen in the control group. There were no significant complications, infections, or thrombophlebitic events in either group. The authors concluded that they could find no correlation between postsurgical recovery and morbidity related to the surgical approach employed. They did, however, feel that the vastus medialis-sparing method was more technically demanding and made exposure more difficult. Thus, they expressed their continued preference for a medial parapatellar arthrotomy.

Trivector Retaining Arthrotomy Technique for Knee Arthroplasty

Bramlett, et al. have proposed a "trivector-retaining arthrotomy technique" as an alternate method of knee exposure (3). They advocate its use in both primary and revision total knee replacement procedures. Theoretically, this method spares the anatomic trivector arrangement of the quadriceps (vastus medialis, vastus inter-

medius, vastus lateralis, and rectus femoris) insertion into the patellar. Advocates of this technique feel that it is reproducible and combines advantages of both the standard medial parapatellar arthrotomy with those inherent to the subvastus approach. They feel that these benefits are achieved while reducing disadvantages intrinsic to both methods. The trivector approach is similar to the subvastus method in that both minimize disruption of the vastus medialis insertion and the vascular supply to the patellar. However, advocates of the trivector approach feel that it allows for a more extensive exposure of both the lateral and posterolateral knee compartments than does the subvastus technique. Thus, this method can theoretically be used in revision arthroplasty and in obese patients.

Procedure

The trivector technique begins with a routine midline skin incision. This is carried both above and below the patellar for a distance of approximately 4 finger-breadths. Dissection proceeds down through the fascial tissue until the triangular tendon insertion of rectus intermedius and the three separate vastus muscle groups can be easily identified. The knee is then flexed to 90 degrees, and a straight arthrotomy is performed. The arthrotomy begins at a point approximately 3 finger-breadths above the superior pole of the patellar and 1.5 centimeters medial to the medial border of the quadriceps tendon. The arthrotomy proceeds directly through the vastus medialis oblique (VMO) muscle. It is extended distally in a straight line running one centimeter medial to the patellar and carried distally to the level of the tibial tubercle. (Fig. 66.8). Once the trivector arthrotomy technique has been performed, patellar eversion and posterior lateral exposure are easily obtained.

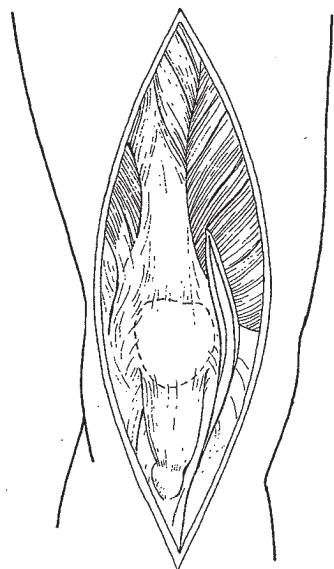


Figure 66.8. The retinacular incision with the trivector retaining arthrotomy technique extends directly through the anterior fibers of the vastus medialis. (Drawn from photo courtesy of Kenneth W. Bramlett, M.D., Birmingham, Alabama.)

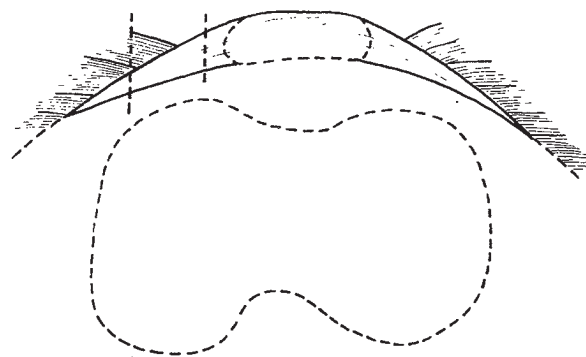


Figure 66.9. Cross section of the quadriceps tendon showing the inferior extension of the tendon below the muscle belly fibers. (Drawn from photo courtesy of Kenneth W. Bramlett, M.D., Birmingham, Alabama.)

Advocates of this technique feel that it is acceptable to incise the distal portion of the VMO fibers. They feel that there is a medial extension of the common quadriceps tendon that underlies the oblique anterior VMO muscle fibers (Fig. 66.9). It is this underlying tendon that provides for a secure arthrotomy closure. Bramlett, et al. feel that, with this technique, the remaining VMO function plus contributions from the nonviolated quadriceps muscles prevent unopposed lateral pull on the patella. They feel that the increased anatomic pull of these remaining muscles helps minimize the need for lateral retinacular releases.

Results with Trivector Retaining Arthrotomy Technique

Bramlett, et al. have reported on 148 total knee arthroplasties performed over a 21-month period during which this particular technique was utilized (3). Surgical procedures included 103 index total knee arthroplasties, 26 unicondylar replacements, and 19 knee revisions. There were no patella tendon ruptures nor patella evulsions in their series. Only one "V-Y" turndown was necessary; this turndown became necessary in a knee undergoing a third revision procedure. All patients were able to initiate physical therapy on the first postoperative day. There were no wound complications nor infections in this cohort of patients, but one patient underwent reoperation for closure of a synovial fistula. In addition, they did not find any patella fractures, patella component loosening, or tendon unit failures. Finally, in utilizing this approach, they found no evidence of recurrent dynamic patella subluxation or patella dislocation.

Lateral Approach for Knee Arthroplasty

Keblish (13a) advocates a lateral approach for knee arthroplasty when performing the procedure on knees with a fixed preoperative valgus deformity. He feels the standard medial approach has significant technical limitations and disadvantages, resulting in an increased incidence of patellar maltracking and extensor mechanism problems. This is because the medial exposure requires lateral displacement and eversion of the exten-

sor mechanism, which is accomplished with external tibial rotation. Thus, this technique indirectly approaches the most severely involved lateral pathologic anatomy, while the external tibial rotation further retracts the knee's posterior-lateral corner away from the operative field. Additionally, the medial exposure usually requires an extensive lateral release in valgus knees, thereby violating the blood supply to the extensor mechanism on both the medial and lateral sides.

Keblish developed the lateral approach in an attempt to deal with these problems and utilizes it when correcting a valgus deformity during total knee arthroplasty. He believes that advantages of this technique include a more direct approach to the pathologic lateral anatomy. A lateral retinacular release is routinely performed as an integral part of the exposure. Medial displacement of the extensor mechanism causes internal rotation of the tibia, further exposing the posterior-lateral corner. Vascularity is preserved because the extensor mechanisms medial blood supply is undisturbed. Finally, he feels that adequate tracking of the patellar is easily achieved via the self-centering mechanism of the retained extensor mechanism.

Keblish does concede that the lateral technique is technically more demanding than the traditional medial approach. Orientation is reversed, and the anatomy is less familiar to most surgeons. Finally, medial eversion and displacement of the extensor mechanisms is more difficult.

Procedure

The lateral approach to the knee commences with a long longitudinal incision. This is made just lateral to the midline, and is carried distally to a point 1 to 2 cm lateral to the lateral aspect of the tibial tubercle. As with other knee approaches, previous longitudinal incisions should be utilized whenever possible to minimize wound problems. The lateral retinacular arthrotomy originates proximally along the lateral border of the quadriceps tendon and extends distally 1 to 2 cm lateral to the lateral patellar border. The arthrotomy courses along the medial border of Gerdy's tubercle, ending distally in the anterior compartment fascia at a point approximately 2 cm lateral to the lateral patellar tendon border (Fig. 66.2). Care must be taken during the exposure not to violate the fat pad as the preservation of its blood supply is necessary for soft tissue closure.

After the arthrotomy is performed, Keblish advocates testing the limb in extension in order to evaluate the degree, if any, of iliotibial band contracture. This is accomplished by applying a varus stress to the extremity while it is held in full extension. If the knee cannot be brought to an acceptable anatomic alignment, the iliotibial (IT) band is released proximally at a point approximately 10 cm proximal to the joint line. If release of the IT band is necessary, it is exposed utilizing blunt finger dissection carried from proximal to distal. Care is taken to palpate and protect the peroneal nerve. Exposure can be enhanced by placing a long instrument from anterior to posterior behind the IT band. While there are several techniques for effecting an IT band release, Keblish ad-

vocates performing multiple small punctures. This is done while an assistant applies a constant varus stress to the extremity. In this way, he feels that he is able to titrate his release to the extent necessary to achieve acceptable limb alignment. If physiological valgus cannot be achieved with this method, then further posterior lateral release is required.

It may be noted that other surgeons (3a) favor a distal IT band release in knees with severe fixed valgus deformities, as opposed to the proximal technique outlined above. Advocates of distal releases normally perform this step after medial displacement of the extensor mechanism with the joint exposed in flexion. The distal release can include elevation of Gerdy's tubercle with a sleeve of anterolateral fascia. In addition, fibular head resection can be added to minimize stress on the peroneal nerve.

The next step with the lateral approach is mobilization of the fat pad and capsule in order to maintain an adequate soft tissue envelope. Because correction of a valgus knee leads to a lateral retinacular gap, it is necessary to mobilize the soft tissues in order to provide an adequate envelope for closure. Keblish advocates sharp dissection along the underside of the patellar tendon. This is carried to the medial extent of the intermeniscal ligament, which is then incised to bone. This allows the composite of fat pad, capsule, intermeniscal ligament, and rim of lateral meniscus to be mobilized laterally. Care is taken not to dissect through the fat pad, especially along its lateral aspect, which is the region for its blood supply.

The next step involves preparation for medial translocation of the extensor mechanism. An osteoperiosteal sleeve is elevated off the lateral tibial tubercle with an osteotome. This is done in a meticulous and careful manner to allow for a gradual peel of the lateral 50% of the patellar tendon. At this time, patellar eversion and medial patellar displacement can be accomplished. This is slightly more difficult than with the traditional lateral displacement techniques, but Keblish believes it can be performed safely and adequately. A varus moment is applied to the flexed knee, while the patellar is everted medially. The patellar tendon attachment is observed at all times during this maneuver. If needed, adhesions or large patellar osteophytes are resected to achieve eversion. Patellar resection, which is part of prosthetic resurfacing, can be accomplished at this time to ease eversion, if desired. Keblish believes that, once medial patellar displacement has been achieved, the tibia will rotate internally, enabling direct visualization and a more accurate analysis of the posterior-lateral corner and arcuate complex.

If necessary, a posterior lateral release can be performed at this point in the exposure. This osteoperiosteal release is carried out along the femur after all osteophytes are excised. This is carefully titrated to minimize the amount of soft tissue stripping necessary to achieve an anatomic valgus limb alignment.

The posterior medial compartment is the most difficult to visualize with this lateral exposure. Curved retractors can be placed over the posterior-medial corner

and the tibia rotated back to a neutral position in order to improve visualization. At this point, it should be possible to perform the proximal tibial cut, as well as the rest of the bone cuts in a relatively straightforward and standard manner.

After component insertion, patellar tracking is assessed. Keblish believes that the extensor mechanism more naturally adjusts to the midline with this lateral approach, thereby minimizing the tendency for lateral patellar subluxation commonly seen with the traditional medial exposure. In addition, a lateral retinacular release has already been routinely performed as part of the initial approach. Closure of the arthrotomy includes utilization of the previously developed lateral soft tissue composite (lateral meniscus, capsule and fat pad) to fill any gap in the lateral retinaculum. Significant expansion of the fat pad can be achieved, while preserving its vascularity, by making transverse relaxing incisions in line with the retained lateral meniscal rim. This composite can then be sutured to the proximal capsular flap, helping to restore a soft tissue retinacular envelope. Final closure of this composite to the border of the lateral extensor mechanism is accomplished with the knee flexed. Closure of the skin incision and postoperative rehabilitation are carried out in a standard manner.

Results with Lateral Approach

Keblish (13a) has reported his results on 53 knees having greater than 2-year follow-up, in which the lateral approach was utilized. Valgus deformities ranged from 12 to 45 degrees (mean: 22 degrees). The vast majority of the knees were implanted with a Low Contact Stress (LCS) (DePuy, Warsaw, IN) knee prosthesis. Cement fixation was used in 12 knees. 94% of the knees scored in the good to excellent range utilizing the New Jersey Orthopaedic Hospital rating scale. Range of motion improved from an average of 85 degrees preoperatively to 115 degrees postoperatively. Complications included 5 nonfatal pulmonary embolisms, 2 subcutaneous hematomas that healed uneventfully, and 1 wound dehiscence requiring debridement and secondary closure. Intraoperative problems included 3 minor split type fractures, and 1 failure of an uncemented patellar component requiring revision to a cemented component. Finally, 1 meniscal-bearing tibial component placed in a knee with a complex deformity was felt to be malpositioned; it required reoperation 1 week after surgery. Both 1 transient sensory and 1 transient motor peroneal nerve palsy resolved uneventfully by 6 months. The authors reported no patellofemoral maltracking problems.

Exposure in Revision or Difficult Knees: General

Routine patella eversion and adequate knee exposure cannot always be easily achieved, especially in knees that have undergone prior surgical procedures, in those with severe flexion contractures or malalignment, or in knees in obese patients. In these instances, it is often possible to improve visualization with some basic tech-

niques. These include extending the quadriceps incision proximally, performing a lateral retinacular release, and, externally, rotating the tibia. External rotation of the tibia enhances medial subperiosteal dissection along the proximal tibia. If patellar eversion and adequate exposure cannot be achieved with these methods, the surgeon must consider alternative techniques (25).

Exposure enhancement normally falls into one of two categories. Some surgeons advocate proximal soft tissue techniques in order to allow retraction of the extensor mechanism laterally and distally (1, 18, 23, 25). Others advocate a distal tibial tubercle osteotomy, letting the extensor mechanism and tibial tubercle retract laterally and superiorly (6, 27, 29). Advocates of proximal soft tissue techniques feel this method minimizes the rate of major mechanical complications that have been reported with tubercle osteotomy (29). They acknowledge the theoretical jeopardy to the extensor mechanism blood supply with proximal soft tissue methods, but feel that this has not been a clinical problem (25). Advocates of tubercle osteotomies believe that an appropriately sized osteotomy will minimize complications. It would also permit bone-to-bone healing, which they postulate is superior to soft tissue healing.

Basic Techniques

The principles of surgical exposure in revision total knee arthroplasty are documented in a short article by Windsor and Insall (28). They describe techniques that were developed on the Knee Service at the Hospital for Special Surgery and successfully applied to over 250 revision knee arthroplasties. This means commencing revision procedures by using the prior skin incision. They suggest that prior midline longitudinal incisions can be lengthened proximally and distally. Undermining the medial and lateral skin flaps should be minimized and carried only to the extent needed to expose the quadriceps tendon, patella, and patellar tendon. They advocate blunt dissection techniques, minimal retraction of the skin flaps, and minimal soft tissue undermining to minimize the risk of skin necrosis. If more than one longitudinal incision is already present, the more lateral of the approaches should be selected. This is based on the belief that the better blood supply is on the medial aspect of the knee.

With adequate exposure of the extensor mechanism, the medial retinacular incision can be made. If possible, a straight longitudinal retinacular incision is performed. A medial parapatellar, retinacular incision can also be done if this will minimize undermining of the skin flaps. Care must be taken not to cut across the proximal extension of the quadriceps tendon. At this point, they recommend careful subperiosteal elevation of soft tissue over the medial tibial cortex, extending to the posterior margin of the tibial plateau. They emphasize the need for a full posterior medial exposure, including the need for sharp dissection of the insertion of the semimembranosus muscle. Care must be taken to leave the medial collateral ligament and medial soft tissues in an intact sleeve.

The next step is the removal of scar tissue, usually found in abundance in the medial and lateral gutters. These adhesions are normally dissected with a combination of sharp and blunt techniques. Patellar eversion is the next step and can usually be accomplished with the knee flexed to 90 degrees. This must be done carefully to minimize patellar tendon disruption. Certain maneuvers can facilitate patella eversion.

First, moving the tibia anteriorly, while rotating externally, will move the extensor mechanism laterally (8). It may be possible to use a bent Hohman or other retractor to pull the extensor mechanism further laterally. This will allow adequate exposure of the knee without eversion of the patella. A lateral retinacular release can also increase exposure of the knee and will, in many instances, facilitate patellar eversion. However, if adequate exposure is not obtained, proximal soft tissue techniques or distal tubercle osteotomies will be necessary (see below).

After adequate exposure of the femur and tibia, Windsor and Insall recommend a "femoral peel" in which the posterior capsule and scar surrounding the distal femur are dissected from bone with a large curette. The scar is "peeled" away, effectively skeletonizing the distal femur in a single layer. The medial and lateral collateral ligaments should be preserved. Severe flexion contractures may necessitate further posterior capsular dissection.

Proximal Soft Tissue Techniques

Coonse and Adams

Coonse and Adams originally described the patellar turndown approach in 1943 as an alternative method for exposure of the knee (5). They described an inverted

"Y" incision. In their original method, the quadriceps tendon was split down the middle, beginning at the tendon's proximal pole. This incision was carried to a point 0.25 to 0.5 inch superior to the bony patella. Two limbs were then extended distally from the end of the midline incision, traveling both medially and laterally to the patella (Fig. 66.10). This soft tissue technique allowed the patella and the patellar tendon to be reflected distally and adequate visualization of the knee obtained. The authors emphasized that this method practically eliminated the need for soft tissue retraction, thereby minimizing trauma to the surrounding knee structures. They felt that this technique would be applicable to fractures, synovectomies, and internal derangements of the knee joint. However, because of the extensive dissection inherent in this method, it never achieved widespread, routine use.

There were some specific difficulties with the method originally devised by Coonse and Adams with regard to knee arthroplasty. The original procedure, like all proximal soft tissue procedures, required a broad-based distal flap in order to maintain an adequate blood supply for the extensor mechanism (29). Thus, the surgeon was obliged to choose whether or not to use this technique before beginning the operation. Since the original method could not be converted from a routine exposure, Insall modified their procedure to a more accommodating "patellar turndown."

Patellar Turndown

The patellar turndown approach (modified Coonse-Adams) described by Insall (11) offers several advantages over the original Coonse-Adams technique. Insall's modification may be used at any stage of the operation,

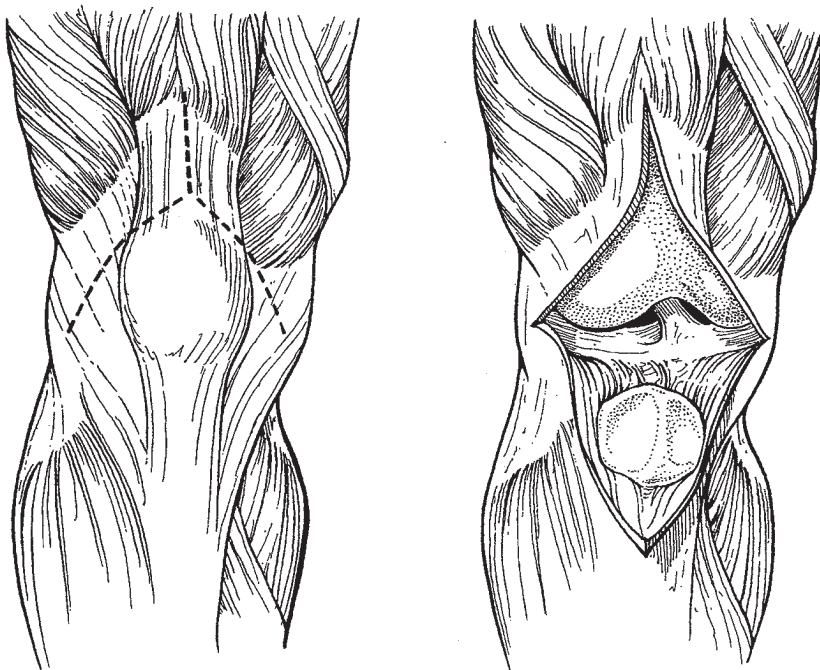
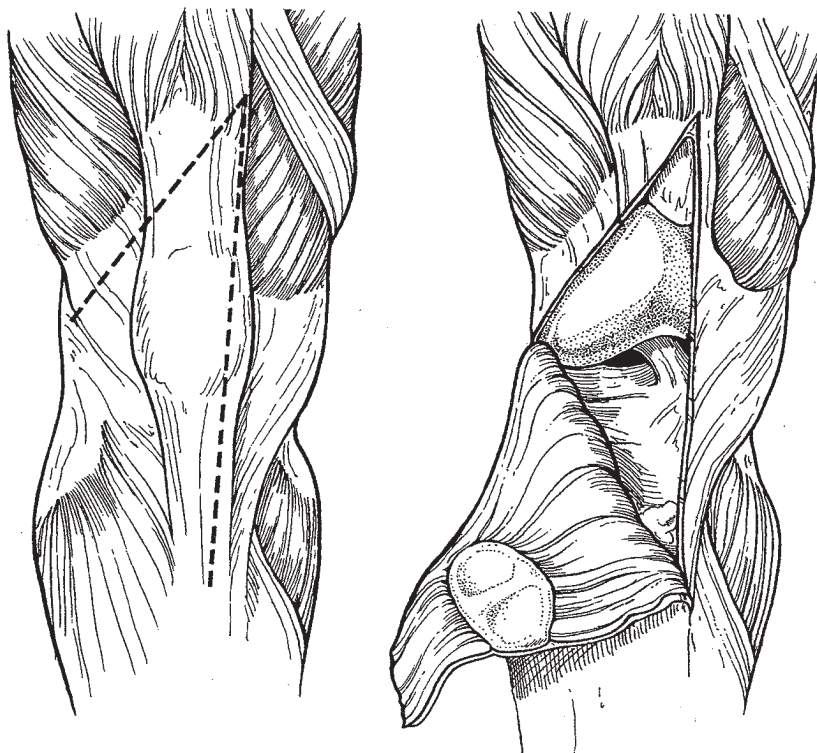


Figure 66.10. The original Coonse-Adams V-Y turn-down technique.

Figure 66.11. The modified Coonse-Adams patellar turndown approach as described by Insall (11). Note that this method commences with the use of a routine midline retinacular arthrotomy. The second quadriceps incision is inclined approximately 45 degrees inferiorly and can be performed at any point if it is needed to enhance exposure.



which commences with a straight anterior skin incision (11). The capsular knee incision is made vertically over the medial aspect of the patella, as in the standard anterior approach (Fig. 66.11). If the surgeon encounters quadriceps tightness or is unable to obtain adequate exposure, a second quadriceps incision is made, inclined approximately 45 degrees to the apex of the first. It is extended laterally and distally through the vastus lateralis and upper portions of the iliotibial tract. Insall describes it as stopping short of the inferior lateral geniculate artery in order to preserve the blood supply. During wound closure, the vertical or medial incision is always repaired. However, the portion of the incision that extends laterally can be left open, if needed, to enhance patella tracking.

Rectus Snip

The patella turndown approach was later modified to a "rectus snip" procedure (26). It was Insall's intent to reduce destruction of the proximal soft tissue envelope. As with the modified Coonse-Adams approach, the initial approach to the knee is made with a standard midline arthrotomy (10). The initial medial arthrotomy is extended distally over the medial aspect of the patella and medial to the patella tendon. If exposure is difficult, it can be enhanced with the "rectus snip" technique (Fig. 66.12). The apex of the quadriceps retinacular incision is extended laterally across the superior portion of the quadriceps tendon into the distal aspect of the vastus lateralis. Lateral mobilization and retraction of the patella and quadriceps tendon can then be accomplished. The arthrotomy is closed with a standard tech-

nique after insertion of the components, and a new, normal postoperative therapy can be instituted.

Results with Proximal Soft Tissue Techniques

Scott and Siliski reviewed the experience at Boston's Brigham and Women's Hospital with the modified V-Y turndown (23). They used this technique in 7 index knee arthroplasties in ankylosed knees. The average preoperative arc of motion was 15 degrees, which improved to a postoperative average of 67 degrees. Postsurgery, the mean flexion contracture was 8 degrees. In this series, only 1 wound complication occurred: a small skin dehiscence in a patient with hemophilia. The wound was resutured and healed. There was 1 poor result in a patient status post five prior lower extremity joint replacements who became nonambulatory after placement in a nursing home.

Aglietti, et al. from Florence, Italy reported their experience with the modified V-Y approach in 1991 (1). They reviewed 16 knees implanted with a posterior cruciate substituting design in which a patellar turndown was utilized. Of the 16 surgeries, 3 were revision procedures, while another 5 were status post prior knee surgery. The average follow-up was 5.5 years. Evaluation of the knees with the Hospital for Special Surgery rating system revealed 6 excellent, 4 good, 5 fair, and 1 poor result. The poor result developed from a late, deep infection. Preoperatively, the arc of knee motion averaged 43 degrees and increased to 74 degrees postsurgery. Flexion contractures decreased from a preoperative average of 25 degrees to a postoperative value of 5 degrees. Extensor lags were seen in 7 cases (47 per-

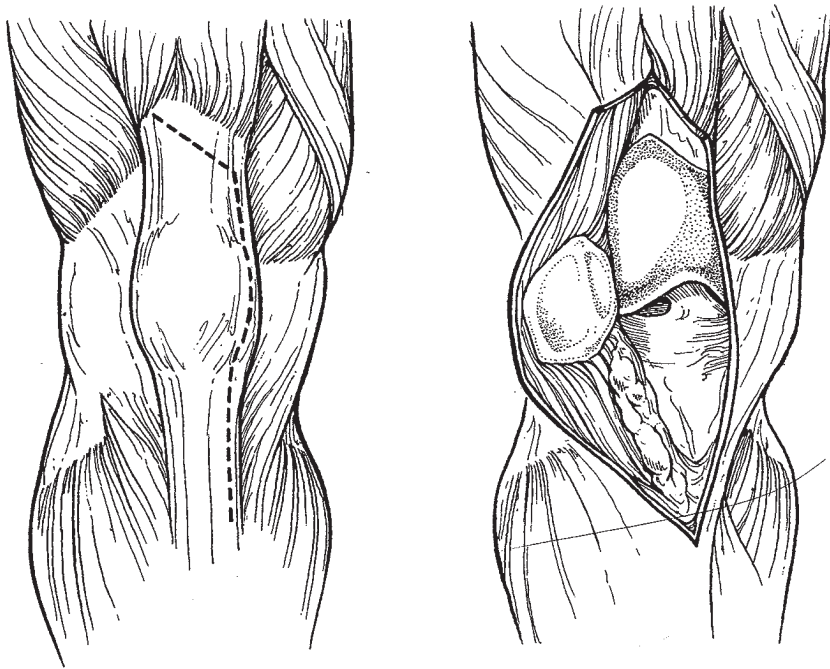


Figure 66.12. The rectus snip approach. As with the modified Coonse-Adams turn-down, this also commences with a routine midline retinacular incision. However, in this approach, the quadriceps retinacular incision is extended laterally across the superior border of the quadriceps tendon in an oblique fashion. As with the modified Coonse-Adams approach, this can be undertaken at any point in the procedure.

cent), and averaged 10 degrees. The authors found no complications that they attributed directly to the V-Y technique. There were no patellar fractures or wound dehiscences. One knee with many previous incisions had skin necrosis that required a graft. Aglietti and colleagues expressed a preference for the V-Y turn-down in difficult knees, because of its success rate and minimal complications. Trousdale, et al. reported on their results with a V-Y quadricepsplasty in 16 total knee arthroplasties (25). There were 10 revision and 6 primary arthroplasties. The average postoperative active range of motion was from 4 to 85 degrees. This represented a mean increase of 12 degrees. Biomechanical testing was carried out in 9 patients. They found a statistically significant weakness in extension in knees with the V-Y quadricepsplasty compared to a normal contralateral knee. When the V-Y quadricepsplasty knees were compared to contralateral knees in which a medial parapatellar incision had been made for arthroplasty, the extensor weakness was still apparent in the V-Y group, but to a lesser degree. They concluded that a V-Y quadricepsplasty would produce near-normal, active extension with moderate weakness. They did not encounter any extensor mechanism necrosis or patella fractures. Because of the low complication rate, satisfactory motion and strength, the authors felt that this technique was safer than tibial tubercle osteotomy for knees that required extraordinary methods of exposure.

Miller, et al. reported on the Hospital for Special Surgery results with the modified Coonse and Adams quadricepsplasty (18), utilizing this technique in 12 revision and 3 primary knee arthroplasties. Follow-up averaged 4 years, when 14 of 15 knees had normal, or 4 of 5, quadriceps strength. They devised a quadriceps score for their knees, finding that 87% of the knees achieved

good or excellent results at follow-up. Extension lags averaged 6 degrees. The authors felt that the arthroplasty results were not compromised by this method of exposure.

Osteotomy of the Tibial Tubercle

Some surgeons advocate osteotomy of the tibial tubercle as a method of achieving surgical exposure in difficult knees. This is especially useful in situations where previous scarring makes eversion of the patella difficult. However, there is concern over the technical difficulties and complications associated with this procedure (24). Conversely, osteotomy offers the potential of bone-to-bone healing and, theoretically, does not jeopardize the patella blood supply. It also offers superior exposure compared with proximal soft tissue techniques.

Procedure

Knees in which a tibial tubercle osteotomy is to be performed are exposed in a standard manner, using previous skin incisions when possible. The tubercle is exposed on both sides (Fig. 66.13). Screw holes that are predrilled facilitate later osteotomy repair (Fig. 66.14). A general attempt is made to retain an adequate lateral periosteal hinge (Fig. 66.15). In Wolff's, et al. report, the length of the osteotomy ranged from 2 to 9 cm (24). However, it is generally felt that a larger tubercle fragment is beneficial. Oscillating saws or osteotomes can be used for the actual osteotomy.

Most surgeons recommend a slight modification in postoperative physical therapy, but range of motion, including use of a continuous passive motion machine, can be instituted. Active extension is avoided for six weeks. The patients wear a knee immobilizer with ambulation or other weight bearing activities.

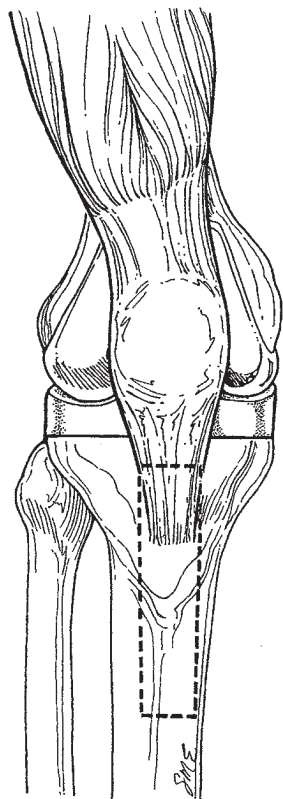


Figure 66.13. Schematic detailing of the area of exposure needed to perform a tibial tubercle osteotomy.

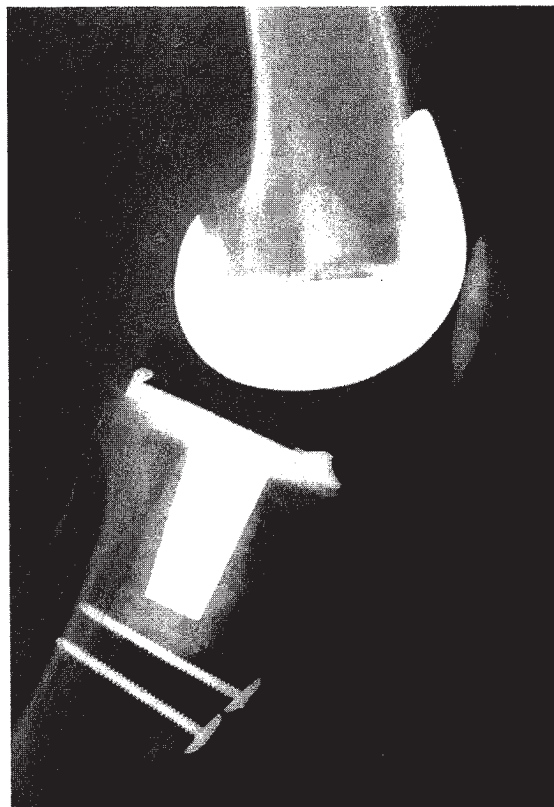
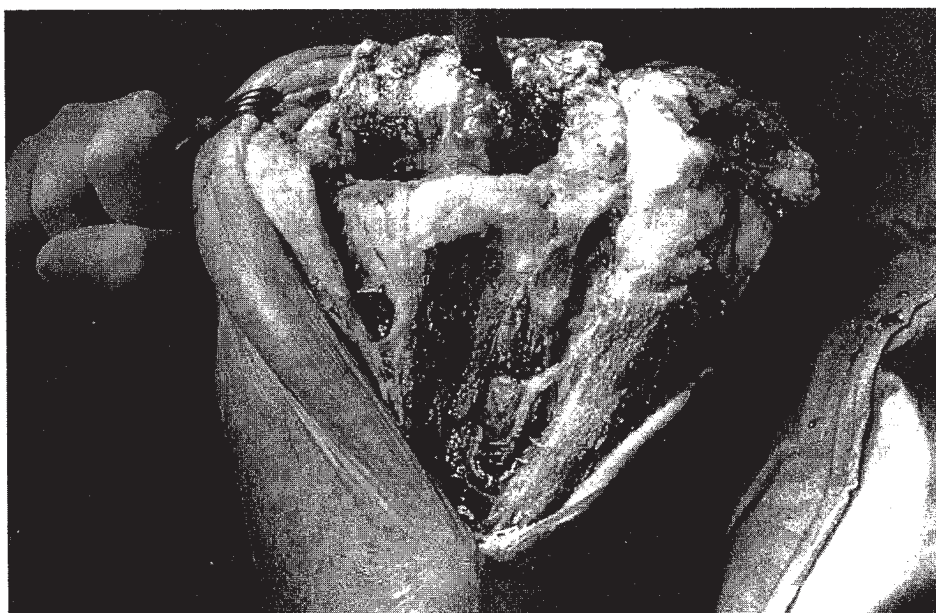

Figure 66.14. Lateral radiograph of a knee in which a tibial tubercle osteotomy was performed with screws utilized for fixation. (Photo courtesy of Richard Wixson, Northwestern University, Chicago, Illinois.)

Figure 66.15. Intraoperative photograph of a tibial tubercle osteotomy. Notice that the osteotomized bone is hinged laterally to aid in exposure. (Photo courtesy of William Brien, M.D., Los Angeles, California.)



Results with Tibial Tubercle Osteotomy

In 1983, Dolin reported on his results with a tibial tubercle osteotomy in 30 patients (6). In his original reports, the osteotomy was approximately 45 mm in length. The tibial tubercle was reattached using a 36 mm cortical screw inserted with a lag effect into a threaded hole in the tibial bone cement. The only complication was a partial perforation of the anterior proximal tibial cortex because of excessive thickness of the osteotomy. He stated in his report that the technique allowed early physical therapy to be administered. In addition, all patients could move the knee and bear weight within a week of surgery. He did not report any failures of fixation or nonunions.

Wolff, et al. reported on the results with a tibial tubercle osteotomy in 26 knees (6). They found complications in 35% of the knees. Six knees (23 percent) had major nonmechanical complications ranging from superficial skin necrosis to deep infections or deep wound necrosis requiring a gastrocnemius flap. Fifteen percent of knees (note: 1 knee had both mechanical and nonmechanical complications) had major mechanical complications ranging from displacement of the osteotomized segment to patellar tendon rupture. The complication rate was higher in patients with rheumatoid arthritis. The authors found higher rates of osteotomy union with two cortical lag screws and recommended long osteotomy segments to minimize stress concentrations in the osteotomized bone.

Whiteside and Ohl reported on tibial tubercle osteotomy for difficult knee replacements in 71 knees (27). This included 54 revisions, 10 procedures for lysis of adhesions, 3 for primary total knees in patient status post patellectomy, and 4 for exposure of primary total knee arthroplasty in patients with quadriceps contracture. Their technique requires careful attention to detail. They stressed the need to take a long, thick segment of the anterior tibial crest, which was elevated with the tubercle. They further suggested an oscillating saw to transect the tibial crest between 8 and 10 cm below the tubercle. A curved osteotome was used to separate the crest and tubercle finally from the underlying host tibial bed. The lateral periosteal and muscular attachments should remain fixed to the elevated bone. The bone was reattached with two heavy gauge cobalt chromium wires that were passed through the lateral edge of the tibial tubercle fragment and through the medial tibial cortex. Early motion and full weight bearing were allowed within the first week of surgery. The authors reported no failures with this technique. None of their tibial tubercles fractured or pulled loose. In significant contrast to the report from Wolff, et al., Whiteside and Ohl concluded that the higher success rate of their patients was the result of the longer fragment of osteotomized bone in their series. They pointed out that the failures in Wolff's series involved smaller tibial tubercle ostomies. Whitesides and Ohl preferred the osteotomy technique to proximal soft tissue releases, because secure fixation could be achieved with heavy wire loops passed through bone. They contrasted this to

repair that is achieved with proximal procedures, in which sutures are passed through soft tissue to resist tension failure.

Osteotomy and Transfer of the Tibial Tubercle

An alternative method of a tibial tubercle osteotomy has been suggested by Masini and Stulberg wherein the osteotomized tubercle is actually transferred medially and placed in a new bone bed (16). Proponents of this technique feel that it can be utilized for distal realignments or difficult exposures in either complex primary or revision knee arthroplasties. In their technique, thick medial and lateral soft tissue flaps must be preserved. A fixation of the long strip of tibial crest is achieved with bone staples that do not penetrate the graft.

A standard midline or medial parapatellar approach may be used for this technique. Dissection is extended distally along the tibial crest to approximately 15 cm inferior to the tubercle. Great care is taken to maintain full thickness soft tissue sleeves. On the medial side, the subperiosteal dissection is carried to the posterior margin of the tibia. Laterally, the full thickness soft tissue sleeve is extended to the lateral margin of the tibial tubercle.

At this point, a standard medial retinacular incision is made, as well as a complete lateral release. The lateral retinacular is released from outside to inside. The region for a rectangular osteotomy is then defined along the anterior tibial cortex. The osteotomized bone should be a 1.5 by 10 cm rectangle created with a drill and osteotome or an oscillating saw. The medial tibia is decorticated with a high speed burr to create a cancellous bone bed that will accommodate the osteotomized fragment.

After the arthroplasty is accomplished, the tibial tubercle is transferred into the medial cancellous bone bed. The osteotomized bone segment is secured with multiple staples (16 by 10 mm) implanted with a power stapler. Care is taken to place the staples over, but not into, the osteotomy segment. After stable fixation is ensured, the soft tissue flaps are reattached via sutures passed either through drill holes or anchored into bone, utilizing Mitek or Statak. Advocates of this technique feel that excellent soft tissue coverage can be obtained because the bone segment is inset into a cancellous bone bed and not elevated as with a Macquet procedure. Cast immobilization is recommended for 6 weeks post-surgery to reduce complications. One case been reported with this technique.

References

1. Aglietti P, Buzzi R, D'Andria S. Quadricepsplasty with the V-Y incision in total knee arthroplasty. *Ital J Orthop Traum* 1991;17(1):23-29.
2. Boiardo RA, Dorr LD. Surgical approaches for total knee replacement arthroplasty. *Contemp Orthop* 1986;12:60.
3. Bramlett KW. Trivector arthrotomy for total knee arthroplasty. *American Academy of Orthopaedic Surgeons, Poster Exhibit*. San Francisco, CA, February, 1993.
- 3a. Buechel FF. A sequential three-step lateral release for correcting fixed

- valgus knee deformities during total knee arthroplasty. *Clin Orthop* 1990;260:170.
4. Cameron HU, Fedorkow DM. The patella in total knee arthroplasty. *Clin Orthop* 1982;165:197.
 5. Coonse K, Adams JD. A new operative approach to the knee joint. *Surg Gynecol Obstet* 1943;77:344.
 6. Dolin MG. Osteotomy of the tibial tubercle in total knee replacement. *J Bone Joint Surg* 1983;65A:704.
 7. Erkes F. Weitere Erfahrungen mit physiologischer Schnittführung zur Eröffnung des Kniegelenks. *Brunns' Beitr zur Klin Chir* 1929;147:221.
 8. Gustke KA. Southern approach for total knee replacement. *Florida Orthop Soc J* 1989;31.
 9. Hoffman AA, Plaster RL, Murdock LE. Subvastus (Southern) approach for primary total knee arthroplasty. *Clin Orthop* 1991;269:70.
 10. Insall JN. A midline approach to the knee. *J Bone Joint Surg* 1971;53A:1584.
 11. Insall JN. Surgical approaches to the knee. In: *Surgery of the Knee*. New York: Churchill Livingstone, 1984:41.
 12. Johnson DP, Houghton TA, Radford P. Anterior midline or medial parapatellar incision for arthroplasty of the knee. A comparative study. *J Bone Joint Surg* 1986;68B:812.
 13. Kayler DE, Lyttle D. Surgical interruption of patellar blood supply by total knee arthroplasty. *Clin Orthop* 1988;229:221.
 - 13a. Keblish PA. The lateral approach to the valgus knee: Surgical technique and analysis of 53 cases with over two-year follow-up evaluation. *Clin Orthop* 1991;271:52.
 14. Kim JM. Orthopedic surgery in Korea. Quadriceps dislocation medial approach for intra-articular and medial structures of the knee. *Orthopaedics* 1991;14:1147.
 15. Krakow KA. The technique of total knee arthroplasty. St. Louis: CV Mosby, 1990:168-197.
 16. Masini MA, Stulberg SD. A new surgical technique for tibial tubercle transfer in total knee arthroplasty. *J Arthroplasty* 1992;7(1):81-86.
 17. Merkow RL, Soudry M, Insall JN. Patellar dislocation following total knee replacement. *J Bone Joint Surg* 1985;67:1321.
 18. Miller DV, Insall JN, Urs WK, Windsor RE. Quadricepsplasty in total knee arthroplasty. *Orthop Trans* 1988;12(3):706.
 19. Mochizuki RM, Schurman DJ. Patellar complications following total knee arthroplasty. *J Bone Joint Surg* 1979;61A:879.
 20. Mullen JO. Range of motion following total knee arthroplasty in ankylosed joints. *Clin Orthop* 1983;179:200.
 21. Rand JA, Morrey BF, Bryan RS. Patellar tendon rupture after total knee arthroplasty. *Clin Orthop* 1989;244:233.
 22. Ritter MA, Keating EM, Faris PM. Comparison of two anterior medial approaches to total knee arthroplasty. *Am J Knee Surg* 1990;3(4):168.
 23. Scott RD, Siliski JM. The use of a modified V-Y Quadricepsplasty during total knee replacement to gain exposure and improve flexion in the ankylosed knee. *Orthopaedics* 1985;8(1):45-48.
 24. Scuderi GR, Windsor RE, Insall JN. Observations on patellar height after proximal tibial osteotomy. *J Bone Joint Surg* 1989;71(2):245-248.
 25. Trousdale RT, Hanssen AD, Rand JA, Cahalan TD. V-Y quadricepsplasty in total knee arthroplasty. *Clin Orthop* 1993;286:48-55.
 26. Vince KG. Revision arthroplasty technique. Instructional course lectures. In: Heckman J, ed. *Total Joint Arthroplasty*. Rosemont IL: American Academy of Orthopaedic Surgeons, 1993:325-339.
 27. Whiteside LA, Ohl MD. Tibial tubercle osteotomy for exposure of the difficult total knee arthroplasty. *Clin Orthop* 1990;260:6-9.
 28. Windsor RE, Insall JN. Exposure in revision total knee arthroplasty: The femoral peel. *Techn Orthop* 1988;3(2):1-4.
 29. Wolff AM, Hungerford DS, Krackow KA, Jacobs MA. Osteotomy of the tibial tubercle during total knee replacement. A report of twenty-six cases. *J Bone Joint Surg* 1989;71A:848.