

Clinical Orthopaedics and Related Research

MARSHALL R. URIST

Editor-in-Chief

With the Assistance of

THE ASSOCIATE EDITORS

THE BOARD OF ADVISORY EDITORS

THE BOARD OF CORRESPONDING EDITORS



Number Two Hundred Sixty-Nine



J. B. LIPPINCOTT COMPANY

Philadelphia

S&N EXHIBIT 1036

S&N v. BSI

IPR2013-00629

CLINICAL ORTHOPAEDICS AND RELATED RESEARCH GUIDELINES FOR AUTHORS

CLINICAL ORTHOPAEDICS AND RELATED RESEARCH is designed for the publication of original articles offering significant contributions to the advancement of orthopedic knowledge. Articles are accepted only for exclusive publication in CLINICAL ORTHOPAEDICS AND RELATED RESEARCH; published articles and their illustrations become the property of CLINICAL ORTHOPAEDICS AND RELATED RESEARCH.

- **TO COVER COSTS** of postage and other overhead expenses, contributors should send a check for \$50.00 (U.S.), \$75.00 (other countries), with each unsolicited manuscript to CLINICAL ORTHOPAEDICS AND RELATED RESEARCH, UCLA Bone Research Laboratory, 1000 Veteran Ave., A340, Los Angeles, CA 90024.

- **ORGANIZE YOUR MANUSCRIPT** as follows: Abstract; Introduction; Materials and Methods; Results; Discussion. A section in Materials and Methods should identify the name and location of the manufacturer of specific prostheses, apparatuses, chemicals, medications, materials, and equipment.

- **THE ACCURACY OF THE INFORMATION** and of the citations of literature is the sole responsibility of the author(s).

- **AUTHORS ARE NOT ENCOURAGED** to submit articles in series, e.g., "Part I: Fractures of the Hip; Part II: Complications of Fractures of the Hip; Part III: etc."

- **THE ABSTRACT** should consist of a *one paragraph* statement less than 200 words in length, stating the main conclusions without reference to any other part of the manuscript. The abstract must be independently understood for reproduction by libraries and other publications as a separate entity.

- **ALPHABETIZE AND NUMBER REFERENCES.** A bibliography of numbered references in alphabetical order should be attached to the manuscript. Each reference must be cited in the text by number. Follow exact style of references published in this copy of CLINICAL ORTHOPAEDICS AND RELATED RESEARCH. Each reference must list *all* coauthors.

- **ALL TABULAR MATERIAL OR STATISTICAL DATA** must be in the form of clear tables, placed one to a page, at the end of the manuscript. Tables must be titled, numbered, and cited in the text in numerical order.

- **INCLUDE A SHEET OF LEGENDS DESCRIBING ILLUSTRATIONS.** A separate sheet of typed legends (captions) describing *each* illustration should be attached to the manuscript.

- **SEND FOUR SETS OF UNMOUNTED BLACK AND WHITE GLOSSY PRINTS** approximately 5" x 7" for all figures, for reviewers' use. Original drawings and X-rays must be of professional quality and photographed as black and white glossy prints. Do not make a montage. Submit your figures unmounted and separated. Do not write on the face of illustrations; put as much information as possible in the legends. If arrows or letters are necessary, use a professional product such as Letraset or Paratype. Attach a label to the backs of illustrations indicating "top," figure number, and author's name, or enter this information lightly with a pencil. Each figure must be cited in the appropriate place in the text in numerical order. Submit the minimum number

of figures and tables necessary to highlight the article. The publisher reserves the right to charge for illustrations and tables in excess of one page of illustrations, including tabular material, per four pages of printed text.

- **LETTERS OF PERMISSION** from the publisher of any borrowed illustration or table should be enclosed with the manuscript. Acknowledgment of the sources must also be included at the end of the legend for borrowed illustrations and as a footnote to the table of any borrowed tabular material.

- **SEND THE ORIGINAL TYPESCRIPT AND THREE DUPLICATES.** Manuscripts must be in English, typed double-spaced on one side of 8½" x 11" paper with wide margins and pages numbered. Authors should retain copies of manuscripts and illustrations. Page 1 of the manuscript should be a cover (title) page listing the title of the article and authors' names and degrees, and page 2 should include a complete reprint address.

- **SEND A LETTER OF TRANSMITTAL SIGNED BY ALL AUTHORS** containing the following paragraph: "In consideration of CLINICAL ORTHOPAEDICS AND RELATED RESEARCH reviewing and editing my (our) submission, the author(s) undersigned hereby transfer(s), assign(s), or otherwise convey(s) all copyright ownership to CLINICAL ORTHOPAEDICS AND RELATED RESEARCH, and represent(s) that he (they) own(s) all rights in the material submitted. This assignment is to take effect only in the event that such work is published in CLINICAL ORTHOPAEDICS AND RELATED RESEARCH."

- **CLINICAL ORTHOPAEDICS AND RELATED RESEARCH** will expedite publication of selected manuscripts. To qualify for accelerated publication, the work must be judged to be of exceptional significance and immediate interest. Such manuscripts must be labelled "FOR EXPEDITED PUBLICATION," contain the elements of a regular manuscript, and satisfy the criteria governing the publication of papers in CO&RR *but must not exceed 12 manuscript pages* (excluding illustrations, tables, and references). The manuscript must be accompanied by a transmittal letter giving the reasons why the authors believe the work justifies expedited publication and the names of at least three knowledgeable surgeons who will immediately return the manuscript with an impartial, detailed review. Except for minor revisions, such manuscripts will be either accepted or rejected within four to eight weeks. The aim is to publish an expedited paper within six months after submission. The number of expedited publications is limited to one per issue.

- **REPRINTS.** The publisher will provide the reprint author, free of charge, with 50 reprints of his article. If additional reprints are desired, they may be ordered on the order form furnished with page proofs.

Following are the subjects of Symposia to be published in forthcoming numbers:

Newest Knowledge of Osteosarcoma
Newest Knowledge of Total Knee Arthroplasty
Advances in Poland

Copyright © 1991, BY J. B. LIPPINCOTT COMPANY
Library of Congress Catalog Card Number 53-7647

CLINICAL ORTHOPAEDICS AND RELATED RESEARCH (ISSN 0009-921X) is published monthly by J. B. Lippincott Company, at 100 Insurance Way, Suite 114, Hagerstown, MD 21740. Business offices are located at East Washington Square, Philadelphia, PA 19105. Printed in the U.S.A. © Copyright 1991 by J. B. Lippincott Company. All rights reserved. Second class postage paid at Hagerstown, MD, and at additional mailing offices.

Subscription information, orders or changes of address: (except Japan) 100 Insurance Way, Suite 114, Hagerstown, MD 21740, or call 1-800-638-3030; in Maryland, call collect 301-824-7300. In Japan, contact USACO Corporation, 13-12, Shimbashi 1-chome, Minato-ku, Tokyo 105, Japan. In India, Nepal, Bangladesh, and Sri Lanka, contact Universal Subscription Agency Pvt. Ltd., 101-102 Community Centre (F.F.) Saket, New Delhi-110017, India.

Annual subscription rates: U.S. \$225.00 individual, \$325.00 institution; all other countries except Japan, India, Nepal, Bangladesh, and Sri Lanka, \$275.00 individual, \$375.00 institution. Resident rate, U.S.: \$125.00, Canada: \$160.00. Single copies \$35.00. Rates for airmail delivery available upon request. Japan: 81,800 yen individual, 103,800 yen institution (includes airmail postage). Copies will be replaced without charge if the publisher receives a request within 60 days of the mailing date in the U.S. or within 5 months in all other countries.

Indexing: Articles are indexed in Biological Abstracts, Chemical Abstracts, Excerpta Medica, Index Medicus, Science Citation Index, Current Contents, Hospital Literature Index, Social Sciences Citation Index, and BRS.

POSTMASTER: Send address changes to CLINICAL ORTHOPAEDICS AND RELATED RESEARCH, P.O. Box 1550, Hagerstown, MD 21740.

Subvastus (Southern) Approach for Primary Total Knee Arthroplasty

AARON A. HOFMANN, M.D., RODNEY L. PLASTER, M.D., AND LOUIS E. MURDOCK, M.D.

The subvastus or Southern approach to the knee had been described as early as 1929 but is not found in standard modern orthopedic textbooks. This approach for primary total knee arthroplasty (TKA) preserves the integrity of the extensor mechanism and maintains the vascular supply to the patella. To appreciate the potential benefits of this approach, a complete understanding of the surgical anatomy is essential. The benefits of the subvastus approach make it a valuable technique for primary TKA.

During the early development of TKA, the medial parapatellar arthrotomy became the standard extensile incision. This approach provides excellent exposure and is associated with a very low incidence of tibial or femoral complication.¹⁰ However, patellofemoral complications occur at a rate of 5% to 30%.^{13,15,16} These complications include subluxation, dislocations, and avascular induced fracture of the patella.^{5,7,17,18,22,24} These complications may be related to the surgical exposure. To help prevent such complications, a more anatomic approach is advocated in the form of the subvastus medial approach (Fig. 1).

The subvastus medial arthrotomy provides excellent exposure for TKA while preserving

the extensor mechanism. The vascularity to the patella and extensor mechanism can be maintained even when coupled with a lateral retinacular release. It is believed that this dissection technique is associated with less postoperative pain and a stronger extensor mechanism,¹¹ and the possibility of vastus medialis obliquus (VMO) disassociation and dehiscence postoperatively is eliminated.⁷ Evaluating patellar tracking intraoperatively after implantation of components is easy because towel clips or the thumb test are unnecessary.

Although these advantages would make the subvastus approach very attractive, very little has been written about it. It first appeared in the German literature in 1929⁹ and later was described in 1945 as an oblique medial arthrotomy with the proximal limb using the subvastus route.^{1,28} Indications were for limited procedures on the medial side of the joint although the patella was subluxated to view the anterior joint. In the 1970s, a variation of the same approach was recommended for patellofemoral prosthetic replacement by Bechtol.³ More recently, others have utilized it for unicompartmental replacements or total condylar replacements in selected individuals.^{11,19}

The subvastus approach is not found in standard orthopedic texts or surgical approach manuals.^{6,8,12} The purpose of this report is to describe the surgical anatomy, surgical approach, and indications for this exposure.

From the Division of Orthopedic Surgery, University of Utah Medical Center, Salt Lake City, Utah.

Reprint requests to Aaron A. Hofmann, M.D., Division of Orthopedic Surgery, 50 North Medical Drive, Salt Lake City, Utah 84132.

Supported by the Veterans Affairs Medical Center, Salt Lake City, Utah.

Received: June 11, 1990.

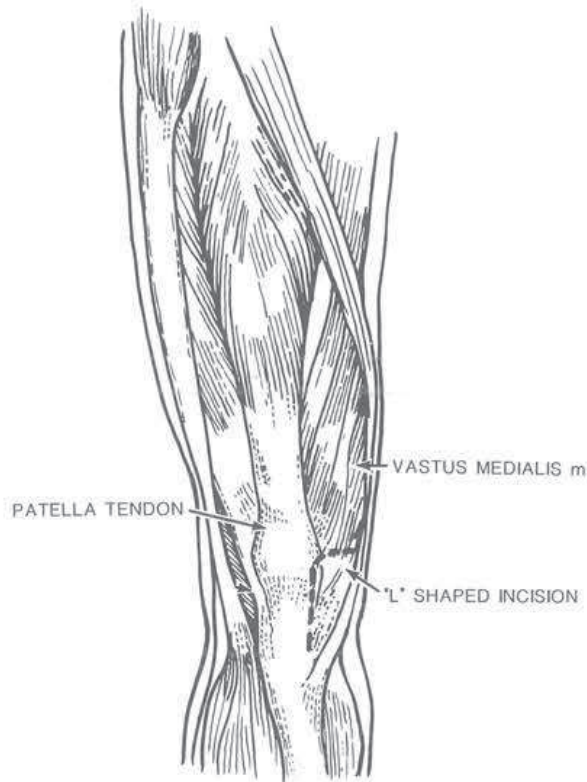


FIG. 1. L-shaped deep capsular incision used in the subvastus approach.

SURGICAL ANATOMY

A straight anterior midline skin incision is utilized. The first deep layer to be encountered is the superficial fascial layer I that is the continuation of the deep fascia of the thigh, deep to the adipose layer.²⁹ It is well-defined proximally and can be separated from the thinner fascia covering the vastus medialis muscle proper. Inferiorly, this layer blends with fibrous tissue derived from the vastus medialis to form the medial patellar retinaculum.¹² The surgical approach will be deep to the superficial fascial layer and under the muscle belly of the VMO.

The vascularity to the patella has been shown to be dependent on six major vessels: the articular branch of the descending genicular, the paired superior and inferior geniculates, and the anterior tibial recurrent (Figs. 2A and 2B). These anastomose to form an arterial circle or patellar plexus that supplies

the patella by two intraosseous systems: (1) midpatellar vessels on the anterior surface of the patella and (2) a polar system that enters the patella inferiorly between the patella tendon and the articular surface (Fig. 3).^{2,23,27} There are minor vessels entering the patella through the quadriceps tendon.⁴

Important to the subvastus approach is the articular branch of the descending geniculate (also called the supreme geniculate). This vessel lies within the belly of the vastus medialis and joins the anastomotic ring with the medial superior geniculate at the superomedial corner of the patella. This portion of the superior ring and the midpatellar vessels lies in the dense connective tissue superficial to the patella, whereas the inferior portion of the ring is deep to the patella tendon.²³

Innervation of the vastus medialis is derived from a branch of the femoral nerve (Fig. 4). This motor branch parallels the saphenous sensory nerve in the proximal thigh before piercing the vastus medialis in the proximal to middle third of the muscle belly. The saphenous nerve continues in the intermuscular septum and may or may not enter the adductor canal before exiting between the sartorius and gracilis.

SURGICAL APPROACH

A general or spinal anesthetic with complete motor block is recommended. The limb is exsanguinated and the tourniquet inflated with the knee flexed to 90° to avoid any tenodesis effect on the extensor mechanism. With the knee flexed to 90° or more, a direct anterior midline skin incision is utilized beginning approximately four finger breadths above the patella. The inferior portion of the incision continues one finger breadth distal to and just medial to the tibial tubercle. This slightly longer incision is required to avoid any skin tension. Making the skin incision with the knee in flexion centers the incision over the patella and allows the tissues to separate as the incision is deepened, allowing eas-

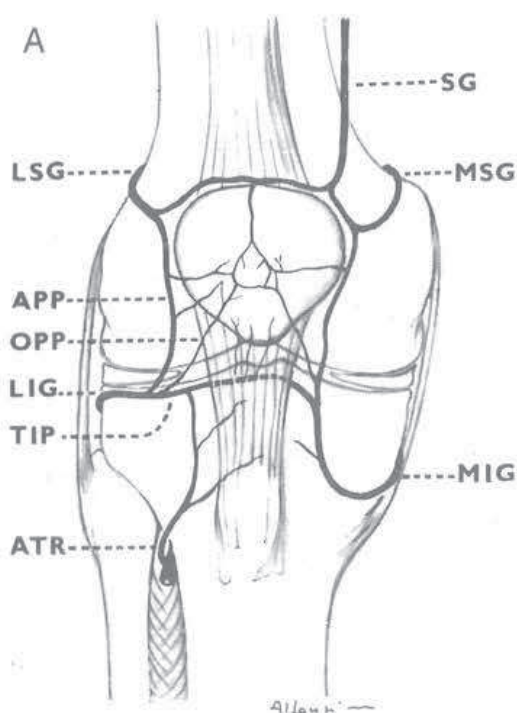
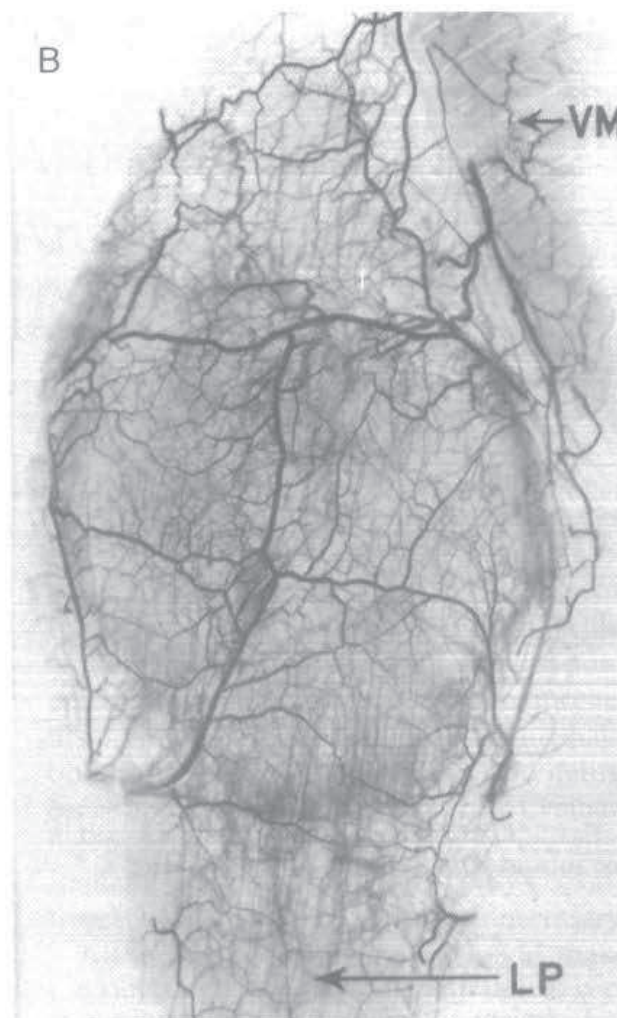

Diagram of the main vessels contributing to the supply of the patella. SG=supreme genicular artery. MSG=medial superior genicular artery. MIG=medial inferior genicular artery. LSG=lateral superior genicular artery. APP=ascending prepatellar artery. OPP=oblique prepatellar artery. MIG=medial inferior genicular artery. TIP=transverse infrapatellar artery. ATR=anterior tibial recurrent artery.



FIGS. 2A–2B. The vascular ring supplying the patella. (Reprinted with permission from R. Scapinelli and J. Bone Joint Surg.) (B) The extraosseous vascular ring supplying the patella. VM, vastus medialis; LP, ligamentum patella. (Technique: Injection of Micropaque Suspension. Reprinted with permission from R. Scapinelli and J. Bone Joint Surg.)

ier identification of fascial layers without the use of skin retractors.

Fascial layer I is identified proximally and incised in line with the skin incision. At the level of the patella, it is incised slightly medially to prevent injury to the prepatellar plexus of vessels that can interrupt intraosseous flow.^{5,14} Beginning proximally, a finger is utilized to bluntly raise the fascial layer I off the thinner perimuscular fascia of the vastus medialis down to its insertion site (Figs. 5A and 5B). The inferior edge of the vastus is identified and the muscle is lifted off the periosteum and intermuscular septum

with blunt finger dissection for a distance of approximately 10 cm proximal to the adductor tubercle. Occasionally, a small vein is found entering the vastus distally and coagulated.

The descending genicular artery and saphenous nerve are not in danger of injury when blunt dissection is used to raise the vastus medialis off the intermuscular septum. By tensing the vastus medialis muscle belly anteriorly (Fig. 6), the two to three centimeter wide tendinous insertion of the vastus medialis to the medial capsule is identified and transversely incised about midpatella by

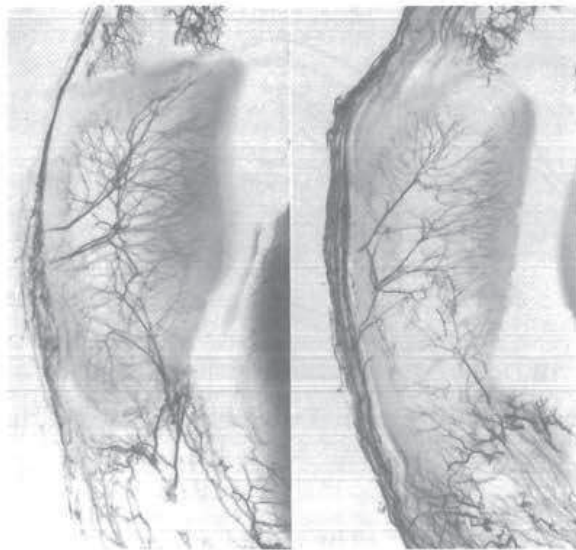


FIG. 3. Two patellae in sagittal section to show the large vessels that enter through foramina situated in the middle third of the anterior surface and in the lower pole behind the ligamentum patella. (Reprinted with permission from R. Scapinelli and J. Bone Joint Surg.)

lightly touching the scalpel to its fibers (Fig. 7). Care is taken to avoid incising the synovium. The rest of the vastus medialis remains attached to the patella and quadriceps tendon.

Lifting the extensor mechanism anterior and lateral allows a curvilinear medial arthrotomy to be made beginning in the suprapatellar pouch and ending at the tibial tubercle (Fig. 8). Incising along the medial edge of the patellar fat pad minimizes bleeding. Sharp soft-tissue release from the proximal tibia is performed. Partial release of the patellar tendon is avoided to decrease the risk of avulsion. The patella is everted and dislocated laterally with the knee in full extension. The knee is slowly flexed while the vastus medialis muscle belly is bluntly dissected off the intermuscular septum more proximally to avoid over stretching of the vastus and excessive tension on the patellar tendon insertion (Fig. 9).

After preparing the knee and applying the components, patellar tracking should be visualized by reducing the patella and placing the

knee through flexion and extension. Because the extensor mechanism is still intact, tracking can be easily determined by observing the patella through the inferomedial window. Any subluxation or tilting of the patella is

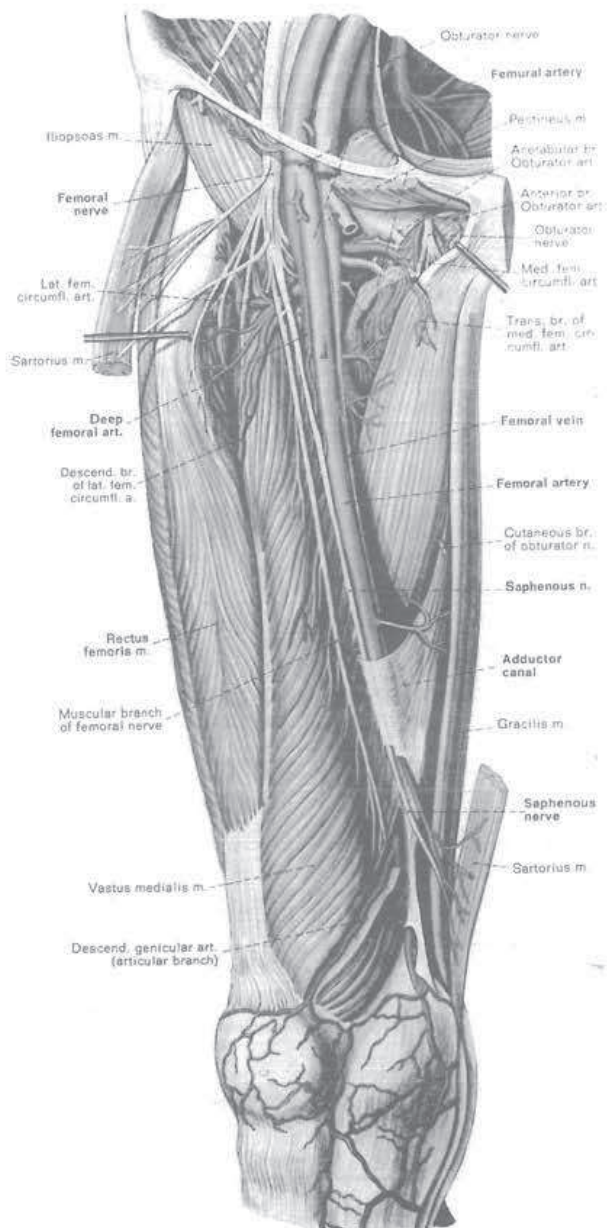
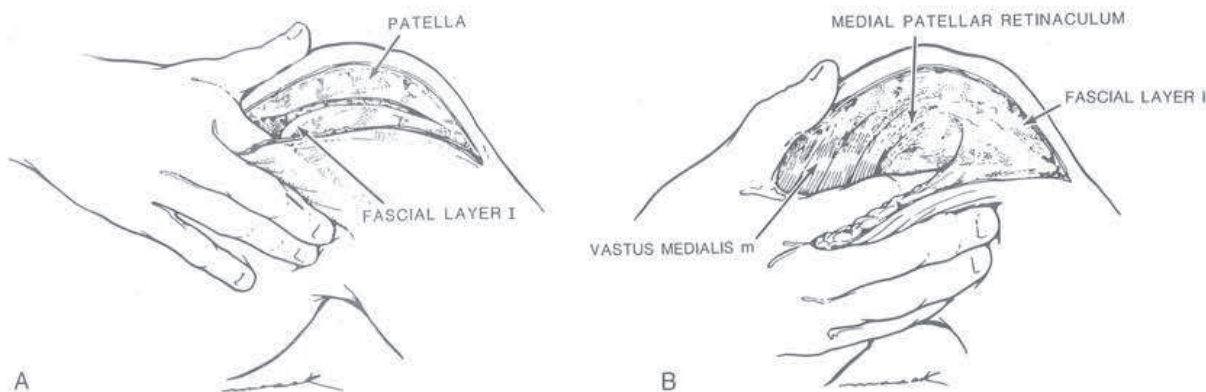


FIG. 4. The muscular branch of the femoral nerve enters the muscle belly proximal to the surgical approach. (Reprinted from Clemente, C.D., Clemente Anatomy, ed. 3, Urban & Schwarzenberg, Baltimore-Munich, 1987, by permission of the publisher.)



FIGS. 5A AND 5B. (A) Layer I is identified proximally first. (B) Layer I is bluntly elevated off the perimuscular fascia of the VMO down to its insertion site.

unacceptable and requires at least a partial lateral release.

If a lateral release is needed, it is performed from outside in, with the knee in full flexion. Fascial layer I is bluntly dissected off the lateral retinaculum. The release is titrated to involve only the portion of the lateral capsule that is tight to palpation or visualization. This frequently leaves the synovium intact. A complete release is rarely needed. The recurrent anterior tibial vessels and usually the lateral inferior geniculate are avoided when the release is made at least 1.5 cm lateral to the patella.^{6,14,16}

The wound is drained and closure accomplished with absorbable suture. The capsule layer of the proximal limb of the incision can

best be identified by applying medial soft-tissue tension with a blunt retractor (Fig. 10). The L-shaped capsular incision is closed with a suture at the apex and two sutures reattaching the vastus medialis tendon insertion (proximal limb of the L) to the medial retinaculum. No reattachment of the muscle belly to the intermuscular septum is required. Distally, the capsule is closed with interrupted sutures. The superficial fascial layer I is closed separately with a few simple interrupted sutures to cover the vastus medialis muscle belly. Subcutaneous and skin closure is routine and performed with the knee partially flexed to ensure proper approximation and tension. A compressive Jones dressing is applied and a continuous

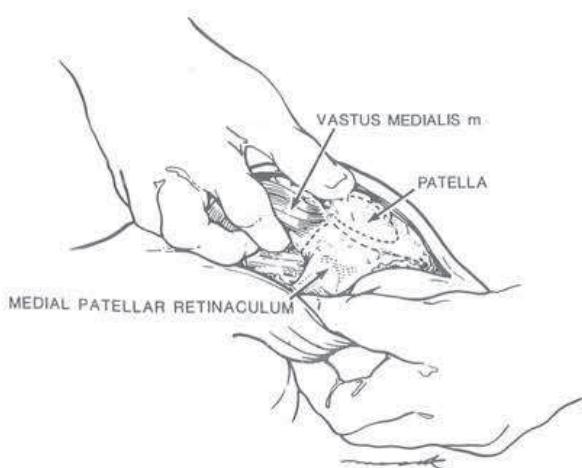


FIG. 6. Teasing the muscle belly anteriorly identifies the tendinous insertion to the medial patellar retinaculum.

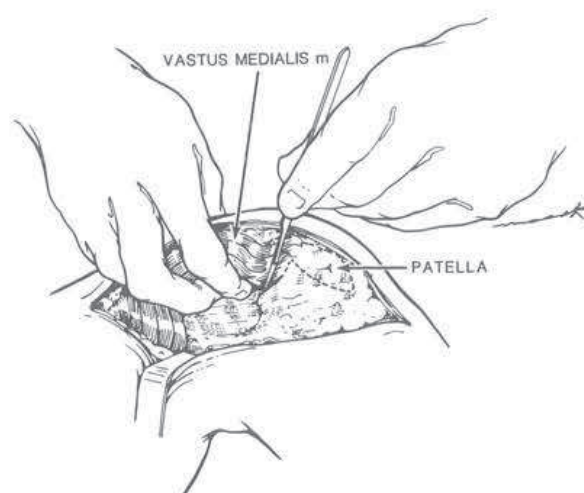
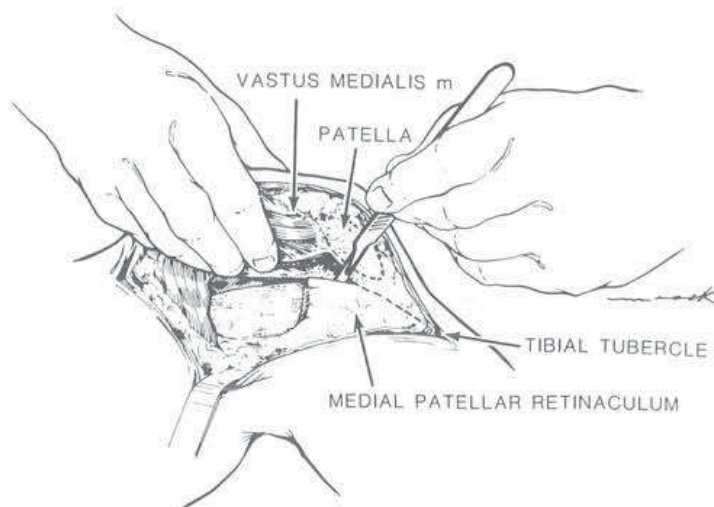


FIG. 7. The transverse limb of the capsular incision is made with the muscle belly under tension.

FIG. 8. The arthrotomy is performed by incising synovium proximally and capsule distally.



passive motion machine is initiated in the recovery room from 0° to 30°. It has been the authors' experience that patients can usually initiate straight leg raises by 24 hours. The compressive dressing is removed at 72 hours and routine active and passive exercises are performed.

DISCUSSION

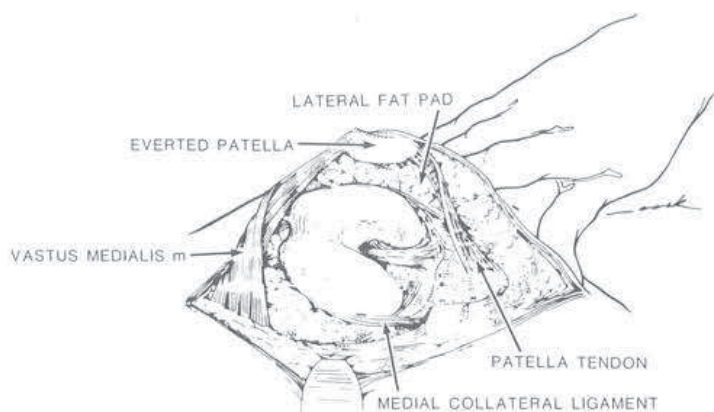
Experience with the subvastus (Southern) approach for primary TKA has proven it to be a very rapid anatomical approach producing equivalent exposure for femoral, tibial, and patellar preparation when compared to the parapatellar approach. Leaving the extensor mechanism intact appears to be a natural solution to the vascular and tracking problems of the patella.

Leaving the extensor mechanism intact has the distinct advantage of allowing the sur-

geon to more accurately judge patellar tracking and titration of a lateral release. Towel clip approximation of the vastus or thumb pressure to maintain patella tracking is unnecessary. Because of inherent stability of the patellofemoral joint, there is no likelihood of dehiscence of the arthrotomy that may contribute to patellar subluxation. If skin problems, such as infection, were to occur, the full thickness of the vastus medialis is protecting deeper structures. Closure of the described approach is anatomic and avoids the possibility of excess medial reefing.

Several authors have evaluated the problem of lateral release combined with medial parapatellar arthrotomy.^{4,21,25,30} Scuderi²⁵ reported a cold patella on technetium scan after medial parapatellar arthrotomy in 56% of patellas following arthroplasty with lateral release, as compared to 15% of patellar arthroplasty without lateral release. The stan-

FIG. 9. The patella is everted and the knee slowly flexed.



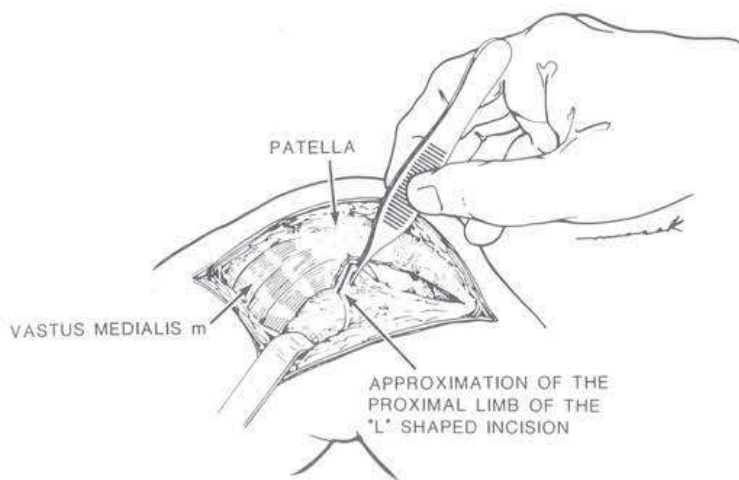


FIG. 10. The proximal limb of the capsular incision is best identified with medial soft tissue tension. A corner stitch is placed first to anatomically reapproximate the capsule.

Standard medial parapatellar arthrotomy separates the vastus medialis from the patella by the intratendinous incision resulting in loss of vascular supply by the medial vessels, which include the descending geniculate, medial superior geniculate, and the medial inferior geniculate.¹⁴ Further vascular compromise may occur if lateral retinacular release transects the lateral inferior geniculate and lateral superior arteries and possibly the recurrent anterior tibial vessel.²⁶ Injury to the inferior geniculate artery during the lateral meniscectomy may occur.³⁰ This vessel is often seen and coagulated as it passes deep to the fibular collateral ligament anterior to the popliteus hiatus at the lateral meniscal rim. By leaving the vastus medialis attached to the rest of the extensor mechanism, the descending geniculate artery is preserved as a principal blood conduit to the superior portion of the patellar vascular network. The recurrent anterior tibial artery may be maintained to contribute to the inferior portion of the ring even if the lateral superior and inferior arteries are lost in the lateral release. The lateral inferior geniculate artery may be preserved if the release does not go too inferiorly and if the rim of the lateral meniscus is preserved during meniscectomy. When a maltracking patella requires a lateral retinacular release, more patellar arterial blood may be preserved by the subvastus approach than by a lateral release combined with medial parapatellar arthrotomy.

Fat pad resection is avoided and is not required for exposure. Dissection between the patellar tendon, fat pad, and inferior pole of the patella are kept to a minimum to prevent injury to the inferior pole vessels.^{14,20} When making the medial arthrotomy, incising along the medial edge of the patellar fat pad minimizes bleeding, maximizes local vascularity, and decreases postoperative adhesions.

Hematoma formation is guarded against by utilizing blunt dissection deep to fascial layer I and careful inspection of the intermuscular bed after tourniquet deflation. Mullen¹⁹ has suggested that dissection should begin outside fascial layer I distally; however, the authors feel that protection of the structures along the intermuscular septum and further posteriorly can be accomplished by staying deep to fascial layer I.

In severely arthritic knees, eversion of the patella can be more difficult and can require release of the lateral patellofemoral ligament, removal of osteophytes, or use of a towel clip. In these cases, the knee is slowly flexed while the amount of proximal blunt dissection of the vastus muscle belly off the intermuscular septum is titrated to avoid over stretching of the vastus or excess tension on the patellar tendon insertion.

Relative contraindications to utilizing this approach include revision TKAs or any previous major arthrotomy about the knee. The aforementioned procedures leave significant scar tissue, making eversion of the pa-

tella much more difficult and thus infringing upon visualization. High tibial valgus osteotomy produces infrapatellar tendon scarring, making visualization of the posterior-lateral corner of the tibia difficult. Patients weighing over 200 pounds, especially when combined with a shorter femur, are also a relative contraindication because of excess soft-tissue impingement when everting the patella.

The subvastus approach for primary TKA is a more natural and logical choice than a medial parapatellar incision if vascular and muscular anatomy and physiology are considered. In the virgin knee, the vascularity to the patella is maintained via the intramuscular articular branch of the descending geniculate and extensor mechanism is not violated providing more inherent stability to the patellofemoral joint. It can be rapidly mastered and does not add to the operating time when utilized for primary TKA.

REFERENCES

- Abbott, L. C., and Carpenter, W. E.: Surgical approaches to the knee joint. *J. Bone Joint Surg.* 27(A):277, 1945.
- Arnocsky, S. P.: Blood supply to the anterior cruciate ligament and supporting structures. *Orthop. Clin. N. Am.* 16:15, 1985.
- Bechtol, C. O.: Richards Patello-Femoral Replacement Surgical Technique Brochure. 1976, 1978, pp. 2, 14, 26.
- Bjorkstrom, S., and Goldie, I. F.: A study of the arterial supply of the patella in the normal state, in chondromalacia patella & in osteoarthritis. *Acta Orthop. Scand.* 51:63, 1980.
- Cameron, H. U., and Fedorkow, D. M.: The patella in total knee arthroplasty. *Clin. Orthop.* 165:197, 1982.
- Chapman, W.: *Operative Orthopaedics*. Lippincott, Philadelphia, Pennsylvania, 1988, p. 720.
- Clayton, M. L., and Thirupathi, R.: Patellar complications after total condylar arthroplasty. *Clin. Orthop.* 170:152, 1982.
- Crenshaw, A. H.: *Campbells Operative Orthopaedics*. Seventh Edition. C. V. Mosby, St. Louis, Missouri, 1987, p. 37.
- Erkes, F.: Weitere Erfahrungen mit physiologischer Schnitt fuhrung zur Eroffnung des Kniegelenks. *Bruns' Beitr. zur Klin. Chir.* 147:221, 1929.
- Fisher, A. G. T.: Treatment of internal derangements of the knee-joint: A new method of operative exposure. *Lancet* 204:945, 1923.
- Gustke, K. D.: Southern approach for total knee replacement. *Florida Orthop. Trans.*, 1989.
- Hoppenfeld, S., and deBoer, P.: *Surgical Exposures in Orthopaedics. The Anatomic Approach*. Lippincott, Philadelphia, PA, 1984, p. 400.
- Hungerford, D. S., and Krackow, K. A.: Total joint arthroplasty of the knee. *Clin. Orthop.* 192:23, 1985.
- Kayler, D. E., and Lyttle, D.: Surgical interruption of patellar blood supply by total knee arthroplasty. *Clin. Orthop.* 229:221, 1988.
- Leblanc, J. M.: Patella complications in total knee arthroplasty a literature review. *Orthop. Rev.* 18:296, 1989.
- Merkow, R. L., Soudry, M., and Insall, J. N.: Patellar dislocation following total knee replacement. *J. Bone Joint Surg.* 67:1321, 1985.
- Mochizuki, R. M., and Schurman, D. J.: Patellar complications following total knee arthroplasty. *J. Bone Joint Surg.* 61:879, 1979.
- Moreland, J. R.: Mechanism of failure in total knee arthroplasty. *Clin. Orthop.* 226:49, 1988.
- Mullen, M. T.: A VMO approach to total knee surgery - A modified technique. *AAOS Video Library*, 1989.
- Ogata, K., Shively, R. A., Shoenecker, P. L., and Chang, S. L.: Effects of standard surgical procedures on the patellar blood flow in monkeys. *Clin. Orthop.* 215:254, 1987.
- Ritter, M. A., and Campbell, E. D.: Postoperative patellar complications with or without lateral release during total knee arthroplasty. *Clin. Orthop.* 219:163, 1987.
- Roffman, M., Hirsh, D. M., and Mendes, D. G.: Fracture of the resurfaced patella in total knee replacement. *Clin. Orthop.* 148:112, 1980.
- Scapinelli, R.: Blood supply of the human patella. *J. Bone Joint Surg.* 49:563, 1967.
- Scott, W. N., Rozbruch, J. D., Otis, J. C., Insall, J., Ranawat, C. S., and Burstein, A. H.: Clinical and biomechanical evaluation of patellar replacement in total knee arthroplasty. *Orthop. Trans.* 2:203, 1978.
- Scuderi, G., Scharf, S. C., Meltzer, B. A., and Scott, W. N.: The relationship of lateral releases to patellar viability in total knee arthroplasty. *J. Arthroplasty* 2:209, 1987.
- Scuderi, G., Scharf, S. C., Meltzer, L., Nisonson, B., and Scott, W. N.: Evaluation of patella viability after disruption of arterial circulation. *Am. J. Sports Med.* 15:490, 1987.
- Shim, S. S., and Leung, G.: Blood supply of the knee joint: A microangiographic study in children and adults. *Clin. Orthop.* 208:119, 1986.
- Von Langenbeck, B.: Zur Resection des Kniegelenks. *Verhandl. d. Deutschen Gesellsch. f. Chir.*, VII:23, 1878.
- Warren, L. F., and Marshall, J. L.: The supporting structures and layers on the medial side of the knee. *J. Bone Joint Surg.* 61:56, 1979.
- Wetzner, S. M., Bexreh, J. S., Scott, R. D., Bierbau, B. E., and Newberg, A. H.: Bone scanning in the assessment of patellar viability following knee replacement. *Clin. Orthop.* 199:215, 1985.