

no patellofemoral arthritis, then either geometric or anametric prosthetic units can be used. When there is significant patellofemoral arthritis, the anametric total knee is indicated. When a choice is to be made between arthrodesis and total knee replacement, the following conditions would favor total knee replacement: bilateral knee disease; concomitant hip disease; back pain; situations in which the contralateral knee has been arthrodesed for any reason; and in a patient with systemic arthritis whose disease is likely to be progressive in the future (rheumatoid arthritis). Once rheumatoid arthritis has passed beyond the synovial phase and significant joint damage is recognizable by roentgenogram, total knee arthroplasty should be considered.

INDICATIONS FOR TOTAL KNEE REPLACEMENT

One should attempt total knee replacement only after a complete course of conservative therapeutic modalities has been established and has failed. The treatment plan should include any or all of the following as they apply: weight loss, anti-inflammatory agents, ambulatory aids, diagnostic arthrography and/or arthroscopy. Magnuson debridement, high-tibial osteotomy, or even unicompartmental replacement

CONTRAINDICATIONS FOR GEOMETRIC AND ANAMETRIC TOTAL KNEE REPLACEMENTS

The following circumstances are direct contraindications to total joint replacement of the knee: prior joint sepsis; a fused knee; quadriceps paralysis; poor skin coverage; neuropathic joints; and gross instability. The presence of poor dentition, urinary tract obstruction, sepsis anywhere in the body, and concomitant ipsilateral hip pain are conditions which should be remedied before any total joint surgery is performed.

GEOMETRIC TOTAL KNEE ARTHROPLASTY TECHNIQUE*

Approach

Step I. The knee is approached by a long, medial parapatellar incision beginning four to six inches above the superior pole of the patella, curving gently around its medial border and ending one inch distal to the

* Adapted from Murray, W. R.: Technique for geometric total knee arthroplasty. Rutherford NJ, New medical Surgical Techniques, 1973.

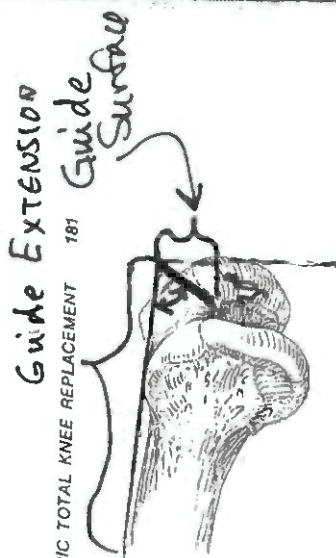


Figure 8. Placing of femoral cutting guide.

tibial tubercle. The approach is made under tourniquet control. Quadriceps mechanism, joint capsule, and synovium are incised on the same line. An anterior synovectomy is done if there is considerable hypertrophic proliferative synovium. The knee is flexed to 90 degrees with the patella turned 180 degrees on its long axis, thereby, exposing the joint and distal femur.

Step II. (Fig. 8) The femoral cutting guide is inserted in the midline, deep to the suprapatellar pouch. The initial transverse femoral osteotomies are made with a power hand saw parallel with the guide which is approximately 90 degrees to the long axis of the femur.

Figure 9 shows the appearance of the femur after this initial osteotomy with the distal-most portions of the medial and lateral femoral condyles removed.

Step III. (Fig. 10) The femoral cutting jig is then tipped in place with the central guide post in the midline. The downward projection of the central guide post must not extend anterior to a line projected along the anterior femoral cortex. Drill holes are then passed through the drill hole guides into the distal femur to assist in stabilizing the jig in place (Fig. 10).

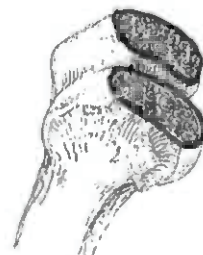


Figure 9. Appearance of femur after cutting of distal condyles.