

2 08 93

Dermatology

Editorials	
Dermatologische Zeitschrift	1
Dermatologica-Dermatology:	
A Centenary 1893-1993	
Holubar, K. (Vienna)	
In vivo Confocal Microscopy:	4
A New Paradigm in Dermatology	
Piérard, G.E. (Liège)	
Comment	
Clinical Investigation of Skin	6
Microcirculation	
Bongard, O.; Bounameaux, H. (Geneva)	
Clinical and Laboratory Investigations	
Cutaneous Malignant Melanomas	12
with Other Coexisting Neoplasms:	
A True Association?	
Schallreuter, K.U.; Levenig, Ch.; Berger, J. (Hamburg)	
Comparison of the Pathology of Fascia in	18
Eosinophilic Myalgia Syndrome Patients	
and Idiopathic Eosinophilic Fasciitis	
Umbert, I.; Winkelmann, R.K.; Wegener, L. (Scottsdale, Ariz.)	
Severity Scoring of Atopic Dermatitis:	23
The SCORAD Index. Consensus Report of the	
European Task Force on Atopic Dermatitis	
European Task Force on Atopic Dermatitis (Bordeaux)	
Evolving Pattern of Drug-Induced Toxic	32
Epidermal Necrolysis	
Correia, O.; Chosidow, O.; Saiag, Ph.; Bastuji-Garin, S.; Revuz, J.; Roujeau, J.-C. (Créteil)	
Effects of All-Trans-Retinoic Acid on	38
Melanocyte Adhesion and Motility	
Situ, R.; Inman, D.R.; Fligel, S.E.G.; Varani, J. (Ann Arbor, Mich./Allen Park, Mich.)	
Soluble CD14 Monocyte Antigen in	45
Suction Blister Fluid and Serum of	
Patients with Psoriasis	
Schopf, R.E.; Dörmeyer, J.; Dörmeyer, Th.; Morsches, B. (Mainz)	
In vivo Vision of the Human Skin with the	50
Tandem Scanning Microscope	
Corcuff, P.; Lévêque, J.-L. (Aulnay-sous-Bois)	
Pharmacology and Treatment	
Azelaic Acid Has Antimycotic Properties	55
in vitro	
Brasch, J.; Christophers, E. (Kiel)	
Onychomycosis: Successful Treatment	59
with Once-Weekly Fluconazole	
Nahass, G.T.; Sisto, M. (Miami, Fla.)	
Therapeutic Efficacy of Oral Low-Dose	62
Cyclosporin A in Severe Psoriatic	
Arthritis	
Wagner, S.A.; Peter, R.U.; Adam, O.; Ruzicka, T. (Munich)	
Case Reports	
Epidermolysis bullosa simplex	68
Dowling-Meara: Troublesome Blistering	
and Pruritus in an Adult Patient	
McGrath, J.A.; Burrows, N.P.; Jones, R.R.; Eady, R.A.J. (London)	
Primary Infection by Human Parvovirus	72
B19	
Veraldi, S.; Rizzitelli, G.; Lunghi, G.; Cardo, R. (Milano)	
Acute Generalized Exanthematous	75
Pustulosis due to Doxycycline	
Trüeb, R.M.; Burg, G. (Zürich)	
Letters to Dermatology	
Topical Podophyllotoxin in Psoriasis	79
vulgaris	
Wantke, F.; Fleischl, G.; Götz, M.; Jarisch, R. (Vienna)	
Positive Response to 5HT-2 Antagonists	80
in a Family Affected by Epidermolysis	
bullosa Dowling-Meara Type	
Tadini, G.; Ermacora, E.; Cambiaghi, S.; Brusasco, A.; Cavalli, R. (Milan)	

ISSN 1018-8665
DERAEG
186(1) 1-80 (1993)

S. Karger
Medical and Scientific
Publishers
Basel · Freiburg
Paris · London
New York · New Delhi
Bangkok · Singapore
Tokyo · Sydney

KARGER

Dr. Reddy's Laboratories, Ltd., et al.
v.
Galderma Laboratories, Inc.
IPR2015-
Exhibit 1038

R.M. Trüeb

G. Burg

Department of Dermatology,
University Hospital, Zurich, Switzerland

Acute Generalized Exanthematous Pustulosis due to Doxycycline

Key Words

Pustular drug rash
Lymphocyte transformation test
Rechallenge
Allergy to doxycycline

Abstract

Sterile epidermal neutrophilic pustulation can be observed in a variety of diseases. Though drug hypersensitivity is an uncommon cause, it is yet a known entity to be considered in the differential diagnosis of generalized pustulosis. In a 40-year-old woman, who developed a generalized pustular eruption after starting on doxycycline therapy of bronchitis, the rash was concluded to be drug induced after exclusion of other pustular dermatoses. Sensitization to doxycycline was demonstrated by in vitro lymphocyte testing and correlated with clinical drug hypersensitivity after recurrence of the pustular eruption on nonintentional rechallenge with doxycycline.

Pustular eruption is an uncommon manifestation of drug sensitivity [1]. A variety of dermatoses presenting with sterile epidermal neutrophilic pustulation must be considered in its differential diagnosis. Toxic pustuloderma [2, 3] has been delineated as a clinical entity characterized by a single self-limiting pustular eruption and some degree of a vasculitic reaction pattern [4, 5]. It is most frequently precipitated by drugs, in particular antimicrobials [6, 7]. The pathogenesis of toxic pustuloderma has remained subject to speculation. A severe form of toxic erythema has been proposed [3], also a reaction pattern favored by a psoriatic background has been suggested, though clinically and histologically different from pustular psoriasis [7]. We report a case in which drug allergy to doxycycline could be demonstrated by lymphocyte transformation testing.

Case Report

A 40-year-old woman suffering from allergic bronchial asthma was treated with doxycycline prior to the development of a pruritic erythematous rash, beginning in the flexural areas of the groin and elbows to subsequently spread over the trunk and limbs with a pustular eruption. Other medication at the time included acetylsalicylic acid, acetaminophen, N-acetylcystein, theophylline and salbutamol. She had neither a personal nor a familial history of any other skin disease. On admission to the hospital in June 1990 she exhibited a widespread patchy erythematopapular rash superimposed with several superficial pinhead-sized nonfollicular pustules (fig. 1).

The white cell count at the time was $11,200/\text{mm}^3$ with 84% neutrophils, the erythrocyte sedimentation rate was 28 mm/h. Blood chemistry was within normal limits. Cultures repeatedly taken from pustular lesions showed negative findings for bacterial or fungal organisms.

Skin biopsy revealed subcorneal pustules with neutrophils and a perivascular infiltrate in the superficial dermis composed of polymor-

Received:
March 6, 1992
Accepted:
July 7, 1992

Dr. R.M. Trüeb
Dermatologische Universitätsklinik
Gloriastrasse 31
CH-8091 Zürich (Switzerland)

© 1993 Karger AG, Basel
1018-8665/93/1861-0075
\$ 2.75/0

phonuclear cells and lymphocytes (fig. 2). Direct immunofluorescence testing did not demonstrate any immunoglobulin or complement deposits in the skin or vessel walls.

Patch-scratch testing was performed failing to reveal any hypersensitivity reaction to the implicated medicaments. A lymphocyte transformation test performed with doxycycline and acetylsalicylic acid in the Institute of Clinical Immunology of the University of Berne (director: Prof. Dr. A.L. de Weck) by Prof. Dr. W.J. Pichler demonstrated sensitization to doxycycline by a stimulation index of 13, whereas a stimulation index of up to 2 can be regarded as nonsignificant in regard to drug-specific hypersensitivity [pers. commun. of Prof. Dr. W.J. Pichler].

All previous medication was stopped and prednisone administered at a dose of 40 mg daily. Within few days the rash cleared with subsequent desquamation of the affected skin. In March 1991 the patient presented again with recurrence of the generalized pustular eruption after accidental ingestion of doxycycline. Other medication included theophylline, salbutamol and levomepromazine. After withdrawal of doxycycline and a short course of oral prednisone the pustular exanthema resolved within a week. There has been no recurrence since then.

Discussion

There is a variety of dermatoses presenting with generalized sterile epidermal neutrophilic pustulation. It is not an uncommon event. Any infectious cause of the pustules must first be excluded. Pustular eruption is a rather unusual manifestation of drug sensitivity [1], yet a known entity [7] to be considered. Its diagnosis is based on the temporal relationship incriminating the presumed causative agent, an often strikingly short interval between administration of the drug and the skin reaction [7], and on the exclusion of other pustular dermatoses (table 1). Among drug-induced pustular dermatoses the acneiform eruptions (e.g. halogen acne) must be differentiated from nonfollicular pustuloderma.

In 1984, Staughton et al. [2] delineated toxic pustuloderma as a new entity comprising a self-limiting syndrome presenting with an erythematous and pustular eruption associated with fever, peripheral blood leukocytosis and subcorneal pustules. The eruption is more frequently precipitated by drugs [1-3, 6-19], although other causative agents [3, 7, 12, 17] have been incriminated (table 2).

Three histological patterns to drug-induced pustular eruptions have recently been described: (a) one indistinguishable from the changes in Sweet's syndrome, (b) leukocytoclastic vasculitis and (c) the subcorneal polymorphonuclear microabscesses and upper dermal perivascular infiltrate composed of lymphocytes and neutrophils of toxic pustuloderma. It has been suggested to possibly consider these changes as a continuous spectrum in which neutro-

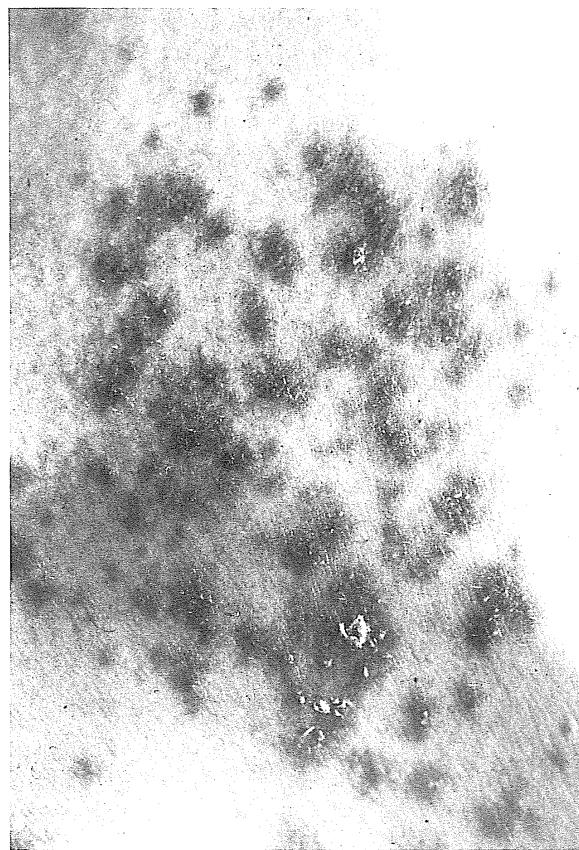


Fig. 1. Generalized exanthematous pustulosis: superficial pin-head-sized nonfollicular pustules superimposed on a background of patchy erythema.

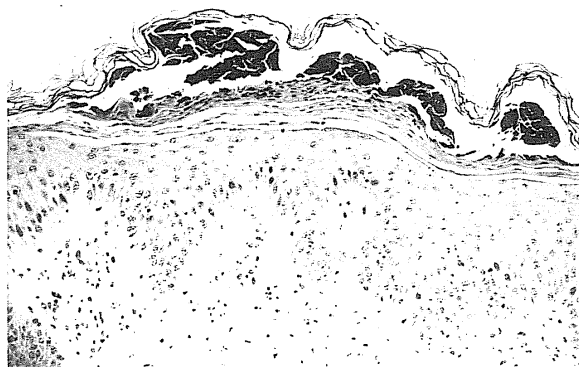


Fig. 2. Histologic features of acute generalized exanthematous pustulosis: subcorneal pustule with polymorphonuclear leukocytes. Hematoxylin-eosin. $\times 200$.

Table 1. Differential diagnosis of acute generalized exanthematous pustulosis

Subcorneal pustular dermatosis
Generalized pustular psoriasis
Impetigo herpetiformis
Pustulosis acuta generalisata
Pustular necrotizing angitis
Pustular erythema multiforme
Intraepidermal immunoglobulin A pustulosis

Table 2. Causative agents in acute generalized exanthematous pustulosis

Cause	Reference
Drugs	
Acetaminophen	7
Acetazolamide	16
Amoxicillin	6, 7
Ampicillin	7
Bufexamac	7
Carbamazepine	2, 7
Carbutamide	7
Cefaclor	16
Cefazoline	13
Cefradine	10
Cefuroxime	3
Cephalexin	12
Chloramphenicol	1
Clobazam	7
Cyclines	7, 11
Diltiazem	14
Erythromycin	7
Furosemide	1
Hydroxychloroquine	15
Nifedipine	7
Penicillin	7
Phenytoin	8
Pipemidic acid	7
Piperazine	1
Pristinamycin	7
Pyrimethamine	1
Quinidine	7
Roxithromycin	7
Spiramycin	7
Streptomycin	9
Sulbutiamine	7
Vancomycin	7
Other causes	
Viral infection	7, 17
Mercury	7
Food poisoning	3

phils collect around the dermal blood vessels, form subepidermal pustules and are then eliminated transepidermally [5].

The clinical identification of adverse drug reactions is largely based on subjective criteria [18]. Direct challenge provides the most definitive information on the relationship of a suspected drug to a given clinical syndrome but is usually not justified because of the potential morbidity involved. After implicating the causative agent, the clinician dealing with a drug reaction is faced with three issues: (1) immunologic versus nonimmunologic origin of the drug reaction, (2) detection of the responsible one of multiple drugs in case of an immunologic drug reaction, (3) risk of eliciting an allergic reaction to readministration of the drug [18]. To prove the immunologic origin of a given drug reaction, an immune response to the drug and a similar drug-initiated clinical reaction must be demonstrated. Because of the aforementioned difficulties associated with readministration of suspected drug allergens, in vitro tests have been devised to demonstrate a drug-specific immune response [20]. To detect drug-specific cellular immune response in drug hypersensitivity states, delayed tuberculin-type skin testing and the lymphocyte transformation test [21] have been used. The former is however of limited value with a possible risk of reexposing the sensitized patient to antigen, whereas with the latter in most instances it has not been possible to correlate the cell-mediated responses with clinical drug hypersensitivity. In our case the lymphocyte transformation test disclosed sensitization to doxycycline. Nonintentional rechallenge with doxycycline occurred. Recurrence of the rash on this occasion permitted the most clear-cut correlation of the in vitro demonstrated cell-mediated immune response with clinical hypersensitivity to doxycycline. We believe this has demonstrated a drug-specific cell-mediated immune response as causative in our case of an acute generalized exanthematous pustulosis.

References

- 1 Macmillan AL: Generalized pustular drug rash. *Dermatologica* 1973;146:285-291.
- 2 Staughton RCD, Rowland Payne CME, Harper JJ, McMichen H: Toxic pustuloderma - A new entity? *J R Soc Med* 1984;77(suppl 4):6-8.
- 3 Rustin MHA, Robinson TWE, Dowd PH: Toxic pustuloderma: A self-limiting eruption. *Br J Dermatol* 1990;123:119-124.
- 4 Beylot C, Bloulac P, Doutre MS: Pustuloses exanthématiques aiguës généralisées. *Ann Dermatol Vénéréol* 1980;107:37-48.
- 5 Burrows NP, Jones RR: Pustular drug eruptions: A histopathological spectrum. In press.
- 6 Armster H, Schwarz Th: Arzneimittelreaktion auf Amoxicillin unter dem Bild eines toxischen Pustuloderms. *Hautarzt* 1991;11:713-716.
- 7 Roujeau JC, Bioulac-Sage P, Bourseau C, Guillaume JC, Bernard P, Lok C, Plantin P, Claudy A, Delavierre C, Vaillard L, Wechsler J, Danan G, Bémichou C, Beylot C: Acute generalized exanthematous pustulosis. Analysis of 63 cases. *Arch Dermatol* 1991;127:1333-1338.
- 8 Stanley J, Fallon-Pellici V: Phenytoin hypersensitivity reaction. *Arch Dermatol* 1978;114:1350-1353.
- 9 Kushimoto H, Anoki T: Toxic erythema with generalized follicular pustules caused by streptomycin. *Arch Dermatol* 1981;117:444-445.
- 10 Kalb R, Grossman ME: Pustular eruption following administration of cephradine. *Cutis* 1986;38:58-60.
- 11 Delavierre C, Milpied B, Bureau B, Litoux P: Les pustuloses exanthématiques aiguës généralisées: À propos de 5 cas. *Sémin Hôp Paris* 1988;64:365-367.
- 12 Jackson H, Vion B, Levy PM: Generalized eruptive pustular drug rash due to cephalixin. *Dermatologica* 1988;177:292-294.
- 13 Fayol J, Bernard P, Bonnetblanc JM: Pustular eruption following administration of cefazolin: A second case report. *J Am Acad Dermatol* 1988;19:571.
- 14 Lambert DG, Dalac S, Beer F, Chavannet P, Portier H: Acute generalized exanthematous pustular dermatitis induced by diltiazem (letter). *Br J Dermatol* 1988;118:308-309.
- 15 Lotem M, Ingber A, Segal R, Sandbank M: Generalized pustular drug rash induced by hydroxychloroquine. *Acta Derm Venereol* 1990;70:250-251.
- 16 Ogoshi M, Yamada Y, Tani M: Acute generalized exanthematous pustulosis induced by cefaclor and acetazolamide. *Dermatology* 1992;184:142-144.
- 17 Rouchouse B, Bonnefoy M, Pallot B, Jacqueline L, Dimoux-Dime G, Claudy AL: Acute generalized exanthematous pustular dermatitis and viral infection. *Dermatologica* 1986;173:180-184.
- 18 Wintroub BU, Stern RS, Arndt KA: Cutaneous reactions to drugs; in Fitzpatrick TB, Eisen AZ, Wolff K, Freedberg I, Austen KF (eds): *Dermatology in General Medicine*. New York, McGraw-Hill International Book Co, 1986, pp 1353-1366.
- 19 Kramer MS: An algorithm for the operational assessment of adverse drug reactions. *JAMA* 1979;242:623.
- 20 Parker CW: Drug allergy. *New Engl J Med* 1975;292:511, 732, 957.
- 21 Rocklin RE: Clinical application of in vitro lymphocyte tests; in Schwartz RS (ed): *Progress in Clinical Immunology*. New York, Grune & Stratton, 1974, vol II, p 21.