
Thomas B. Fitzpatrick
Arthur Z. Eisen
Klaus Wolff
Irwin M. Freedberg
K. Frank Austen

Third Edition
**DERMATOLOGY
IN GENERAL
MEDICINE**

Dr. Reddy's Laboratories, Ltd., et al.
v.
Galderma Laboratories, Inc.
IPR2015-
Exhibit 1056

NOTICE

Medicine is an ever-changing science. As new research and clinical experience broaden our knowledge, changes in treatment and drug therapy are required. The editors and the publisher of this work have made every effort to ensure that the drug dosage schedules herein are accurate and in accord with the standards accepted at the time of publication. Readers are advised, however, to check the product information sheet included in the package of each drug they plan to administer to be certain that changes have not been made in the recommended dose or in the contraindications for administration. This recommendation is of particular importance in regard to new or infrequently used drugs.

DERMATOLOGY IN GENERAL MEDICINE

Copyright © 1987, 1979, 1971 by McGraw-Hill, Inc. All rights reserved. Printed in the United States of America. No part of this publication may be reproduced, stored in a retrieval system, or transmitted, in any form or by any means, electronic, mechanical, photocopying, recording, or otherwise, without the prior written permission of the publisher.

1234567890 DOWDOW 89876

This book was set in Times Roman by Ruttle, Shaw & Wetherill, Inc. The editors were J. Dereck Jeffers, Eileen Scott, and Julia White; the cover was designed by Edward R. Schultheis; the production supervisor was Ave McCracken. R. R. Donnelley & Sons Company was printer and binder.

Library of Congress Cataloging in Publication Data

Main entry under title:

Dermatology in general medicine.

Includes bibliographies and index.

1. Dermatology. 2. Cutaneous manifestations of general diseases. I. Fitzpatrick, Thomas B. [DNLM: 1. Skin diseases. 2. Skin Manifestations. WR 100 D4383]

RL71.D46 1987 616.5 86-10633

ISBN 0-07-079689-0 (set)

ISBN 0-07-021205-8 (v. 1)

ISBN 0-07-021206 (v. 2)

method for differentiating redness due to vascular dilatation (erythema) from redness due to extravasated erythrocytes or erythrocyte products (purpura). If the redness remains under the pressure of the slide, the lesion is purpuric.

An *infarct* is an area of cutaneous necrosis resulting from occlusion of blood vessels, as in vasculitis and bacterial embolism. Cutaneous infarcts have a variegated, dusky red, grayish hue. They are irregularly shaped macules, sometimes depressed slightly below the plane of the skin and often surrounded by a pink zone of hyperemia. They may be tender.

Disseminated small erythematous macules occur in exanthems such as roseola and drug eruptions. Confluent erythematous macules may cover a whole extremity or half of the face, as in capillary hemangioma (nevus flammeus). Macules may be pigmented, such as the café au lait-colored macules of neurofibromatosis; hypopigmented, as in postinflammatory hypopigmentation; and depigmented, as in vitiligo. Hypomelanotic macules, often with an outline resembling the shape of an ash leaf, have been identified as the earliest visible marker of tuberous sclerosis. Collections of dermal melanocytes may impart a gray color to the skin, as in Mongolian spots. A blue color may arise from the scattering of light as it passes through the turbid medium of the dermis (Tyndall phenomenon), as in nevus of Ota. Fine scaling may be seen in the maculosquamous lesions of tinea versicolor, pityriasis rosea, and erythrasma.

Telangiectases are commonly observed on faces of persons chronically exposed to the wind and sun. They are a prominent feature of the erythematous color noted in cutaneous lupus erythematosus. In addition, periungual telangiectases are an important marker for collagen vascular disorders such as lupus erythematosus and dermatomyositis. In hereditary hemorrhagic telangiectasia, the lesions are usually nonpulsatile, dull red, sharply outlined macules or papules, most commonly present on the tongue, lips, face, and fingers. Telangiectases are also a prominent feature of rosacea.

Papules. A papule is a small, solid, elevated lesion (Fig. 4-2). Papules are smaller than 1 cm in diameter, and the major portion of a papule projects above the plane of the surrounding skin. *Oblique lighting with a flashlight in a darkened room is often necessary to detect slight elevation.* The elevation can be the result of metabolic deposits, localized hyperplasia of cellular components of the epidermis or dermis, or localized cellular infiltrates in the dermis. Superficial papules with sharp borders are seen when the lesion is the result of an increase in the number of epidermal cells or melanocytes, as in verruca vulgaris or melanocytic nevi.

Papules may have a variety of shapes. They may be acuminate (pointed), as in miliaria rubra (prickly heat rash); surmounted with scale or keratin, as in secondary syphilis; dome-shaped, as in molluscum contagiosum; or flattopped, as in lichen planus.

Other features, such as color, are also important in the identification of papular lesions. Red papules are seen in psoriasis, often with a superimposed scale that produces bleeding when removed (Auspitz's sign). Papules with scaling are referred to as *papulosquamous* lesions. A copper color is noted in the lesions of secondary syphilis.

Flattopped papules with a violaceous hue are characteristic of lichen planus. The presence of fine, netlike white markings, called Wickham's striae, on the surface of the lesion provides further evidence for the diagnosis of lichen planus. Yellow papules are seen in xanthomatosis. Hemorrhagic or necrotic papules are noted in cutaneous vasculitis and meningococcemia. Purpuric papules—*palpable purpura*—are indicative of vasculitis until proved otherwise. Brownish, rough (keratotic) papules are quite typical of keratosis follicularis (Darier's disease). Pigmented nevi and early malignant melanoma often occur as rounded, brown or black papules and are to be differentiated from pigmented basal cell carcinoma, which has a somewhat similar appearance but is waxy-smooth with a raised, rolled, telangiectatic border. A dark blue or black, rounded papular lesion may suggest a blue nevus, nodular melanoma, angiokeratoma, or Kaposi's sarcoma.

Rounded, skin-color papules may be seen in adenoma sebaceum and amyloidosis. Molluscum contagiosum may be identified as a rounded, translucent papule with a central umbilication; when the papule is punctured, a rounded, central "molluscum body" is noted. Pedunculated papules, darker than, or the same color as, normal skin, occur in neurofibromatosis. Skin tags (acrochordon) are pedunculated or filiform lesions that are usually skin colored. Papules may be follicular and perifollicular, as in acne, folliculitis, and Darier's disease.

A papule or plaque (see below) may consist of multiple, small, closely packed, projected elevations that are known as a *vegetation* (Fig. 4-2). Vegetations may be covered with thick dry scales, and described as *keratotic* (as in verruca vulgaris), or may be soft and smooth (as in condyloma acuminatum). Seborrheic keratoses are common vegetative lesions, especially in older age groups. They may be yellowish, tan, brown, or black, and often have a soft, greasy surface. Dry, scaly vegetations occur in actinic keratoses.

All erythematous papules should be examined by diascopy (see "Aids in the Clinical Examination of Skin and Hair," later in this chapter), inasmuch as a yellow-brown color appears in the papules found in a number of granulomatous disorders, and an erythematous papule that does not blanch on diascopy may be a sign of vasculitis (palpable purpura).

Although certain eruptions may have both macular and papular components, we believe that the abused term *maculopapular* is a non sequitur, or at best an oxymoron, and we avoid using it for the sake of clear thinking and communication.

Plaques. A plaque is a mesalike elevation that occupies a relatively large surface area in comparison with its height above skin level (Fig. 4-3). Plaques are often formed by a confluence of papules, as in psoriasis. The typical psoriatic lesion is a raised, erythematous plaque with layers of silvery scale, often described as micaceous.

Repeated rubbing, especially in people with chronic eczema, leads to areas of *lichenification*. Proliferation of keratinocytes and stratum corneum, in combination with changes in the collagen of the underlying dermis, causes lichenified areas of skin to appear as thickened plaques with accentuated skin markings. The lesions may resemble tree bark.

The presence of atrophy, especially in the presence of

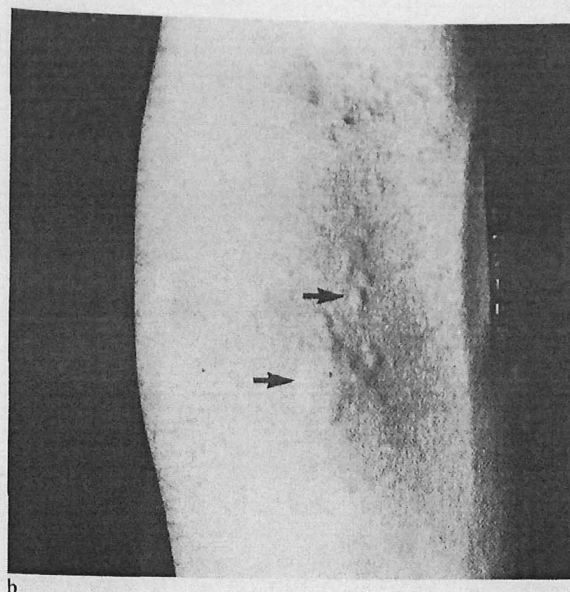
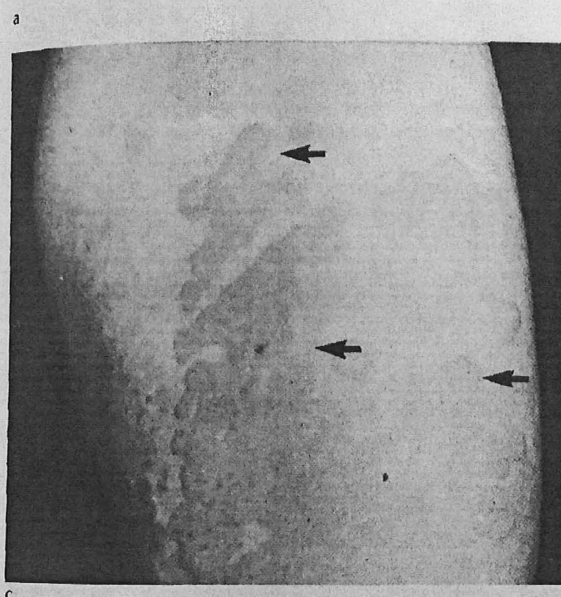
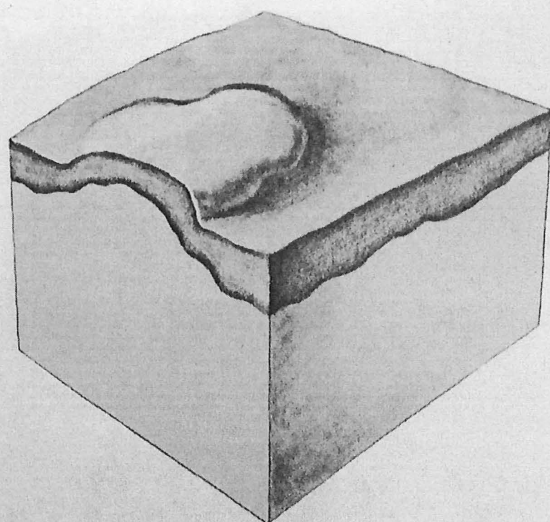


Fig. 4-5 Wheal. A wheal, shown in the drawing (a), is a rounded or flattopped elevated lesion that is characteristically evanescent, disappearing within hours. Wheals may be tiny papules 3 to 4 mm in diameter as in cholinergic urticaria which is shown in the clinical photograph (b). They may be large, coalescing plaques as in allergic reactions to penicillin, other drugs, or alimentary allergens, as shown in (c). An eruption consisting of wheals is termed *urticaria* and is characterized by itching.

When the epidermis is lost, usually as a result of vesication, the circumscribed denudation is known as an erosion and appears as a moist, slightly depressed lesion (see below).

Erosions. An *erosion* is a moist, circumscribed, usually depressed lesion that results from loss of all or a portion of the viable epidermis (Fig. 4-9). After the rupture of vesicles or bullae, the moist areas remaining at the base are called erosions. Extensive areas of denudation due to erosions may be seen in bullous diseases such as pemphigus. Unless they become secondarily infected, erosions usually do not scar. If inflammation extends into the papillary dermis, an ulcer is present and scarring results, as in vaccinia and variola, and less often in herpes zoster and varicella.

Pustules and other pyodermatoses. A *pustule* is a circumscribed, raised lesion that contains a purulent exudate (Fig. 4-10). Pus, composed of leukocytes with or without cellular debris, may contain bacteria or may be sterile, as in the

lesions of pustular psoriasis. Pustules may vary in size and shape and, depending on the color of the exudate, may appear white, yellow, or greenish yellow. Follicular pustules are conical, usually contain a hair in the center, and generally heal without scarring.

Pustules are characteristic of rosacea, pustular psoriasis, Reiter's disease, and some drug eruptions, especially those due to bromide or iodide. Vesicular lesions of some viral diseases (varicella, variola, vaccinia, herpes simplex, and herpes zoster), as well as the lesions of dermatophytosis, may become pustular. A Gram's stain and culture of the exudate from pustules should always be performed.

A *furuncle* is a deep necrotizing form of folliculitis, with pus accumulation. Several furuncles may coalesce to form a *carbuncle*. An *abscess* is a localized accumulation of purulent material so deep in the dermis or subcutaneous tissue that the pus is usually not visible on the surface of the skin. It is red, warm, and tender. An abscess frequently begins as a folliculitis and is commonly a manifestation of cutaneous streptococcal or *Staphylococcus aureus* infection.

A *sinus* is a tract leading from a suppurative cavity to the skin surface, or between cystic or abscess cavities. A sinus near the rectum may be seen in rectal abscess, carcinoma of the bowel, or inflammatory bowel disease. Sinuses of the neck suggest actinomycosis, scrofula, branchial pouch, or dental sinus. Deep sinus tracts may occur in hidradenitis suppurativa and acne conglobata.

Cysts. A *cyst* is a sac that contains liquid or semisolid material (fluid, cells, and cell products). A spherical or

somal hydrolases by polymorphonuclear leukocytes is anti-*P. acnes* antibody dependent [44]. There is other evidence of changes in the immune response as demonstrated by increased response to *P. acnes* injections in patients with acne [45,46], an increase in the lymphocyte transformation after exposure to *P. acnes* antigens in patients with severe nodulocystic acne [47], and an increase in leukocyte migration upon exposure to *P. acnes* in patients with severe acne [48].

Androgenic stimulation at puberty induces sebaceous gland development, as already indicated, and it has been proposed that acne results from hormonal imbalances between androgens and estrogens with an increase in the androgen/estrogen ratio. Most of the data to support such a contention are based on studies using less accurate steroid measurements. Plasma and urinary testosterone levels have been reported to be normal in both men [49-51] and women [52] with acne. However, there are now several reports of endocrinologic changes in patients with acne. These are as follows: (1) it has been shown that during early puberal development, plasma testosterone levels are higher in those with acne [53]; (2) it has also been shown that urinary androgen metabolites are increased in young children if acne is present [54]; (3) in female patients with acne, it has been shown that there may be increased peripheral tissue conversion of testosterone to androstenediol, and this is presumed to have occurred in the skin [52]; (4) direct incubation of skin from men and women with acne indicates that there is an increase in the metabolic conversion of testosterone to dihydrotestosterone, and the increase is far in excess of that which could occur from an increase in the volume of sebaceous tissue [55]; (5) in a small group of older women with recalcitrant acne, a partial 11- or 21-hydroxylase block has been demonstrated [56,57] (the detection of this block was made easier by the use of a 24-h ACTH infusion); and (6) there are new studies that have demonstrated an increase in various androgen blood levels in men and women [50,51,53,58-63]. These studies have been summarized [64], and include elevations of total plasma testosterone in men [53] and women [51,58,60,61,63], of free testosterone in women [60], of Δ^4 -androstenedione in women [58], of dehydroepiandrosterone in women [59,62], of dehydroepiandrosterone sulfate in men [63] and women [62,63], and free 17β -hydroxysteroids in women [50]. Still, there are other studies that report normal values for all of these androgens. As the significance of all these endocrinologic abnormalities becomes clear in the next few years, there may be changes in the therapy of acne.

Acne also may be aggravated by the administration of hormones such as testosterone, anabolic agents, gonadotropins, corticosteroids, and ACTH. In addition, these latter two agents are the cause of steroid acne, an entity to be described later. Because of the influence of hormones on acne, and the information given above, the sudden appearance of acne in an adult should alert the physician to the possibility of an underlying disorder of the pituitary-gonadal or pituitary-adrenal axis. Furthermore, emotional stress may aggravate acne. While no definite evidence exists to show that such stress increases sebaceous gland activity, the pituitary-adrenal axis may be involved, since it has been shown that patients with acne have a greater increase in urinary glucocorticoid levels after corticotropin administration than that seen in normal persons [65].

Clinical manifestations

The primary site of acne is the face, and to a lesser degree the back, chest, and shoulders. On the trunk, lesions tend to be numerous near the midline. The disease is characterized by a great variety of clinical lesions. While one type of lesion may be predominant, close observation usually reveals several types of lesions (Fig. 67-3). The lesions may be either noninflammatory or inflammatory. The non-inflammatory lesions are comedones (Fig. 67-4). These may be either open (blackheads) or closed (whiteheads). The open comedo appears as a flat or slightly raised lesion with a central follicular impaction of keratin and lipid. The brown or black color is not the result of accumulation of dirt nor due to the compaction of the keratinous material at the follicular orifice. There is evidence that there are melanocytes at the follicular orifice and the pigment of the blackhead has been identified as melanin [66-68]. The closed comedones, in contrast to the open comedones, may be difficult to visualize. They appear as pale, slightly elevated, small papules. They do not have a clinically visible orifice. Stretching of the skin is an aid in detecting the lesions. Since the closed comedones are the precursors for the large inflammatory lesions, they are of considerable clinical importance. Comedones are the primary lesions of acne, but they are not unique in this disease since they may be seen under other conditions (e.g., so-called senile comedones which are common, particularly in the periorbital area of older persons; comedones which are seen in the atrophic skin resulting from x-ray therapy).

The inflammatory lesions vary from small papules with an inflammatory areola to pustules to large tender fluctuant nodules and cysts (Figs. 67-5 and A1-1). All these lesions show an inflammatory infiltrate in the dermis, and their clinical appearance depends on the size and location of this infiltrate.

In addition to the above-described lesions, patients may have varying-sized cysts and scars. The characteristic scar of acne is a sharply punched-out pit. These are ordinarily single, but where inflammation has been marked, the pits may have multiple openings. Less commonly, broader pits may occur and in rare instances, especially on the trunk, the scars may be hypertrophic.

It has been mentioned that seborrheic dermatitis is commonly seen in association with acne, but there does not appear to be any relation between these two diseases.

Laboratory findings

Many laboratory studies have been done in the past, but in general the findings have not been significant. More details on sebum, microbiologic and hormonal changes have been mentioned in the section on "Etiology and Pathogenesis" above. X-ray studies in a few instances have demonstrated localized calcium deposits in areas of severe scarring [69].

Pathology

As already stated, acne develops in the sebaceous follicles, and the primary lesion is the comedo. Comedo development starts in the midportion of the follicle as an expanding mass of lipid-impregnated keratinous material, resulting in thinning and ballooning-out of the follicular wall. Gradu-

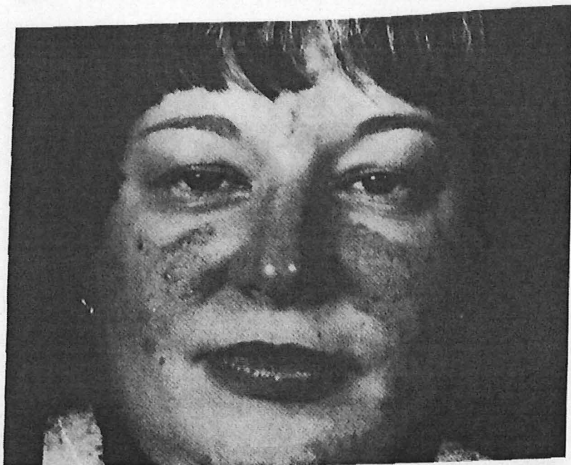

Fig. 67-14 Rosacea with acneform lesions.

in women, but more severe involvement is found in the male. Blacks are rarely involved.

Etiology and pathogenesis. There is no adequate explanation for the vascular dilatation. The affected skin shows a normal response to chemomediators such as epinephrine, norepinephrine, acetylcholine, and histamine [141] and there is no evidence of vascular instability after local cooling of the skin [142].

It has been proposed that this disease is related to the presence of the mite, *Demodex folliculorum*. Since this is a normal follicular inhabitant, and since the topical application of sulfur ointment will improve rosacea without affecting the mite population [143], the etiologic importance of this parasite in the disease process is doubtful. The same may be said for many other constitutional factors such as focal infection, vitamin deficiencies, and endocrine abnormalities. Psychogenic stress also has been mentioned as an etiologic factor, although this has not been proved in a controlled study.

The acneform component, which is not always present, is similar to acne vulgaris. While these patients have a prominent poral pattern, suggesting the presence of large sebaceous glands, sebum secretion is not elevated [144]. However, this has been measured on the forehead, and not at the site of the disease, so local enlargement still may exist.

Clinical manifestations. **CUTANEOUS LESIONS.** The onset of rosacea (Fig. A1-2) is insidious; most patients cannot state when it actually started. Initially, there is transient vascular dilatation with varying erythema. Primary involvement occurs over the blush area of the cheeks and nose. The chin and central portion of the forehead also may be involved. While the lesions are intermittent initially, eventually persistent erythema accompanied by telangiectasia appears. The areas of erythema blanch on diascopy. In certain instances, only telangiectasia appears. The predominant lesions are papules and pustules (Fig. 67-14), although in rare instances, nodules also may appear. In contrast to acne vulgaris, comedones are rare. Granulomatous plaques may be seen. These result from a merging of the individual lesions [145]. This form of the disease is very rare.

Rhinophyma is more common in males (Fig. 67-15). The lower portion of the nose is involved first. There is irregular thickening of the skin, and the follicular orifices are enlarged. The color of the skin, which is not uniform, varies from bright red to purplish red. The amount of thickening varies and, in some instances, the adjacent portions of the cheeks are involved. Rhinophyma is usually seen in severe rosacea but may occur as the only manifestation of the disease.

OTHER PHYSICAL FINDINGS. A variety of ocular lesions may accompany rosacea [146,147]. Blepharitis, conjunctivitis, episcleritis, iritis, and keratitis have all been seen. The group of patients studied will influence the observed incidence of these eye changes. Thus, in 134 rosacea patients in a general hospital, there were 4 cases with ocular lesions; in contrast, 99 of 104 rosacea patients seen in an eye hospital had ocular lesions [146]. Blepharitis and conjunctivitis are most common, and the former may reflect the concurrent appearance of seborrheic dermatitis. Keratitis, while less common, is more serious since ulceration and ultimate impairment of vision often occurs. The ocular lesions are chronic and frequently progressive. In one-fifth of Borrie's [146] cases, the ocular lesions preceded the cutaneous lesions by periods of up to 30 years. While many theories have been proposed for the relation between the ocular and cutaneous lesions, none of these is proved.

Laboratory findings. Achlorhydria is of no significance, since it is seen in just as many normal persons of similar age. Nevertheless, various gastrointestinal complaints have been reported in rosacea patients. Furthermore, on gastroscopy, either atrophic, hypertrophic, or superficial gastritis has been found in most rosacea patients. Usher [148] found gastritis in 18 of 19 patients, and Conrad et al [149] observed abnormal stomach patterns in 10 of 12 rosacea cases. Changes are not restricted to the stomach,

Fig. 67-15 Marked rhinophyma of nose in rosacea. The adjacent portion of the cheeks is also involved.

