

## Successful treatment of Sweet's syndrome with doxycycline

R.K.JOSHI, D.N.ATUKORALA, A.ABANMI, O.AL KHAMIS AND A.HALEEM\*

Departments of Dermatology and \*Pathology, Riyadh Armed Forces Hospital, Riyadh, Saudi Arabia

Accepted for publication 18 November 1992

### Summary

Two patients with Sweet's syndrome are described, both of whom were treated with doxycycline 200 mg daily, and responded well to therapy. Doxycycline appears to be an effective alternative to corticosteroids for the treatment of Sweet's syndrome.

In 1964 Sweet<sup>1</sup> described eight patients with a condition he designated 'acute febrile neutrophilic dermatosis', and which has subsequently become known as Sweet's syndrome. This disorder comprises fever, neutrophil leucocytosis, and skin lesions with characteristic histological features.<sup>2–4</sup>

Sweet's syndrome responds rapidly to systemic corticosteroids, but relapses frequently occur. This treatment may not be ideal for all patients with Sweet's syndrome, and several alternative therapies, including potassium iodide,<sup>5</sup> clofazimine,<sup>6</sup> indomethacin,<sup>7</sup> colchicine and dapsone<sup>8</sup> have been tried, with limited success.

We describe two female patients with Sweet's syndrome who responded to treatment with oral doxycycline.

### Case reports

#### Case 1

A 41-year-old Saudi woman presented in April 1989 with erythematous, indurated, tender plaques on the forearms (Fig. 1). She was afebrile, and there was no history of arthropathy, or recent respiratory or urinary-tract infection. She had suffered from recurrent attacks of similar painful skin lesions, mainly on the dorsa of the hands and/or forearms for the previous 4 years. The lesions were observed to improve when she received treatment for her rosacea with doxycycline. Pulmonary tuberculosis was diagnosed in 1980, and treated with antituberculous therapy for 18 months with a multiple-drug regimen. In February 1988, she developed scrofuloderma involving the cervical lymph nodes, and was given a further course of antituberculous therapy. This was followed by a persistent tuberculous sinus in the neck which was excised in September 1989.

A skin biopsy from a forearm lesion showed a dense

infiltrate principally composed of neutrophils, with leucocytoclasia, and a few histiocytes. There was no evidence of true vasculitis. The epidermis was unremarkable (Fig. 2). A full blood count and routine biochemistry were normal. The ESR was 68 mm/h. Hepatitis serology, and serological tests for syphilis were negative. Skin-slit smears for acid-fast bacilli and *Leishmania* bodies were negative. Urine and stool analyses revealed no abnormality.

Because of the previous response to doxycycline, she was treated with doxycycline 100 mg twice daily. There was improvement after 1 week of treatment, and the lesions gradually resolved over the next 2 weeks. In view of her previous history of recurrences, she was given a further 3 weeks' treatment at a reduced dose of 100 mg daily. Thereafter, she did not develop any further lesions during a 15-month follow-up period.

#### Case 2

A 37-year-old Saudi woman was seen in November 1989, with a 7-year history of recurrent, painful skin lesions consisting of furunculoid and erythematous plaques. These episodes were frequently associated with respiratory- or urinary-tract infections, but on other occasions there were no obvious precipitating factors. Skin lesions appeared predominantly on her limbs, with a few on the trunk and face. She had been seen in outpatient departments many times, and was admitted to hospital on three occasions with widespread skin lesions, fever and arthralgia. Pregnancy exacerbated the skin lesions. Histology of a skin biopsy showed changes similar to those in Case 1, which were consistent with the diagnosis of Sweet's syndrome. Leucocytosis ranged between  $12.6$  and  $16.8 \times 10^9/l$  (normal range  $4-11$ ), and the ESR between 24 and 45 mm/h.

Before attending in November 1989, she had been treated at another hospital with prednisolone 40 mg daily for 6 weeks. On reducing the dose of prednisolone

Correspondence: Dr R.K.Joshi, Riyadh Armed Forces Hospital, P.O. Box 7897, Riyadh 11159, Saudi Arabia.

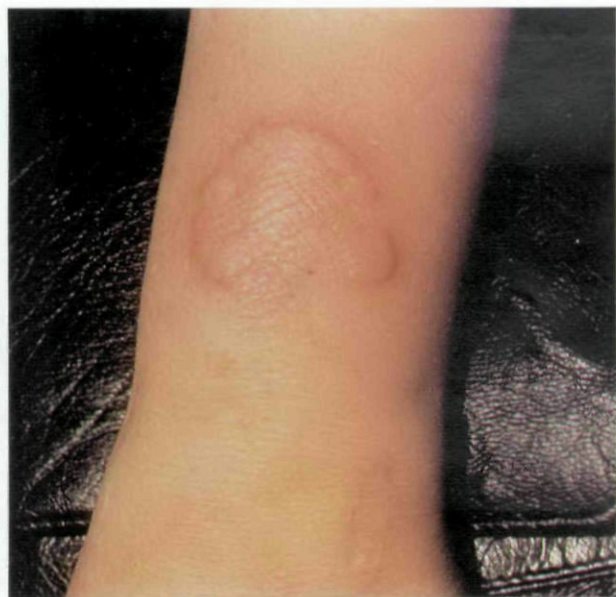

Figure 1. Case 1. Typical lesion of Sweet's syndrome on the left forearm.

to 10 mg daily, she developed multiple, indurated, erythematous plaques surmounted by flaccid blisters.

In view of the tendency for her lesions to relapse, and because of our previous experience with Case 1, we added doxycycline 100 mg twice daily, and were then able to wean her off the prednisolone. She began to improve within 2 weeks, but then stopped all medications when she became pregnant. There were recurrent exacerbations of her skin lesions during the pregnancy, which were helped by topical steroids and oral non-steroidal anti-inflammatory agents. We saw her again after her child was born in January 1992, and she had florid skin lesions. Treatment with doxycycline 100 mg twice daily was started, and there was a dramatic improvement within 2 weeks. The lesions resolved completely, leaving residual hypopigmentation, after 4 weeks. We continued to treat her with a reduced dose of 100 mg doxycycline daily for 4 weeks, followed by 50 mg daily for a further 4 weeks. She has been virtually free of skin lesions for the past 4 months on this regimen.

## Discussion

Systemic corticosteroids are still considered to be the treatment of choice in Sweet's syndrome,<sup>9</sup> although in cases of relapsing Sweet's syndrome other anti-inflammatory drugs have been tried, with some success.<sup>5-8</sup> Both our patients had relapsing Sweet's syndrome. Possible precipitating factors could have been tuberculo-

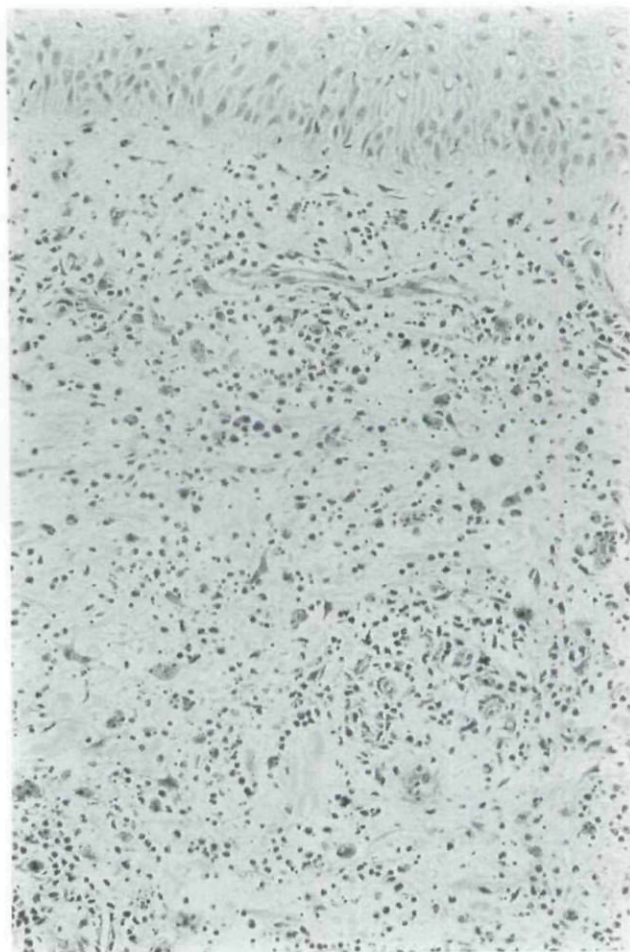


Figure 2. Photomicrograph of skin biopsy from Case 1. The upper and mid-dermis is heavily infiltrated by inflammatory cells mixed with nuclear dust.

sis in the first patient, and respiratory or urinary infections in the second patient. Pregnancy is another reported exacerbating factor.<sup>10</sup>

We are not aware of any reports of Sweet's syndrome treated with tetracyclines. There is, however, one report of minocycline as a possible causal agent.<sup>11</sup> The success of doxycycline therapy in our patients is unlikely to be a coincidence. Tetracycline has been found to be effective in dermatoses with neutrophilic infiltration. Two of six female patients with a variant of pustular psoriasis reported by Barlow and Schulz<sup>12</sup> responded to treatment with tetracycline. A combination of nicotinamide and tetracycline has been found to be effective in patients with bullous pemphigoid,<sup>13</sup> erythema elevatum diutinum,<sup>14</sup> and linear IgA bullous dermatosis.<sup>15</sup> Tetracycline has been found to suppress leucocyte chemotaxis *in vitro* and *in vivo* at therapeutic serum concentrations,<sup>16</sup> and patients with inflammatory acne vulgaris, who were



treated with oral tetracycline 1 g daily, showed significant suppression of both random migration and chemotaxis of neutrophil polymorphonuclear leucocytes.<sup>17</sup>

The pathogenesis of Sweet's syndrome is not fully understood, but the frequent association with infections suggests that bacterial antigens, or antigen-antibody complexes, may play a pathogenic role. Antigens resulting from tissue breakdown in malignancy are thought to be pathogenic in some cases.<sup>18</sup> The association with arthritis<sup>19</sup> and Sjögren's syndrome,<sup>20</sup> and the prompt response to corticosteroids suggest that immune mechanisms are involved.

The effectiveness of doxycycline in our patients might be due to a combination of anti-inflammatory effects, the inhibition of neutrophil chemotaxis, and its likely suppressive effects on the complement-mediated inflammatory process.

To our knowledge, this is the first report of the successful use of doxycycline in Sweet's syndrome, and we suggest that a trial of this anti-inflammatory antibiotic be considered in this condition, using doses of 200 mg daily.

## References

- 1 Sweet RD. An acute febrile neutrophilic dermatosis. *Br J Dermatol* 1964; **76**: 349-56.
- 2 Mensing H. Akute febrile neutrophile Dermatoze: Sweet-Syndrom. *Med Klin* 1988; **83**: 48-51 (Ger) (Eng Abstr).
- 3 Gunawardena DA, Gunawardena KA, Ratnayaka R, Vasanathan NS. The clinical spectrum of Sweet's syndrome (acute febrile neutrophilic dermatosis)—a report of eighteen cases. *Br J Dermatol* 1975; **92**: 363-73.
- 4 Hönigsmann H, Wolff K. Acute febrile neutrophilic dermatosis (Sweet's syndrome). In: *Dermatology in General Medicine* (Fitzpatrick TB, Eisen AZ, Wolff K, Freedberg IM, Austen KF, eds), 3rd edn., Vol. 1. New York: McGraw Hill, 1986; 1323-8.
- 5 Leibovici V, Matzner Y, Lijovetzky G. Sweet's syndrome. *Int J Dermatol* 1987; **26**: 178-80.
- 6 Saxe N, Gordon W. Acute febrile neutrophilic dermatosis (Sweet's syndrome). Four case reports. *S Afr Med J* 1978; **53**: 253-6.
- 7 Hoffman GS. Treatment of Sweet's syndrome with indomethacin. *J Rheumatol* 1977; **4**: 201-6.
- 8 Koranda W. Behandlung des Sweet-Syndrom mit dapsone. *Akt Dermatol* 1982; **8**: 10-12.
- 9 Kemmett D, Hunter JAA. Sweet's syndrome: a clinicopathologic review of twenty-nine cases. *J Am Acad Dermatol* 1990; **23**: 503-7.
- 10 Saxena U, Ramesh V, Misra RS. Sweet's syndrome in pregnancy. *Dermatologica* 1988; **177**: 20-1.
- 11 Mensing H, Kowalzik L. Acute febrile neutrophilic dermatosis (Sweet's syndrome) caused by minocycline. *Dermatologica* 1991; **182**: 43-6.
- 12 Barlow RJ, Schulz EJ. Chronic subcorneal pustulosis with vasculitis: a variant of generalized pustular psoriasis in black South Africans. *Br J Dermatol* 1991; **124**: 470-4.
- 13 Berk MA, Lorincz AL. The treatment of bullous pemphigoid with tetracycline and niacinamide. *Arch Dermatol* 1986; **122**: 670-4.
- 14 Kohler IK, Lorincz AL. Erythema elevatum diutinum treated with niacinamide and tetracycline. *Arch Dermatol* 1980; **116**: 693-5.
- 15 Peoples D, Fivenson DP. Linear IgA bullous dermatosis: successful treatment with tetracycline and nicotinamide. *J Am Acad Dermatol* 1992; **26**: 498-9.
- 16 Majeski JA, Alexander JW. Evaluation of tetracycline in the neutrophil chemotactic response. *J Lab Clin Med* 1977; **90**: 259-65.
- 17 Esterly NB, Koransky JS, Furey NL, Trevisan M. Neutrophil chemotaxis in patients with acne receiving oral tetracycline therapy. *Arch Dermatol* 1984; **120**: 1308-13.
- 18 Weiss RM, Schulz EJ. Complement deficiency in Sweet's syndrome. *Br J Dermatol* 1989; **121**: 413-15.
- 19 Trentham DE, Masi AT, Bale GF. Arthritis with an inflammatory dermatosis resembling Sweet's syndrome. *Am J Med* 1976; **61**: 424-32.
- 20 Prystowsky SD, Fye KH, Goette KD, Daniels TE. Acute febrile neutrophilic dermatosis associated with Sjögren's syndrome. *Arch Dermatol* 1978; **114**: 1234-5.