

between HP infection and rosacea, we found a more favourable clinical response to anti-HP treatment in the CLO-positive than in the CLO-negative group of rosacea patients. Our results support the theory that HP is not the direct cause of rosacea but that it may be an aggravating factor, probably more in the erythematous type than in the papular and glandular types. However, to establish the exact causative role of HP in rosacea, studies with a larger group of patients must be carried out.

Departments of Dermatology
and *Internal Medicine,
Korea University College of Medicine,
Guro 152-703,
Seoul,
Korea

S.W.SON
I.H.KIM
C.H.OH
J.G.KIM*

References

- 1 Parish LC, Witkowski JA. Acne rosacea and *Helicobacter pylori* betrothed. *Int J Dermatol* 1995; 34: 236–7.
- 2 Rebora A, Drago F, Parodi A. May *Helicobacter pylori* be important for dermatologists? *Dermatology* 1995; 191: 6–8.
- 3 Rebora A, Drago F, Picciotto A. *Helicobacter pylori* in patients with rosacea. *Am J Gastroenterol* 1994; 89: 1603–4.
- 4 Kolibásová K, Tóthová I, Baumgartner J, Filo V. Eradication of *Helicobacter pylori* as the only successful treatment in rosacea. (Letter.) *Arch Dermatol* 1996; 132: 1393.
- 5 Powell FC, Dawa MA, Duguid C. Positive *Helicobacter pylori* serology in rosacea patients. *Ir J Med Sci* 1992; 161: S75 (Abstr.).
- 6 Schneider MA, Skinner RBJ, Rosenberg EW *et al.* Serological determination of *Helicobacter pylori* in rosacea patients and controls. *Clin Res* 1992; 40: 831A (Abstr.).
- 7 Malaty HM, Kim JG, Kim SD *et al.* Prevalence of *Helicobacter pylori* infection in Korean children: inverse relation to socioeconomic status despite a uniformly high prevalence in adults. *Am J Epidemiol* 1996; 143: 257–62.
- 8 Sharma VK, Lynn A, Kaminski M *et al.* A study of the prevalence of *Helicobacter pylori* infection and other markers of upper gastrointestinal tract disease in patients with rosacea. *Am J Gastroenterol* 1998; 93: 220–2.

Minocycline for the treatment of cutaneous silicone granulomas

SIR, Granulomatous reactions named siliconomas have been reported after silicone injections in face or breast soft tissues and after silicone implants.¹ Treatment of siliconoma is difficult and often requires surgical excision. We report two patients with exuberant siliconoma who were successfully treated with minocycline.

The first patient, a 49-year-old woman, presented with a diffuse, erythematous and indurated facial oedema (Fig. 1a). Cervical lymphadenopathy was also noted. Histopathological examination of a skin biopsy showed vacuoles in the dermis surrounded by a dense mononuclear infiltrate (Fig. 2). A clear, greasy material extracted from a fresh biopsy was identified as dimethylsiloxane oil by Fourier transformed infrared spectroscopy. The likely cause was treatment of facial wrinkles by

local injections over a 3-year period, 8 years ago. Prednisone 1 mg/kg per day was first given, but 4 days later the patient developed glucose intolerance for which she required insulin therapy. Because of the glucose intolerance and the lack of efficacy of high doses of prednisone, minocycline 100 mg twice daily was added as adjuvant therapy to the previous corticosteroid regimen.

The clinical response of cutaneous symptoms was noticeable 3 weeks after the introduction of the minocycline and allowed a rapid reduction of the prednisone dosage. The erythematous indurated oedema of the face progressively decreased, leading to a complete resolution in 8 weeks (Fig. 1b). Prednisone was stopped 4 months after the onset of minocycline therapy. Two months later the dose of minocycline was reduced to 100 mg once daily. The oedema reappeared clearly on the lower eyelids. Complete resolution was again rapidly obtained when the dosage of minocycline was increased once more to 100 mg twice daily.

The second patient, a 39-year-old woman, received illicit fluid silicone injections in the soft tissue of the breasts 5 years ago. She developed erythematous lesions which began 2 months after the injections. There was a progressive extension of indurated painful subcutaneous masses on the breasts and painful enlarged axillary lymph nodes. Histopathological examination of a skin biopsy showed vacuoles in the dermis surrounded with a mononuclear cellular infiltrate. Surgical excision was not possible because of the extension of lesions, leading to the introduction of minocycline as first-line therapy at the same dosage as that in the first case. Regression of the inflammatory symptoms and induration began 3 weeks after starting minocycline, and the patient's condition was still improving after 2 months.

The tolerance to the treatment was excellent in both cases.

Many local and general adverse effects were reported after cosmetic usage² of silicone oil (polydimethylsiloxane) injections and its use was progressively abandoned. However, illicit silicone injections are still performed.³ Injected silicone is responsible for granulomatous tissue reactions like foreign body granuloma occurring from a few months to 15 years^{3–5} after injection. These reactions were reported at the site of the injection but also in the lymph nodes and in the liver because of migration of silicone particles.^{2,3} The treatment of siliconoma is difficult and, until now, surgical excision is warranted when possible.⁵ Even though corticosteroids have beneficial effects in the treatment of granulomatous diseases like sarcoidosis, their usage is often associated with serious adverse effects, such as glucose intolerance in our first case and drug dependence leading to a relapse of symptoms when prednisone dosage is tapered.

Minocycline is considered a major drug in the treatment of various dermatoses like acne, rosacea and perioral dermatitis, and more recently in the treatment of rheumatoid arthritis. The beneficial effects of minocycline are related to anti-inflammatory and/or immunomodulating effects and to antigranulomatous properties which have been demonstrated *in vitro*.^{6–8} These data lead to the proposal of minocycline as a therapeutic agent for granulomatous skin reactions.

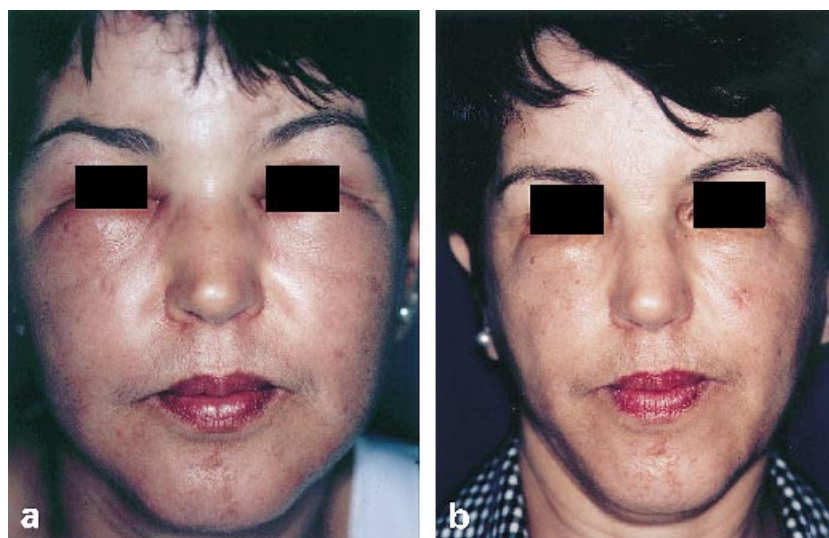


Figure 1. Patient 1. (a) Diffuse erythematous and indurated oedema of the face before treatment with minocycline. (b) Resolution of the oedema 2 months after the beginning of minocycline therapy.

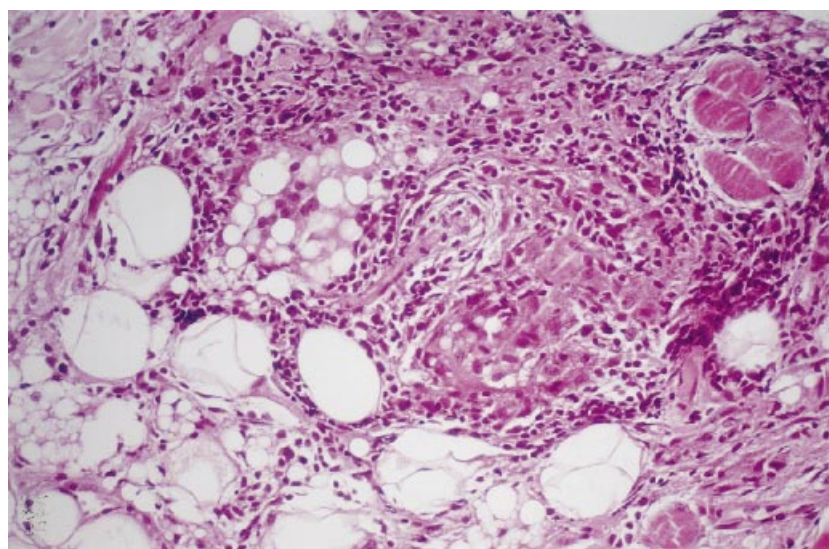


Figure 2. Phagocytic granuloma with lipidic droplets resorption (haematoxylin and eosin, original magnification, $\times 200$).

For both patients, our follow-up period is still short. The duration of the treatment may need to be long, possibly increasing the risk of adverse effects such as pigmentation. These two cases support a role for minocycline in the management of severe granulomas induced by silicone use when surgical excision is not possible.

Acknowledgments

We thank Dr MF Grenier for helpful discussion and for biochemical analysis of the skin biopsy.

Service de Dermatologie,
Institut de Recherche sur la Peau,
Pavillon Bazin,
Paris,
France

P.SENET
H.BACHELEZ
L.OLLIVAUD
D.VIGNON-PENNAMEN*
L.DUBERTRET

*Service d'Anatomopathologie,
Hôpital Saint-Louis,
1 Avenue Claude Vellefaux,
75475 Paris Cedex 10,
France

References

- 1 Faure M. Complications des implants de silicone et autres matériaux dits inertes. *Ann Dermatol Venerol* 1995; **122**: 455–9.
- 2 Ellenbogen R, Ellenbogen R, Rubin L. Injectable fluid silicone therapy. Human morbidity and mortality. *JAMA* 1975; **234**: 308–9.
- 3 Travis WD, Balogh K, Abraham JL. Silicone granulomas: Report of three cases and review of the literature. *Hum Pathol* 1985; **16**: 19–27.
- 4 Achauer BM. A serious complication following medical-grade silicone injection of the face. *Plast Reconstr Surg* 1983; **71**: 251–4.

- 5 Rees TD, Ballantyne DL, Seidman I. Eyelid deformities caused by injection of silicone fluid. *Br J Plast Surg* 1971; **24**: 125–8.
- 6 Celerier P, Litoux P, Dreno B. In vitro modulation of epidermal inflammatory cytokines (IL-1 α , IL-6, TNF α) by minocycline. *Arch Dermatol Res* 1996; **288**: 411–14.
- 7 Webster GE, Toso Sm, Hegemann L. Inhibition of a model of *in vitro* granuloma formation by tetracyclines and ciprofloxacin. Involvement of protein kinase C. *Arch Dermatol* 1994; **130**: 748–52.
- 8 Tilley BC, Alarcon GS, Heyse SP *et al*. Minocycline in rheumatoid arthritis. A 48-week, double-blind, placebo-controlled trial. *Ann Intern Med* 1995; **122**: 81–9.

Bowen's disease of the leg treated with weekly pulses of 5% fluorouracil cream

SIR, Bowen's disease is a premalignant dermatosis characterized histologically as carcinoma *in situ* with full-thickness dysplasia of the epidermis. It mainly affects the elderly¹ and occurs particularly on sun-exposed sites, predominantly the lower legs in women and the scalp and ears in men.^{1,2} Left untreated, 3–5% of patients may develop invasive carcinoma.^{3,4} Among 74 patients with Bowen's disease, invasive carcinoma developed in eight over a 10-year period.⁵ Bowen's disease has a low malignant potential, and metastases develop in less than 1% of cases.⁶

Table 1. Patient details (all are women) and the results of treatment

Age (years)	Duration of treatment (months)	Outcome (? clear)	Rim active?
69	6	no	yes
82	6	no	yes
81	3	yes	no
84	3	no	yes
80	3	yes	no
79	4	no	yes
92	6	yes	no
80	4	no	yes
86	2	yes	no
65	3	no	yes
61	6	no ^b	all active
85	4	yes	no
55	3	no	yes
68	4	yes	no
71	4	yes	no
59	2	yes ^a	no
63	6	no	yes
80	4	yes	no
61	5	no ^b	all active
77	6	no	yes
85	6	no	yes
79	4	no	yes
76	4	yes	no
95	4	yes	no
80	3	yes	no
75	6	no	yes

^a Ulcer developed.

^b No benefit gained.

Bowen's disease of the lower leg may be difficult to treat, particularly in the elderly, who may have thin skin and venous disease. Excision with direct closure may be impossible, and skin grafts or flaps heal poorly on the lower leg.⁷ With cryotherapy, morbidity can be high and healing slow.⁸ Radiotherapy is seldom used on the lower leg because of radiation necrosis and prolonged ulceration.⁹ There is a recurrence rate of 25%¹⁰ for all treatments in Bowen's disease, possibly related to ill-defined margins and follicular involvement.¹⁰ A recurrence rate of 72% after curettage/cautery and 87% after radiotherapy has been reported.¹¹

Actinic keratoses and Bowen's disease are frequently treated with topical 5-fluorouracil (5-FU), twice daily for several weeks, until the lesions become inflamed.^{11,12} Aggressive treatment may cause ulceration, and there is a recurrence rate of 8%.¹⁰ We have examined the efficacy of weekly 'pulse' 5-FU cream (Efudix, Roche) for managing Bowen's disease of the lower leg.

Twenty-six women (mean age 76 years; range 55–95 years) presented with Bowen's disease of the lower leg, present for up to 12 years. The diagnosis was confirmed histologically. The sites of the lesions were recorded and photographed. Patients were instructed to apply 5-FU cream to the lesions in the morning and evening on 1 day each week and given an information sheet that explained the treatment. We emphasized the importance of applying cream to a rim of normal-looking skin around the whole plaque. Treatment

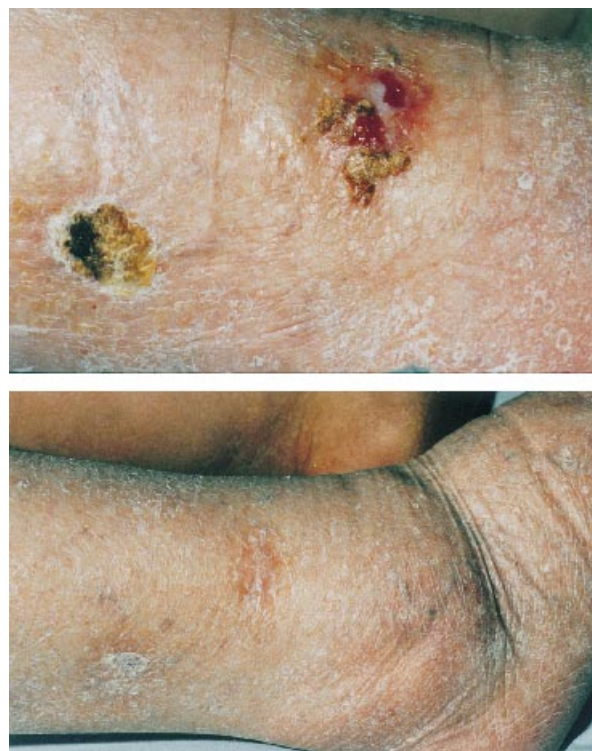

Figure 1. (a) Two areas of Bowen's disease are evident on the lower left leg. (b) The lesions cleared after 3 months of treatment with pulsed 5-fluorouracil cream.