

# **JOURNAL of the** **AMERICAN ACADEMY OF** **DERMATOLOGY**

VOLUME 16 NUMBER 2 PART 1

**february 1987**

**CME article**

**Etretinate therapy**


**CHARLES N. ELLIS, M.D., and JOHN J. VOORHEES, M.D., Ann Arbor, MI**

**PUBLISHED BY THE C.V. MOSBY COMPANY**

**ST LOUIS**

Dr. Reddy's Laboratories, Ltd., et al.  
v.  
Galderma Laboratories, Inc.  
IPR2015-\_\_\_\_\_  
**Exhibit 1061**





# **JOURNAL of the** **AMERICAN ACADEMY OF** **DERMATOLOGY**



VOLUME 16 NUMBER 2 PART 1

**february 1987**

**CME article**


**Etretinate therapy**

**CHARLES N. ELLIS, M.D., and JOHN J. VOORHEES, M.D., Ann Arbor, MI**

**PUBLISHED BY THE C.V. MOSBY COMPANY**  
**ST. LOUIS, MISSOURI 63146**

**ISSN 0190-9622**





**Editor**

J. Graham Smith, Jr., M.D.

**Associate Editor**

Donald C. Abele, M.D.

**Editorial Office**

Department of Dermatology  
Medical College of Georgia  
Augusta, Georgia 30912-7400  
404-828-4684

**Assistant Editors**

Philip C. Anderson, M.D.  
Walter H. C. Burgdorf, M.D.  
Richard L. Dobson, M.D.  
John H. Epstein, M.D.  
Stephen I. Katz, M.D.  
W. Clark Lambert, M.D.  
Walter G. Larsen, M.D.  
Alan R. Shalita, M.D.  
John S. Strauss, M.D.

Vol. 16, No. 2, Part 1, February 1987, the Journal of the American Academy of Dermatology (ISSN 0190-9622) is published monthly by The C. V. Mosby Company, 11830 Westline Industrial Dr., St. Louis, MO 63146.

Annual subscription rates: \$57.00 for individuals, \$104.00 for institutions.

Second class postage paid at St. Louis, MO, and additional mailing offices. Printed in the U.S.A. Copyright © 1987 by the American Academy of Dermatology, Inc.

Postmaster: Send address changes to The C. V. Mosby Company, 11830 Westline Industrial Dr., St. Louis, MO 63146.

**Contents** February, Part 1, 1987

**CONTINUING MEDICAL EDUCATION**

- Etretinate therapy** 267  
Charles N. Ellis, M.D., and  
John J. Voorhees, M.D.,  
*Ann Arbor, MI*

- CME examination** 292

- Answers for CME examination** 294  
(Identification No. 887-101, January 1987  
issue of the JOURNAL OF THE AMERICAN  
ACADEMY OF DERMATOLOGY)

- CME examination answer sheet** 295

**CLINICAL AND LABORATORY STUDIES**

- Isotretinoin treatment of pityriasis  
rubra pilaris** 297  
Charles H. Dicken, M.D., *Rochester, MN*

- Zinc deficiency in two full-term breast-fed  
infants** 301  
Lynne J. Roberts, M.D.,  
Constance F. Shadwick, M.D., and  
Paul R. Bergstresser, M.D., *Dallas, TX*

- Bullous pemphigoid controlled  
by tetracycline** 305  
Carl R. Thornfeldt, M.D., and  
Andrew W. Menkes, M.D.,  
*San Diego, CA*

- Syringoma presenting as milia** 310  
Stephen J. Friedman, Major, MC, USA,  
and David F. Butler, Major, MC, USA,  
*El Paso, TX*

*Continued on page 7A*

5A

# Bullous pemphigoid controlled by tetracycline

Carl R. Thornfeldt, M.D., and Andrew W. Menkes, M.D. *San Diego, CA*

Two men with nonscarring, persistent, localized bullous pemphigoid, whose eruption is completely controlled with daily doses of oral tetracycline, are described. A review of the literature on persistent, localized bullous pemphigoid is presented. The effects of tetracycline on leukocytes that may play a role in the response of these patients are discussed. (*J AM ACAD DERMATOL* 1987;16:305-10.)

Bullous pemphigoid is an autoimmune disease characterized by large, tense, subepidermal bullae. These lesions arise on urticarial plaques, erythematous macules, or normal-appearing skin. They commonly involve flexural areas, especially the groin and axillae.<sup>1,2</sup> In contrast to pemphigus, Nikolsky's sign is absent. Nearly 80% of the individuals afflicted are at least 60 years old, and generally the severity of the disease increases as the age of onset increases. Bullous pemphigoid begins at a localized site and rarely remains localized throughout its course.<sup>3-5</sup> On the basis of the clinical presentation, persistent, localized bullous pemphigoid is divided into scarring and nonscarring forms. Corticosteroids, systemic and/or topical, are usually employed for the treatment of all types of bullous pemphigoid, although in severe cases, immunosuppressive agents or sulfones are required.<sup>2-6</sup> Recently erythromycin has been successfully used to control this disease, as has a combination of tetracycline and niacinamide.<sup>7,8</sup>

## CASE REPORTS

### Case 1

A 66-year-old Filipino man with hypertension and angina complained of a pruritic eruption of 10 years' duration on the lower part of both legs, which was not associated with pustules, painful lymph nodes, or fever.

From the Division of Dermatology, University of California, San Diego, School of Medicine.

Accepted for publication July 17, 1986.

Reprint requests to: Dr. Carl Thornfeldt, 1021 S.W. 5th Ave., Ontario, OR 97914.

He had received nitroglycerin, isosorbide, and nifedipine for his cardiovascular illness.

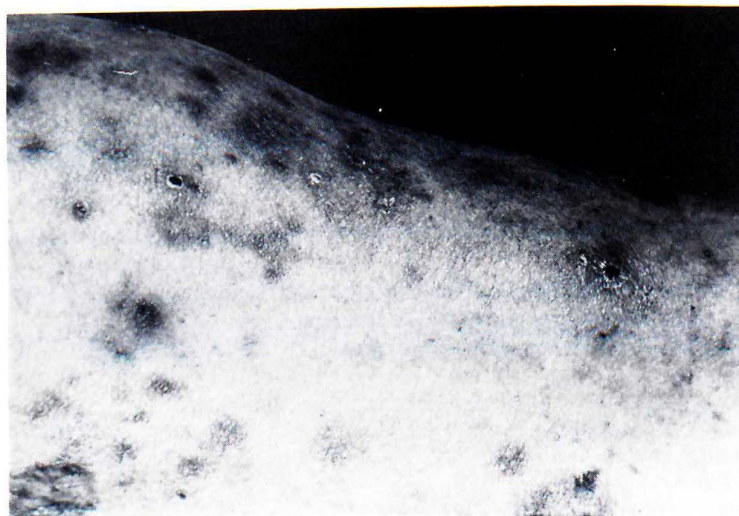
Physical examination revealed a healthy-appearing Oriental man with lesions distributed symmetrically over both pretibial surfaces. The lesions consisted of multiple hyperpigmented macules, several tense, clear vesiculobullae on erythematous and nonerythematous skin, and a few brown-black crusts on erythematous skin (Fig. 1). There was no fever, inguinal adenopathy, or signs of lymphangitis. The white blood cell count, differential count, erythrocyte sedimentation rate, fasting blood sugar level, and urinalysis results were normal, and there were no antinuclear antibodies. Biopsy of a blister on normal-appearing skin showed a non-acantholytic, subepidermal bulla containing a few eosinophils. There was also a mild papillary dermal and perivascular infiltrate consisting of mononuclear cells and a few eosinophils (Fig. 2). Direct immunofluorescence was positive for IgG and C3 in a linear pattern along the basement membrane zone. No circulating antibodies were detected by immunofluorescence with guinea pig esophagus used as a substrate.

The eruption was refractory to topical therapy with betamethasone valerate and dipropionate, the latter with plastic occlusion. A therapeutic trial of oral tetracycline, 250 mg twice daily for 2 to 3 weeks, cleared all the bullae and inflammatory lesions. This therapy was discontinued on two occasions, and within 3 weeks the bullae and erythematous plaques recurred. Reinstitution of oral tetracycline on each occasion resulted in clinical remission for over a year on a regimen of only 250 mg of tetracycline daily.

### Case 2

A 48-year-old Mexican American man with a seizure disorder was referred for a 5-year history of an inter-





**Fig. 1.** Case 1. Several vesicles, crusts, and hyperpigmented macules on the pretibial area.

mittent pruritic, blistering eruption of the medial aspect of the left thigh. The eruption was not associated with other cutaneous lesions nor with systemic symptoms. It had been refractory to mid- and high-potency topical corticosteroids and topical and systemic antimycotic agents. The eruption also was refractory to short courses of diaminodiphenylsulfone and chloroquine. The patient had partial relief of itching and diminished blistering with 60 mg of prednisone daily for 2 weeks. He had initially received phenobarbital and phenytoin for his seizure disorder but had switched to carbamazepine shortly thereafter because of overt seizure activity.

Physical examination revealed an obese man with multiple tense bullae on erythematous plaques and on nonerythematous skin of the proximal medial portion of the left thigh and the left crural fold (Fig. 3). Multiple striae were present. There were no pustules, fever, or lymphadenopathy. Bacterial cultures from the blister fluid were negative. A Tzanck smear from the bulla base revealed no multinucleated giant cells, and a potassium hydroxide smear showed no hyphae. The white blood cell count, differential count, erythrocyte sedimentation rate, fasting blood sugar level, and urinalysis results were normal. There were no antinuclear antibodies. Biopsy of a bulla on an erythematous plaque showed a nonacantholytic, subepidermal bulla containing eosinophils. There was a dense, diffuse papillary dermal mixed infiltrate consisting predominantly of neutrophils, with many eosinophils and few mononuclear cells (Fig. 4). Direct immunofluorescence was positive for linear IgG and C3 along the basement mem-

brane zone. No circulating antibodies were detected by immunofluorescence.

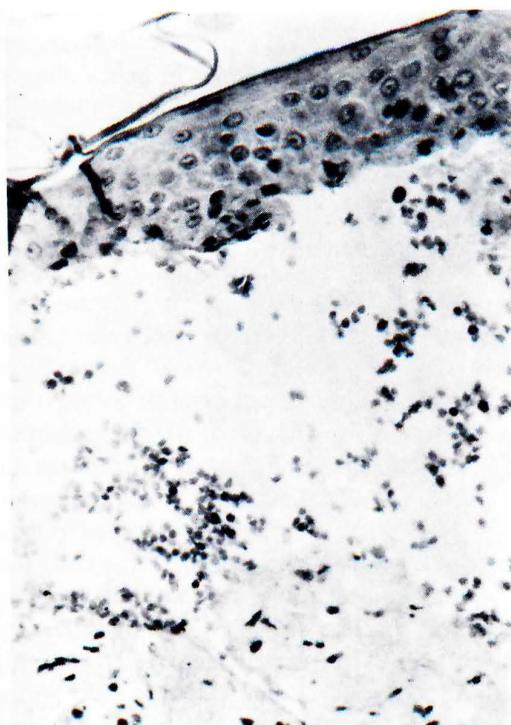
Oral tetracycline, 500 mg twice daily, and prednisone, 60 mg in a single morning dose, produced complete resolution of the eruption in 3 weeks. Ten weeks after tapering off these two agents, the lesions recurred. Both this and a later episode completed cleared after 2 weeks of oral tetracycline, 500 mg three times daily. The patient has now been in clinical remission for 9 months on a regimen of 500 mg of tetracycline in a single daily dose.

## DISCUSSION

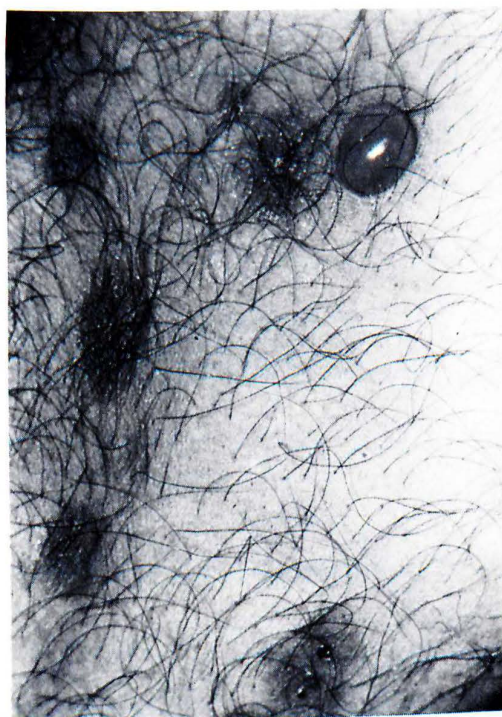Only fifty-eight cases of persistent, localized bullous pemphigoid have been documented in the English-language literature in the past 25 years, but the true incidence of this entity may be much greater. On initial evaluation of patients with bullous pemphigoid, 16.5% of patients in one large series had lesions localized to a single site. However, the lesions on only one fourth of them remained localized. On the other patients, the localized lesions eventually generalized, some even 14 years after the initial eruption.<sup>4,6,9-22</sup> Lesions appearing first over areas of traumatized or preexisting skin disease or lesions distributed periumbilically are especially prone to generalization.<sup>3</sup>

Persistent, localized bullous pemphigoid is divided into Brunsting-Perry pemphigoid, which





**Fig. 2.** Case 1. Subepidermal bulla containing a few eosinophils. ( $\times 25$ .)



**Fig. 3.** Case 2. Tense vesicle on erythematous plaque and tense bulla on nonerythematous skin of the proximal medial portion of the thigh.

scars, and a nonscarring form. Only thirty-nine of the fifty-eight reported cases of persistent, localized bullous pemphigoid provide adequate data to draw conclusions as to sex distribution, anatomic site, and presence of scarring. Of the well-documented cases, two thirds were the Brunsting-Perry type; male patients predominated in this group 3:1. Also called localized chronic pemphigoid, this entity presents with one or several discrete erythematous plaques that eventually heal with atrophic scars.<sup>5,8,10</sup> Brunsting-Perry pemphigoid shares several histologic and immunofluorescent characteristics with both generalized bullous pemphigoid and cicatricial pemphigoid, which will be noted below.<sup>16-20</sup> A recent report documented the coexistence of this entity with generalized bullous pemphigoid in one patient.

The nonscarring form of persistent, localized bullous pemphigoid is characterized by recurrent crops of multiple pruritic, vesiculobullous, and inflammatory lesions usually localized to the pretib-

ial surfaces. They tend to be symmetrical when distributed bilaterally and to heal without scarring. The lesions commonly resolve with postinflammatory hyperpigmentation. Only two of the fourteen reported cases with nonscarring persistent, localized bullous pemphigoid spared the pretibial area. One patient had lesions only on the forearms and periumbilical area; the second had a dyshidrosiform eruption of the palms and soles.<sup>4,11</sup> Recently a patient was reported with pretibial nonscarring persistent, localized bullous pemphigoid and concurrent subcorneal pustulosis and morphea.<sup>21</sup> Except for the man with palm and sole lesions, all the patients with nonscarring persistent, localized bullous pemphigoid reported prior to this communication were postmenopausal women. In patients with generalized bullous pemphigoid, both ultraviolet light and scratching are known to induce bullae identical to the lesions of the disease.<sup>23-25</sup> A relative increase of exposure to these insults by women who usually wear skirts



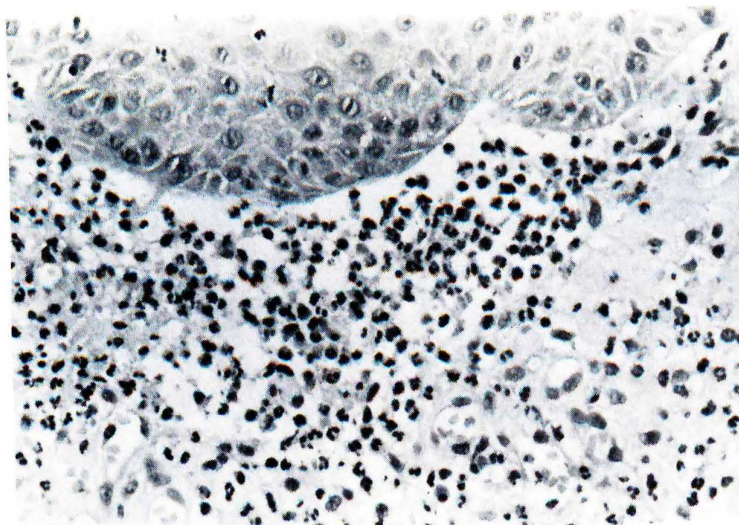


Fig. 4. Case 2. Subepidermal bullae with dense infiltrate consisting predominantly of neutrophils with many eosinophils and a few mononuclear cells. ( $\times 25$ .)

or dresses may account for the predominance of the pretibial site of nonscarring persistent, localized bullous pemphigoid in female patients.

The histologic changes in nonscarring persistent, localized bullous pemphigoid closely resemble those of generalized bullous pemphigoid. As found in our case, in the blisters on nonerythematous skin, there is a nonacantholytic, subepidermal bulla with a rare eosinophil in the cavity associated with a mild papillary dermal and perivascular infiltrate or mononuclear cells and a few eosinophils. Bullae on erythematous skin of nonscarring persistent, localized bullous pemphigoid and in the plaques of the Brunsting-Perry type have a much denser infiltrate usually composed of mononuclear cells and eosinophils but sometimes composed largely of neutrophils.<sup>25</sup> The scarring form also has a significant amount of fibrosis, which is absent in all lesions of nonscarring persistent, localized bullous pemphigoid but present in cicatricial pemphigoid.<sup>8</sup>

In all types of pemphigoid, there is no correlation between the extent of the skin lesions and antibody titers.<sup>3</sup> The immunofluorescent findings in both forms of persistent, localized bullous pemphigoid are identical. Contrary to early reports, current evidence indicates that the incidence of positive findings on direct immunofluorescence in

persistent, localized bullous pemphigoid is similar to that found in generalized bullous pemphigoid. In two recent series of persistent, localized bullous pemphigoid, all thirteen cases studied had linear deposition of IgG and/or C3 at the basement membrane zone.<sup>10,11</sup> However, only two had positive findings on indirect immunofluorescence. This incidence correlates with the 10% to 20% incidence of positive results on determinations of circulating antibodies found in cicatricial pemphigoid.<sup>26</sup>

Brunsting-Perry pemphigoid is usually difficult to control with systemic corticosteroids. Two cases have been reported to respond to sulfones.<sup>8,20</sup> The skin of ten patients with nonscarring persistent, localized bullous pemphigoid cleared with topical corticosteroids and wet compresses. The other four patients required either additional sulfone, sulfapyridine, systemic corticosteroids, or methotrexate to clear the eruption.

Tetracycline, minocycline, and erythromycin all block bacterial protein synthesis by binding to the ribosome 30s subunit, thus competitively inhibiting the binding of transfer ribonucleic acid (RNA) to messenger RNA. Tetracycline and erythromycin, to a lesser degree, both inhibit neutrophil chemotaxis and random migration and thus are also anti-inflammatory. Minocycline and erythromycin at moderate and high concentrations, respectively,



inhibit the mitogenic response of lymphocytes, but tetracycline does not.<sup>27-33</sup> These observations have been confirmed in vitro by two cases of mycosis fungoides that cleared with the use of tetracycline, five cases of pyoderma gangrenosum that responded to minocycline, two cases of bullous pemphigoid that remitted with the use of erythromycin, and four cases of bullous pemphigoid that cleared with the use of tetracycline and niacinamide.<sup>7,34-38</sup>

In summary, the cases of two men with non-scarring persistent, localized bullous pemphigoid are presented. To our knowledge, one is the first man reported to have the lesions localized to the pretibial area. The two men are the first patients with any form of bullous pemphigoid whose eruption is completely controlled by oral tetracycline, possibly because of its effects on polymorphonuclear leukocytes, including eosinophils. These cases indicate that this antibiotic may be used in localized bullous pemphigoid as a sole therapeutic agent or as a systemic corticosteroid-sparing one. Further trials of tetracycline in generalized bullous pemphigoid may reveal a systemic corticosteroid-sparing effect.

## REFERENCES

1. Sams W Jr. Bullous pemphigoid: is it an immunologic disease? *Arch Dermatol* 1970;102:485-7.
2. Domonkos AAN, Arnold HL, Odom RB. Chronic bullous disease. In: Andrews' diseases of the skin. Philadelphia: WB Saunders, 1981:590.
3. Sneddon IB. Bullous eruptions. In: Rook A, Wilkinson DS, Ebling FJG, eds. Textbook of dermatology. Oxford: Blackwell Scientific Publications, 1979:1462-5.
4. Person JR, Rogers RS, Perry HO. Localized pemphigoid. *Br J Dermatol* 1976;95:531-4.
5. Braverman IM. Skin signs of systemic disease, 2nd ed. Philadelphia: WB Saunders, 1981:498-9.
6. Downham TF, Chapel TA. Bullous pemphigoid. *Arch Dermatol* 1978;114:1639-42.
7. Fox BJ, Odom RB, Findlay RF. Erythromycin therapy in bullous pemphigoid: possible anti-inflammatory effects. *J AM ACAD DERMATOL* 1982;7:504-10.
8. Brunsting LA, Perry HO. Benign pemphigoid? A report of seven cases with chronic, scarring herpetiform plaques about the head and neck. *Arch Dermatol* 1957;75:489-501.
9. Ahmed AR. Bullous pemphigoid: clinical and immunologic follow-up after successful therapy. *Arch Dermatol* 1977;113:1043-6.
10. Michel B, Bean SF, Chorzelski T, et al. Cicatricial pemphigoid of Brunsting-Perry. *Arch Dermatol* 1977;113:1403-5.
11. Bernstein JE, Medenica M, Soltani K. Coexistence of localized bullous pemphigoid, morphea and subcorneal pustulosis. *Arch Dermatol* 1981;117:725-7.
12. MacVicar DN, Graham HJ. Localized chronic pemphigoid: a clinicopathologic histochemical study. *Am J Pathol* 1966;48:52.
13. Sparrow GP. Localized pemphigoid. *Br J Dermatol* 1976;95(suppl 14):26-8.
14. Trepanier Y. Localized bullous dermatitis herpetiformis. *Arch Dermatol* 1970;101:98-9.
15. Weedon D, Robertson E. Localized chronic pemphigoid. *J Cutan Pathol* 1976;3:41-4.
16. Jacoby WD Jr, Bartholome CW, Ramchand SC, et al. Cicatricial pemphigoid (Brunsting-Perry type): case report of immunofluorescent findings. *Arch Dermatol* 1978;114:779-81.
17. Nieboer C, Roeleveld CG, Kalsbeek GL. Localized chronic pemphigoid. *Dermatologica* 1978;156:24-33.
18. Graham JH, MacVicar DH. Bullous dermatoses. In: Graham JF, Johnson WC, Helwig EB, eds. Dermatopathology. Philadelphia: Harper & Row, 1972:301-22.
19. Perret WJ. Localized pemphigoid. *Int J Dermatol* 1980;19:47-8.
20. Hanno R, Foster DR, Bean SF. Brunsting-Perry cicatricial pemphigoid with bullous pemphigoid. *J AM ACAD DERMATOL* 1980;3:470-3.
21. Levine N, Freilich A, Barland P. Localized pemphigoid simulating dyshidrosiform dermatitis. *Arch Dermatol* 1979;115:320-1.
22. Person JR, Rogers RS. Bullous and cicatricial pemphigoid. *Mayo Clinic Proc* 1977;52:54-66.
23. Cram DL, Fukuyama K. Immunohistochemistry of ultraviolet-induced pemphigus and pemphigoid lesions. *Arch Dermatol* 1972;106:819-24.
24. Dahl MGC, Cook LJ. Lesions induced by trauma in pemphigoid. *Br J Dermatol* 1979;101:469-73.
25. Lever WF, Schaumburg-Lever G. Histopathology of the skin, 6th ed. Philadelphia: JB Lippincott, 1983:114, 116.
26. Perry HO. Cicatricial pemphigoid. In: Demis DJ, Dobson RL, McGuire J, eds. Clinical dermatology. Philadelphia: Harper & Row, 1982:3 (sections 6-13).
27. Esterly NB, Furey NL, Flanagan LE. The effect of antimicrobial agents on leukocyte chemotaxis. *J Invest Dermatol* 1978;70:51-5.
28. Plewig G, Schopf E. Anti-inflammatory effects of antimicrobial agents: an in vivo study. *J Invest Dermatol* 1975;65:532-6.
29. Martin RR, Warr GA, Couch RB, et al. Effect of tetracycline on leukotaxis. *J Infect Dis* 1974;129:110-6.
30. Forsgren A, Schmeling D. Effect of antibiotics on chemotaxis of human leukocytes. *Antimicrob Agents Chemother* 1977;11:580-4.
31. Banck G, Forsgren A. Antibiotics and suppression of lymphocyte function in vitro. *Antimicrob Agents Chemother* 1979;16:554-60.
32. Thong TG, Ferrante A. Inhibition of mitogen-induced human lymphocyte proliferative responses to tetracycline analogues. *Clin Exp Immunol* 1979;35:443-6.
33. Elewski BE, Lamb BAJ, Sams W Jr, Gammon WR. In vivo suppression of neutrophil chemotaxis by systemically and topically administered tetracycline. *J AM ACAD DERMATOL* 1983;8:807-12.
34. Lynch WS, Bergfeld WE. Pyoderma gangrenosum re-



- sponsive to minocycline hydrochloride. *Cutis* 1978; 21:535-8.
35. Davies MG, Piper S. Pyoderma gangrenosum: successful therapy with minocycline. *Clin Exp Dermatol* 1980; 6:219-23.
  36. Shelley WB. Demethylchlortetracycline and griseofulvin as examples of specific treatment for mycosis fungoides. *Br J Dermatol* 1981;104:477.
  37. Thomsen K. Mycosis fungoides responding to demethylchlortetracycline and griseofulvin. *Br J Dermatol* 1981; 105:483-4.
  38. Berk MA, Lorincz AL. The treatment of bullous pemphigoid with tetracycline and niacinamide. *Arch Dermatol* 1986;122:670-4.

## Syringoma presenting as milia\*

Stephen J. Friedman, Major, MC, USA, and David F. Butler, Major, MC, USA  
*El Paso, TX*

We present two unrelated patients with numerous infraocular milium-like lesions that histologically revealed syringoma with many overlying keratin cysts in the papillary dermis. A Fontana-Masson stain revealed no melanin-containing cells in the keratin cyst walls, suggesting that they originated from eccrine ductal structures. A classification of the clinical variants of syringoma is presented. (*J AM ACAD DERMATOL* 1987;16:310-4.)

Syringomas are common benign appendageal tumors derived from the intraepidermal eccrine ducts.<sup>1,2</sup> Although sometimes solitary,<sup>3</sup> syringomas usually are multiple and localized,<sup>4-13</sup> although they may be generalized.<sup>14,15</sup> Usually the lesions are small, firm, dermal papules ranging in size from a few millimeters to 1 cm. Ordinarily, they are flesh-colored but may be in shades of red, tan, or brown. Multiple lesions may simulate multiple basal cell carcinomas, pigmented nevi, trichoepitheliomas, angiofibromas, cylindromas, and lichen planus-like lesions.<sup>2,7,14</sup> We found no mention in the literature of syringoma presenting as milium-like lesions. We report two patients with multiple clustered infraorbital milium-like lesions with typical histologic findings of syringoma.

From the Department of Internal Medicine Dermatology Service, William Beaumont Army Medical Center.

Accepted for publication July 17, 1986.

Reprint requests to: Dr. Stephen J. Friedman, Dermatology Service, William Beaumont Army Medical Center, El Paso, TX.

\*The opinions or assertions contained herein are the private views of the authors and are not to be construed as official or as reflecting the views of the Department of Defense.

### CASE REPORTS

#### Case 1

A 23-year-old white woman presented to the William Beaumont Army Medical Center Dermatology Clinic in August 1985, complaining of the gradual appearance of grouped white papules on the lower eyelids and upper aspect of the cheeks for 3 years. The lesions were asymptomatic but were of cosmetic concern. There was no history of local trauma. The patient was in excellent health. No other family members had a similar problem.

Examination revealed multiple white, firm, globoid papules measuring 1-3 mm in diameter on the lower eyelids and upper aspect of the cheeks bilaterally (Fig. 1). No similar lesions were present elsewhere.

#### Case 2

A 20-year-old Latin-American man presented to the dermatology clinic in April 1986, complaining of the gradual appearance of grouped white papules on the lower eyelids and upper aspect of the cheeks for 3 years. The lesions were asymptomatic but were of cosmetic concern. There was no history of local trauma. The patient was in excellent health. No other family members had a similar problem.

Physical examination revealed multiple white, firm, globoid papules measuring 1-3 mm in diameter on the