

JOURNAL of the American Academy of Dermatology

Univ. of Minn.
Bio-Medical
Library
1 06 93

VOLUME 28 NUMBER 1

January 1993

CME article


Cutaneous markers of internal malignancy.
I. Malignant involvement of the skin and the genodermatoses

STACIA POOLE, MD, and NEIL A. FENSKE, MD Tampa, Florida

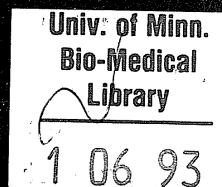
Self-Assessment examination

PUBLISHED BY MOSBY-YEAR BOOK, INC.
ST. LOUIS

Dr. Reddy's Laboratories, Ltd., et al.
v.
Galderma Laboratories, Inc.
IPR2015-_____
Exhibit 1062



JOURNAL of the American Academy of Dermatology



VOLUME 28 NUMBER 1

January 1993

CME article

**Cutaneous markers of internal malignancy.
I. Malignant involvement of the skin and the genodermatoses**

STACIA POOLE, MD, and NEIL A. FENSKE, MD Tampa, Florida

Self-Assessment examination

PUBLISHED BY MOSBY-YEAR BOOK, INC.

ST. LOUIS, MISSOURI 63146

ISSN 0190-9622

- cal correlations, and a review of the literature. *Am J Clin Pathol* 1972;58:524-30.
9. Martin S. Cryofibrinogenemia, monoclonal gammopathy, and purpura. *Arch Dermatol* 1979;115:208-11.
 10. Jager BV. Cryofibrinogenemia. *N Engl J Med* 1962;266:579-83.
 11. Ritzman SE, Levin WC. Cryopathies: a review. *Arch Intern Med* 1961;107:186-204.
 12. Kalbfleisch JM, Bird RM. Cryofibrinogenemia. *N Engl J Med* 1960;263:881-6.
 13. Rachmilewitz EA, Sacks MI, Zlotnik A. Essential cryofibrinogenemia: clinical pathological and immunological studies. *Isr J Med Sci* 1970;6:32-43.
 14. Copeman PWM. Cryofibrinogenemia and skin ulcers: treatment with plasmapheresis [Abstract]. *Br J Dermatol* 1979;101(suppl 17):57.
 15. Jarrett PEM, Morland M, Clemenson G. Treatment of Raynaud's syndrome with stanozolol [Abstract]. *Br J Surg* 1975;62:654.
 16. Ayres ML, Jarrett PEM, Browse NL. Blood viscosity, Raynaud's phenomenon and the effect of fibrinolytic enhancement. *Br J Surg* 1981;68:51-4.
 17. Davidson JF, Lochhead M, McDonald GA, et al. Fibrinolytic enhancement by stanozolol: a double blind trial. *Br J Haematol* 1972;22:543-59.
 18. Glazer G. Atherogenic effects of anabolic steroids on serum lipid levels. *Arch Intern Med* 1991;151:1925-33.

Treatment of generalized bullous pemphigoid with oral tetracycline

Isabelle Thomas, MD, Sylvie Khorenian, MD, and David M. Arbesfeld, MD
Newark, New Jersey

Background: Although bullous pemphigoid (BP) is a benign self-limited disease, the mainstay of treatment remains systemic steroids, often in combination with immunosuppressive agents. This therapy has considerable potential toxicity, particularly in elderly patients with preexisting problems.

Objective: The purpose of this study was to evaluate the efficacy of oral tetracycline as first-choice therapy in patients with BP.

Methods: Every patient newly diagnosed with generalized BP was treated with oral tetracycline and a midpotency topical steroid.

Results: In all five patients, blister formation was stopped and reepithelialization completed within 1 to 3 weeks. There was no relapse or toxicity noted; follow-up ranged from 16 to 24 months.

Conclusion: Oral tetracycline was found to be rapidly efficacious in all patients and devoid of toxicity.

(*J AM ACAD DERMATOL* 1993;28:74-7.)

Bullous pemphigoid (BP) is an autoimmune disorder that tends to affect elderly persons who frequently have preexisting medical problems. Its course is relatively benign and, unlike pemphigus vulgaris, rarely life-threatening, even without treatment.¹ However, the tendency has been to treat these patients with systemic steroids in a manner similar to pemphigus. As a result, the side effects resulting from therapy often tend to be more severe than the disease itself. In the present study, in an attempt to avoid systemic steroids, we treated every

patient with a confirmed diagnosis of BP with oral tetracycline and midpotency topical steroids.

METHODS

The diagnosis was based on clinical examination and histologic and direct and indirect immunofluorescence studies. Patients were observed weekly until blister formation stopped, monthly until therapy was discontinued and then every 6 months.

RESULTS

The case reports are summarized in Tables I and II. All patients were men, which reflects the patient population seen at our medical center. Three were black and two white. Age of the patients ranged from 63 to 84 years (mean 71 years). Duration of

From the New Jersey Medical School and the Dermatology Service,
East Orange Veterans Administration Medical Center.

No reprints available.

16/1/41471

Table I. Characteristics of the patients

Patient No.	Age (yr)	Sex	Medical history	Medications	Lesions
1	63	Male	Hypertension Right CVA Left hemiparesis Seizures	HCTZ [*] Isosorbide Phenytoin Hydroxyzine	Multiple Face, neck Extremities Trunk
2	70	Male	Hypertension Bilateral CVA CHF Dementia ITP	HCTZ Phenytoin Danazol Prednisone 20 mg q.d.*	Multiple Trunk Extremities
3	75	Male	Hypertension Arrhythmia Abdominal aortic aneurysm Diabetes mellitus	HCTZ Captopril Nitroglycerin Dipyridamole Acetylsalicylic acid	Multiple Neck Trunk Extremities Mouth (one)
4	63	Male	Unremarkable	None	Multiple Trunk Extremities
5	84	Male	Hypertension Left CVA	HCTZ	Scattered Trunk Extremities

CHF, Congestive heart failure; CVA, cerebrovascular accident; HCTZ, hydrochlorothiazide; ITP, idiopathic thrombocytopenic purpura.

*Administered for ITP.

disease was 3 weeks to 6 months before the initiation of tetracycline. Four patients had hypertension complicated by cerebrovascular accidents in three patients. One had diabetes mellitus. Lesions were generalized in all patients, but less numerous in one. In all cases, the histologic findings were consistent with the diagnosis of BP, showing a subepidermal bulla with a mixed dermal inflammatory infiltrate made of mononuclear cells and eosinophils. Direct immunofluorescence was positive in all cases, with a linear deposition of IgG and C3. Indirect immunofluorescence was positive in three cases and negative in two. Except for one patient, all were treated with tetracycline, 2 gm daily, and a midpotency topical steroid cream. Bulla formation was significantly reduced within 1 week and stopped within 1 to 3 weeks. Complete reepithelialization was noted after 1 to 3 weeks. The 2 gm dosage was maintained for 1 to 2 months, decreased by 500 mg decrements every month, and then stopped. All patients are in remission at this time; there has been no relapse, except in one patient for whom tetracycline was discontinued too soon. Follow-up after discontinuation of tetracycline ranges from 16 to 24 months. No toxicity or morbidity was noted.

DISCUSSION

Until Lever's description in 1953,² BP had been grouped with pemphigus vulgaris. In 1967, in confirmation of Lever's hypothesis, Jordon et al.³ defined both disorders as distinct immunologic entities. Unlike pemphigus vulgaris in which the mortality rate was high (90%) before the steroid era, the natural course of BP tends to be more benign and less protracted. It rarely lasts more than 5 to 6 years and has a low mortality rate even if untreated. BP is characterized by spontaneous remissions and exacerbations; relapses are easily controlled.⁴ However, to date systemic steroids remain the mainstay of therapy for generalized disease.⁵ To reduce the dose of steroids and their side effects, immunosuppressive agents such as azathioprine, cyclophosphamide, methotrexate, or chlorambucil with their own potential toxicity are frequently used, sometimes from the onset.

It seems that in many cases the toxicity resulting from treatment is disproportionate to the low risk from the disease itself. Only recently have more benign treatments been reported. Erythromycin has been used in a few cases since 1982, but results are inconclusive.^{6,7} Topical steroids have generally been

Table II. Therapy and results

Patient No.	Disease duration (mo)	Treatment	Results		
			Blisters	Reepithelialization	Follow-up after discontinuation of TCN
1	4 mo	Betamethasone valerate 0.1% cream × 1 wk Betamethasone dipropionate 0.05% cream—TCN × 1 mo, 2 gm × 2 mo, 1.5 gm × 2 mo, 1 gm × 2 mo, 500 mg × 2 mo, then stopped	None at 3 wk	3 wk	16 mo, no relapse to date
2	Unknown	Fluocinonide 0.05% ointment TCN 2 gm × 1 mo, 1.5 gm × 1 mo, 1 gm × 1 mo, 500 mg × 1 mo, then stopped	None at 1 wk	2 wk	16 mo, died of gastrointestinal bleeding
3	1 mo	Fluocinonide 0.05% ointment TCN 2 gm × 1 mo, then stopped TCN 2 gm × 1 mo, 1.5 gm × 1 mo, 1 gm × 1 mo, 500 mg × 1 mo, then stopped	None at 1 wk None at 1 wk	2 wk 1 wk	Mild flare at 2 wk after discontinuation of TCN 24 mo
4	1 mo	Fluocinonide 0.05% ointment TCN 2 gm × 1 mo, 1.5 gm × 1 mo, 1 gm × 1 mo, 500 mg × 1 mo, then stopped	None at 1 wk	1 wk	21 mo
5	6 mo	Fluocinonide 0.05% ointment alone TCN × 4 mo TCN 1 gm × 2 mo, 500 mg × 2 mo, then stopped	1 to 2 per wk None at 1 wk	Erosions 1 wk	N/A

N/A, Not applicable; TCN, tetracycline.

reserved for localized disease although clobetasol propionate alone was reported to clear 10 patients, but the extent of the bullous eruption was not specified.⁸

Tetracycline alone has been used for localized disease⁹ or in combination with niacinamide.¹⁰ However, there is no publication on the use of tetracycline alone for generalized disease.

Antibiotics such as tetracycline and erythromycin block bacterial synthesis by binding to the ribosomal 30s subunit and competitively inhibit the binding of transfer RNA to messenger RNA. They suppress inflammation by inhibiting neutrophil chemotaxis and random migration in vitro and in vivo.¹¹ In BP they may inhibit the complement-mediated inflammatory response to the basement membrane zone

and mediators of the inflammatory response. In addition, tetracycline has been shown to affect the cohesion of the dermoepidermal junction.¹² In rats, it significantly prolongs suction blister time, which suggests that cohesion of the dermoepidermal junction is increased.¹³

Therapy with systemic steroids in elderly debilitated patients has considerable potential toxicity. Deaths, particularly from bronchopneumonia associated with systemic steroids, are still reported in recent publications.¹⁴⁻¹⁶ The use of immunosuppressive agents as steroid-sparing agents also carries its own potential morbidity. In addition, steroids do not seem to clear the bullous eruption more quickly or prevent relapses more effectively than tetracycline.

It seems that it would be worth trying a more benign treatment first rather than using systemic steroids or immunosuppressive agents from the start. In our study all patients responded rapidly to tetracycline therapy, and there was no relapse or morbidity.

REFERENCES

1. Lever WF. Pemphigus and pemphigoid. *J AM ACAD DERMATOL* 1979;1:2-31.
2. Lever WF. Pemphigus. *Medicine* 1953;32:1-123.
3. Jordon RE, Beutner EH, Witebsky E, et al. Basement membrane zone antibodies in bullous pemphigoid. *JAMA* 1967;200:751-6.
4. Person JR, Rogers RS. Bullous and cicatricial pemphigoid. *Mayo Clin Proc* 1977;52:54-66.
5. Korman N. Bullous pemphigoid. *J AM ACAD DERMATOL* 1987;16:907-24.
6. Fox BJ, Odom RB, Findlay RF. Erythromycin therapy in bullous pemphigoid: possible anti-inflammatory effects. *J AM ACAD DERMATOL* 1982;7:504-10.
7. Rigon JL. Traitement de la pemphigoïde bulleuse par l'érythromycine. Thèse Nancy, 1986:1-150.
8. Westerhof W. Treatment of bullous pemphigoid with topical clobetasol propionate. *J AM ACAD DERMATOL* 1989; 20:458-61.
9. Thornfeldt CR, Menkes AW. Bullous pemphigoid controlled by tetracycline. *J AM ACAD DERMATOL* 1987; 16:305-10.
10. Berk MA, Lorincz AL. The treatment of bullous pemphigoid with tetracycline and niacinamide. *Arch Dermatol* 1986;122:670-4.
11. Esterly NB, Furey NL, Flanagan LE. The effect of antimicrobial agents on leukocyte chemotaxis. *J Invest Dermatol* 1978;70:51-5.
12. Humbert P, Treffel P, Chapuis J-F, et al. The tetracyclines in dermatology. *J AM ACAD DERMATOL* 1991;25:691-7.
13. Humbert P, Renaud A, Millet J, et al. Evaluation of the effect of heparin and tetracycline on the cohesion of the dermal-epidermal junction. *Acta Dermatol Venereol (Stockh)* 1989;69:434-6.
14. Stevenson CJ. Treatment in bullous diseases with corticosteroid drugs and corticotrophin. *Br J Dermatol* 1960;72:11-21.
15. Savin JA. The events leading to the death of patients with pemphigus and pemphigoid. *Br J Dermatol* 1979;101:521-34.
16. Milligan A, Hutchinson PE. The use of chlorambucil in the treatment of bullous pemphigoid. *J AM ACAD DERMATOL* 1990;22:796-801.

BOUND VOLUMES AVAILABLE TO SUBSCRIBERS

Bound volumes of the JOURNAL OF THE AMERICAN ACADEMY OF DERMATOLOGY are available to subscribers (only) for the 1993 issues from the Publisher at a cost of \$69.00 for domestic, \$91.83 for Canadian, and \$87.00 for international for volume 28 (January-June) and volume 29 (July-December). Shipping charges are included. Each bound volume contains a subject and author index and all advertising is removed. Copies are shipped within 60 days after publication of the last issue in the volume. The binding is durable buckram with the journal name, volume number, and year stamped in gold on the spine. *Payment must accompany all orders.* Contact Mosby-Year Book, Inc., Subscription Services, 11830 Westline Industrial Dr., St. Louis, MO 63146-3318. USA: phone (800) 325-4177, ext. 4351; (314) 453-4351.

Subscriptions must be in force to qualify. Bound volumes are not available in place of a regular journal subscription.