

ARTICLES



ROSACEA: WHERE ARE WE NOW?

JOSEPH B BIKOWSKI MD¹, MITCHEL P GOLDMAN MD²

1 BIKOWSKI SKIN CARE CENTER, SEWICKLEY, PENNSYLVANIA

2 DEPARTMENT OF DERMATOLOGY/MEDICINE, UNIVERSITY OF CALIFORNIA, SAN DIEGO, CALIFORNIA, AND DERMATOLOGY/COSMETIC LASER ASSOCIATES OF LA JOLLA, INC., LA JOLLA, CALIFORNIA

Abstract

Advances continue to be made in the classification and treatment of rosacea, a chronic dermatologic syndrome. A new empiric classification system identifies 4 rosacea subtypes (erythematotelangiectatic, papulopustular, phymatous, and ocular) that may aid in more precise diagnosis. Several new therapies have recently been approved for treatment of rosacea. Azelaic acid 15% gel is a new first-tier topical agent proven effective in reducing inflammatory lesions and erythema. New formulations of metronidazole and sulfacetamide 10%/sulfur 5% that offer cosmetic or tolerability advantages are now available. Intense pulsed light therapy has demonstrated effectiveness in reducing flushing, erythema, and telangiectases, with greater tolerability than existing laser systems. Other treatments under investigation include low-dose doxycycline hyclate (which may provide greater safety than existing oral antibiotics), benzoyl peroxide/clindamycin gel, and tacrolimus ointment (for steroid-induced rosacea). With this expanded armamentarium of medical and light-based therapies, clinicians can now implement a multifaceted approach to treatment, crafting new treatment combinations to address the unique and evolving features of rosacea in each individual patient.

Introduction

To date, there is no clearly identified cause for rosacea and no recognized cure^{1,4}. Rosacea is a condition that is managed. For many of the 14 million Americans diagnosed with this dermatologic syndrome, the marked stigmata of rosacea contribute to low self-esteem, stress on the job, and social isolation^{1,5}. Thus, the paramount goal of all rosacea management strategies must be to improve quality of life for patients. Fortunately, new advances in the understanding of rosacea and an expanding array of treatment options are making it possible to more finely tune treatment to address the individual needs of each patient, leading to improved outcomes. This article will review advances in the classification and treatment of rosacea that have occurred over the last few years and will suggest a multifaceted approach to treatment of each recognized subtype of rosacea.

A More Precise Classification System

Rosacea is not a disease but rather a syndrome with an individual presentation in each patient¹. Most patients experience

flushing and/or erythema; many present with inflammatory papules and pustules, edema, telangiectasia, or ocular symptoms; a few (mostly men) develop rhinophyma^{1,3}. In each patient, these characteristic signs and symptoms appear in different configurations that often change over time, as flare-ups interrupt periods of remission^{1,3}. Historically, rosacea has been described in terms of 4 stages: prerosacea (intermittent episodes of flushing or blushing); stage 1 (erythema persisting for hours or days and tiny telangiectases); stage 2 (inflammatory papules and pustules, persistent erythema, more telangiectasia); and stage 3 (moderate to severe erythema, inflammatory lesions, and/or telangiectasia, appearance of phymas)^{1,3,7}. Many practitioners, as well as the published literature and clinical trial evaluations, continue to rely on this staging system. However, stages imply a progressive disease course, suggesting that flushing leads to persistent erythema, then eventually to the appearance of inflammatory lesions, worsening telangiectasia, and in some cases phymatous growth. This evolutionary progression, while observed in some patients, is not congruent with clinical findings by dermatologists in many patients.

A standard, empiric classification system, developed by an expert committee of the National Rosacea Society and published in 2002, aims to establish a more scientifically precise paradigm for diagnosis of rosacea². Because there is no clear etiology or pathogenesis of rosacea, the classification is based on morphologic characteristics. Four primary features of rosacea are identified: flushing, nontransient erythema, papules and pustules, and telangiectasia. At least 1 of these features, with a central face distribution, is required for a diagnosis of rosacea.

ADDRESS FOR CORRESPONDENCE:

Joseph B Bikowski MD
Bikowski Skin Care Center
500 Chadwick St
Sewickley, PA 15143
Phone: (412) 741-2810

Secondary features that may be present include burning/stinging, plaque, dry appearance, edema, ocular manifestations, peripheral location, and phymatous changes. Common patterns of features are grouped into 4 subtypes (erythematotelangiectatic, papulopustular, phymatous, and ocular) and 1 variation (granulomatous), described in Table I¹. Differences in severity may occur within each subtype, and some patients may have features of more than one subtype simultaneously².

This standard classification has not yet been universally embraced by dermatologists, in part because it is perceived to be complex. However, this complexity reflects the attempt to

remain in the investigational stage. The following section will review both newly approved therapies for rosacea and investigational agents that have shown early promise.

Oral Therapies

There have not been any major advances in systemic treatments for rosacea for several decades. The oral antibiotics (tetracycline, doxycycline, minocycline, erythromycin, and metronidazole) that are used off-label to treat rosacea, primarily the papulopustular subtype, have been available for the past 30 to 40 years^{3,9}. While their efficacy is well established, the

Table I. Characteristics of 4 rosacea subtypes and a variant²

Subtype	Characteristics
Erythematotelangiectatic	Flushing and persistent central facial erythema with or without telangiectasia.
Papulopustular	Persistent central facial erythema with transient, central facial papules or pustules or both.
Phymatous	Thickening skin, irregular surface nodularities, and enlargement. May occur on the nose, chin, forehead, cheeks, or ears.
Ocular	Foreign-body sensation in the eye, burning or stinging, dryness, itching, ocular photosensitivity, blurred vision, telangiectasia of the sclera or other parts of the eye, or periorbital edema.
Variant	
Granulomatous	Noninflammatory; hard; brown, yellow, or red cutaneous papules; or nodules of uniform size.

precisely describe the numerous features of the rosacea syndrome and systematically organize them into definable subtypes. More time is needed to determine the validity and practical relevance of this classification in patient diagnosis and treatment. Nevertheless, careful assessment of each patient's disease features and determination of the relevant rosacea subtype(s) under the new classification can be useful in developing an effective individualized treatment plan for each patient, as discussed later in this article.

New Therapies for Rosacea

Several new agents have recently become available or are currently being explored for use in the treatment of rosacea. As shown in Table II, the Food and Drug Administration has approved a number of new or reformulated topical agents and light-based therapies for use in rosacea, while other agents

possible associated adverse events generally make long-term use undesirable. This is a serious problem given the chronicity of rosacea, which requires long-term maintenance therapy or repeated treatment of recurrences. Efforts to improve systemic therapy are currently focused on improving safety to permit extended use.

Early results suggest that a low, subantimicrobial dose of doxycycline may provide efficacy in rosacea with a reduced incidence of adverse events¹⁰. The tetracycline doxycycline hyclate is currently used as first- or second-tier therapy for rosacea at a daily dose of 100 - 200 mg¹¹⁻¹³. Though it is generally well tolerated, known adverse events include skin rash, gastrointestinal distress, esophageal irritation, and (rarely) photosensitivity^{6,11,13}. Tetracyclines, including doxycycline, have been discovered to have nonantimicrobial properties (i.e., inhibition of matrix-degrading metalloproteinases (MMPs)). At subantimicrobial doses, they have been shown to provide activity against chronic

Table II. New treatments recently FDA approved or under investigation for the treatment of rosacea

Topical Agents	Light-based Therapies	Systemic Agents
New therapeutic class	Intense pulsed light devices	Doxycycline hyclate
Azelaic acid 15% gel (Finacea™)	Various devices with outputs of 560-900 nm, spot sizes ranging from 4 - 8 mm to 10 - 50 mm, and maximum fluence ranging from 10 - 90 J/cm²	Subantimicrobial-dose 20 mg (Periostat®)
Existing therapeutic classes		Topical Agents
Metronidazole Topical emulsion 0.75% (Rozex™)	Aurora SR™ and SR/DS™ D-Light SR™ EsteLux™ Lux Y™ and Lux G™ IPL™ Quantum HR and SR Multilight® HR OmniLight™ FPL Photoderm® VL/PL Platinum HR/SR Prolite™ SpectrPulse® Vasculight™ Elite, HR, SR, and VS	Benzoyl peroxide 5%/clindamycin 1% gel (BenzaClin®, Duac™)
Sulfacetamide 10%/sulfur 5% Green tinted gel (Avar™ Green) Untinted gel and cleanser (Avar™) Aqueous gel and cleanser in 10% urea vehicle (Rosula®) Alcohol-free emollient cream and foaming wash (Clenia™) pH neutral cleanser (Rosanil™) Combination cream with two sunscreens (Rosac®)		Tacrolimus 0.1% ointment (Protopic®)

periodontitis and acne without an effect on the bacterial microflora. Thus, efficacy is achieved with a low incidence of side effects and reduced risk of development of bacterial resistance¹⁰.

Low-dose doxycycline hyclate (Periostat®) has recently shown promise in treatment of rosacea. An 8-week open-label study evaluated monotherapy with doxycycline 20 mg twice daily in patients with all stages of rosacea (N=50); most patients had received no prior treatment. At an average of 4 weeks, patients showed an 80% to 100% reduction in inflammatory lesions, a 50% decrease in erythema, and a decrease in the size and diameter of telangiectases. These outcomes are consistent with those reported for conventional doses of tetracyclines. No incidence of nausea, vomiting, headache, diarrhea, vaginitis, or photosensitivity was reported, even in patients who had previously reported such events while taking higher doses of doxycycline¹⁰.

A phase 3 multicenter, double-blind, placebo-controlled trial (N=150) to evaluate the effectiveness of monotherapy with subantimicrobial-dose doxycycline (doxycycline hyclate 20 mg twice daily) for 4 months is currently being conducted. Results from this trial, expected in 2004, may help determine the future role of low-dose antibiotic therapy in the long-term treatment of rosacea.

Another possible new oral therapy for the management of rosacea is prophylactic use of baby aspirin. Migraine headaches

are reported 2 to 3 times more frequently in rosacea patients, perhaps due to the vascular instability associated with both conditions^{14,15}. Some neurologists recommend use of baby aspirin (81 mg enteric coated) as prophylaxis against migraine headaches. In Dr. Bikowski's personal experience over a 2-year period among approximately 100 patients who took 1 baby aspirin nightly, the majority reported a subjectively significant decrease in flushing and subsequent erythema after 1 to 3 months of treatment. However, to date there have been no controlled trials validating use of aspirin in rosacea.

Topical Agents

Over the past decade, improvements in the topical therapy arena have been limited to the development of new formulations (i.e., creams, lotions, gels, emulsions, cleansers) and different dose concentrations (e.g., 0.75% vs. 1%) of existing therapeutic agents, such as metronidazole and sulfacetamide 10%/sulfur 5%. This fine-tuning has contributed to improved delivery of the active agent into the skin, enhanced cosmetic acceptability of medications, and some reduction in skin irritation¹⁶. However, introduction of new topical agents that provide improved efficacy and/or tolerability can ultimately be expected to have a greater impact overall on patient well-being.

Azelaic acid gel

Azelaic acid is a naturally occurring dicarboxylic acid that has shown anti-inflammatory effects in vitro^{17,18}. It has recently been developed as a polyacrylic-acid-based aqueous 15% gel

J Drugs Dermatol 2004; 3(3):251-261

with several advantages over the 20% cream formulation, including improved drug release and absorption. The gel incorporates a higher percentage of micronized azelaic acid (25%) than the cream (3%). In vitro, 25.3% of the azelaic acid penetrated into viable skin when the gel was applied to hairless mouse skin in a Franz flow-through diffusion cell study, compared with only 3.4% of the cream^{19,20}. The pH of the gel (approximately 4.8) is the optimum for maintaining formulation consistency and does not interfere with the skin acid mantle (pH approximately 5.5), in contrast to the more acidic cream (pH 3.3)²⁰.

Azelaic acid 15% gel (FinaceaTM) is the first new class of medication to be approved for the treatment of rosacea in more than 10 years. The effectiveness of azelaic acid 15% gel in reducing inflammatory papules and pustules and erythema has been demonstrated in 3 large phase 3 randomized, multicenter, double-blind trials: two pivotal 12-week vehicle-controlled studies (N=664)²¹ which formed the basis of FDA approval, and a 15-week comparative study vs. metronidazole 0.75% gel (MetroGel[®]), currently the most widely used topical agent for rosacea (N=251)²². Treatment with azelaic acid gel resulted in significant percent reductions in inflammatory lesions, ranging from 51% to 73%. The percentage of patients whose erythema severity improved ranged from 44% to 56% in these 3 trials. In all trials, treatment with azelaic acid gel resulted in continuous improvement from visit to visit, and the differences vs. the comparator (vehicle or metronidazole gel) at the end of study were significant ($P \leq .02$). At the end of each study, close to two thirds of patients (61% and 62% pivotal; 69% comparative) achieved "success" as defined by a new 7-point investigator's global assessment^{21,22}. Figures 1A and 1B illustrate the symptom resolution in a patient with papulopustular rosacea after just 4 weeks of treatment with azelaic acid gel.

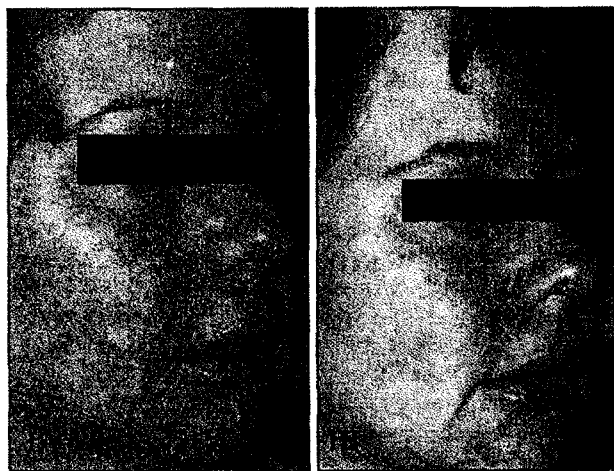

Figure 1A: Patient with papulopustular rosacea at baseline.
Figure 1B: Same patient after 4 weeks of twice-daily treatment with azelaic acid 15% gel.

In all trials, a higher incidence of patients treated with azelaic acid experienced adverse events, such as burning, stinging, tingling, or itching, which were mild and transient in the majority of patients^{21,22}. Nevertheless, in clinical trials, around 90% of patients rated local tolerability good or acceptable despite minor irritation^{21,22}, and tolerability has not been reported to be a major patient concern in clinical use.

Based on its established efficacy against inflammatory lesions and erythema, demonstrated vs. both vehicle and metronidazole 0.75% gel, azelaic acid 15% gel is now considered a first-tier agent for the treatment of rosacea^{23,24}.

Metronidazole

Metronidazole has been used as a topical therapy for rosacea since its approval in 1988²⁵. Numerous clinical trials have established its efficacy in reducing inflammatory papules and pustules and producing overall improvement, both as monotherapy and maintenance therapy^{26,27}. Metronidazole is available in a variety of formulations (gel, lotion, cream) and strengths (0.75% and 1%), which have been shown to have equivalent efficacy^{26,27}. In 2003, a water-based 0.75% topical emulsion (RozexTM), applied twice daily, was approved for topical treatment of papules and pustules of rosacea²⁸. Although presented as a new product, its ingredients are identical to those in the metronidazole 0.75% topical cream (MetroCream[®]) formulation^{28,29}. Because no clinical trial results have been reported, efficacy is expected to be similar to that of metronidazole cream. The most frequently reported adverse events (<3% of patients) with the emulsion are the same as with the cream: burning and stinging, erythema, skin irritation, pruritus, and worsening of rosacea^{28,29}.

Sulfacetamide 10%/Sulfur 5%

Sodium sulfacetamide 10%/sulfur 5% is a supplemental option for topical treatment of rosacea that is generally used in addition to, or after, oral or first-line topical therapies. It is used for the topical control of acne vulgaris, rosacea, and seborrheic dermatitis³⁰. The efficacy of the sulfacetamide 10%/sulfur 5% combination in the treatment of rosacea was first established in the 1950s^{30,31}. Since then, a plethora of different formulations of sulfacetamide/sulfur have become available, many in the last year alone. The first to be developed were lotions (currently marketed as Nicosyn[™] and Sulfacet-R[®] tinted and tint-free), followed by topical suspensions and cleansers (Plexion[®], Avar[™], Rosula[®], Rosanil[™], Clenia[™]), creams (Plexion[®] SCT, Clenia[™], Rosac[®]), and gel formulations (Avar Green[™], Avar[™], Rosula[®]).

Because of its pre-1962 regulatory status, the sulfacetamide 10%/sulfur 5% combination is known as a DESI (Drug Efficacy Study Implementation) drug³². As a result, information on the status of new agents and the drug approval process is not available through the FDA's Electronic Orange Book, which lists

only products approved based on safety and effectiveness³³. Moreover, the core content of the prescribing information for each of these different formulations is identical and does not contain any supporting clinical data that would permit a critical or comparative analysis of the efficacy of these agents. The efficacy of the lotion and cleanser formulations has been established in a few small 8-week clinical studies (<100 patients each), which showed that treatment with sulfacetamide/sulfur reduced inflammatory lesion count, erythema severity, and overall rosacea severity²⁶. Safety and tolerability are good, with rare reports of skin irritation, dryness, or redness.

Within the past year, 3 new water-based gels, an emollient cream, 3 cleansers, a foaming wash, and a cream with sunscreens, all containing sulfacetamide 10%/sulfur 5% as active ingredients, have become available for use in rosacea. Water-based gel formulations represent the latest technological advance in topical therapies, offering less irritation and better skin aesthetics¹⁹. A green-tinted sulfacetamide/sulfur gel (Avar Green™) may provide some patients with an additional immediate cosmetic benefit by masking the appearance of erythema. Green cosmetics have long been recognized as useful tools for camouflaging the redness of flushing and erythema¹³. Overlaying green onto red creates the perception of a more neutral flesh tone; however, the extent and duration of the perceptual effect in this sulfacetamide/sulfur gel have not been measured. Unlike cosmetics, the gel contains an active agent, so it should only be applied as directed, 1 to 3 times daily. A similar untinted gel and cleanser (Avar™) are also available³⁴.

Two other new formulations, an aqueous gel and a cleanser (Rosula®), are based in a 10% urea vehicle. The humectant properties of urea may help minimize irritation and dryness³⁵. A new alcohol-free emollient cream and a foaming wash (Clenia™) also may have moisturizing effects that would be beneficial in patients with sensitive or dry skin³⁶. An additional new cleanser formulation (Rosanil™) is fragrance free and pH neutral³⁷. A small open-label study (N=31) of this sulfacetamide 10%/sulfur 5% cleanser, used in combination with twice-daily metronidazole 0.75% gel for 4 weeks, established its tolerability and showed a trend toward improvement in lesion count, erythema severity index, and overall rosacea severity³⁸.

Finally, a new sulfacetamide 10%/sulfur 5% cream combined with two non-PABA sunscreen agents (Rosac®) has also recently become available. The inclusion of avobenzone, a UVA filter, and octinoxate, a UVB filter, helps protect patients against sun exposure, which is a primary rosacea trigger factor³². In an investigator-blinded, randomized, parallel-group study (N=50) vs. metronidazole 0.75% cream (MetroCream®), 12 weeks of treatment with this sulfacetamide/sulfur/sunscreen cream resulted in a significantly greater improvement in the investigator's global severity rating (83% vs. 58% with metronidazole cream). In addition, significant differences in percent reduction in inflammatory lesions (82% vs. 68%) and percent of

patients with improved erythema (63% vs. 42%) were observed with sulfacetamide/sulfur/sunscreen cream compared with metronidazole cream, respectively³³.

While each of these formulations is unique, the active ingredients are identical to each other and to existing sulfacetamide/sulfur agents. With the exception of the combined sunscreen formulation, no new clinical data is available for these new products, thus efficacy can be expected to be similar to that of other sulfacetamide/sulfur products currently in use. Clinical experience will remain paramount in distinguishing between these products and determining how they can best be used to benefit patients.

Investigational Treatments

The following topical agents are not yet approved for use in rosacea but have shown some activity against it in exploratory investigations. Larger controlled trials will be needed to confirm their efficacy and safety in rosacea patients.

Benzoyl peroxide/clindamycin gel

Topical clindamycin 1% has shown efficacy in rosacea³⁸ and is currently available as both a lotion (Cleocin T™) and a gel (Clindagel®). It is considered a second-tier treatment option³¹. Combination gels containing clindamycin 1% and benzoyl peroxide (BP) 5% (BenzaClin®, Duac™) are an approved treatment for acne vulgaris^{39,40}. A small exploratory trial has investigated the utility of BP/clindamycin, applied once daily, for the treatment of moderate rosacea. In a 12-week, randomized, double-blind, multicenter, placebo-controlled trial (N=53), a >70% reduction in inflammatory lesions was achieved with BP/clindamycin ($P \leq .02$ vs. placebo) by week 6, and was maintained through week 12. Reductions in erythema, flushing and blushing, and overall severity of rosacea were also observed in patients treated with BP/clindamycin ($P \leq .001$). Treatment with BP/clindamycin resulted in a 30% improvement in overall rosacea severity vs. 10% with placebo^{34,41}.

Tacrolimus ointment and pimecrolimus cream

Tacrolimus and pimecrolimus are nonsteroidal immunomodulators that act by calcineurin inhibition. They prevent inflammation primarily by inhibiting cytokine production and blocking T-cell activation in a manner similar to that of cyclosporine^{42,43}. Tacrolimus 0.1% ointment (Protopic®) and pimecrolimus 1% cream (Elidel®) have recently been approved for the treatment of atopic dermatitis when conventional therapy is inadvisable^{44,45}. Because of its anti-inflammatory properties, tacrolimus is currently being evaluated for use in a variety of other inflammatory skin conditions, including rosacea⁴¹.

Several case studies have suggested that tacrolimus 0.075% or

J Drugs Dermatol 2004; 3(3):251-261

0.1% ointment, twice daily, given with or without oral tetracycline, is effective in resolving the signs and symptoms of steroid-induced rosacea, including pruritus, tenderness, and erythema^{46,47}. Tacrolimus appears to have a rapid onset of action, with signs of improvement often observed within a few days and marked improvement achieved after several weeks of treatment^{46,47}. Because pimecrolimus has a similar mechanism of action and anti-inflammatory activity in other dermatologic disorders, its efficacy in steroid-induced rosacea also deserves investigation.

Light-Based Therapies

Laser therapy can be effective in treating the vascular symptoms of rosacea, especially those that are not responsive to either systemic or topical therapy such as telangiectasia and persistent erythema. Until recently, pulsed dye laser (PDL) at 585 nm or 595 nm has been the treatment of choice for these symptoms, especially telangiectasia^{48,51}. Its effectiveness was recently confirmed in a prospective controlled study (N=12), which reported highly significant reductions in telangiectasia (75%), flushing (55%), and erythema (50%) scores ($P<.01$)⁴⁸. However, patient acceptability of PDL has been limited by inconsistent results and the frequent occurrence of purpura, which can last for several weeks and is difficult to conceal by most patients^{49,50,52,53}.

The advent of intense pulsed light (IPL) therapy has broadened the treatment possibilities for patients with vascular symptoms. IPL employs selective photothermolysis with a broad spectrum of light, unlike the single wavelength of a laser. Like lasers, IPL focuses sufficient heat on targeted vessels in a specific time interval to destroy them by coagulation while leaving the surrounding tissue undamaged^{50,52}. Advantages of IPL include the ability to select a wavelength within a broader spectrum ranging from visible to infrared light; sequential pulsing (with systems manufactured by Lumenis Inc), which permits epidermal cooling between pulses; and a variable pulse duration, which enables different-sized vessels located at different depths to be effectively targeted - an advantage in treating small facial telangiectases^{49,52}. Most IPL systems have a spot size much larger than lasers, which facilitates treatment of the entire face quickly - an advantage in addressing erythema and flushing⁴⁹.

Recent studies have shown reductions in redness, flushing, and telangiectasia with IPL therapy. In a large study conducted over 2 years, 188 evaluable patients (74 with rosacea) were treated with IPL (PhotoDerm® VL), with a median of 2 treatments per patient⁵². Facial clearing of 75% to 100% was noted in the majority (93%) of patients. These results were achieved after only 1 treatment in 68% of patients, although full clearance of the diffuse facial veins associated with rosacea occasionally required 2 treatments. In 3 rosacea patients who had been unsuccessfully treated with pulsed dye or copper laser, a single treatment with IPL resulted in 75% to 100% clearing. Adverse

events, reported by 18% of patients, included bruising, persistent edema, and transient hypopigmentation⁵².

In another study, 32 patients with predominantly moderate rosacea of subtype I or II who had plateaued on conventional therapy received 1 to 7 IPL treatments (VascuLight™ Plus/VascuLight™ SR)⁴⁹. A 2.4 ms/4.0 ms double pulse was administered with a 20 ms delay time, and fluences were 32 J/cm² to 36 J/cm² with a 570 nm filter or 27 J/cm² to 32 J/cm² with a 560 nm filter⁴⁹. Among 28 evaluable patients, 83% rated their redness better or much better, 75% rated flushing and skin texture better or much better, and 64% noted that acneiform breakouts were better or much better⁴⁹. Very few adverse events were reported (1 purpura, 1 peeling, 1 postinflammatory hyperpigmentation), and all were reversible⁴⁹.

In one attempt to objectively quantify the effectiveness of IPL (PhotoDerm® VL) in 4 patients, scanning laser Doppler and computer image analysis revealed decreases in blood flow (30%), telangiectasia area (29%), and erythema intensity (21%)⁵⁴. Figure 2A and 2B illustrate the response of a rosacea patient presenting with telangiectasia and erythema 6 months after completion of three IPL treatments. This patient was treated with PhotodermVL using a 550 nm cutoff filter with a double pulse of 2.5 and 4.0 ms with a 10 ms delay at 38 J/cm².

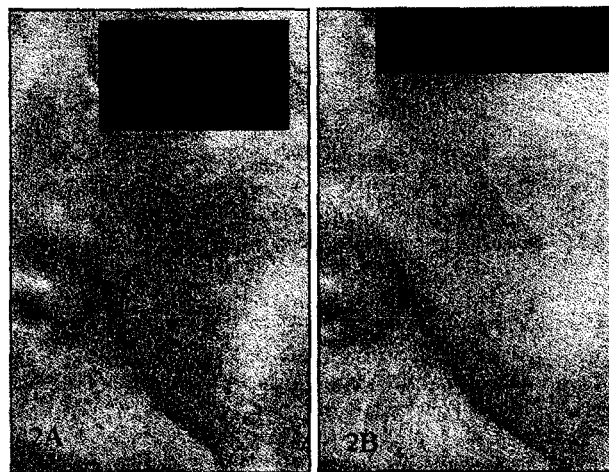


Figure 2A: Rosacea patient with centrofacial telangiectasia and erythema. Figure 2B: Same patient 6 months after completion of 3 IPL treatments with Photoderm VL using a 550 nm cutoff filter with a double pulse of 2.5 and 4.0 ms with a 10 ms delay at 38 J/cm².

Other approaches to laser treatment of telangiectasia and erythema have been tried in rosacea patients with limited success. Long-pulse KTP laser and long-pulse PDL have been used at lower fluences to eliminate red vessels associated with erythema with minimal purpura⁵⁵, but these have not proven as effective as IPL. Longer wavelength devices for deeper vessels, such as the Nd:YAG laser, do not work as well for treating the superficial, smaller, bright red vessels found in patients with rosacea. "Stacking" - using multiple pulses of PDL at the same time or

making multiple passes – can be more effective in treating facial telangiectasia, though purpura remains a concern and the technique is more time consuming⁵¹. Another advance in treating photodamage and rosacea involves the use of 5-aminolevulinic acid (ALA; Levulan® Kerastick®) applied for 15 to 60 minutes prior to laser or IPL treatment. Studies have demonstrated that ALA selectively penetrates into sebaceous glands and is then activated by the laser or IPL to damage or destroy them^{55,58}.

A Multifaceted Approach to Treatment

Because of the variable presentation of rosacea, its treatment has long been considered as much an art as a science^{11,12}. Each patient is a unique case requiring an individualized treatment plan that must be adjusted over time based on the patient's success with lifestyle management, response to therapies, and the unpredictable course of the disease.

Patient education is the necessary first step in effective management of all rosacea subtypes. Medical interventions alone may have limited effectiveness if not combined with patient self-care. Physicians must explain to patients the importance of proper skin care and the myriad factors that can trigger rosacea symptoms, particularly flushing. New patients should be encouraged to keep notes identifying their own personal tripwires and then urged to make every effort to avoid them. Pathogenically, it has been hypothesized that prolonged flushing and erythema in genetically predisposed persons may trigger a cascade of events that leads to edema, telangiectasia, and phymatous growth¹. Thus patient diligence in avoiding rosacea triggers may be important not only in ensuring short-term symptom relief but also in preventing worsening of the condition.

Despite their importance, behavioral modifications alone are seldom sufficient to keep rosacea under control, and medical intervention will almost always be required. The expanded armamentarium of medications and light-based therapies has made possible a multifaceted treatment approach. Specific treatments – oral antibiotics, topical agents, cleansers, lasers, dermatosurgical procedures – can be aimed specifically at distinct features of the disease, concomitantly and/or sequentially, leading to new treatment combinations. The skill, judgment, and creativity of the clinician in crafting strategic interventions will be critical to the outcomes achieved.

Erythematotelangiectatic

Flushing is the most prominent and, in some patients, may be the only symptom of this subtype². Flushing is difficult to treat, thus patients' avoidance of trigger factors is critical to preventing flush attacks. According to National Rosacea Society surveys, the most common trigger factors include sun exposure; physical overexertion; alcohol consumption; hot or spicy foods;

emotions (stress); hot, cold, or windy weather; and various topical medications and skin-care products⁵. When flushing occurs, ice chips held in the mouth, an icy compress applied to the face, or even drinking ice water may provide temporary relief⁹.

Very little can be done medically to resolve flushing once it has begun. Clonidine, an imidazoline used primarily as an antihypertensive agent, has been shown at doses of 0.05 mg twice daily to have a limited effect in suppressing flushing attacks in some rosacea patients¹¹. However, because of potential unwanted effects (sexual dysfunction, hypersensitivity) as well as serious risks that may occur with rapid discontinuation of therapy, it should be considered a last resort^{11,60}. Beta-blockers may also be considered to prevent flushing but, again, should only be considered in severe cases because of the associated adverse events and possible impact on heart rate¹¹.

For nontransient erythema, begin with topical therapies. Metronidazole 1% cream (Noritate®) is formally indicated for the topical treatment of erythema, with reductions of 40% to 42% seen at week 10 in its 2 pivotal trials⁶¹. Some reductions in erythema have also been seen with other metronidazole formulations²⁷. Azelaic acid 15% gel is effective in many patients, with 44% to 56% of patients showing improvement in erythema after 12 or 15 weeks of treatment^{21,22}. Green-tinted sulfacetamide 10%/sulfur 5% gel may offer short-term cosmetic relief in some patients by masking their erythema, though the extent of its overall clinical benefit is not known.

If topical therapies are ineffective or a plateau in efficacy is reached, IPL treatment may be a useful tool in addressing persistent erythema. Effective results have been achieved with few adverse events, although cost may be an issue for some patients because most insurers still classify it as an elective procedure. In Dr. Goldman's experience, many patients remain free of the erythematous component of rosacea for 2 to 4 years. In some patients, flushing may also be eliminated for many years. Flushing often resolves better with PDL than with IPL, probably because a 0.5 ms pulse of the PDL is more effective in treating the small 40 mm to 60 mm vessels involved in flushing than the longer 2 ms to 6 ms pulse durations of an IPL. Because laser and light treatments are not curative, consideration might be given to follow-up use of a topical agent to thwart new vessel formation⁴⁹.

While telangiectases are commonly noted in this subtype, they are usually small and may not require treatment. For those patients who wish to pursue treatment, both IPL and PDL can provide effective results.

Papulopustular

For mild papulopustular disease, monotherapy with a topical agent is the preferred first-line therapy because of the con-

firmed efficacy and greater safety of topical vs. oral agents. However, in treating flare-ups or moderate to severe cases, the combination of a topical preparation and systemic antibiotic is recommended, as each agent may block different pathways of inflammation and maximize symptom reduction more rapidly. Moreover, because of the need for ongoing maintenance therapy in most patients, it is advantageous to initiate combination therapy, thus ensuring continuity of therapy upon discontinuation of the oral agent.

In terms of topical agents to consider, metronidazole has a proven track record of results in lesion reduction and overall improvement, with few adverse events (low incidence of burning, irritation, and dry skin)²⁷. It is available in a variety of formulations (gel, lotion, cream, emulsion) and strengths (0.75% and 1%), which have been shown to have equivalent efficacy^{26,27}. Azelaic acid 15% gel should now also be considered for first-line monotherapy. It has proven highly effective in both inflammatory lesion and erythema reduction in 3 large controlled trials, and it has demonstrated superiority to metronidazole gel in reducing these key rosacea signs as well as in overall rosacea improvement^{21,22}. For patients with moderate rosacea who do not quickly respond to monotherapy, consider adding a sulfacetamide/sulfur cleanser or topical formulation.

In terms of systemic therapies, the most widely used antibiotic is tetracycline, 250 mg to 1000 mg daily (given in 2 to 4 doses), largely because it offers the best balance between efficacy and cost-effectiveness. Other effective alternatives include doxycycline hyclate or monohydrate (100 mg to 200 mg daily), enteric-coated erythromycin (250 mg to 1000 mg daily, given in 2 to 4 doses), minocycline (100 mg to 200 mg daily), and metronidazole (400 mg daily).

Patient response to and tolerability of oral medication will determine the appropriate length of therapy. Gastrointestinal disturbance is the most common limiting short-term side effect with oral antibiotics. Other rare but potentially troubling adverse reactions that have been reported, primarily with the tetracyclines, include serum-sickness-like reaction, hypersensitivity syndromes, pseudotumor cerebri and, with minocycline, lupus-like syndrome, blue-black macular pigmentation, and vertigo/dizziness^{8,11}. Photosensitization may occur with doxycycline, but very rarely^{8,11}. Once rosacea signs and symptoms have been brought under control – typically in 6 to 12 weeks – the oral agent should be tapered down and eventually discontinued, if possible. A topical agent can then be used to maintain remission. However, many patients may require at least a low-dose, long-term systemic therapy to remain clear of symptoms.

For treatment-resistant cases, low-dose oral isotretinoin may be considered. It has been in use at higher doses for several decades and is effective against both the inflammatory and vascular signs of rosacea^{11,62}. Low-dose isotretinoin (10 mg/day) has been shown to produce declines in inflammatory lesions,

erythema, and telangiectasia after 9 weeks⁶². Isotretinoin is highly teratogenic at any dose, but many of its unpleasant or serious adverse events (e.g., cheilitis, facial dermatitis, alopecia, epistaxis, muscle and joint pains, conjunctivitis, cataracts, and increased serum triglycerides and cholesterol) are rarely observed at a daily dose of 10 mg^{11,62}. Nevertheless, isotretinoin should still be administered with caution to rosacea patients.

Phymatous

In early stages of phymatous changes, prior to the formation of substantial fibrous growth, treatment with isotretinoin at 0.5 mg/kg to 1.0 mg/kg for 4 to 6 months can shrink the phymatous tissue in some patients by as much as 23%⁶³. Laser treatment that targets the underlying vascular component may be also effective in removing phymatous tissue while preventing further growth¹¹. However, once advanced, the only effective treatment for phymas consists of dermatosurgical intervention to excise the phymatous tissue. Options include the classic cold steel excision, electrosurgery with the cauterizing (Shaw) scalpel, and carbon dioxide (CO₂) laser, alone or in combination. Traditional sculpting with a scalpel, razor blade, or dermatome permits precise removal of tissue but is associated with substantial bleeding that may make it difficult to achieve an even surface. The thermal scalpel makes tissue removal easier but carries a significant risk of scarring. The CO₂ laser is quicker and more precise, and it facilitates accurate sculpting, but the risk of thermal scarring also exists. Thus, each of these treatments must be carried out with great care^{30,64}.

Ocular

More than one half of all rosacea patients are estimated to eventually develop ocular involvement^{65,66}, which follows or appears simultaneously with cutaneous symptoms in the majority of patients⁶⁶. Patient self-care through good eyelid hygiene, warm compresses, and artificial tears may offer some relief¹¹. Systemic antibiotic therapy with oral tetracycline (1 g/day) or doxycycline (100 mg/day) is still considered the treatment of choice for ocular rosacea, based on the improvement in signs and symptoms observed after 6 weeks of therapy^{65,67,68}. Erythromycin and metronidazole are other viable options with efficacy similar to the tetracyclines⁶⁶. Most patients with ocular rosacea respond to systemic antibiotics, which will prevent the corneal involvement that leads to scarring. Because dermatologists use systemic antibiotics for both cutaneous and ocular rosacea, rarely is referral to an ophthalmologist needed.

Conclusion

Although the pathogenesis of rosacea still remains elusive, progress continues to be made in understanding how this dermatologic syndrome presents in specific patients. The primary features and subtypes of rosacea that are delineated in the new

classification system provide practitioners with a valuable tool to aid in more accurate diagnosis and development of treatment approaches. At the same time, new advances in both medical and light-based therapies have significantly expanded the available treatment options. Practitioners can now customize their patients' therapy, prescribing one or more treatments together or in sequence directly targeted to each patient's distinct disease features. Thus, the expanding array of new treatments is helping to empower clinicians to improve the quality of life for their patients living with rosacea.

Trademark Acknowledgements

Aurora SR is a trademark of Syneron, Inc.

Avar and Nicosyn are trademarks of Sirius Laboratories, Inc.

BenzaClin, Noritate, and Sulfacet-R are registered trademarks of Dermik Laboratories.

Clenia is a trademark of Upsher-Smith Laboratories, Inc.

Cleocin T is a registered trademark of Pharmacia & Upjohn Company.

Clindagel, MetroCream, and MetroGel are registered trademarks of and Rosanil and Rozex are trademarks of Galderma Laboratories, LP.

Elidel is a registered trademark of Novartis Pharmaceuticals Corp.

EsteLux, Lux G, and Lux Y are trademarks of Palomar Biomedical Technologies, Inc.

Finacea is a trademark of Berlex Laboratories.

Levulan and Kerastick are registered trademarks of DUSA Pharmaceuticals.

OmniLight is a trademark of the Luxsano group of companies.

Periostat is a registered trademark of CollaGenex Pharmaceuticals, Inc.

PhotoDerm, D-Light SR, EpiLight IPL, Lumenis One, MultiLight, and Vasculight are registered trademarks of Lumenis, Inc.

Plexion is a registered trademark of Medicis.

Prolite is a trademark of Alderm, N.A. LLC.

Protopic is a registered trademark of Fujisawa Healthcare, Inc.

Rosac is a registered trademark of and Duac is a trademark of Stiefel Laboratories, Inc.

Rosula is a registered trademark of Doak Dermatologics.

SpectraPulse is a registered trademark of Primary Technology, LLC.

Dr. Bikowski is a consultant and Speakers Bureau member for and has received honoraria and expenses from 3M Pharmaceuticals; CollaGenex Pharmaceuticals, Inc.; Galderma Laboratories, LP; Healthpoint Laboratories; Medicis; and Stiefel Laboratories, Inc. He is a Speakers Bureau member for and has received honoraria and expenses from Allergan/Proctor & Gamble, Aventis, Pfizer Pharmaceuticals, and Novartis Pharmaceuticals Corp; is a consultant to Berlex Laboratories; and is a Speakers Bureau member for Connetics Corporation.

Dr. Goldman is a consultant for and has received research grants from Lumenis, Inc; Cynosure, Inc; and DUSA Pharmaceuticals.

References

1. Wilkin JK. Rosacea: pathophysiology and treatment. Arch Dermatol 1994; 130:359-362.
2. Wilkin J, Dahl M, Detmar M, et al. Standard classification of rosacea: report of the National Rosacea Society Expert Committee on the Classification and Staging of Rosacea. J Am Acad Dermatol 2002; 46:584-587.
3. Dahl MV. Pathogenesis of rosacea. Adv Dermatol 2001; 17:29-45.
4. National Rosacea Society. 14 Million Americans have rosacea; and most of them don't know it. Available at: www.rosacea.org. Accessed September 9, 2003.
5. Zuber TJ. Rosacea. Prim Care 2000; 27:309-318.
6. Plewig G, Kligman AM. Rosacea. In: Plewig G, Kligman AM. Acne and Rosacea. Springer-Verlag, Berlin, 1993; 433-475.
7. Cohen AF, Tiemstra JD. Diagnosis and treatment of rosacea. J Am Board Fam Pract 2002; 15:214-217.
8. Del Rosso JQ. Systemic therapy for rosacea: focus on oral antibiotic therapy and safety. Cutis 2000; 66:7-13.
9. Katsambas AD, Nicolaidou E. Acne, perioral dermatitis, flushing, and rosacea: unapproved treatments or indications. Clin Dermatol 2000; 18:171-176.
10. Bikowski JB. Subantimicrobial dose doxycycline for acne and rosacea. SKINmed 2003; 2:234-245.
11. Rebora A. The management of rosacea. Am J Clin Dermatol 2002; 3:489-496.
12. Landow K. Unraveling the mystery of rosacea: keys to getting the red out. Postgrad Med 2002; 112:51-82.
13. Bikowski JB. Rosacea: a tiered approach to therapy. Cutis 2000; 66(suppl 4):3-6.
14. Cunliffe WJ, Dodman B, Binner JG. Clonidine and facial flushing in rosacea. Br Med J 1977; 1:105.
15. Millikan L. The proposed inflammatory pathophysiology of rosacea: implications for treatment. SKINmed 2003; 2:43-47.
16. Del Rosso JQ. Keeping it clean: a look at the clinical benefits of newer formulations of therapeutic cleansers for acne, rosacea and seborrheic dermatitis. Skin & Aging 2003; 11:82-88.

17. Passi S, et al. The oxyradical-scavenging activity of azelaic acid in biological systems. *Free Rad Res Comm* 1991; 15:17-28.
18. Akamatsu H, et al. Inhibitory effect of azelaic acid on neutrophil functions: a possible cause for its efficacy in treating pathogenetically unrelated diseases. *Arch Dermatol Res* 1991; 283:162-166.
19. Draelos ZD. What's in a formulation? *Cosmetic Dermatol* 2003; 16(11):56-58.
20. Draelos ZD, Graupe K. A new topical formulation for the treatment of mild to moderate papulopustular rosacea: azelaic acid 15% gel. Poster presented at the 61st Annual Meeting of the American Academy of Dermatology; March 21-26, 2003; San Francisco, Calif.
21. Thiboutot D, Thieroff-Ekerdt R, Graupe K. Efficacy and safety of azelaic acid (15%) gel as a new treatment for papulopustular rosacea: results from two vehicle-controlled, randomized phase III studies. *J Am Acad Dermatol* 2003; 48:836-845.
22. Elewski BE, Fleischer AB Jr, Pariser DM. A comparison of 15% azelaic acid gel and 0.75% metronidazole gel in the topical treatment of papulopustular rosacea: results of a randomized trial. *Arch Dermatol* 2003; 139:1444-1450.
23. Del Rosso JQ. Medical management of rosacea with topical agents: a thorough appraisal of available treatment options and recent advances. *Cosmetic Dermatol* 2003; 16(8):47-60.
24. Tuleya S. Research highlights of acne and rosacea treatments: the latest research from recent AAD meetings and more. *Skin & Aging* 2003; 11:70-72.
25. US Food and Drug Administration. Search results from the "Rx" table for query on "019737." *Electronic Orange Book: Approved Drug Products With Therapeutic Equivalence Evaluations*. 23rd ed. Available at: www.accessdata.fda.gov/scripts/cder/ob/docs/temptndet.cfm?Appl_No=019737&TABLE1=Rx. Accessed November 6, 2003.
26. Del Rosso JQ. A status report on the medical management of rosacea: focus on topical therapies. *Cutis* 2002; 70:271-275.
27. McClellan KJ, Noble S. Topical metronidazole: a review of its use in rosacea. *Am J Clin Dermatol* 2000; 1:191-199.
28. Rozex [package insert]. Galderma Laboratories, LP, Fort Worth, Tex, 2003.
29. MetroCream [package insert]. Galderma Laboratories, LP, Fort Worth, Tex, 1995.
30. Shalita AR, et al. A comparative efficacy study of Rosac® cream with sunscreens (sodium sulfacetamide 10%/sulfur 5%) and MetroCream® (metronidazole 0.75%) in the twice daily treatment of rosacea. *Skin & Aging* 2003; 11(suppl):17-22.
31. Olansky S. Old drug - in a new system - revisited. *Cutis* 1977; 19:852-854.
32. US Food and Drug Administration. Questions and Answers on the Unapproved Drug Compliance Policy Guide (CPG). Available at: www.fda.gov/cder/compliance/CPG_QandA.htm. Accessed November 5, 2003.
33. US Food and Drug Administration. Preface. *Electronic Orange Book: Approved Drug Products With Therapeutic Equivalence Evaluations*. 23rd ed. Available at: www.fda.gov/cder/ob/docs/preface/ecpreface.htm. Accessed November 6, 2003.
34. Avar [package insert]. Sirius Laboratories, Inc, Vernon Hills, Ill, 2003.
35. Rosula [package insert]. Doak Dermatologics, Fairfield, NJ, 2003.
36. Clenia [package insert]. Upsher-Smith Laboratories, Minneapolis, Minn, 2003.
37. Rosanil [package insert]. Galderma Laboratories, LP, Fort Worth, Tex, 2002.
38. Wilkin JK, DeWitt S. Treatment of rosacea: topical clindamycin versus oral tetracycline. *Int J Dermatol* 1993; 32:65-67.
39. BenzaClin [package insert]. Dermik Laboratories, Berwyn, Pa, 2003.
40. Duac [package insert]. Stiefel Laboratories, Inc, Coral Gables, Fla, 2002.
41. Breneman D. Double blind, multicenter, comparison study of combination benzoyl peroxide/clindamycin or placebo in patients with moderate rosacea [abstract]. In: American Academy of Dermatology 61st Annual Meeting Poster Abstracts. American Academy of Dermatology, Schaumburg, Ill, 2003. Abstract P43.
42. Nghiem P, Pearson G, Langley RG. Tacrolimus and pimecrolimus: from clever prokaryotes to inhibiting calcineurin and treating atopic dermatitis. *J Am Acad Dermatol* 2002; 46:228-241.
43. Ruzicka T, Assmann T, Lebwohl M. Potential future dermatological indications for tacrolimus ointment. *Eur J Dermatol* 2003; 13:331-342.
44. Protopic [package insert]. Fujisawa Healthcare, Inc, Deerfield, Ill, 2000.
45. Elidel [package insert]. Novartis Pharmaceuticals Corp, East Hanover, NJ, 2003.
46. Goldman D. Tacrolimus ointment for the treatment of steroid-induced rosacea: a preliminary report. *J Am Acad Dermatol* 2001; 44:995-998.
47. Pabby A, An KP, Laws RA. Combination therapy of tetracycline and tacrolimus resulting in rapid resolution of steroid-induced periocular rosacea. *Cutis* 2003; 72:141-142.
48. Clark SM, Lanigan SW, Marks R. Laser treatment of erythema and telangiectasia associated with rosacea. *Lasers Med Sci* 2002; 17:26-33.
49. Taub AF. Treatment of rosacea with intense pulsed light. *J Drugs Dermatol* 2003; 3:254-259.
50. Goldman MP, Fitzpatrick RE. *Cutaneous Laser Surgery: The Art and Science of Selective Photothermolysis*. 2nd ed. Mosby, St. Louis, 1999.
51. Lowe NJ, Behr KL, Fitzpatrick R, Goldman M, Ruiz-Espaza J. Flash lamp pumped dye laser for rosacea-associated telangiectasia and erythema. *J Dermatol Surg Oncol* 1991; 17:522-525.
52. Angermeier MC. Treatment of facial vascular lesions with intense pulsed light. *J Cutan Laser Ther* 1999; 1:95-100.
53. Krivda M. Getting the red out. *Skin & Aging* 2003; 11:74-80.
54. Mark KA, Sparacio RM, Voigt A, Marenus K, Sarnoff DS. Objective and quantitative improvement of rosacea-associated

erythema after intense pulsed light treatment. *Dermatol Surg* 2003; 29:600-604.

55. Goldman MP, Boyce SM. A single-center study of aminolevulinic acid and 417 nm photodynamic therapy in the treatment of moderate to severe acne vulgaris. *J Drugs Dermatol* 2003; 2:393-396.
56. Goldman MP. Using 5-aminolevulinic acid to treat acne and sebaceous hyperplasia. *Cosmetic Dermatol* 2003; 16(4):57-58.
57. Hongcharu W, et al. Topical ALA-photodynamic therapy for the treatment of acne vulgaris. *J Invest Dermatol* 2000; 115:183-192.
58. Itoh Y, Ninomiya Y, Tajima S, Ishibashi A. Photodynamic therapy of acne vulgaris with topical 5-aminolaevulinic acid and incoherent light in Japanese patients. *Br J Dermatol* 2001; 144:575-579.
59. National Rosacea Society. Lifestyle management helps patients enjoy summer while reducing flare-ups. Available at: www.rosacea.org/rr/2003/summer/article_1.html. Accessed September 9, 2003.
60. Wilkin JK. Effect of subdepressor clonidine on flushing reactions in rosacea: change in malar thermal circulation index during provoked flushing reactions. *Arch Dermatol* 1983; 119:211-214.
61. Noritate [package insert]. Dermik Laboratories, Berwyn, PA, 2002.
62. Erdogan FG, et al. Efficacy of low-dose isotretinoin in patients with treatment-resistant rosacea. *Arch Dermatol* 1998; 134:884-885.
63. Jansen T, Plewig G. Clinical and histological variants of rhinophyma, including nonsurgical treatment modalities. *Facial Plast Surg* 1998; 14:241-253.
64. Bogetti P, et al. Surgical treatment of rhinophyma: a comparison of techniques. *Aesth Plast Surg* 2002; 26:57-60.
65. Tanzi EL, Weinberg JM. The ocular manifestations of rosacea. *Cutis* 2001; 68:112-114.
66. Kligman AM. Ocular rosacea: current concepts and therapy. *Arch Dermatol* 1997; 133:89-90.
67. Frucht-Pery J, et al. Efficacy of doxycycline and tetracycline in ocular rosacea. *Am J Ophthalmol* 1993; 116:88-92.
68. Michel J-L, Cabibel F. Fréquence, gravité et traitement de la rosacée oculaire au cours de la rosacée cutanée. *Ann Dermatol Vénereol* 2003; 130:20-24.



gel cream

BRIEF SUMMARY

Rx ONLY

INDICATIONS AND USAGE: Naftin® Cream, 1% is indicated for the topical treatment of tinea pedis, tinea cruris, and tinea corporis caused by the organisms *Trichophyton rubrum*, *Trichophyton mentagrophytes*, and *Epidermophyton floccosum*. Naftin® Gel, 1% is indicated for the topical treatment of tinea pedis, tinea cruris, and tinea corporis caused by the organisms *Trichophyton rubrum*, *Trichophyton mentagrophytes*, *Trichophyton tonsurans*, *Epidermophyton floccosum*. *Efficacy for this organism in this organ system was studied in fewer than 10 infections.

CONTRAINDICATIONS: Naftin® Cream and Gel, 1% are contraindicated in individuals who have shown hypersensitivity to any of their components.

WARNINGS: Naftin® Cream and Gel, 1% are for topical use only and not for ophthalmic use.

PRECAUTIONS:

General: Naftin® Cream and Gel, 1%, are for external use only. If irritation or sensitivity develops with the use of Naftin® Cream or Gel, 1%, treatment should be discontinued and appropriate therapy instituted. Diagnosis of the disease should be confirmed either by direct microscopic examination of a mounting of infected tissue in a solution of potassium hydroxide or by culture on an appropriate medium.

Information for patients: The patient should be told to:

1. Avoid the use of occlusive dressings or wrappings unless otherwise directed by the physician.
2. Keep Naftin® Cream and Gel, 1% away from the eyes, nose, mouth and other mucous membranes.

Carcinogenesis, mutagenesis, impairment of fertility: Long-term studies to evaluate the carcinogenic potential of Naftin® Cream and Gel, 1% have not been performed. *In vitro* and animal studies have not demonstrated any mutagenic effect or effect on fertility.

Pregnancy: Teratogenic Effects: Pregnancy Category B:

Reproduction studies have been performed in rats and rabbits (via oral administration) at doses 150 times or more than the topical human dose and have revealed no evidence of impaired fertility or harm to the fetus due to naftifine. There are, however, no adequate and well-controlled studies in pregnant women. Because animal reproduction studies are not always predictive of human response, this drug should be used during pregnancy only if clearly needed.

Nursing mothers: It is not known whether this drug is excreted in human milk. Because many drugs are excreted in human milk, caution should be exercised when Naftin® Cream or Gel, 1% are administered to a nursing woman.

Pediatric use: Safety and effectiveness in pediatric patients have not been established.

ADVERSE REACTIONS: During clinical trials with Naftin® Cream, 1%, the incidence of adverse reactions was as follows: burning/stinging (6%), dryness (3%), erythema (2%), itching (2%), local irritation (2%). During clinical trials with Naftin® Gel, 1%, the incidence of adverse reactions was as follows: burning/stinging (5.0%), itching (1.0%), erythema (0.5%), rash (0.5%), skin tenderness (0.5%).

Manufactured for
Merz Pharmaceuticals
Greensboro, NC 27410

© 1999 Allergan, Inc. Rev B/03

