

A. SZLACHCIC, Z. ŚLIWOWSKI, E. KARCZEWSKA, W. BIELAŃSKI,  
J. PYTKO-POLONCZYK\*, S.J. KONTUREK

## HELICOBACTER PYLORI AND ITS ERADICATION IN ROSACEA

Department of Physiology and \*Department of Conservative Dentistry, University School of Medicine, Cracow, Poland.

*Rosacea* is a common condition of unknown etiology usually accompanied by gastrointestinal symptoms and favorably responding to the treatment with antibiotics. This study was designed to examine the prevalence of gastric *Helicobacter pylori* (Hp) infection verified by  $^{13}\text{C}$ -UTB-test, CLO, Hp culture and serology (IgG) in patients with *rosacea*. Gastroduodenoscopy was combined with pentagastrin secretory test and antral and fundic biopsy samples were taken for histological evaluation (the Sydney system). Blood samples were also taken for the determination of plasma gastrin using RIA and plasma interleukin (IL)-8 and tumor necrosis factor alpha (TNF $\alpha$ ) using ELISA. This study was performed in 60 patients, 31–72 year old, with visible papules and pustules associated with erythema and flushing on the face and on 60 age- and gender-matched patients without any skin diseases but with similar as in *rosacea* gastrointestinal symptoms but without endoscopic changes in gastroduodenal mucosa (non-ulcer dyspepsia — NUD). The Hp prevalence in *rosacea* patients was about 88 % as compared to 65% in control NUD patients. Among *rosacea* patients, 67% were cytotoxin associated gene A (CagA) positive, while in NUD patients only 32% were CagA positive. *Rosacea* patients showed gastritis with activity of about 2.1 in antrum and 0.9 in the corpus of the stomach while those with NUD only mild gastritis with activity of  $\sim 1.0$ ) confined to the antrum only. Following initial examination, typical 1 wk anti-Hp therapy including omeprazole (20 mg bd.), clarithromycin (500 mg bd.) and metronidazol (500 mg bd.) was carried out. After eradication, 51 out of 53 treated *rosacea* patients became Hp negative. Within 2–4 weeks, the symptoms of *rosacea* disappeared in 51 patients, markedly declined in 1 and remained unchanged in 1 other subject. A dramatic reduction in activity of gastritis (to 0.3 in antrum and to 0.1 in corpus) was observed. Basal plasma gastrin decreased from  $48 \pm 5$  pM before to  $17 \pm 3$  pM after eradication, while pentagastrin-induced maximal (MAO) declined, respectively, from about  $16.6 \pm 4.2$  to  $8.5 \pm 1.8$  mmol/h. Plasma TNF $\alpha$  and IL-8 were reduced after the therapy by 72% and 65%, respectively. We conclude that: 1) *Rosacea* is a disorder with various gastrointestinal symptoms closely related to gastritis, especially involving the antrum mucosa, with Hp expressing *cagA* in the majority of cases and elevated plasma levels of TNF $\alpha$  and IL-8; 2) The eradication of Hp leads to a dramatic improvement of symptoms of *rosacea* and reduction in related gastrointestinal symptoms, gastritis, hypergastrinemia and gastric acid secretion; and 3) *Rosacea* could be considered as one of the major extragastric symptoms of Hp infection probably mediated by Hp-related cytotoxins and cytokines.

**Key words:** *Rosacea*, *Helicobacter pylori*, cytotoxins, IL-8, TNF $\alpha$ , gastric mucosa, gastrin

## INTRODUCTION

*Rosacea* belongs to the group of chronic skin diseases involving about 2% of the population and most often appears in adults usually in their thirties and older (1). Although more frequent in women, the symptoms are more intensive in men (2). The skin changes are symmetrical and located mainly in the middle area of the face. Still, they can also appear on the neck and legs. At first, they are characterized as erythematous changes, which with time lead to *teleangiectasia*, papular and pustular eruption, an overgrowth of connective tissue and sebaceous glands, especially in men (*rhinophyma* (3, 4, 5). Except for the classic *rosacea*, there are also atypical forms: circumscribed, diffuse, extra-facial, conglobata, fulminant or granulomatous (3, 5).

The course of *rosacea* is chronic with periodic improvement or aggravation. It was noted that the worsening of skin changes can occur after excessive exposure to ultraviolet light and stress, after alcohol intake, strong coffee or hot food etc. Additionally, a connection between intensified *rosacea* and hormonal changes during menstruation period or menopause in women has been noticed (3—5).

Except for the skin, eye changes occur with the characteristics of eyelid inflammation, *conjunctivitis*, *iritis*. Besides, gastric disorders such as hypochlorhydria, *gastritis* and peptic ulcer disease (3, 4, 5) have also been noted.

Despite numerous studies, the pathogenesis of *rosacea* remains unknown. It is assumed that the development of skin changes is caused by many, unrelated factors. It is believed that, dependent on emotional factors or resulting from excessive vessels' sensitivity to endogenous opiates or its excessive secretion, vasomotor disorders play a marked role (6, 7). Moreover, it has been observed in patients with *rosacea* an increased concentration of substance P, which has an influence on vasodilation and a local inflammatory reaction (8).

No relation between the degree of the development in skin changes and seborrhea has been noted despite the location of the skin symptoms in so called seborrheic areas (9).

Intensified skin changes during menstruation and their aggravation in women during menopause suggest hormonal factors in the pathogenesis of *rosacea* (4).

The occurrence of *Demodex folliculorum* in hair follicles and sebaceous glands located within the skin changes could indicate their participation in the pathomechanism of *rosacea*. Although can be found more often in the affected areas, it can be also found in skin appendages in healthy patients (10—12).

In patients with *rosacea*, digestive disorders such as achlorhydria, *gastritis* or even chronic peptic ulcer disease are very often observed (3—5, 13—16). At present it is known that *Helicobacter pylori* (Hp) plays the key role in the development of *gastritis*, peptic ulcer, MALT lymphoma or even gastric cancer

strongly suggesting an involvement of the bacterium also in the mechanisms of certain skin changes diseases. Hp is a spiral bacterium which, is linked to B-form of *gastritis*, and the release of various noxious substances including platelet activating factor (PAF), lipopolysaccharides (LPS), cytotoxins such as CagA and VacA proteins and numerous cytokines originating from the host cells such as interleukin (IL)-8, IL1 $\beta$ , TNF $\alpha$ , ammonia due to high urease activity and others. These substances may contribute to the inflammation of gastric mucosa, alterations in gastric acid secretion ranging from achlorhydria in acute phase of infection with *pangastritis* to gastric hyperchlorhydria in chronically infected patients with typical chronic active *antritis* and high plasma gastrin levels. In addition, there is an increase in production of IgG and IgA antibodies to Hp in gastric juices and in the plasma (17–20).

This study was designed: 1) to establish the prevalence of Hp infection in the stomach of patients with *rosacea* symptoms as based on standard Hp detection tests, 2) to assess the relation between the colonization of the gastric mucosa with Hp and the symptoms of *rosacea*, and 3) to compare the co-existence of the Hp infection in the stomach and skin disorders before and after the application of one-week triple therapy (omeprazol + clarythromycin + metronidazol).

## MATERIAL AND METHODS

The studies were performed on 60 control subjects without any demonstrable endoscopic gastroduodenal changes but with various subjective gastrointestinal symptoms of non-ulcer dyspepsia (NUD) similar to those recorded in *rosacea* patients and on 60 patients with *rosacea*, all aged between 30 and 70 years. Skin symptoms were evaluated on a three grade scale; I — erythematous alone, erythematous and papular; II — papular, papulo-pustular and teleangiectasias; III — inflammatory infiltration, nodulous changes, *rhinophyma* (5).

The tests were conducted before and after four weeks of anti-Hp therapy. Patients had no ailments in other organs and took no antibiotics for at least four weeks prior to the tests. All patients underwent gastroscopy during which mucosal biopsy samples were taken from the stomach (from *antrum* and from *corpus*) to perform a rapid urease CLO-test (Jartox-H.p.-test, Procter and Gamble, Pharmaceutical, Weiterstradt, Germany) and bacterial culture from biopsy samples on special agar plates with the addition of 5% of horse serum and antibiotics blocking the growth of bacteria others than Hp. Furthermore, the biopsy samples of antral and fundic mucosa were taken for histological evaluation using Sydney classification. To confirm the Hp infection in the stomach, the <sup>13</sup>C-urea breath test (<sup>13</sup>C-UBT) was performed as described before (21). Additionally, the level of IgG anti-Hp and anti-CagA antibodies were measured in plasma by ELISA as described before (21). Blood samples were withdrawn under basal conditions for determination of plasma gastrin by radioimmunoassay and TNF $\alpha$  and interleukin-8 (IL-8) using ELISA as described before (21). Finally, gastric secretory test was performed during the endoscopy using single dose (2  $\mu$ g/kg) of pentagastrin (Peptavlon, Zeneca, Macclesfield, Cheshire, UK) injected i.m. 10 min before the start of the start of endoscopy. The gastric juice present in the stomach was removed and then aspirated during 10 min of gastric endoscopy as described before (22). The

volume of collected juice was multiplied by  $H^+$  concentration and again multiplied by 6 to express the  $H^+$  output in mmol/h.

All patients with a diagnosed Hp infection underwent a one-week triple therapy (23, 24) including omeprazol 2x20 mg, clarytromycin 2x500 mg and metronidazol 2x500 mg. Despite symptoms no other dermatological treatment was applied 10 days before and during anti-Hp therapy.

Four weeks after the completion of the therapy, all laboratory tests were repeated to establish the effectiveness of the applied therapy. The results were statistically analysed by means of the chi 2 test, with a significance degree of  $p < 0.05$ .

## RESULTS

In the group of 60 patients with *rosacea*, 53 (88.3%), while in 60 age- and gender-matched NUD controls only 69 (65%) had the Hp infection as confirmed by at least two of Hp tests ( $^{13}C$ -UBT, CLO, culture (Fig. 1). The largest number of the infected patients were between 41–50 years of age (20 patients — 37.7%) and the smallest number aged between 31–60 years (3 patients — 5.6%) (Fig. 2). The Hp positivity was detected in 88% of *rosacea* patients and in 65% in NUD controls was largely observed in

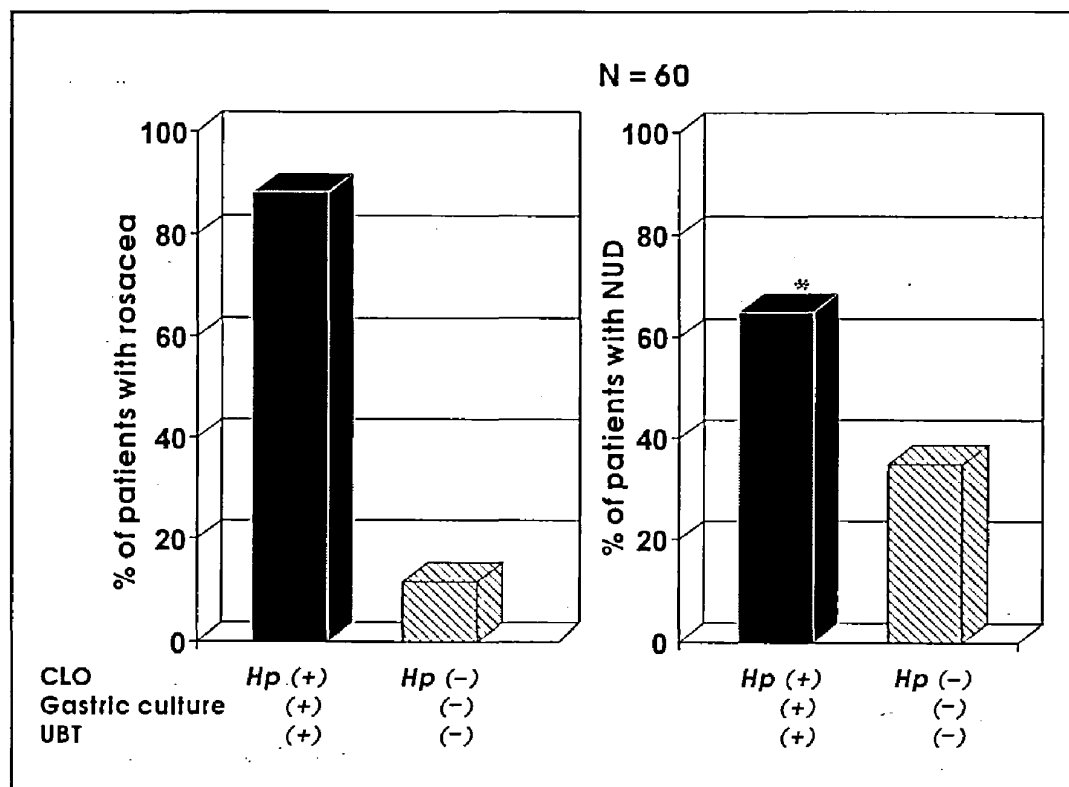


Fig. 1. The Hp positivity measured by CLO, culture and UBT in *rosacea* and NUD controls. Asterisk indicates significant decrease below the value obtained in *rosacea* patients.

patients between 31 and 60 years of age. The overall difference in Hp prevalence between *rosacea* patients and NUD controls was statistically significant (Fig. 1).

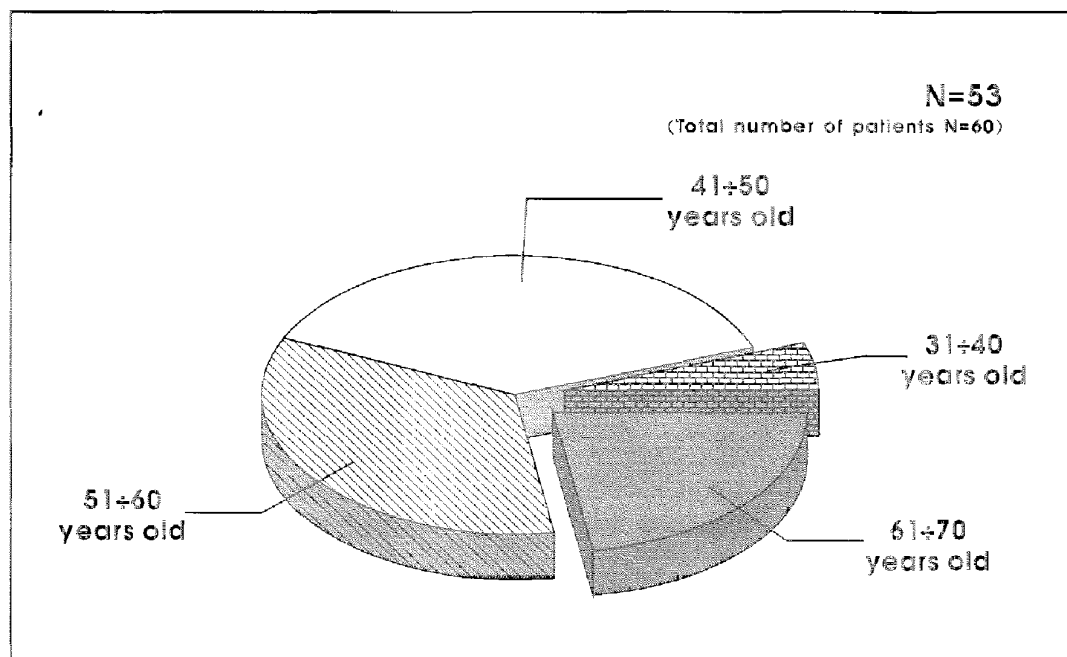


Fig. 2. The age distribution of Hp positive patients with *rosacea*.

Fig. 3 shows the occurrence of gastrointestinal symptoms in patients with *rosacea* and the presence of Hp in their stomach. Among 52 *rosacea* patients reporting a variety of gastrointestinal symptoms, e.g., heartburn, flatulence, belching, light pain, diarrhea, etc., 47 were Hp-positive, and in the group without symptoms (8 patients) the presence of the bacterium was found in 6 patients. Among NUD controls all patients showed gastrointestinal symptoms irrespective whether they were Hp positive or Hp negative.

Based on the histological examination of biopsy specimens taken from gastric mucosa, it was established (based on the classification of inflammatory changes according to the Sydney system) that the largest proportion of *rosacea* patients, i.e. 72%, exhibited the histologically chronic active *gastritis*, predominantly involving the antral portion of the stomach (*antritis*). In about 10% of the patients chronic active multifocal inflammation of the stomach (*gastritis multifocalis*), and in remaining 18% *antritis* and chronic inflammation of the body of the stomach (*corpusitis*) were found (Fig. 4). In NUD controls, only antral chronic active *gastritis* without involvement of the fundic gland area was found in histology.

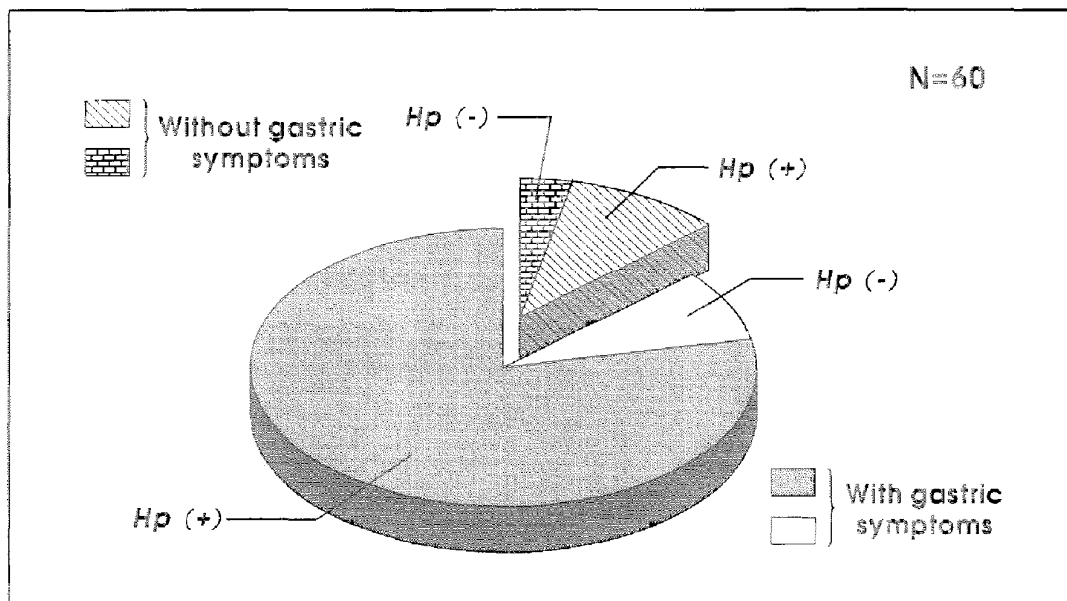


Fig. 3. The occurrence of gastrointestinal symptoms in Hp positive and Hp negative *rosacea* patients.

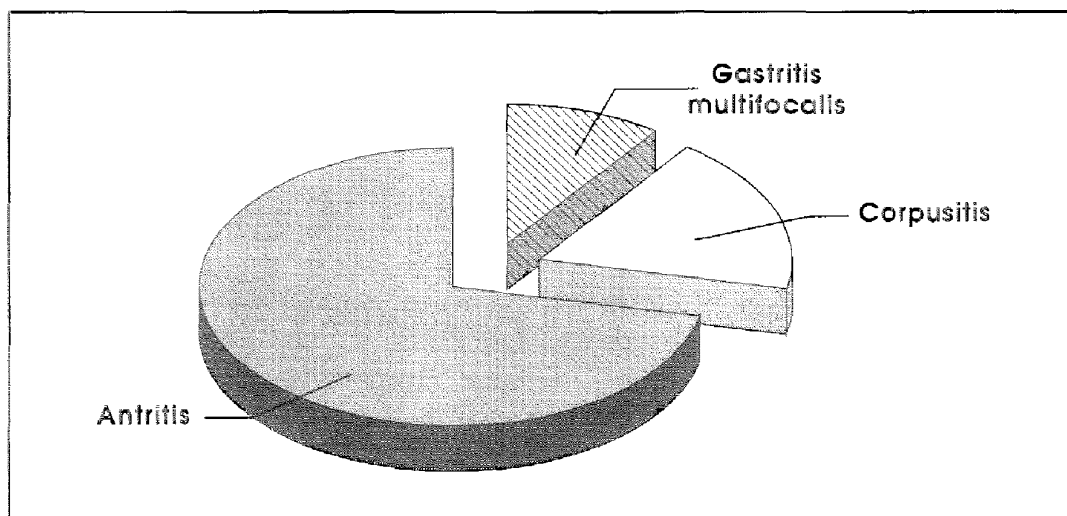


Fig. 4. Histology findings in the *antrum* and *corpus* of the stomach in *rosacea* patients.

Based on serological tests, it turned out that in patients with Hp infection in the stomach, the plasma anti-Hp antibodies of IgG class were present in about 88% of infected patients and antibodies to CagA in about 67% of these patients (Fig. 5). These seroprevalence of anti-Hp and anti-CagA antibodies between *rosacea* patients and NUD controls was statistically significant.

Out of 53 Hp-positive patients with typical for *rosacea* skin changes, the anti-Hp therapy resulted in Hp eradication in all treated patients as confirmed

by at least two of the Hp detecting tests. The cutaneous *rosacea* symptoms disappeared or fully receded in 51 patients, markedly declined in one but remained unchanged in one other patients (Fig. 6).

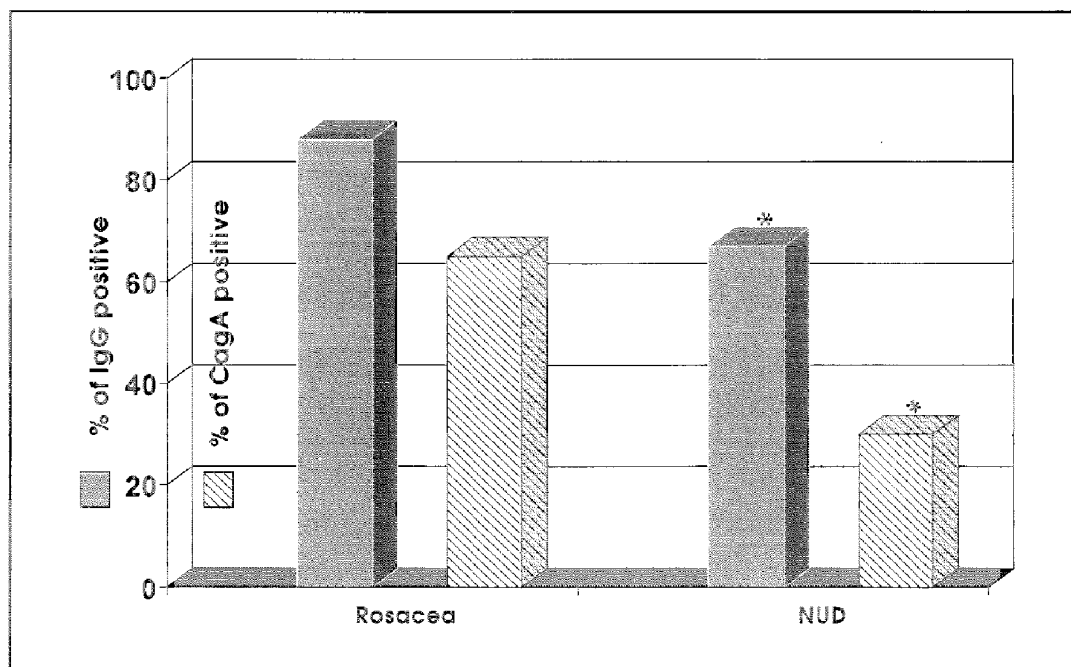


Fig. 5. Serum levels of IgG anti-Hp and anti-CagA antibodies to Hp in patients with *rosacea* and in NUD controls. Asterisk indicates significant decrease below the value obtained in *rosacea* patients.

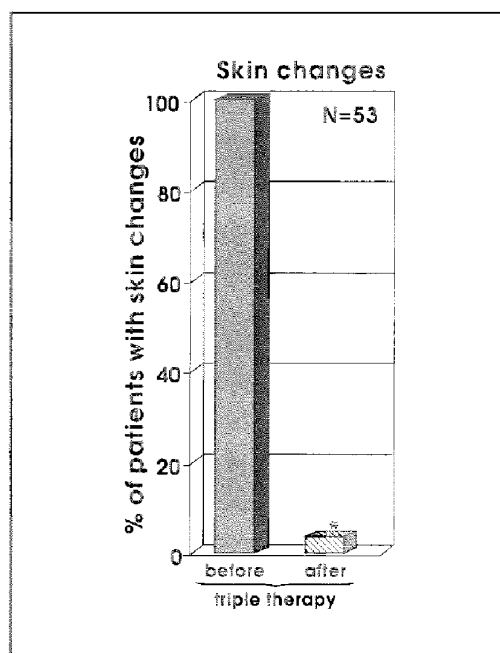


Fig. 6. Dermatological effects of Hp eradication.

Serum levels of TNF $\alpha$  and IL-8 were reduced after anti-Hp therapy by 72 and 65%, respectively. Serum gastrin level that under basal conditions amounted to about  $48 \pm 5$  pM was reduced after Hp therapy by 35%. Maximal gastric acid secretion induced by pentagastrin that averaged about  $16.6 \pm 4.2$  mmol/h in *rosacea* patients before the anti-Hp therapy was significantly reduced to about  $8.5 \pm 1.8$  mmol/h 4 weeks upon the completion of this therapy.

## DISCUSSION

Hp is an undoubtedly the most common cause of infection of the world dimension and is usually accompanied by *gastritis* and various gastrointestinal symptoms that favorably respond to antibiotic therapy (25). The major interest in Hp-related diseases has so far been focused on local gastro-duodenal disorders induced by the inoculation of gastro-duodenal mucosa by Hp and resulting in *gastritis*, peptic ulcerations, gastric cancer and MALT lymphoma (25).

More recently numerous publications described an association, mostly based on epidemiological studies, between the gastric Hp infection and certain extragastric symptoms of this infection including cardio-vascular system (26), extragastric MALT lymphoma (26), food allergy (27), certain skin diseases (28) and others described, in part, in this issue of this Journal.

Our present results provide an evidence that *rosacea* could be considered as one of major extragastric manifestations of Hp infection in the stomach. We found that the prevalence of Hp infection in *rosacea* patients was significantly higher than in age- and gender-matched controls as documented by  $^{13}\text{C}$ -UBT, CLO, culture and serology. Also the expression of Hp-related CagA cytotoxin was significantly higher in *rosacea* patients (about 67%) than in age- and gender-matched controls (32%). The seropositivity of CagA and significantly elevated serum levels of proinflammatory cytokines such as TNF $\alpha$  and IL-8, were probably the major factors in the pathogenesis of *rosacea* symptoms. These factors could also explain the presence of chronic active *gastritis* in all subjects tested and confined predominantly to the *antrum* (*antritis*) and less often to the *corpus* (*corpusitis*) in our *rosacea* patients.

The major support for the notion that Hp infection is strongly associated with *rosacea* is provided by our finding that the successful anti-Hp therapy, including antibiotics (clarithromycin + metronidazole) combined with omeprazole, was followed by the disappearance of the *rosacea* symptoms in almost all patients and also caused a marked reduction in gastrointestinal symptoms. Also, the serum levels of proinflammatory cytokines such as TNF $\alpha$  and IL-8, were dramatically reduced (by 72% and 65%, respectively) following such anti-Hp therapy.



As critically discussed in present issue of this journal by Wedi and Kapp (27), various skin diseases have been linked to Hp infection with best evidence for such association found with *urticaria* and *rosacea*. The major problems with clear cut documentation of this linkage are various confounding factors, especially properly selected control group, which have to be taken under consideration in epidemiological studies related to this linkage. So far only Bamford *et al.* (28), conducted the double-blind placebo control randomized study but, while in their study no difference was found in the Hp prevalence between *rosacea* and their double-blind controls, they also showed marked improvement of the *rosacea* symptoms thought it was irrespective to the presence of Hp infection. Authors concluded, therefore, that Hp is not the major determinant of the presence, severity and extent of *rosacea*.

Our results confirms, in part, these finding by showing that: 1) the Hp prevalence is significantly higher in the *rosacea* patients than in age- and gender, and 2) the anti-Hp therapy is highly efficient in the reduction in the *rosacea* symptoms. Our conclusions differ, however, from those of Bamford *et al.* (28), as we demonstrated for the first time that not Hp alone, but the Hp-related virulence factors (CagA) and cytokines (TNF $\alpha$ , IL-8) are probably the major pathogenic factor in the Hp-infected *rosacea* patients and that the eradication of Hp in the *rosacea* patients abolish both the cutaneous and gastrointestinal symptoms. Furthermore, the anti-Hp therapy dramatically improved the histology of the gastric mucosa and restored highly elevated plasma gastrin level and elevated gastric acid secretion. Thus, it is reasonable to accept that CagA positive Hp and various Hp-related cytokines contribute to the pathogenesis of *rosacea* and accompanying gastrointestinal symptoms.

#### REFERENCES

1. Chu T. Treatment of *rosacea*. *Practitioner* 1993; 237: 941—945.
2. Amichai B, Grunwald MH, Avinoach J, Halevy S. Granulomatous *rosacea* associated with *Demodex folliculorum*. *Int J Dermatol* 1992; 31 (10): 718—719.
3. Jabłońska S, Chorzelski T. *Skin Disease* (in Polish). PZWL 1994, pp. 386—387.
4. Gwóźdźński Z. *Rosacea — pathogenesis and treatment* (in Polish). *Medipress Dermat* 1998; 3: 1—3.
5. Braun-Falco O, Plewig G, Wolff HH, Winkelmann RK. *Dermatology*. Springer Verlag Berlin Heidelberg 1991.
6. Wilkin JK. *Rosacea*. Pathophysiology and treatment. *Arch Dermatol* 1994; 130: 359—362.
7. Zegarska B. Pathological processes in the upper digestive tract in patients with *rosacea* and role of food allergens in etiopathogenesis of this disease. (in Polish). Doctor's Thesis, Medical Academy, Bydgoszcz 1993.
8. Powell EC, Corbally N, Powell D. Substance P and *rosacea*. *J Am Acad Dermatol* 1993; 28: 132—133.

9. Koźmińska-Kubarska A. *Outlines of Medical Cosmetic* (in Polish). PZWL Warszawa 1991: 149—151.
10. Bonnar E, Eustace P, Powell FC. The *Demodex* mite population in *rosacea*. *J Am Acad Dermatol*. 1993; 28: 443—448.
11. Niczyporuk W, Dąbrowski M. *Rosacea a Demodex folliculorum*. *Post Dermatol* 1992; 9: 165—167.
12. Nowicki R. Demodicosis (*Acne rosacea demodes*). *Przegl Dermatol* 1993; 80: 568—570.
13. Broniarczyk-Dyla G, Dubla-Berner M. Current review of etiopathogenesis and treatment of *rosacea* (in Polish). *Nowa Medycyna* 1997; 4: 23—24.
14. Maciejewska-Udziela B, Jakubowicz K. Secretory function and morphology of gastric mucosa in *rosacea* (in Polish) *Przegl Dermatol* 1985; 72: 3—6.
15. Rebora A, Drago F, Parodi A. May *Helicobacter pylori* be important for dermatologist? *Dermatology* 1995; 191 (1): 6—8.
16. Utas S, Ozbakir O, Turasan A, Utas C. *Helicobacter pylori* eradication treatment reduces the severity of *rosacea*. *J Am Acad Dermatol* 1999; 40 (3): 433—435.
17. McColl KEL, El-Omar EM, Gillen D. The role of *H. pylori* infection in the pathophysiology of duodenal ulcer disease. *J Physiol Pharmacol* 1997; 48 (3): 287—295.
18. Konturek PCh, Konturek JW, Konturek S J. Gastric secretion and the pathogenesis of peptic ulcer in the *Helicobacter pylori* infection. *J Physiol Pharmacol* 1996; 47 (1): 5—19.
19. Marshall BJ, Barret LJ, Prakash C *et al*. Urea protects *Helicobacter* (*Campylobacter*) *pylori* from the bactericidal effect of acid. *Gastroenterology* 1990; 99: 697—702.
20. Shimoyama T, Crabtree JE. Mucosal chemokines in *Helicobacter pylori* infection. *J Physiol Pharmacol* 1997; 48 (3): 315—323.
21. Pytko-Polończyk J, Konturek SJ, Karczewska E, Bielanski W, Kaczmarczyk-Stachowska A. Oral cavity as permanent reservoir of *Helicobacter pylori* and potential source of infection. *J Physiol Pharmacol* 1996; 47: 121—127.
22. Iijima K, Ohara S, Sekine H *et al*. Changes in gastric secretion assayed by endoscopic test before and after *Helicobacter pylori* eradication. *Gut* 2000; 46: 20—26.
23. Labenz J, Malfertheiner P. European Concepts for the Management of *Helicobacter pylori* Infection. *Munch Med Wschr* 1997; 24: 30—32.
24. Cave DR, Hoffman JS. Treatment of *H. pylori* infection in patients with ulcer disease. (in polish). *Med Dypl* 1996; 5: 171—179.
25. Konturek PC, Hahn EG, Konturek SJ. *Helicobacter pylori* associated gastric pathology. *J Physiol Pharmacol* 1999, 50: 695—710.
26. Konturek SJ. Role of *Helicobacter pylori* infection in extragastro-duodenal disorders: Introductory remarks. *J Physiol Pharmacol* 1999; 50: 683—694.
27. Wedi B, Kapp A. *Helicobacter pylori* infection and skin diseases. *J Physiol Pharmacol* 1999, 50: 753—776.
28. Bamford JTM, Tilden RL, Blankush JL, Gangness DE. Effect of treatment *Helicobacter pylori* infection on *rosacea*. *Arch Dermatol* 1999; 135: 659—663.

Received: October 28, 1999

Accepted: November 24, 1999

Author's address: A. Szlachcic, Department of Physiology Univ. Med. School, Cracow, Poland.