
ADVANCES IN

Dermatology®

VOLUME 17

Editor-in-Chief

William D. James, MD

Albert M. Kligman Professor of Dermatology, Director of Resident Program and Faculty Clinic, University of Pennsylvania School of Medicine, Philadelphia

Associate Editors

Clay J. Cockerell, MD

Director, Division of Dermatopathology, Clinical Professor of Pathology and Dermatology, University of Texas Southwestern Medical Center, Dallas

Mary E. Maloney, MD

Professor of Medicine (Dermatology), Clinical Division Chief and Director of Dermatological Surgery, University of Massachusetts Medical School, Worcester

Amy S. Paller, MD

Professor of Pediatrics and Dermatology, Northwestern University Medical School; Head, Division of Dermatology, Children's Memorial Hospital, Chicago

Kim B. Yancey, MD

Professor and Chair, Department of Dermatology, Medical College of Wisconsin, Milwaukee





Publisher: Cynthia Baudendistel
Developmental Editor: Victoria Cernich
Manager, Continuity Production: Idelle L. Winer
Senior Production Editor: Pat Costigan
Project Supervisor, Production: Joy Moore
Composition Specialist, Production: Betty Dockins

Copyright © 2001 by Mosby, Inc

All rights reserved. No part of this publication may be reproduced, stored in a retrieval system, or transmitted, in any form or by any means, electronic, mechanical, photocopying, recording, or otherwise, without prior written permission from the publisher.

Permission to photocopy or reproduce solely for internal or personal use is permitted for libraries or other users registered with the Copyright Clearance Center, provided that the base fee of \$35.00 per chapter is paid directly to the Copyright Clearance Center, 21 Congress Street, Salem, MA 01970. This consent does not extend to other kinds of copying, such as copying for general distribution, for advertising or promotional purposes, for creating new collected works, or for resale.

Printed in the United States of America
Composition by Thomas Technology Solutions, Inc
Printing/binding by the Maple-Vail Book Manufacturing Group

Editorial Office:
Mosby, Inc
11830 Westline Industrial Drive
St Louis, MO 63146
Customer Service: hhspcs@harcourt.com

International Standard Serial Number: 0882-0880
International Standard Book Number: 0-323-01535-2

C

CHAPTER 2

Pathogenesis of Rosacea

Mark V. Dahl, MD

Professor and Chairman, Department of Dermatology, Mayo Clinic
Scottsdale, Scottsdale, Ariz

EDITOR'S COMMENT

Rosacea is a source of constant embarrassment and worry for our affected patients. Bright red cheeks, enlarged noses, and erythematous papules and pustules interfere with social and occupational interactions. Depression, anxiety, and inferences about alcoholism haunt sufferers of this fiery disease. To compound their misery, very few hard data exist regarding the etiopathogenesis of rosacea. Dr Mark Dahl, who has a long interest in helping alleviate the effects of this illness, shares his insights in this superbly written article. Mark separates rosacea into several subsets of specific findings. Explanations behind the appearance of each of them are reviewed. In the concluding section, a unifying concept is proposed to bring all of these contributing factors into focus and explain the totality of the signs and symptoms of this chronic and very public disease. Expanding this knowledge base and using our discoveries to improve therapy are goals we look forward to being realized.

William D. James, MD

Rosacea is a disease composed of many elements or subsets. Rosacea is more like a syndrome than a single disease. Although all patients with rosacea develop some erythema of their skin, not all patients develop all other stigmata. Some patients have centrofacial flushing and edema. Others are more troubled by papules and pustules. Still others are more troubled by burning and stinging sensations, or by rhinophyma. Subsets of rosacea are listed in Table 1.

The cause of the rosacea complex is unknown, and unifying hypotheses are speculative. Whatever the cause, facial skin is

TABLE 1.
Subsets of Rosacea

Erythema
Flushing
Edema
Papules and pustules
Telangiectasias
Stinging and burning sensations
Rosacea dermatitis
Rosacea cellulitis
Fibrosis/rhinophyma

predisposed. The disease affects only the facial skin and cornea. The tip of the nose is affected first, followed sequentially by the cheeks, forehead, and chin.

ERYTHEMA

Many people have ruddy complexions. Not all of these people have rosacea. The ruddy erythema of rosacea tends to persist (erythema congestivum) and usually waxes and wanes markedly in response to changes of body temperature, ingestion of certain foods, evoked emotions, or other factors. Sometimes the erythema involves the whole face, but more often it involves just the central face. Erythema is often striped by telangiectatic blood vessels.

A red complexion characterizes people of European extraction, particularly Celts. In addition to this obvious genetic element, erythema is more pronounced in some families than in others. The amount of blood in the facial skin and blood vessels is high. Total movement of red blood cells in flush areas of rosacea skin is 3 to 5 times higher than in controls.¹

Finally, the erythema of rosacea seems aggravated by chronic sun exposure and photodamage. People without rosacea can develop poikiloderma of Civatte (erythromelanosis coli), and this same propensity toward erythema and telangiectasia seems to augment the baseline erythema among patients with rosacea and lightly pigmented skin. Solar damage is not a prerequisite for the development of rosacea.^{2,3} Patients with rosacea are not more prone to sunburn.⁴

The blushlike redness that develops on rosacea faces during and after exposure to sunlight is more likely caused by heat from infrared radiation than by photons from ultraviolet radiation. The radiant heat-derived redness develops quickly during (rather than

after) exposure. Exposing facial skin to other sources of radiant heat, such as heat from a fireplace or stove, reproduces it.

Immunofluorescence staining of rosacea skin often finds immunoglobulins, especially IgG and IgM, at the dermal-epidermal junction of sun-damaged skin and facial skin of patients with rosacea. This can be an artifact produced by preserving specimens in Michel's transport media, which seems prone to increase non-specific staining of dermis, dermal-epidermal junction, and blood vessels, especially in sun-damaged skin (unpublished observations). In other patients, the appearance of immunoglobulin deposits at the dermal-epidermal junction (especially in dermal papillae) is an artifact allegedly produced by compression of autofluorescing elastic tissue against the dermal-epidermal junction by edema and dilated papillary dermal blood vessels (Burnham's "fibrillar pseudoband").⁵

Perhaps in others, antibodies bind to sun-damaged connective tissue.⁶⁻⁹ Circulating IgG and IgM antibodies to collagen, anti-nuclear antibodies, and anti-*Demodex* antibodies have been found in patients' sera. In addition, eluates from autologous circulating lymphocytes in peripheral blood of patients with rosacea have reacted with nuclei of "dermal cells," endothelial cells, and eccrine duct cells.⁷

FLUSHING

Both flush and erythema occur when blood vessels dilate and blood flow increases in superficial vessels of the skin. Whereas the erythema is chronic and persistent and varies subtly, the flushing can wax and wane quickly. Flushing usually involves the central face and is associated with a warming of surface skin.

Patients with mastocytosis and carcinoid syndrome can develop all the stigmata of rosacea, including ocular rosacea, facial telangiectasia, and connective tissue hypertrophy.¹⁰⁻¹² Flushing can be stimulated by various environmental trigger factors as listed in Table 2.

In hyperthermic, but not normothermic healthy human beings, cool venous blood from the face and scalp enters the dural venous sinus via vascular pathways or emissary veins. The cooler blood intermingling with the brain and meningeal blood vessels keeps the intracranial temperature cool. Brinnel et al¹³ found that venous blood flow from the skin to the brain was suppressed in patients with rosacea, thus inhibiting selective brain cooling in hyperthermic conditions. Apparently, the facial skin acts like an automobile radiator to lose heat by radiation, convection, and conduction. In

TABLE 2.

Environmental Trigger Factors

Foods	Temperature Related	Beverages	Weather Sun (radiant heat)	Emotional Influences	Drugs	Physical Exertion	Skin Care Products	Menopause
Cheese (not cottage cheese)	Saunas	Alcohol	Hot, humid temperatures	Rage	Vasodilators	Exercise	Alcoholic or	
Vanilla	Simple overheating	(especially red wine)	Strong winds	Anger	Nicotinic acid	Medical conditions	acetone substances	
Thermally hot foods	Excessively warm environments	Hot drinks	Cold	Stress	Cholinergic agents	Menopause	Any substance that causes	
Chocolate			Spring season	Embarrassment	Calcium channel blockers	Caffeine withdrawal	redness or	
Soy sauce	Hot baths				Topical steroids	Straining	stinging	
Spicy foods	Radiant heat				Cyclosporin	Frequent flushing	Some cosmetics	
Liver					Opiates	Chronic cough		
Yogurt					Tamoxifen	Stress and strain jobs		
Vinegar					Rifampin			
Eggplant								
Avocados								
Spinach								
Broad-leaf beans								
Citrus fruits								

(Adapted from Dahl MV: Optimal strategies for the treatment of rosacea. *Skin & Aging* March 1999, pp 44-50, and a survey of patients by the National Rosacea Society.)

patients with rosacea, the cooled blood does not flow well from the central face. The veins of the central face (venae supratrochlearis, venae palpebrales superioris et inferioris, venae nasales externae, venae faciei profunda, venae labialis superior, venae labialis inferiores, venae submentalis, etc) drain through the cavernous sinus to co-mingle with arteries in the dura to cool them and to cool the brain. If this were impaired, flushing and venous congestion would occur. The brain would keep sending vessel dilatory signals to the blood vessels of the central face in hopes of getting more cooling action. Alternatively, the congestion could simply be passive, based on a relative block of efferent blood flow.

Here's how this study by Brinnel et al¹³ was done. The tympanic, esophageal, forehead skin surface, and hand skin surface temperatures were recorded in 4 patients with rosacea and 2 controls. Each took a 1-hour hot bath (38°C-39°C). During the last half of the bath, the facial skin was "vigorously fanned." Blood flow was measured by ultrasonic Doppler flowmeters in the sensory emissary veins of the cranium. During hyperthermia and face fanning, all control subjects had their tympanic temperatures decrease below their esophageal temperatures, indicating that the facial vessels had cooled the eardrum (a measure of intracranial temperature) relative to the central (core, esophageal) temperature. In contrast, the tympanic temperature always remained higher than the esophageal temperatures in patients with rosacea. As expected, patients with rosacea had higher forehead temperature than did controls. Sweating rates on the face were equal among patients and controls. After hot baths, Doppler flowmeters showed a rapid inward blood flow from skin to brain in control subjects, but there was no change in patients with rosacea. The authors concluded that venous blood flow from the skin to the brain is suppressed in rosacea, thus inhibiting brain cooling in hyperthermic conditions.

Flushing, at least from ingestion of alcoholic beverages, may be mediated by catecholamines derived from the gastric mucosa. Alcohol would liberate catecholamines, which would elevate levels of bradykinin in blood, leading to flushing.¹⁴ As might be predicted from such a hypothesis, clonidine (an α_2 -agonist) could inhibit such flushing, and indeed it does. However, alcohol-induced flushing might also be mediated by opioids, since it also can be partly blocked by the opiate antagonist naloxone.¹⁵

Although caffeine and coffee are alleged to provoke flushing, ingestion of neither caffeine nor coffee at 22°C leads to flushing reactions. However, ingestion of both coffee and water at 60°C causes flushing reactions. Apparently the heat of the beverage, not

the caffeine or coffee in it, produces the flush in coffee drinkers.¹⁶ Migraine headaches occur more commonly among patients with rosacea, which is not surprising because both are associated with abnormal vascular reactivity, and both are aggravated by stress.¹⁷ Substance P may be involved in neural flush.¹⁸

Although a link between rosacea and gastrointestinal illness seems plausible, linking mechanisms, if any, are speculative. Clearly, administration of hot beverages, spicy foods, and other foods can evoke flushing and rosacea. Flushing in these cases might be caused by direct effects of secondary mediators on all blood vessels or by overzealous attempts to cool the body or brain. Both gastrin and vasoactive intestinal peptide have vasodilatory actions, so these agents could elicit flushes from gastrointestinal illnesses and stimulations. This is speculative. Jejunal biopsy specimens taken from 34 patients with rosacea and compared with those from 34 patients with other skin diseases showed no consistent abnormality. Careful history taking from patients showed no difference in the prevalence of gastrointestinal illness or symptoms in the 2 groups.¹⁹ Pancreatic exocrine function is normal, although the output of pancreatic lipases is lower among patients with rosacea.²⁰ In a study comparing organisms isolated from feces, patients with rosacea harbored a significantly higher frequency of *Penicillium lanoso-coeruleum* and *Aspergillus niger*. Patients with rosacea also harbored a larger amount of antibodies to these organisms in their blood.²¹ The significance of these findings is unknown.

Helicobacter pylori is a bacterium that frequently colonizes the stomach and is associated with gastric ulcer disease. A study of 60 rosacea patients with papules, pustules, erythema, and flushing found a prevalence of *H. pylori* of 88% compared with 65% in control patients. Patients with rosacea were more likely to have gastritis in their stomach's antrum. After treatment for *H. pylori* with omeprazole, clarithromycin, and metronidazole, symptoms of rosacea disappeared in 51 patients, markedly decreased in 1 patient, and remained unchanged in 1 other patient. Vasogastrin levels decreased from 48 pmol/L before treatment to 17 pmol/L after treatment. Levels of pentagastrin, plasma tumor necrosis factor- α , and interleukin-8 were also reduced slightly in sera after treatment. The authors concluded that rosacea was a disorder closely linked to gastritis, especially in the antrum mucosa. Both occurred frequently in patients colonized by *H. pylori* expressing the cytotoxin-associated gene A (CagA).²² Other researchers also have noted that rosacea improves when *H. pylori* is eradicated by

treatment, but the improvement may be more related to the well-known (and perhaps independent) response of rosacea to many of the antibiotics that are used to kill the associated *H pylori*.²³⁻²⁵

EDEMA

After blood vessels dilate, plasma can exude from the dilated vessels. If the outflow is high enough, the outflow surpasses the ability of lymphatics to carry the excess fluid away, resulting in clinical swelling. Facial swelling is observed from time to time among patients with rosacea, although usually not in a physician's office. Edema clearly can develop after vasodilation. The role of edema in producing other sequelae of rosacea (such as inflammatory papules) is more speculative. Wilkins²⁶ believes that inflammatory edema can appear in these circumstances, especially when facial cutaneous lymphatic vessels are damaged. Exposure to ultraviolet radiation may damage lymphatic vessels and thereby slow clearance of tissue fluids. Edema can produce low-grade cellulitis. Rosacea occurs in patients with Morbihan disease (lymph vessel dysplasia), lending support to the notion that edema is the fuse that ignites inflammation.

Stigmata of rosacea are typically found in areas of the face overlying relatively inactive musculature. In these areas, edema caused by flushing might tend to persist, since edema fluid and venous blood in vessels in this area would not be subjected to pumping effects related to contraction of adjacent muscles.²⁷ Interrelationships among edema, elastin degeneration, neutrophil proteases, and cutaneous cellulitis have been reviewed.²⁶ Furthermore, transudation of factor XIII can cause connective tissue hypertrophy and fibroplasia that might lead to fibrosis and phymas.²⁸

PAPULES AND PUSTULES

Papules and pustules of rosacea so much resemble acne vulgaris that the condition has been called acne rosacea. However, comedones are absent. Papules and pustules are limited to the face (especially the flush and erythematous areas), and no bacterium has been consistently isolated from pustules. Oil glands secrete sebum at normal rates.²⁹ Follicle and surface lipid compositions are probably normal,³⁰ although epidermally derived surface cholesterol levels may be increased.³¹ The amounts of free fatty acids in surface lipids may decrease and amounts of free squalene may increase after treatment with tetracycline, although studies are

controversial.^{30,31} Serum levels of testosterone and estradiol are normal, as are cellular levels of estrogen and androgen.³²

Biopsy specimens from patients with rosacea show an inflammatory cell infiltrate in the upper and mid-dermis consisting mostly of lymphocytes and histiocytes intermingled with polymorphonuclear leukocytes, plasma cells, and giant cells. Only about 25% of biopsy specimens show areas of acute folliculitis. In the remainder, the inflammation is entirely independent of the pilosebaceous unit.³³ Surprisingly, much of the inflammation resides far away from the pilosebaceous apparatus. In fact, Marks et al³³ found acute folliculitis in only 25% of 24 serially sectioned skin biopsy specimens. In 51%, the infiltrate was partially distributed around the hair follicles, 78% showed some follicular plugging, and 19% showed recognizable *Demodex*. Granulomatous rosacea also shows no particular predilection to follicles.³⁴

Despite these findings, I believe that the papules and pustules do have a bacterial origin. The prompt improvement and even clearing of papules and pustules that routinely follows the use of numerous oral and topical antibiotics of completely different chemical structures and microbial spectrums would seem to support this view. I believe that normal bacteria on the skin surface or in follicles behave differently in the milieu of elevated skin surface temperature. Indeed, staphylococci isolated from pustules secrete different products when cultured at different temperatures (Dahl MV, Shlievert P: submitted for publication). The role, if any, of staphylococcal exotoxins acting as superantigens to elicit cell-mediated inflammation is unknown. Furthermore, the role, if any, of toxins or other products elaborated at various temperatures by normal *anaerobic* constituents of the follicles (such as *Propionibacterium acnes*) is also unknown.

Demodex mites are frequently found in facial follicles of patients with rosacea.^{33,35,36} These organisms constitute part of the normal flora of the face, but the prevalence of *Demodex* mites in facial skin of patients with rosacea is greatly increased.³⁷ Although many follicles of patients with rosacea harbor numerous *Demodex* organisms, there is no difference in the number of mites in infested follicles of patients with rosacea compared with controls.³⁸

The role of *Demodex* mites in producing follicular papules and pustules in patients with rosacea is speculative. Forton³⁹ found a positive correlation between the presence of *Demodex* mites and the development of inflammation ($P < .001$). Elimination of *Demodex* mites with treatment sometimes leads to improvement. Infrequently, *Demodex* parts have been seen in the inflammatory milieu

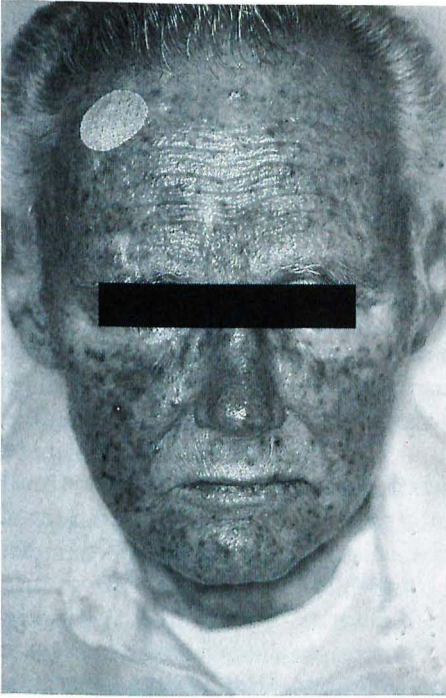

FIGURE 1.

Demodex folliculitis. This man developed these widespread facial red papules and crusted papules only 3 months previously. Biopsy specimens showed *Demodex folliculorum* and follicular inflammation. The papules responded promptly to treatment with a single overnight application of lindane and systemic tetracycline.

around a ruptured follicle of a patient with rosacea, suggesting that the inflammatory response resulted from the extruded organism. Whereas rosacea is usually successfully treated with tetracycline, mite counts do not decrease during treatment.³⁷ Perhaps *Demodex* folliculitis is a separate disease from rosacea that is frequently associated with rosacea because of the high prevalence of mites on facial skin of patients with rosacea (Fig 1).

TELANGIECTASIA

Telangiectases are dilated blood vessels. They are frequently found in the milieu of erythema and flush and are usually particularly prevalent in the area near the nasolabial fold. With long-standing erythema and flush, vessels become more apparent on the nose and

cheeks. Endothelial walls are often thicker than normal, and a perivascular inflammatory cell infiltrate around telangiectatic blood vessels is not rare in rosacea compared with other telangiectases in otherwise normal patients.^{40,41} A role for sun damage as a cofactor seems likely because telangiectases are often seen in chronically sun-damaged skin. Furthermore, more elastotic change was found in patients with rosacea than in controls, despite the fact that the controls reported more sun exposure.^{41,42}

STINGING AND BURNING SENSATIONS

Patients with rosacea frequently complain that their skin is "sensitive"; moisturizers, cosmetics, sunscreens, and other topically applied products cause unpleasant burning and stinging sensations. The skin feels tight or dry. The reason for this is speculative. Substance P is released from nerves by various stimuli, and substance P is found in abundance around papillary dermal blood vessels of patients with rosacea.⁴² Even serum levels of substance P may be increased among patients with rosacea.⁴³ I speculate that acetylcholine released from keratinocytes after activation by soaps and detergent-like emulsifiers might also cause stinging and burning sensations.^{44,45} In these patients, the keratinocyte acts as the end organ, secreting acetylcholine to activate cutaneous neurons.

Barrier function may be compromised by rosacea dermatitis. The disruption or abnormality of the stratum corneum could allow increased penetration of sensory irritants. Alternatively, nerves of patients with rosacea may react abnormally to sensory irritants. When 5% lactic acid (or water) was applied to the cheeks of patients with rosacea, 24 of 32 patients with rosacea reported stinging as opposed to only 6 control subjects ($P < .001$).⁴⁶ All 7 patients with erythematotelangiectasia reported stinging. This suggests a relationship of blood vessels and pain (erythrodysesthesia).⁴⁷

Whatever the cause, patients often stop washing their faces because they believe soap not only causes burning sensations, but also because they believe soap-and-water washings cause dryness. Ayres and Ayres⁴⁸ noted this habit decades ago. They believed failure to wash facial skin leads to higher densities of *Demodex* mites, which in turn leads to stinging, burning, and dryness, which in turn leads to still less frequent washing. Treatment with sulfur (which eliminates *Demodex*) seemed helpful. They advised these patients to resume face-washing.

ROSACEA DERMATITIS

Many patients with rosacea experience roughness and scaling (they call it "dryness"), especially on the cheeks. Clinicians frequently diagnose seborrheic dermatitis, but more typical sites for seborrheic dermatitis such as the scalp and eyebrows are usually spared. Other clinicians believe the dermatitis results from irritation, and take the frequent association of stinging and burning sensations as evidence. Pityriasis folliculorum consists of follicular plugs, and fine, rough, white scales occurring on flushed faces. It may be a dermatitis caused by *Demodex folliculorum*.⁴⁸ Sometimes large numbers of *Demodex* organisms can even produce scaling patches.⁴⁹

The dermatitis in rosacea seems unique enough to me to be considered as an eczematous process in its own right. Roughness and sometimes mild erythema of the skin on the cheeks are present, especially near the nasolabial folds. The dermatitis responds to topical steroids, but it also variably responds to topical and systemic antibiotics and to topical and systemic antifungal agents such as ketoconazole. Here again, higher densities of *Demodex* or staphylococcal organisms on the skin surface may play a role. The higher skin surface temperature of chronically erythematous skin may support higher densities of bacteria and enhanced toxin production.

ROSACEA CELLULITIS

The inflammatory response affecting patients with rosacea spreads well beyond facial follicles and may involve large areas. Rosacea cellulitis likely has causes similar to causes of papules and pustules, as evidenced by the following: (1) the disorder spreads from typical papules and pustules; (2) the disorder is almost always associated with the presence of active inflammatory papules and pustules elsewhere on the skin; and (3) the disorder improves rapidly after administration of antibiotics that typically help the papules and pustules of rosacea.

PHYMAS

In some but not all patients with rosacea, fibrosis develops in affected areas, especially in the noses of men. Rhinophyma is frequently associated with fibrosis elsewhere, such as on the chin or above the nasolabial fold on the cheeks. Factor XIII in edema fluid has been blamed. Indeed, men wearing heavy glasses may develop rhinophyma distal to the nose pads as a consequence of

lymphatic obstruction ("pseudorhinophyma"; Fig 2). Microscopic examinations of rhinophyma usually show marked dermal thickening, absence of pilosebaceous units, sclerotic collagen bundles, large amounts of mucin, and dilated blood vessels.⁵⁰ The inflammatory infiltrate are inconspicuous, but there are interstitial spindle cells reactive with factor XIIIa. The picture resembles the histology of chronic lymphedema.

Alternatively, long-standing chronic inflammation of rosacea papules, pustules, dermatitis, or cellulitis may generate fibrosis. Indeed, patients with the common form of rhinophyma show a very different histologic picture from that of severe rhinophyma discussed above. Specifically, skin biopsy sections of common rhinophyma show findings of typical rosacea, except for prominent sebaceous hyperplasia.⁵⁰

The reasons men seem so much more likely to develop phymas than women are unknown, but the sex difference suggests hormonal causes. Men may be less likely to seek treatment for rosacea, but it is premature to conclude that early treatment can prevent rhinophyma.

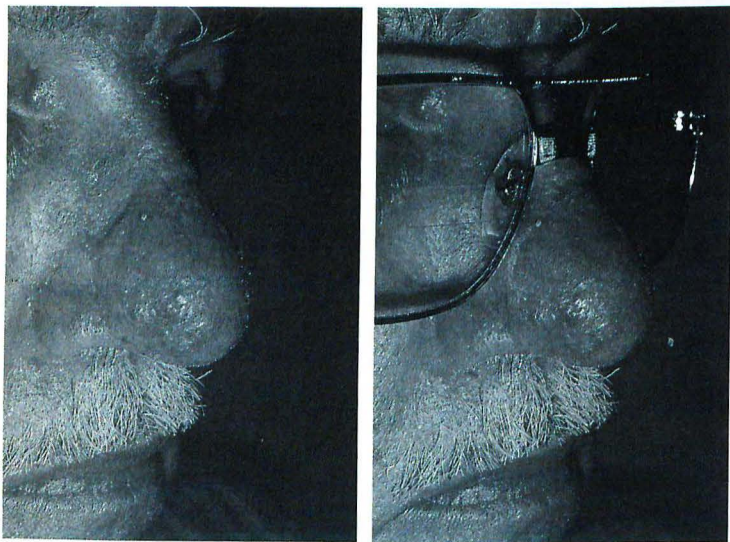


FIGURE 2.

Pseudorhinophyma. This man has a bulbous nose, presumed secondary to lymphatic obstruction of heavy spectacle frames. Lymphedema can produce fibrosis by actions of factor XIII.

OCULAR ROSACEA

Most patients with rhinophyma also have ocular rosacea. Ocular manifestations include blepharitis, meibomitis, chalazia, styes, and hyperemic conjunctivae.⁵¹ The cornea may be involved with erosions or peripheral vascularization. Most patients complain of pain, burning, or the sensation of foreign bodies in their eyes. Both eyes are usually affected. The decade of peak prevalence is 51 to 60 years, but the disorder may affect teenagers.

Bacteria have been incriminated, based on the frequent response of ocular rosacea to administration of systemic antibiotics. However, cultures are often sterile. Staphylococci can often be isolated but may be a secondary invader.⁵² *Demodex* mites frequently are found attached to epilated eyelashes, but barely with increased frequency among patients with rosacea compared with controls.⁵³

Clinically, ophthalmologists frequently observe inspissation of secretions of the meibomian gland orifices.^{54,55} Meibomian lipid composition is similar to that of controls.⁵⁶

Hoang-Xuan et al⁵⁷ suggested that conjunctival inflammation results from a type IV (cell mediated) immune reaction. They found a 3.5-fold increase in the CD4/CD8 ratio of lymphocytes in rosacea conjunctivae compared with those of normal subjects. Most of the cells are in the substantia propria, and sometimes they team up with CD14 antigen-presenting cells and phagocytes to form granulomas there.

More than half of patients with ocular rosacea had dry eyes with less than 8 mm of strip wetting seen on Schirmer testing, compared with 25% of controls ($P < .02$).⁵⁸ Dry eyes may result from ocular rosacea and an inability to maintain a normal precorneal tear film. Because so many patients with ocular rosacea have normal tests, poor tear films are unlikely the cause of rosacea and more likely an effect of it.

UNIFYING HYPOTHESIS

If rosacea is indeed one disease or syndrome, the redness of the face must somehow be related to the papules, pustules, sensations, skin-surface changes, and fibrosis (Fig 3). Erythema may result from odd brain-cooling mechanisms, sun damage, or genetic factors. Rosacea skin is warmer and blood vessels are dilated. Edema and telangiectases may result. Additional redness and edema are elicited by flushing. Edema may set off inflammation and fibrosis. Alternatively, the warm facial skin may change microbial (bacte-

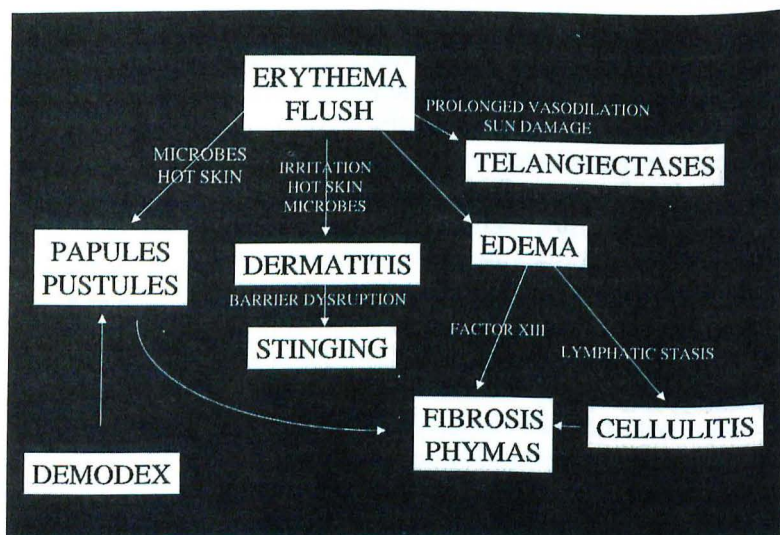


FIGURE 3.

Unifying hypothesis for cause. Erythema and flush cause papules, pustules, dermatitis, and cellulitis. This can be a direct effect of hotter skin on bacteria or skin enzymes, or it can be an indirect effect resulting from edema and lymphatic stasis. Tissue fluid of edema (working through coagulation factor XIII) or chronic inflammation can cause fibrosis.

rial) and arthropod (*Demodex*) behaviors both on the skin and in the follicles. It might also change enzyme activities of keratinocytes or other cells, leading to altered epidermal metabolism and function. These changes could lead to inflammation (papules, pustules, dermatitis, and cellulitis). Long-standing inflammation could also lead to fibrosis and telangiectases.

This hypothesis would predict that measures to control or abolish erythema and flush would stop rosacea and prevent downstream sequelae. Antibiotics may work on bacterial flora and help stop not only papules and pustules, but also stinging, dermatitis, cellulitis, and even fibrosis.

REFERENCES

1. Sibenge S, Gawkrödger DJ: Rosacea: A study of clinical patterns, blood flow, and the role of *Demodex folliculorum*. *J Am Acad Dermatol* 26:590-593, 1992.
2. Dupont C: The role of sunshine in rosacea. *J Am Acad Dermatol* 15:713-714, 1986.

3. Berg M, Sture L: An epidemiological study of rosacea. *Acta Derm Venereol (Stockh)* 69:419-423, 1989.
4. Gotz H, Crone J: Die UV-Lichtempfindlichkeit der Haut bei der Rosacea. *Z Hautkr* 55:232-236, 1980.
5. Burnham TK: The immunofluorescence band test for lupus erythematosus. *Br J Dermatol* 99:413, 1971.
6. Manna V, Marks R, Holt P: Involvement of immune mechanisms in the pathogenesis of rosacea. *Br J Dermatol* 107:203-208, 1982.
7. Nunzi E, Rebora A, Hamerlink FY, et al: Immunopathological studies on rosacea. *Br J Dermatol* 103:543-551, 1980.
8. Nunzi E, Rebora A, Cornelis JJ, et al: UV-induced pyrimidine dimers and rosacea. *Br J Dermatol* 104:711, 1981.
9. Baart de la Faille H, Baart de la Faille-Kuyper EH: Immunofluorescent studies of the skin in rosacea. *Dermatologica* 139:49-54, 1969.
10. Wilkin JK: Rosacea: Pathophysiology and treatment. *Arch Dermatol* 130:359-362, 1994.
11. Wilkin JK: Rapidly progressive rosacea in an adult male with flushing attacks, pruritus, and "freckles." *Contemp Intern Med* 3:150-160, 1991.
12. Findlay JH, Simson IW: Leonine hypertrophic rosacea associated with a benign bronchial carcinoid tumor. *Clin Exp Dermatol* 2:175-176, 1977.
13. Brinnel H, Friedel J, Caputa M, et al: Rosacea: Disturbed defense against brain overheating. *Arch Dermatol Res* 281:66-72, 1989.
14. Guarrera M, Parodi A, Cipriani C, et al: Flushing in rosacea: A possible mechanism. *Arch Dermatol Res* 272:311-316, 1980.
15. Bernstein JE, Soltani K: Alcohol-induced rosacea flushing blocked by naloxone. *Br J Dermatol* 107:59-62, 1982.
16. Wilkin JK: Oral thermal-induced flushing in erythematotelangiectatic rosacea. *J Invest Dermatol* 76:15-18, 1981.
17. Tan SG, Cunliffe WJ: Rosacea and migraine. *Br Med J* 1(6000):21, 1976.
18. Powell FC, Corbally N, Powell D: Substance P in rosacea. *J Am Acad Dermatol* 28:132-133, 1993.
19. Marks R, Beard RJ, Clark ML, et al: Gastrointestinal observations in rosacea. *Lancet* 1:739-742, 1967.
20. Barba A, Rosa B, Angelini G, et al: Pancreatic exocrine function in rosacea. *Dermatologica* 165:601-606, 1982.
21. Baran E: Über die Pilzflora des Verdauungstraktes bei Acne rosacea-Kranken. *Mykosen* 21:277-284, 1978.
22. Szlachet A, Sliwowski Z, Karczewska E, et al: *Helicobacter pylori* and its eradication in rosacea. *J Physiol Pharmacol* 50:777-786, 1999.
23. Bamford JT, Tilden RL, Blankush JL, et al: Effect of treatment of *Helicobacter pylori* infection on rosacea. *Arch Dermatol* 135:659-663, 1996.
24. Uatis S, Ozbakir O, Durasan A, et al: *Helicobacter pylori* eradication treatment reduces the severity of rosacea. *J Am Acad Dermatol* 40:433-435, 1999.

25. Bamford JT, Tilden RL, Blankush JL, et al: Effect of treatment of *Helicobacter pylori* infection on rosacea. *Arch Dermatol* 135:659-663, 1999.
26. Wilkin JK: Rosacea: Pathophysiology and treatment. *Arch Dermatol* 130:359-362, 1994.
27. Sobyte P: Aetiology and pathogenesis of rosacea. *Acta Derm Venereol (Stockh)* 30:137-140, 1950.
28. Penneys NS: Factor XIII expression in the skin: Observations and a hypothesis. *J Am Acad Dermatol* 22:44-48, 1990.
29. Burton JL, Pye RJ, Meyrick G, et al: The sebum excretion rate in rosacea. *Br J Dermatol* 92:541-543, 1975.
30. Pye RJ, Meyrick G, Burton JL: Skin surface lipid concentration in rosacea. *Br J Dermatol* 94:161-164, 1976.
31. Gloor VM, Wiegand I, Baumann CH, et al: Uber Menge und Zusammensetzung der Hautoberflächenlipide bei Rosacea. *Dermatologische Monatsschrift* 160:468-473, 1974.
32. Schmidt JB, Raff M, Spona J: Do sexual steroids contribute to the pathomechanism of rosacea? A study of estrogen and androgen receptors in acne rosacea. *Acta Derm Venereol (Stockh)* 63:64-66, 1982.
33. Marks R, Harcourt-Webster JN, Chir B: Histopathology of rosacea. *Arch Dermatol* 100:683-691, 1969.
34. Helm KF, Menz J, Gibson LE, et al: A clinical and histopathologic study of granulomatous rosacea. *J Am Acad Dermatol* 25:1038-1042, 1991.
35. Helm KF, Menz J, Gibson LE: A clinical and histopathologic study of granulomatous rosacea. *J Am Acad Dermatol* 25:1038-1043, 1991.
36. Erbagci Z, Ozgoztasi O: The significance of *Demodex folliculorum* density in rosacea. *Int J Dermatol* 37:421-425, 1998.
37. Bonnar E, Eustace P, Powell FC: The *Demodex* mite population in rosacea. *J Am Acad Dermatol* 28:443-448, 1993.
38. Roihu T, Kariniemi AL: *Demodex* mites in acne rosacea. *J Cutan Pathol* 25:550-552, 1998.
39. Forton F: Demodex et inflammation perifolliculaire chez l'homme: Revue et observation de 69 biopsies. *Ann Dermatol Venereol* 113: 1047-1058, 1986.
40. Motley RJ, Barton S, Marks R: The significance of telangiectasia in rosacea, in Marks R, Plewig G (eds): *Acne and Related Disorders: Proceedings of an International Symposium (Cardiff)*. London, M. Dunitz, 1989, pp 339-344.
41. Ramelet AA, Perroulaz G: Rosacee: Etude histopathologique de 75 cas. *Ann Dermatol Venereol* 115:801-806, 1988.
42. Kurkcuoglu N, Alaybeyi F: Substance P reactivity in rosacea. *J Am Acad Dermatol* 25:725-726, 1991.
43. Powell FC, Corbally N, Powell D: Substance P and rosacea. *J Am Acad Dermatol* 28:133-134, 1993.

44. Bigliardi PL, Herron MJ, Nelson RD, et al: Effects of detergents on proliferation and metabolism of human keratinocytes. *Exp Dermatol* 3:89-93, 1994.
45. Grando SA, Kist DA, Qi M, et al: Human keratinocytes synthesize, secrete, and degrade acetylcholine. *J Invest Dermatol* 101:32-36, 1993.
46. Lonne-Rahm SB, Fisher T, Berg M: Stinging and rosacea. *Acta Derm Venereol* 79:460-461, 1999.
47. Griffiths D: The red face: An overview and delineation of the MARSH syndrome. *Clin Exp Dermatol* 24:42-47, 1999.
48. Ayres S Jr, Ayres S III: Demodectic eruptions (demodicidosis) in the human. *Arch Dermatol* 83:154-162, 1960.
49. Shelley WB, Shelley D: Unilateral demodectic rosacea. *J Am Acad Dermatol* 20:915-917, 1989.
50. Aloï F, Tomasini C, Soro E, et al: The clinicopathologic spectrum of rhinophyma. *J Am Acad Dermatol* 42:468-472, 2000.
51. Jenkins MS, Brown SI, Lempert SL, et al: Ocular rosacea. *Metab Pediatr Syst Ophthalmol* 6:189-196, 1982.
52. Wise G: Ocular rosacea. *Am J Ophthalmol* 26:591-609, 1983.
53. Post CF, Juhlin E: *Demodex folliculorum* and blepharitis. *Arch Dermatol* 88:298-302, 1963.
54. Browning DJ, Proia AD: Ocular rosacea. *Surv Ophthalmol* 31:145-158, 1986.
55. McCulley JP, Sciallis GF: Meibomian keratoconjunctivitis. *Am J Ophthalmol* 84:788-793, 1977.
56. Cory CC, Hinks W, Burton JL, et al: Meibomian gland secretion in the red eyes of rosacea. *Br J Ophthalmol* 89:25-27, 1973.
57. Hoang-Xuan T, Rodriguez A, Zaltas MM, et al: Ocular rosacea: A histologic and immunopathologic study. *Ophthalmology* 97:1468-1475, 1990.
58. Gudmundsen KJ, O'Donnell BF, Powell FC: Schirmer testing for dry eyes with rosacea. *J Am Acad Dermatol* 26:211-213, 1992.