

眼 紀

5 / Vol.40
1989

BML Stacks

0410

. 40

p. 5

中島 章 教授退任記念論文集

Nippon ganka kiyo = Folia
ophthalmologica japonica =
Bulletin of Japanese
ophthalmology
BML Stacks
UNIVERSITY OF CALIFORNIA,
SAN DIEGO - LIBRARIES

Folia Ophthalmol. Jpn.

The Effect on the Cornea of Various Vehicles for Cyclosporin Eye Drops

Rodolfo M. Alba, Jr. Atsushi Kanai, Toshiyuki Takano,
Chihiro Kobayashi and Akira Nakajima

Department of Ophthalmology, Juntendo University, School of Medicine

Kozo Kurihara

Product Development Laboratories, Sankyo Co.

Masaharu Fukami

Biological Research Laboratories, Sankyo Co.

We tested several solvents, possible vehicles for Cyclosporin, (CYA) as to which had the least corneal toxicity. They were: peanut oil, palm oil, polyoxyethylene castor oil, medium chain-length triglyceride emulsion (MCT) and alpha cyclo-dextrin (α -CD). The concentration of CYA in each vehicle was: 1% in peanut oil, palm oil and MCT; 0.1% in polyoxyethylene castor oil and 0.08% in α -CD. The drugs and normal saline, which served as control, were instilled to rat corneas at frequencies of 10x (every 30 min.) and 5x. Light microscopy revealed that in the MCT, α -CD and peanut oil groups, corneal thickness approximated that in the controls. In the next phase, done on rabbit corneas, we instilled MCT (with and without CYA), α -CD and peanut oil 10x (every 30 min.). Normal saline was applied to the control eye. The Draize test, ultrasonic pachymetry, light and electron microscopic examination indicated that, compared to the other vehicles, α -CD exhibited significant corneal toxicity as evidenced by edema, diminution of microvilli on the epithelium and epithelial craters. Radioimmunoassay of CYA levels in the cornea and aq. humor indicated that α -CD afforded the greatest CYA penetration of the cornea. We then tested 4 different concentrations of α -CD to determine the least toxic concentration. The concentrations were: 80, 40, 20 and 10 mg./ml. of α -CD combined with 0.75, 0.25, 0.09 and 0.03 mg./ml. of CYA. They were applied to rabbit corneas 4x (every 2 hrs.). Histological and RIA studies indicate that 40.0 mg./ml α -CD with 0.25 mg./ml. CYA is an acceptable concentration.

(Folia Ophthalmol. Jpn. 40: 902-908, 1989)

別刷請求先: 113 東京都文京区本郷 3-1-3 順天堂大学医学部眼科学教室 金井 淳
Reprint requests to: Atsushi Kanai, M.D. Dept. of Ophthalmol., Juntendo Univ. School of Med.
3-1-3 Hongo, Bunkyo-ku, Tokyo 113, Japan

I. Introduction

Immunosuppressive drugs have contributed greatly to the success of corneal transplantation. Ideally, they should be able to traverse the cornea in sufficient amounts to prevent rejection from taking place and the dose should be low enough to avoid occurrence of toxic side-effects.

Ciclosporin, a cyclic undecapeptide of fungal origin, has been discovered to be a useful immunosuppressive compound and is used widely in organ transplantation. In previous studies,¹⁻⁵ it was shown that it can prolong survival of transplanted tissues by suppressing the function of T-lymphocytes. Its application in corneal transplantation has been rather limited due to its insolubility in water.

The purpose of this study is to investigate the effect on the cornea of various vehicles for Ciclosporin (CYA).

II. Materials and Method

We performed preliminary studies on rats by testing several solvents as possible vehicle for Ciclosporin. They were: Peanut oil, Palm oil, Polyoxyethylene castor oil, Medium Chain Length Triglyceride Emulsion (MCT) and Alpha cyclo-dextrin (α -CD). We applied normal saline on the control eye. MCT Emulsion consists of glycine, lecithin, ethylene oxidepropylene oxide and NaCl. The concentration of CYA in each eye drop was: 1% in Peanut oil, Palm and MCT; 0.1% in Polyoxyethylene castor oil and 0.08% in α -CD. These concentrations represented the maximum dose of CYA which the corneas did not opacity. The medications and normal saline were administered 10x (every 30 min.) and 5x a day. The rats were sacrificed with an overdose of anesthesia. After the corneas were harvested, they were examined under the light microscope and their thick-

ness compared.

Based on the results of the previous study, we did further experiments on rabbits. We tested 3 vehicles: MCT (with and without CYA), α -CD and Peanut oil. We omitted Polyoxyethylene castor oil and Palm oil. Normal saline was applied on the control eye. The drugs and normal saline were instilled 10x (every 30 min.). Ultrasonic pachymetry and the Draize test was performed before and after application of the eye drops. CYA concentration in the cornea and aq. humor was measured by radioimmunoassay. Thirty minutes after the last eye drop, the rabbits were sacrificed with an overdose of anesthesia. After harvesting the corneas, one half was examined under the light microscope and the other half with the electron microscope (both scanning and transmission).

With the result of the study we tested 4 solutions of α -CD having different concentrations following the previous procedure. The drugs were administered 4x (every 2 hrs.). The corneas were examined by scanning electron microscopy. Corneal and aq. humor concentration of CYA was also determined by radioimmunoassay.

III. Results

Comparing the thickness of the rat corneas where the eye drops were administered 10x and 5x showed that the corneas with MCT and Peanut oil approximated the thickness of the control cornea (Fig. 1,2). Edema was marked in the corneas where Palm oil and Polyoxyethylene castor oil were administered.

In the rabbit study, Ultrasonic pachymetry readings indicated that α -CD produced the greatest amount of edema compared to the others (Table-1). This was statistically significant ($P < 0.01$). The Draize test which is used to evaluate ocular lesions by assigning relative values to ocular

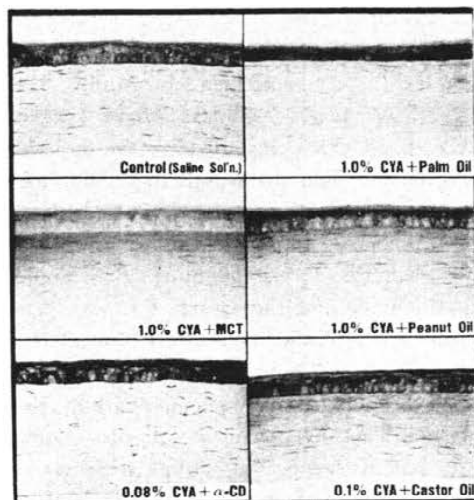


Fig. 1 Light micrograph of rat cornea after administration of various vehicles with Cyclosporin. Frequency of administration was 10× (every 30 min.).

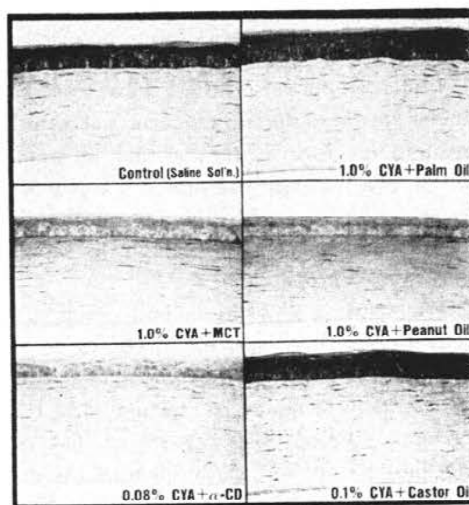


Fig. 2 Light micrograph of rat cornea after administration of various vehicles with Cyclosporin. Frequency of administration was 5×.

Table 1 Pachymetry of rabbit cornea before and after administration of Cyclosporin with various vehicles
Frequency: 10× (every 30 min.)

drug	N	before (mm)	after (mm)	difference (mm)	significance
1% CYA+MCT	3	0.339±0.01	0.334±0.01	-0.01±0.01	SN
0.08% CYA+α-CD	3	0.355±0.03	0.366±0.05	0.01±0.01	p<0.01
1% CYA+peanut oil	3	0.355±0.02	0.348±0.03	-0.01±0.03	NS
Control (saline soln.)	8	0.358±0.02	0.351±0.01	-0.01±0.01	

NS: Not significant

findings demonstrated that α -CD did not cause any irritation and no macroscopic change was noted. In contrast, minimal irritation was evident in the eyes where MCT (with and without CYA) was administered.

We measured the CYA level in the cornea and aq. humor by means of radioimmunoassay (Fig. 3). It revealed that the vehicle with the highest penetrating ability was α -CD and the least was Peanut oil.

The findings on gross examination was further elucidated with light microscopy. When we compared the corneal thickness of

the different samples. MCT approximated the thickness of the control cornea (Fig. 4). With the transmission electron microscope, the findings were unremarkable except for diminution in the number of microvillae on the epithelium associated with α -CD (Fig. 5.) This was corroborated by the findings of the scanning electron microscope (Fig. 6). It showed that compared to the others, the cornea with α -CD had more epithelial craters.

In the last phase of our study we tested 4 different concentrations of α -CD and they were 80, 40, 20 and 10 mg./ml. com-

bined with 0.75, 0.25, 0.09 and 0.03 mg./ml. of CYA respectively. Ultrasonic pachymetry indicated that the difference in the corneal thickness before and after application of the drugs were not statistically

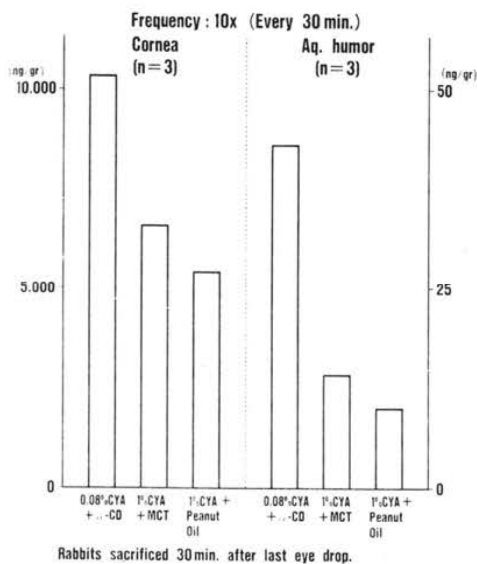


Fig. 3 Pachymetry of rabbit cornea before and after administration of various vehicles with Cyclosporin.

significant. The Draize test revealed that 80 and 40 mg./ml. of α -CD was minimally irritating, 20 mg./ml. was practically non-




Fig. 4 CYA level determination in the cornea and aq. humor after administration of various vehicles with Cyclosporin.

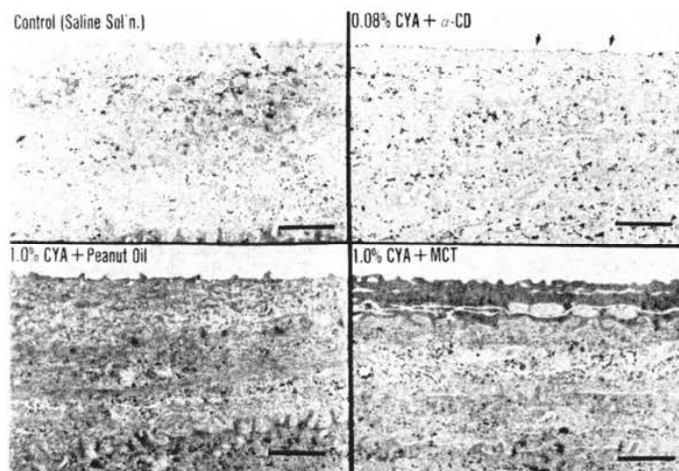


Fig. 5 Light micrograph of rabbit cornea after administration of various vehicles with Cyclosporin. Frequency of administration was 10x (every 30 min.).

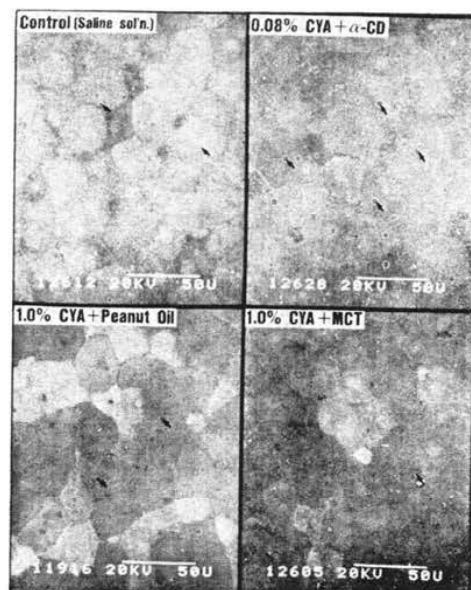


Fig. 6 TEM of rabbit cornea after administration of various vehicles with Cyclosporin. Frequency of administration was $10\times$ (every 30 min.). Samples of 0.08% CYA + α -CD showed diminution in the number of microvilli on the epithelium (arrow).

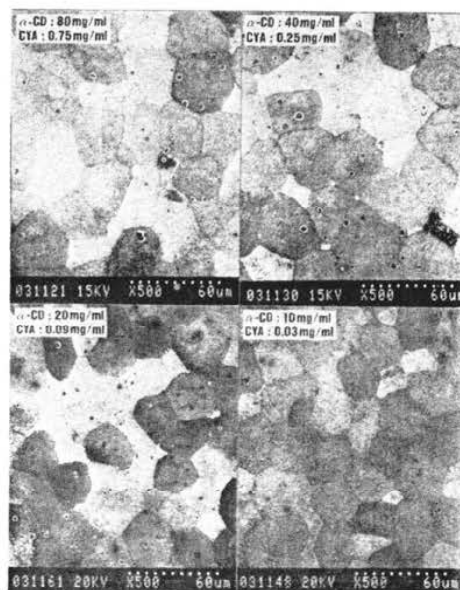

Fig. 7 SEM of rabbit cornea after administration of various vehicles with Cyclosporin. Frequency of administration was $10\times$ (every 30 min.). Sample with 0.08% CYA + α -CD had more epithelial craters (arrow) compared to the others.

irritating and 10 mg./ml. was completely non-irritating. Scanning electron microscopy demonstrated few epithelial erosions associated with 80 and 40 mg./ml. of α -CD (Fig. 7).

We measured the concentration of CYA in the cornea and aq. humor by radioimmunoassay. The sample associated with 80 mg./ml. of α -CD had the highest level and the sample with 10 mg./ml. of α -CD the lowest (Fig. 8). Measuring the CYA level in the aq. humor gave unreliable values and were disregarded. We attributed this to inadequate procedure.

IV. Discussion

Despite the introduction of immunosuppressives 30 years ago, graft rejection has remained a problem in corneal transplantation. The first generation immunosuppressives indiscriminately blocked all cell

divisions thereby negating its beneficial effects. With the advent of newer drugs such as Cyclosporin, the success rate has increased. These new immunosuppressives are capable of selectively affecting certain subpopulation of immunocompetent cells thus preventing rejection from taking place.⁶⁾

The different routes of drug administration have been previously discussed⁷⁾ and the topical route is still the preferred means of instilling the drug in the anterior segment of the eye. Aside from minimizing the occurrence of systemic reactions,^{8,9)} it encourages patient compliance with the drug schedule. Previous studies attest to the efficacy of administering Cyclosporin topically in preventing rejection from taking place.¹⁰⁻¹⁴⁾

The objectives of our investigation are twofold. The first is to search for a suitable

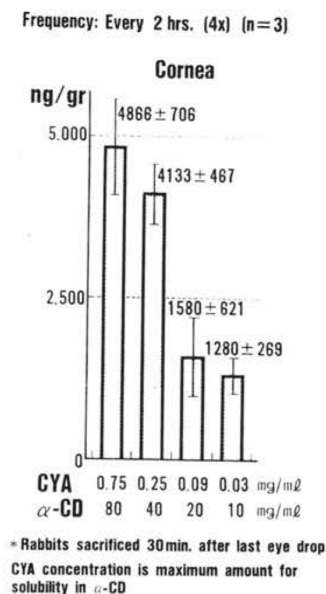


Fig. 8 SEM of rabbit cornea after administration of 4 different concentrations of α -CD. Frequency of administration was 4x (every 2 hrs.).

ble vehicle which when combined with Cyclosporin would cause the least amount of corneal toxicity and the second is to determine whether this new combination would be effective in suppressing the rejection phenomenon. This paper will address the first objective.

A major obstacle in the application of Cyclosporin in ophthalmic preparations is its insolubility in water. We tested several lipophilic vehicles on rat corneas in the initial phase of our study. These vehicles were: Medium Chain Length Triglyceride Emulsion (MCT), Alpha cyclo-dextrin (α -CD), Palm oil, Peanut oil and Polyoxyethylene castor oil. The test drugs were applied at fixed intervals on one eye of rats while normal saline, which served as control, was applied on the contralateral eye. After the corneas were harvested they were examined histologically. The result of the examination indicated that there was signi-

ficant corneal edema associated with Polyoxyethylene castor oil and Palm oil compared to the others. Thus, in the next phase of our study, we limited our test vehicles to three drugs and they were: MCT (with and without CYA), α -CD and Peanut oil. They were instilled on rabbit eyes at regular intervals while normal saline was applied to the control eye. Several procedures were also performed in conjunction with this phase. They were: ultrasonic pachymetry, Draize test, histological examination under light and electron microscopy and radioimmunoassay (RIA). The results showed that compared to the others α -CD caused a great amount of corneal toxicity such as edema, loss of epithelial microvilli and epithelial erosion. The Draize test demonstrated that α -CD was not irritating unlike the others.

We measured the CYA level in the cornea and aq. humor in order to assess the ability of the drug to traverse the cornea in substantial amounts.¹⁵⁻¹⁷ The assay indicated that α -CD had the highest level of concentration and Peanut oil the least.

With these facts in mind, we embarked on the third phase of our investigation and that was to determine the acceptable concentration of α -CD that would give the least amount of corneal toxicity. We evaluated 4 different concentrations of α -CD following the previous procedure and criteria. Evaluation of the results suggests that 20 mg./ml. of α -CD + 0.09 mg./ml. of CYA is the acceptable concentration. In addition, the value we obtained is within the maintenance level of CYA for renal transplant patients (500-1500 ng./gr.).¹⁶

This study, being preliminary in nature, sought to investigate the effects of various vehicles with Cyclosporin on the cornea. It still remains to be resolved whether this new combination would be effective as a topical drug to suppress rejection of corneal grafts.

References

- 1) Foets, B., Missotten, L., Vanderveeren, P. et al.: Prolonged survival of allogenic corneal grafts in rabbits treated with topically applied Cyclosporin A: Systemic absorption and local immunosuppressive effects. *Br. J. Ophthalmol.* 69: 600-613, 1985.
- 2) Salisbury, J.D. & Gebhardt, B.: Suppression of corneal allograft rejection by Cyclosporin A. *Arch. Ophthalmol.* 99: 1640-1643, 1981.
- 3) Mannis, M.J. & May, W.M.: Suppression of the corneal allograft reaction: An experimental comparison of Cyclosporin A and topical steroid. *Cornea* 2: 95-101, 1983.
- 4) Serdaervic, O.N., Goichot-Bonnat, L., Foster, J.O. et al.: The effect of topical Cyclosporin A on corneal reepithelialization. *Cornea* 5: 47-53, 1986.
- 5) Hunter, P.A., Garner, A., Wilhelmus, K.R. et al.: Corneal graft rejection: A new rabbit model and Cyclosporin A. *Br. J. Ophthalmol.* 66: 292-302, 1982.
- 6) Borel, J.F.: The mode of action of immunosuppressive drugs. *Jpn. J. Ophthalmol.* 31: 521-531, 1987.
- 7) Behrens-Baumann, W., Theuring, S., Frey, B. et al.: Cyclosporin concentration in the rabbit aqueous humor and cornea following subconjunctival administration. *Graefes Arch. Clin. Exp. Ophthalmol.* 224: 368-370, 1986.
- 8) Williams, K.A., Grutzmacher, R.D., Roussel, T.J. et al.: A comparison of the effects of topical Cyclosporin and topical steroid on rabbit corneal allograft rejection. *Transplantation* 39: 242-244, 1985.
- 9) Hoffmann, F., Wiederholt, M. & Kossendrup, D.: Der Einfluß von Cyclosporin A, Dexamethason und verschiedene Konservierungsmitteln auf die epitheliale Wundheilung der denervierten Meerschweinchen hornhorst. *Klin. Mbl. Augenheilk* 189: 30-33, 1986.
- 10) Kana, J.S., Hoffmann, F., Buchen, R. et al.: Rabbit corneal allograft survival following topical administration of Cyclosporin A. *Invest. Ophthalmol. Vis Sci* 22: 686-690, 1982.
- 11) Hoffmann, F. & Wiederholt, M.: Topical Cyclosporin A in the treatment of corneal graft reaction *Cornea* 5: 129, 1986.
- 12) Behrens-Baumann, W., Theuring, S. & Brewitt, H.: The effect of topical Cyclosporin A on the rabbit cornea -A clinical and electron microscopic study. *Graefes Arch. Clin. Exp. Ophthalmol.* 224: 520-524, 1986.
- 13) Von Domarus, D., Böhne, M., Meisner, M. et al.: Regeneration artefizieller Hornhautwänden unter Cyclosporin A Augentropfen. *Fortschr. Ophthalmol.* 83: 647-649, 1986.
- 14) Hoffmann, F. & Wiederholt, M.: Lokale Behandlung des Hornhauttransplantates beim Menschen mit Cyclosporin A. *Klin. Mbl. Augenheilk* 187: 92-96, 1985.
- 15) Mosteller, M.W., Gebhardt, B.M., Hamilton, A. et al.: Penetration of topical Cyclosporin into the rabbit cornea, aqueous humor and serum. *Arch. Ophthalmol.* 103: 101-102, 1985.
- 16) Bozkurt, F., Stierle, H. & Schollmeyer, P.: Single dose response kinetics of Cyclosporin. *Clin. Nephrolog* 28: 10-14, 1987.
- 17) Wiederholt, M., Kossendrup, D., Schulz, W. et al.: Pharmacokinetic of topical Cyclosporin A in the rabbit eye. *Invest. Ophthalmol. Vis Sci* 27: 519-523, 1986.