

CELL PROLIFERATION AND FIBER FORMATION IN CHRONIC CARBON TETRACHLORIDE INTOXICATION

A MORPHOLOGIC AND CHEMICAL STUDY

EMANUEL RUBIN, M.D.; FERENC HUTTERER, M.D.; AND HANS POPPER, M.D.

*From the Departments of Pathology, The Mount Sinai Hospital,
and Columbia University College of Physicians and Surgeons,
New York, N.Y.*

Conventional microscopic and fine structural investigations have indicated 3 modes of fiber formation in the liver—perihepatocellular, periductular and portal.¹ The first 2 account for most of the fibrosis in human and experimental cirrhosis. This raises the problem of the relationship of hepatocytes and ductular cells to fibrogenesis. Previous studies of subacute ethionine intoxication in the rat demonstrated the fibrogenesis in that model to be mainly ductular; a parallelism was demonstrated between DNA, as an approximate index of the number of cells, and hydroxyproline, as a measure of collagen, during both the formation and disappearance of fibers.² Electron microscopic investigations have indicated that all tubular structures in the experimental models investigated and the human examples examined were ductules with basement membranes and thus distinct from hepatocytes.^{3,4} Transitional forms were not seen. Since a similar parallelism was reported during fiber disappearance in cirrhosis produced by carbon tetrachloride,⁵ in which perihepatocellular fibrogenesis was claimed,⁶ the stages of carbon tetrachloride induced fibrogenesis were investigated by correlated histologic, autoradiographic and chemical techniques. The problems posed were: (a) the rate of proliferation of hepatocytes and ductular cells in different stages of the intoxication; (b) the relation between the number of cells, reflected in total hepatic DNA content, and the amount of collagen, measured as total hepatic content of hydroxyproline, an amino acid in the liver occurring only in collagen (this was evaluated in consecutive stages, with particular reference to differences between the precirrhotic and cirrhotic stages); and (c) the association between the proliferation of both types of cells and fiber formation.

Supported by Research Grant A-3846 Path. from the National Institute of Arthritis and Metabolic Diseases, National Institutes of Health, United States Public Health Service, and the U.S. Army Medical Research and Development Command under Contract DA-49-007-MD-790.

Accepted for publication, November 27, 1962.

MATERIAL AND METHODS

Forty female Sprague-Dawley rats, with an average weight of 150 gm., were divided into 10 groups of 4 rats each. These were given 0.15 ml. carbon tetrachloride in mineral oil subcutaneously twice weekly. One untreated rat was added to each group as a control. The animals were fed Rockland Farms rat diet. The first 5 groups were killed at 10-day intervals. Subsequent groups were killed at 65, 80, 95, 115 and 135 days. Two hours before sacrifice, each animal received tritiated thymidine, 0.5 μ c. per gm. of body weight, intraperitoneally.

Histologic Evaluation. The livers were weighed and slices fixed in 10 per cent neutral buffered formalin. Paraffin sections were stained with hematoxylin and eosin and chromotrope aniline blue⁷ for connective tissue, and by the Gomori silver impregnation for the demonstration of reticulin fibers.

Autoradiography. Paraffin sections, 4 μ thick, were coated with Kodak NTB-3 nuclear track emulsion, and exposed for 1 month at 4° C. The preparations were developed in Kodak D-19 developing solution and then stained with Harris' hematoxylin. For counting labeled cells, a reticle delimiting a circular field was placed in the eyepiece of the microscope, and cells falling within the circle in random fields were counted. The percentages of labeled cells accounted for by hepatocytes and other hepatic cells were based upon counts of 300 labeled cells in each section.

Chemical Analysis. A 10 per cent homogenate of the liver was prepared in 0.9 per cent KCl. Aliquots of the homogenate were analyzed for DNA, RNA, hydroxyproline and protein by methods described previously.² Chemical data were expressed as mg. per total liver per 100 gm. body weight.

Measurement of Total Uptake of Thymidine- H^3 . The homogenate was treated with cold trichloroacetic acid (TCA), and then with alcohol and ether-alcohol, to eliminate cold acid-soluble materials and lipids, according to the method of Schneider.⁸ DNA was extracted with hot TCA. An aliquot of the TCA extract was analyzed for DNA, and another aliquot was dissolved in a solution containing 1,000 ml. dioxane, 100 ml. absolute ethyl alcohol, 100 ml. toluene, 0.5 gm. dimethyl POPOP [1,4-bis-2-(4-methyl-5-phenyloxazolyl) benzene] and 7 gm. PPO (2,5-diphenyloxazole). Counting was accomplished with a liquid scintillation counter in which internal standards for quenching correction were used. The results were expressed as counts per minute per mg. DNA.

RESULTS

Morphologic Examination

The evolution from acute necrosis to diffuse septal cirrhosis previously described⁹ was divided into 4 stages for the correlation of the various parameters studied.

Control Livers. Autoradiographs showed very few labeled hepatocytes, occasional labeled mesenchymal cells and rare labeled cells of bile duct epithelium.

Necrosis. After 10 days of treatment, centrilobular necrosis and hydropic degeneration of hepatocytes had developed, with accumulation of mesenchymal cells and moderate central and midzonal steatosis. Reticulin and aniline blue stained fibers were increased in the necrotic central zones (Fig. 1). Many labeled hepatocytes were evident (Fig. 2). Labeling of mesenchymal cells had also increased, but not as much as had

that of hepatocytes. Cells of bile duct origin showed more labeling than in the control. Hepatocytes accounted for 41 per cent of all labeled cells, while the great majority of other labeled elements were mesenchymal cells.

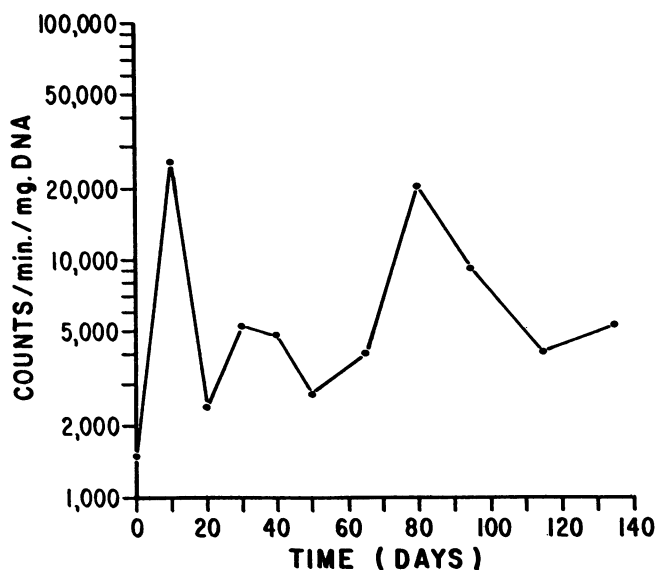
Nonseptal Fibrosis. From 20 to 65 days, connective tissue increased progressively, with fibers radiating from central zones and, to a lesser degree, from portal tracts (Fig. 3). Septums were not found. Necrosis was less conspicuous, and the centrilobular accumulation of mesenchymal cells had decreased. Small bile ducts had proliferated around portal tracts (Fig. 4). Fat was increased and appeared partly as fatty cysts. The number of labeled hepatocytes was greatly decreased. Hepatocytes comprised from 3 to 10 per cent of all labeled cells. This low level of thymidine uptake prevailed until the 65th day. Uptake by mesenchymal cells also decreased, but the number of labeled ductular cells remained about the same.

Septal Fibrosis. At 80 to 95 days connective tissue increased rapidly and progressively, with the formation of septums connecting portal tracts and central canals. Fibers surrounded and extended along strikingly proliferated ductules. The developing septums were conspicuously infiltrated by mononuclear mesenchymal cells. A burst of thymidine labeling was noted at the 80th day. The majority of labeled elements which were not hepatocytes were bile ductular cells within connective tissue septums (Figs. 5 and 6), in some areas constituting as many as 30 per cent of the ductular cells. Many ductular cells were distinguished from mesenchymal elements by a tubular arrangement and a silver impregnated basement membrane. Other ductular cells were identified by their cytologic features. These cell aggregates were morphologically identical with structures which have been shown to be ductules by electron microscopy, primarily by the demonstration of a surrounding basement membrane. At the same time labeled hepatocytes within early nodules were strikingly increased, representing about $\frac{1}{3}$ of all labeled cells. Within the septums, labeled mesenchymal cells were also increased.

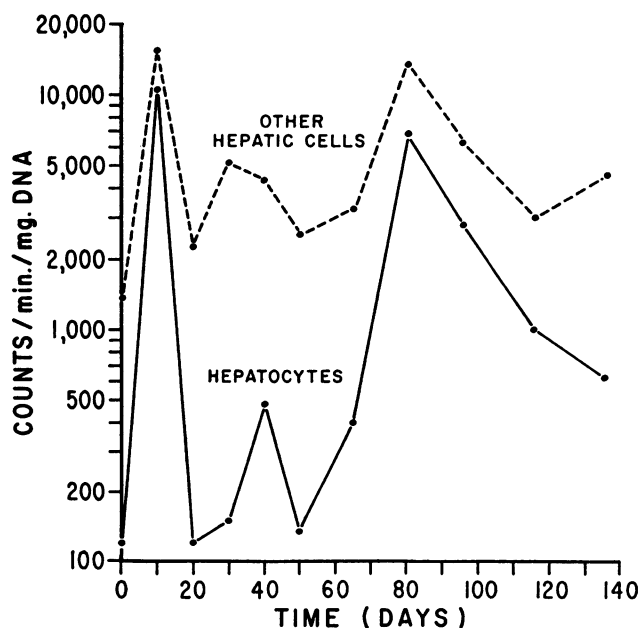
Cirrhosis. After 95 days the septums had increased in thickness and were joined to surround nodules (Fig. 7) in which the hepatocytes showed active regeneration. The latter was characterized by plates 2 cells in thickness and compression of liver cell plates by hyperplasia of adjacent cells. Fat decreased during this period. By 135 days all livers exhibited well-developed septal cirrhosis. The number of labeled cells of all types decreased progressively after 95 days, so that when septal cirrhosis was established at 135 days, few labeled hepatocytes, ductular or mesenchymal cells were present (Fig. 8)—a situation similar to that at 20 to 65 days. Hepatocytes fell to $\frac{1}{10}$ of all labeled cells.

Total Uptake of Thymidine- H^3

The specific activity of hepatic DNA was greatly increased at 10 days in comparison to a low control value (Text-fig. 1). It fell rapidly, so



TEXT-FIG. 1. Total hepatic thymidine uptake in carbon tetrachloride treated rats.

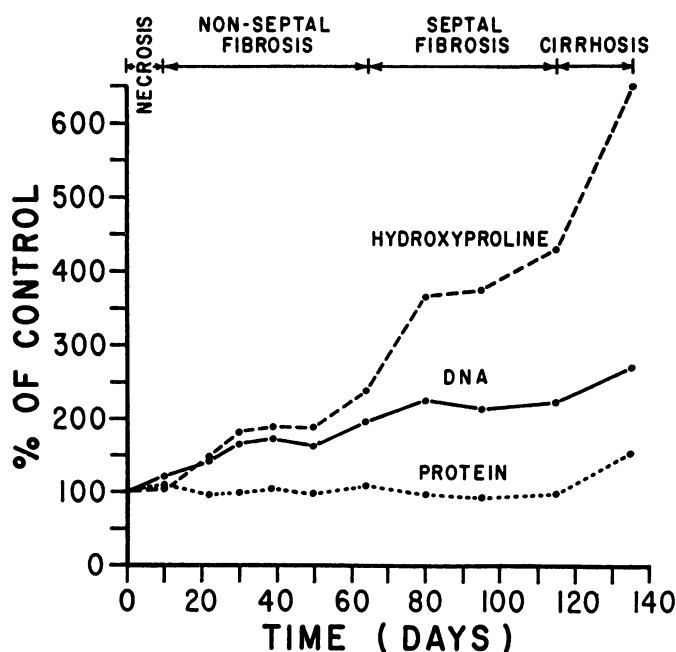


TEXT-FIG. 2. Total thymidine uptake calculated by individual cell types in carbon tetrachloride treated rats.

that at 20 days the activity was only moderately greater than in the control. Subsequently the level fluctuated only slightly until at the 80th day it suddenly increased to nearly that found at 10 days. The uptake rapidly decreased thereafter, and at 115 and 135 days had fallen to almost the same level as at the 20 to 65 day period.

Correlation of Autoradiography and Total Thymidine- H^3 Uptake

To determine the relative contributions of hepatocytes and other cell types to the total uptake of thymidine- H^3 , the percentages of labeled hepatocytes and of other labeled cells were multiplied by the figures for total uptake (Text-fig. 2). Proliferation of one cell type appeared paral-



TEXT-FIG. 3. Hepatic hydroxyproline, DNA and protein content in carbon tetrachloride treated rats.

lel to that of the other. The two peaks of DNA synthesis by hepatocytes occurred during the stage of necrosis and at the onset of septal fibrogenesis and nodule formation. However, the first peak in nonhepatocytes principally reflected DNA synthesis in mesenchymal cells, while DNA synthesis in ductular cells contributed a large part of the second peak.

Chemical Analysis

The body weight of the growing control and treated animals increased progressively during the experiment from an initial average weight of 150 gm. to an average of 250 gm. The ratio of liver weight to body weight

of the control animals was 3.25. After an initial rise to 4.44 at 10 days, the ratio remained fairly stable. The livers in control animals exhibited the following: total protein, 461 ± 39 mg.; DNA, 9.0 ± 0.7 mg.; RNA, 35.7 ± 2.8 mg.; and hydroxyproline, 0.54 ± 0.04 mg. The protein content of the liver remained stable except for a slight increase in the 135 day group (Text-fig. 3). The DNA content increased progressively to about $2\frac{1}{2}$ times the control. The hydroxyproline content was unchanged at 10 days and then rose approximately parallel to the DNA content until the 65th day, the hydroxyproline/DNA ratio remaining about the same (Table I). From that point on the hydroxyproline content rose

TABLE I
CARBON TETRACHLORIDE TREATED RATS
HYDROXYPROLINE/DNA AND RNA/DNA RATIOS IN THE LIVER

Days	Hydroxyproline/DNA	RNA/DNA
0	0.060	3.96
10	0.049	3.04
20	0.061	2.78
30	0.066	2.31
40	0.065	2.51
50	0.069	2.65
65	0.070	2.85
80	0.094	2.49
95	0.105	2.51
115	0.115	2.10
135	0.140	2.26

steeply to over 6 times the initial value. The hydroxyproline/DNA ratio at this time had increased to double the value at 65 days. The RNA/DNA ratio decreased during the experiment, the final value being a little more than half the control (Table I).

DISCUSSION

For the study of the relation between fibers and cells in hepatic fibrosis and cirrhosis, the evolution of the carbon tetrachloride intoxication was divided into stages of necrosis, of nonseptal fiber formation, of septal fiber formation, and of cirrhosis; conventional criteria were applied.¹⁰ Both morphologic and biochemical data exhibited both continuous evolution and discontinuous events.

The initial centrilobular necrosis was associated with central accumulation of fibers. However, the hydroxyproline content, as a measure of collagen in the entire liver, did not increase at this time, and therefore little, if any, new formation of fibers occurred. The central aggregation

of fibers at this stage was thus the result of simple collapse of pre-existing fibers following centrilobular necrosis, as postulated by Cameron and Karunaratne,⁹ rather than the result of fiber formation, as claimed by others.⁶

At this time a peak of regeneration occurred with both hepatocytes and other cells participating; the latter were, in the main, mesenchymal cells. While the regeneration of the hepatocytes was an expected compensatory response to liver cell loss, and therefore comparable to that in partial hepatectomy,¹¹ the increased labeling of mesenchymal cells, predominantly of the reticuloendothelial variety, contrasted with the delayed regeneration of these cells observed after partial hepatectomy.¹² A basic difference was thus indicated between the reaction to simple loss of cells, exemplified by hepatectomy, and to necrosis of cells, as in toxic injury. Hepatectomy stimulated replacement; toxic necrosis was characterized by an inflammation or "reactive hepatitis." The reactive mesenchymal stimulation in CCl_4 intoxication is a feature of the entire reticuloendothelial system.¹³ Later mesenchymal cell proliferation paralleled the regeneration of hepatocytes. German authors have attempted to distinguish pure hepatocellular injury, which they termed "hepatosis," from an inflammatory hepatitis.¹⁴ It would appear that this distinction is not necessarily valid, in that toxic hepatocellular injury is in effect a hepatitis. This explains the well known difficulty in differentiating between toxic "hepatosis" and viral hepatitis in liver biopsy specimens.¹⁵

After 10 days the regeneration of hepatocytes became inactive, as reflected in a fall in total thymidine uptake. This occurred despite the continued administration of carbon tetrachloride. During this period fibers increased diffusely especially about portal tracts. This constituted new formation of fibers, in contrast to the early central fiber aggregation as indicated by an increase in total hepatic hydroxyproline content. In the immediate precirrhotic period, the pattern of DNA synthesis changed; proliferating ductular cells surpassed mesenchymal cells in thymidine uptake. The decrease in the RNA/DNA ratio reflected proliferation of cells with a smaller ratio of cytoplasm to nucleus, in this case ductular and mesenchymal cells,¹⁶ although decreased RNA content of hepatocytes might have been a contributory factor. The ductular proliferation was associated with the formation of septums and nodules.

During the period of septal fibrogenesis, the rapid rise in total thymidine- H^3 uptake was accounted for not only by proliferating ductules but by increased proliferation of hepatocytes in nodules. Thus the nodule was not only the result of passive division of parenchyma by active septum formation but also reflected hepatocellular activity.¹⁷

The decrease in thymidine- H^3 uptake by hepatocytes in well-established nodules contrasted with the persistence of histologic indications of regeneration, reflected by plates 2 cells thick.¹⁸ Low levels of thymidine- H^3 uptake and few mitotic figures in well-developed nodules have been noted in other experimental models.^{19,20} The paradox of nodular regeneration and reduced proliferation of hepatocytes is thus far not resolved. One explanation might be a longer life span of hepatocytes in the nodules of fully developed cirrhosis. The proliferation rate of ductular cells was also decreased after cirrhosis was well established. In a manner thus far not understood, ductular cell and hepatocellular proliferation paralleled each other in the precirrhotic and cirrhotic phases, possibly indicating a relationship of liver cell injury to ductular proliferation. The discontinuous events described were not reflected morphologically, nor were they mirrored in the chemically determined amount of DNA, a measure of cells, which rose continuously during carbon tetrachloride intoxication. The rate of regeneration was thus not necessarily manifested morphologically or chemically.

In the necrotic and nonseptal fibrotic stages, DNA and hydroxyproline content rose in parallel manner, their ratio remaining constant. This was in keeping with the observations at various stages of subacute ethionine intoxication, during both fiber formation and fiber removal; it has been noted after administration of alpha-naphthyl-isothiocyanate, choline-deficient diet and bile duct ligation.² The constant relationship of DNA to hydroxyproline in these models has been taken to indicate the dependence of fibrogenesis upon the cellular framework. A similar parallelism between cells and fibers has been observed in uterine fibrogenesis during pregnancy and during rapid postpartum collagen removal.²¹ Comparisons between normal and hypertrophic heart muscle have also indicated a constant relation of cells to fibers.²² However, during the stages of septal fibrogenesis and subsequent cirrhosis in carbon tetrachloride intoxication, the hydroxyproline content rose much more steeply than did that of DNA. This indicated either a more rapid production of collagen by individual cells or greater persistence of fibers in the septums. That the turnover rate of collagen can be altered *in vivo* has been demonstrated in recovery from acute ethionine intoxication.²³ This is in keeping with the observation that the uptake of glycine- C^{14} in the liver during carbon tetrachloride intoxication was considerably lower in the later than during the early phase.²⁴ Septal fibrosis and cirrhosis are less reversible than diffuse fibrosis. The variation of the hydroxyproline/DNA ratio, therefore, might be related to reversibility of the cirrhosis, high ratios indicating irreversibility.

The data suggest that the rapid proliferation of bile ductules and

accompanying mesenchymal cells, which constitutes the ductular cell reaction,²⁵ was related to the formation of fibrous septums. Fiber formation about proliferating hepatocytes was not seen, and during the period of maximal hepatocyte proliferation the hydroxyproline content was not increased. Thus in chronic carbon tetrachloride intoxication fibrogenesis was predominantly periductular, initially nonseptal and eventually septal. The possibility exists that hepatic fibrosis preceding human cirrhosis might also more frequently be periductular than has been assumed from histologic studies.

SUMMARY

The relation of cells and fibers during hepatic fibrogenesis following chronic carbon tetrachloride intoxication was investigated in rats. Tritiated thymidine was administered before sacrifice, and the histologic changes in the liver were correlated with hepatic content of DNA, RNA, hydroxyproline, total thymidine uptake and with autoradiographs of the liver.

During the period of initial necrosis the new formation of hepatocytes was conspicuously accelerated, and was associated with a striking proliferation of mesenchymal cells, indicating the importance of the mesenchymal reaction in acute hepatic necrosis.

In the precirrhotic stage, ductular cell proliferation and the development of septums coincided with the rapid formation of new hepatocytes in nodules. In the well-developed nodules of established cirrhosis the thymidine-H³ uptake by hepatocytes diminished despite histologic evidence of regeneration, the expansion of nodules and a progressive rise in DNA content.

During nonseptal fibrogenesis, the number of cells measured as DNA, and collagen measured as hydroxyproline, increased in parallel manner. During septal fibrogenesis, however, collagen increased out of proportion to the number of cells, the hydroxyproline/DNA ratio being doubled. Increased hydroxyproline/DNA ratios might reflect irreversibility of cirrhosis. The fibrogenesis in carbon tetrachloride induced cirrhosis was predominantly periductular, indicating the importance of this mode of fiber formation.

REFERENCES

1. POPPER, H.; PARONETTO, F.; SCHAFFNER, F., and PEREZ, V. Studies on hepatic fibrosis. *Lab. Invest.*, 1961, 10, 265-290.
2. HUTTERER, F.; RUBIN, E.; SINGER, E. J., and POPPER, H. Quantitative relation of cell proliferation and fibrogenesis in the liver. *Cancer Res.*, 1961, 21, 205-215.
3. SCHAFFNER, F., and POPPER, H. Electron microscopic studies of normal and proliferated bile ductules. *Am. J. Path.*, 1961, 38, 393-410.

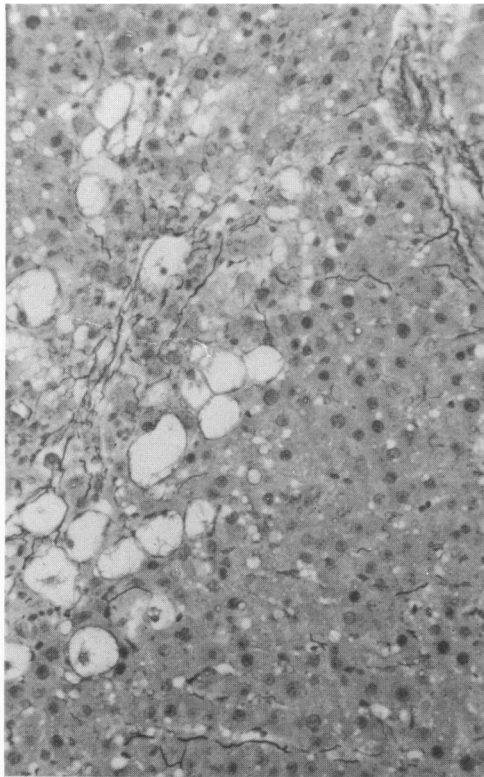
4. GRISHAM, J. W., and HARTROFT, W. S. Morphologic identification by electron microscopy of "oval" cells in experimental hepatic degeneration. *Lab. Invest.*, 1961, 10, 317-332.
5. RABINOVICI, N., and WIENER, E. Collagen and deoxyribonucleic acid concentrations during regeneration in the hepatectomized cirrhotic liver. *Gastroenterology*, 1961, 41, 251-257.
6. ATERMAN, K. Studies in fibrosis of the liver induced by carbon tetrachloride. I. Relation between hepatocellular injury and new formation of fibrous tissue. *Arch. Path.*, 1954, 57, 1-11.
7. CHURG, J., and PRADO, A. A rapid Mallory trichrome stain (chromotrope-aniline blue). *Arch. Path.*, 1956, 62, 505-506.
8. SCHNEIDER, W. C. Phosphorus compounds in animal tissues. I. Extraction and estimation of desoxypentose nucleic acid and of pentose nucleic acid. *J. Biol. Chem.*, 1945, 161, 293-303.
9. CAMERON, G. R., and KARUNARATNE, W. A. E. Carbon tetrachloride cirrhosis in relation to liver regeneration. *J. Path. & Bact.*, 1936, 42, 1-21.
10. POPPER, H., and ZAK, F. G. Pathologic aspects of cirrhosis. *Am. J. Med.*, 1958, 24, 593-619.
11. WEINBREN, K. Regeneration of the liver. *Gastroenterology*, 1959, 37, 657-668.
12. GRISHAM, J. W. A morphologic study of deoxyribonucleic acid synthesis and cell proliferation in regenerating rat liver; autoradiography with thymidine- H^3 . *Cancer Res.*, 1962, 22, 842-849.
13. WIRTSCHAFTER, Z. T., and DEMERITT, M. G. Reticuloendothelial response to carbon tetrachloride. *Arch. Path.*, 1959, 67, 146-158.
14. RÖSSLE, R. Entzündungen der Leber. In: Handbuch der speziellen pathologischen Anatomie und Histologie. Vol. 5, Part 1, Verdauungsdrüsen. HENKE, F., and LUBARSCH, O. (eds.). J. Springer, Berlin, 1930, pp. 243-505.
15. POPPER, H. Pathological findings in jaundice associated with iproniazid therapy. *J.A.M.A.*, 1958, 168, 2235-2242.
16. RUBIN, E.; HUTTERER, F.; GALL, E. C., and POPPER, H. Nature of increased protein and DNA in chronic hepatic injury. *Nature, London*, 1961, 192, 886-887.
17. GOLDFARB, S., and POPPER, H. Morphogenesis of experimental cirrhosis. (Abstract) *Fed. Proc.*, 1962, 21, 303.
18. POPPER, H., and ELIAS, H. Histogenesis of hepatic cirrhosis studied by the three-dimensional approach. *Am. J. Path.*, 1955, 31, 405-441.
19. MACDONALD, R. A. Experimental carcinoma of the liver. "Regeneration" of liver cells in premalignant stages. *Am. J. Path.*, 1961, 39, 209-220.
20. DAOUST, R. The mitotic activity in rat liver during DAB carcinogenesis. *Cancer Res.*, 1962, 22, 743-747.
21. MONTFORT, I., and PÉREZ-TAMAYO, R. Studies on uterine collagen during pregnancy and puerperium. *Lab. Invest.*, 1961, 10, 1240-1258.
22. MONTFORT, I., and PÉREZ-TAMAYO, R. The muscle-collagen ratio in normal and hypertrophic human hearts. *Lab. Invest.*, 1962, 11, 463-470.
23. HUTTERER, F.; RUBIN, E., and POPPER, H. Turnover of hepatic cells and fibers during the development of and recovery from hepatic fibrosis. (Abstract) *Fed. Proc.*, 1962, 21, 303.
24. HIRAYAMA, C. Biochemical aspects of hepatic fibrosis. *Japanese J. Gastroenterol.*, Proceedings of the 47th Annual Meeting, 1961, Part 1, p. 130.
25. POPPER, H.; KENT, G., and STEIN, R. Ductular cell reaction in the liver in hepatic injury. *J. Mt. Sinai Hosp.*, 1957, 24, 551-556.

[*Illustrations follow*]

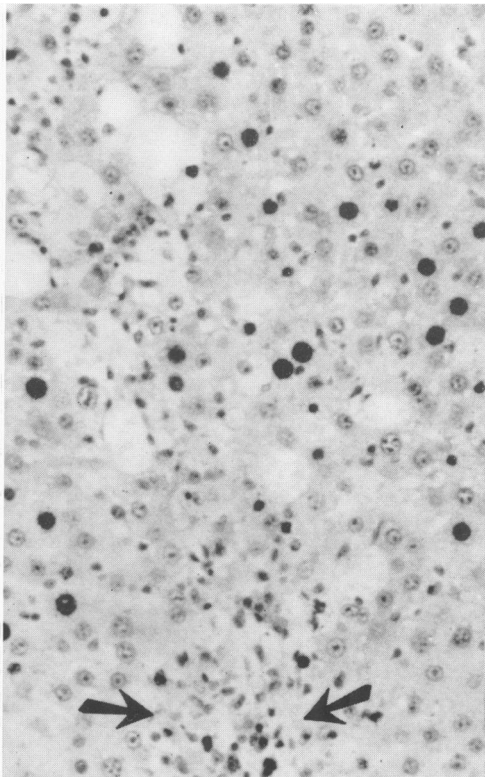
LEGENDS FOR FIGURES

- FIG. 1. Rat liver, carbon tetrachloride administered for 10 days. Fibers are aggregated in the centrilobular zone. Gomori silver stain. $\times 150$.
- FIG. 2. Rat liver, carbon tetrachloride administered for 10 days. An autoradiograph exhibits labeled hepatocytes and numerous labeled mesenchymal cells in the centrilobular zone (arrows). Hematoxylin stain. $\times 150$.
- FIG. 3. Rat liver, carbon tetrachloride administered for 50 days. Increased numbers of fibers do not form septums. Gomori silver stain. $\times 150$.
- FIG. 4. Proliferated ductules (arrows) and mesenchymal cells appear in the liver of a rat treated with carbon tetrachloride for 65 days. Hematoxylin and eosin stain. $\times 450$. *Insert:* In the same specimen basement membranes are evident about ductules. Gomori silver stain. $\times 240$.

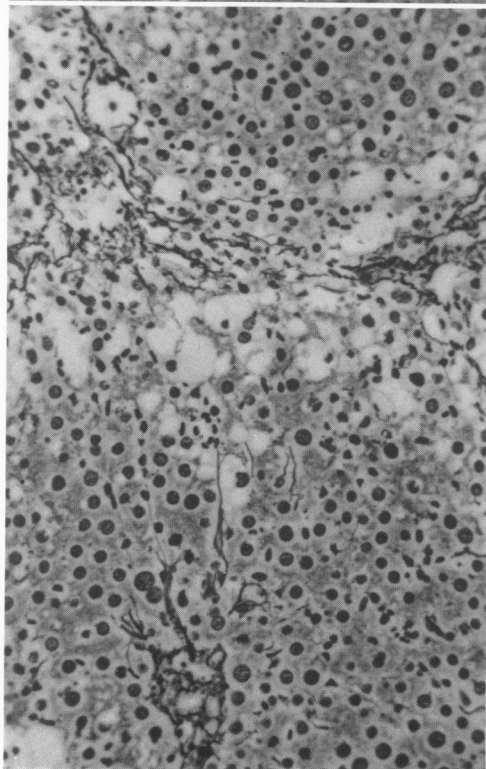
1



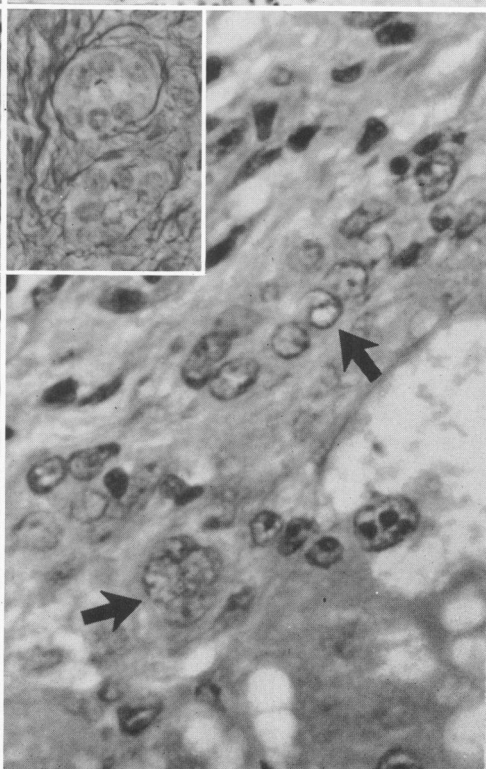
2



3



4



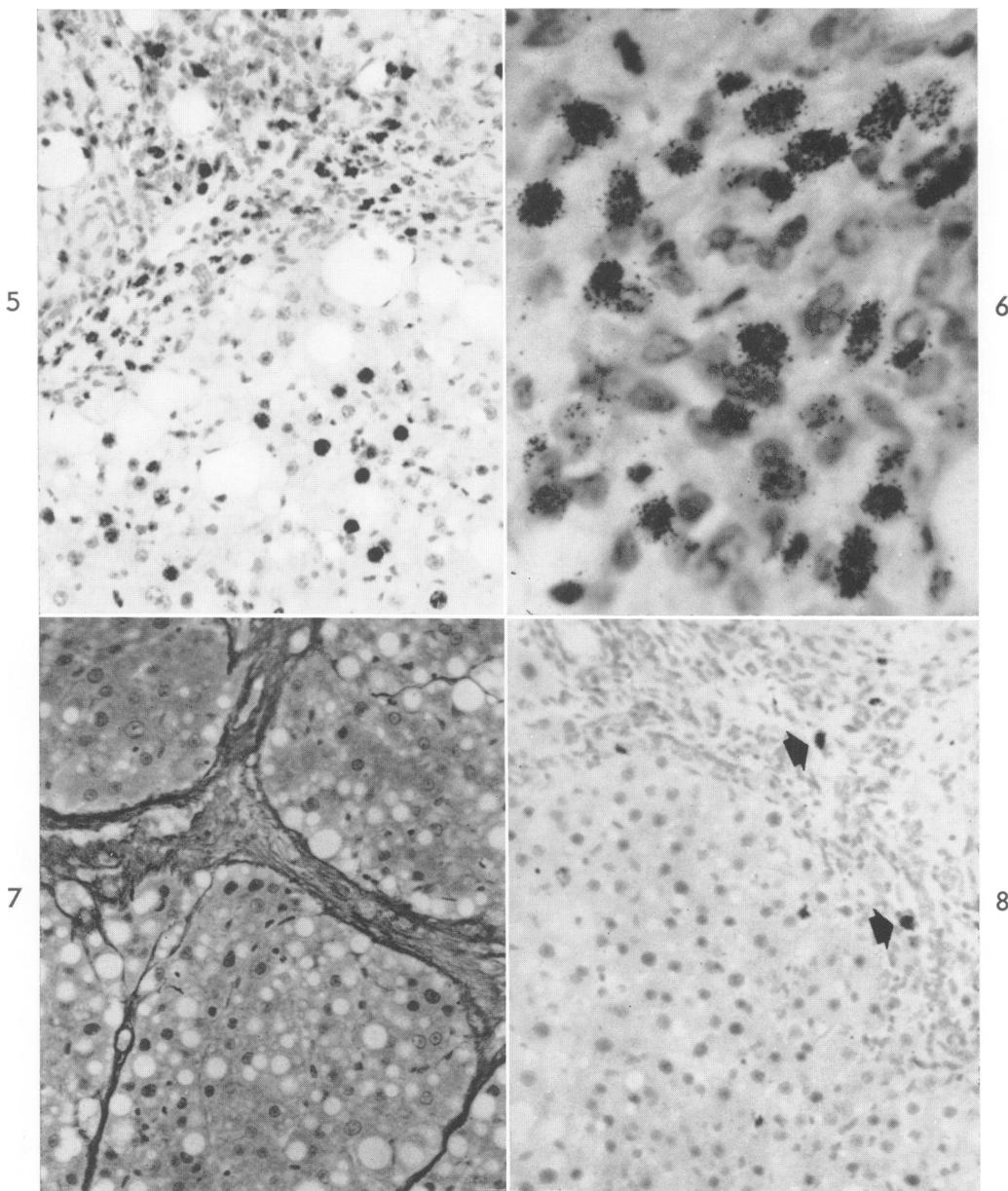


FIG. 5. Rat liver, carbon tetrachloride administered for 80 days. An autoradiograph exhibits striking labeling of ductular cells (identified as such in silver-stained preparations) in a septum. There are also many labeled hepatocytes in a developing nodule. Hematoxylin stain. $\times 150$.

FIG. 6. A higher power view of the area shown in Figure 5. Many labeled ductular cells are evident. $\times 450$.

FIG. 7. Rat liver, carbon tetrachloride administered for 135 days. There is well-developed cirrhosis. Gomori silver stain. $\times 150$.

FIG. 8. Rat liver, carbon tetrachloride administered for 135 days. An autoradiograph reveals no labeled hepatocytes in the nodule. Two labeled mesenchymal cells (arrows) are shown. Hematoxylin stain. $\times 150$.