

# Myocardial ischemia without atherosclerosis

Jan L. Houghton, MD   Thomas W. von Dohlen, MD   Martin J. Frank, MD

## Preview

**Myocardial ischemia is most commonly caused by atherosclerotic disease, but it can also occur in patients with normal epicardial coronary arteries. What are the possible causes of ischemia in such patients? How is it assessed? What therapies are recommended? The authors of this article present guidelines for workup and management of myocardial ischemia in the absence of atherosclerosis.**

Coronary blood flow, with or without epicardial stenosis, can be described by the concept of supply and demand. Myocardial ischemia occurs if the coronary blood supply to heart muscle is inadequate for the demand. In the United States, the most common cause of imbalance between supply of and demand for coronary blood flow is coronary atherosclerosis. However, myocardial ischemia can exist in the setting of normal epicardial coronary arteries. This article describes the less common, non-atherosclerotic causes of myocardial ischemia.

## Historical perspective

Myocardial ischemia with normal epicardial coronary arteries has been recognized as a clinical entity for several decades. Two diseases, in particular—syndrome X and severe aortic stenosis—stimulated most initial interest and work in this area.

In 1967, Likoff and associates<sup>1</sup> described typical anginal chest

pain in 15 female patients whose coronary arteriograms were normal but whose electrocardiograms showed ST-T wave abnormalities at baseline and an ischemic response to exercise. All of the patients were normotensive, and most were not diabetic. The investigators postulated an idiopathic abnormality in the microcirculation or myocardial cell (ie, syndrome X) as the cause. Since this study, other investigators<sup>2</sup> have established that an inadequate coronary vasodilator reserve due to an abnormality in the coronary microcirculation is responsible for myocardial ischemia in such patients.

Typical angina pectoris has been recognized for many years in patients with severe aortic stenosis but normal epicardial coronary arteries. Marcus and associates<sup>3</sup> demonstrated, with use of an intraoperative Doppler probe, a marked decrease in coronary flow reserve in vessels supplying the hypertrophied left ventricle (via the left anterior

descending coronary artery) in patients with severe aortic stenosis. In contrast, coronary flow reserve in the right coronary artery branches supplying the nonhypertrophied right ventricle was normal. These findings demonstrated the limiting effect of left ventricular hypertrophy on coronary flow reserve in these patients, thus elucidating the mechanism responsible for development of angina.

## Two units of coronary circulation

The coronary arterial circulation can be viewed as the composite of a macrocirculatory unit and a microcirculatory unit. The macrocirculation, which can be visualized by coronary angiography, is composed of epicardial coronary arteries and smaller branches as narrow as 500  $\mu\text{m}$  in diameter. The macrocirculation is usually the focus of cardiac investigation because of the high prevalence of coronary atherosclerosis in Western societies. Coronary artery spasm is also an important cause of macrocirculatory angina and should be excluded by provocative testing before microcirculatory angina is considered.

Only recently have technological advances allowed evaluation of the coronary microcirculation in humans, and thus little is


FIBROGEN EXHIBIT 2006 *continued*

GSK v. FibroGen

IPR2016-01315



**With digital angiographic techniques, coronary flow reserve can be estimated by the transit time of contrast material before and after a hyperemic stimulus.**



**Jan L. Houghton, MD**  
**Thomas W. von Dohlen, MD**  
**Martin J. Frank, MD**

Dr Houghton (center) is assistant professor of medicine, section of cardiology, and codirector of the cardiac catheterization laboratory, Medical College of Georgia, Augusta.

Dr von Dohlen (left) is assistant professor of medicine, section of cardiology, and director of the coronary care unit, Medical College of Georgia.

Dr Frank (right) is professor of medicine and chief, section of cardiology, Medical College of Georgia.

known (although much is suspected) about its role in ischemia. The arterial microcirculation comprises intramural small coronary arteries, arterioles, and capillaries. Because of their function as resistance vessels, the coronary arterioles and prearterioles<sup>4</sup> are now generally believed to be responsible for abnormal vasomotor responses after hyperemic stimuli in some patients with microcirculatory angina.

#### **Alternative methods of evaluating ischemia**

Establishing the presence of myocardial ischemia in the absence of coronary atherosclerosis has necessitated the development of new methods of evaluating imbalance between coronary blood supply and demand.

Traditional methods include qualitative and quantitative assessment of stenosis by coronary angiography, assessment of ischemic electrocardiographic

changes during exercise stress testing, and assessment of myocardial perfusion abnormalities during stress testing with a thallium scan. Some of these methods may demonstrate true ischemia in the setting of normal epicardial coronary arteries due to a supply-and-demand imbalance. However, study results have usually been mislabeled clinically as false-positive because of the emphasis on identifying coronary atherosclerosis rather than myocardial ischemia.

An alternative method of assessing myocardial ischemia is to measure a metabolic product that increases in coronary venous blood as a result of coronary insufficiency. Generally, coronary sinus lactate has been measured in the coronary venous effluent to detect ischemia.<sup>5</sup> Coronary sinus blood flow also can be measured in the basal state and again after a maximal vasodilatory stimulus to obtain an estimate of flow reserve (ie, the ratio of maximal coronary flow to basal coronary flow). In humans, such measurement techniques have yielded only approximate results because of variations in the amount of coronary venous drainage through the coronary sinus and problems with stable placement of the coronary sinus catheter. However, use of thermodilution principles and positioning of the catheter near the origin of the

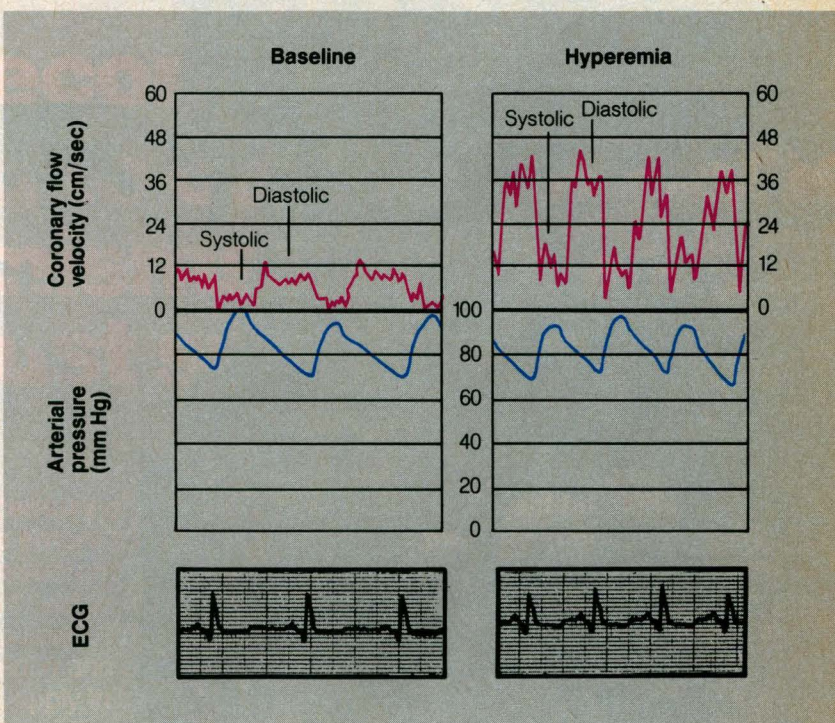


## Coronary vasodilator reserve can be accurately measured with use of an intracoronary Doppler catheter.

great cardiac vein will yield a reasonable approximation of left anterior descending flow.<sup>6</sup> A similar but older method uses gas-clearance techniques to estimate coronary blood flow from serial coronary sinus and arterial gas measurements and the Kety formula (an equation named after the originator of this technique).<sup>6</sup>

Recently perfected digital angiographic techniques are another possible method of evaluating coronary flow reserve,<sup>6</sup> provided that the cardiac catheterization laboratory is equipped with digital subtraction technology. Flow reserve is estimated according to transit time of contrast material before and after a hyperemic stimulus.

Finally, Doppler techniques can directly measure flow velocity in a target coronary artery at baseline and after a hyperemic stimulus by means of a tiny intracoronary Doppler catheter that does not impede coronary flow.<sup>6</sup> Hyperemic flow can be produced in humans in the cardiac catheterization laboratory by atrial pacing, intravenous dipyridamole, or intracoronary papaverine.<sup>7</sup> Coronary vasodilator reserve in the target artery is then calculated as the ratio of peak hyperemic flow velocity to basal flow velocity. In our laboratory, use of intravenous dipyridamole and the Doppler catheter



**Figure 1.** Coronary study performed with Doppler catheter and intravenous dipyridamole in patient with normal coronary vasodilator reserve. Basal and hyperemic coronary flow velocities are shown together with simultaneous arterial blood pressure tracings and electrocardiographic (ECG) tracings. Hyperemic flow velocity is more than three times basal value.

has shown normal flow reserve to be greater than or equal to 3:1 (figure 1).<sup>8</sup>

### Abnormalities in coronary vasodilator reserve

Coronary vasodilator reserve<sup>9</sup> (ie, the ratio of either hyperemic coronary flow to basal flow or hyperemic flow velocity to basal flow velocity) can be measured by an intracoronary Doppler

catheter. The accuracy of this method has been confirmed,<sup>6</sup> and the equipment is relatively inexpensive. Generally, depressed coronary flow reserve is caused by one of two mechanisms: (1) elevation of basal flow at the expense of reserve flow or (2) depression of peak hyperemic flow. Both mechanisms are present in some patients. Via these mechanisms, depressed coro-

*continued on page 126*



**Myocardial ischemia without atherosclerosis should be suspected in patients with classic or near-classic angina, normal epicardial coronary arteries, and negative results on provocative testing for spasm.**

**Table 1. Diseases or conditions with depressed coronary flow reserve**

|                                  |
|----------------------------------|
| Syndrome X                       |
| Left ventricular hypertrophy     |
| Hypertension                     |
| Aortic stenosis                  |
| Aortic regurgitation             |
| Mitral regurgitation             |
| Hypertrophic cardiomyopathy      |
| Hypertension without hypertrophy |
| Dilated cardiomyopathy           |
| Primary scleroderma              |
| myocardopathy                    |
| Lupus cardiomyopathy             |
| Severe anemia                    |
| Hypoxia                          |
| Oxyhemoglobin dissociation       |
| abnormalities                    |
| ?Diabetes                        |

nary flow reserve is present in a number of conditions that coexist with normal coronary arteries, including myocardial hypertrophy from essential hypertension<sup>10</sup> or other, less important causes; syndrome X<sup>2</sup>; hypertension without ventricular hypertrophy<sup>11</sup>; dilated cardiomyopathy<sup>12</sup>; replacement of normal myocardial cells with fibrous tissue from a variety of causes<sup>13,14</sup>; and metabolic<sup>15</sup> and hematologic abnormalities<sup>10</sup> (table 1).

Myocardial hypertrophy from any cause, including hypertension, aortic stenosis or regurgitation, mitral regurgitation, or hypertrophic cardiomyopathy,

can result in an abnormality in coronary flow reserve.<sup>10,16</sup> However, this abnormality is not linearly related to left ventricular mass<sup>17</sup> and thus is not entirely predictable. Generally, flow velocity measured by placement of an intracoronary Doppler catheter is elevated, as is flow, reflecting the increased metabolic requirements of hypertrophied muscle. Maximum flow is limited; thus, basal flow is increased at the expense of reserve, resulting in a depressed coronary vasodilator reserve.

A decrease in the percent luminal diameter of arterioles has been shown in hypertensive patients. This has been postulated to be a result of hypertrophy of arteriolar walls secondary to the effects of chronically increased pressure,<sup>10</sup> which may explain impaired arteriolar vasodilation and thus limitation of peak hyperemic flow. Interestingly, some patients with hypertension but without ventricular hypertrophy have a depressed flow reserve,<sup>11</sup> which suggests that arteriolar abnormalities can occur in hypertensive patients before the development of hypertrophy. Secondary dilated cardiomyopathy may occur in some hypertensive patients, and flow-reserve characteristics become like those of congestive cardiomyopathy.

Syndrome X is a prime exam-

ple of the second type of flow-reserve abnormality, in which basal flow is normal but maximal hyperemic flow is depressed. The likely cause is an anatomic or functional abnormality in arteriolar vasodilation. Often, a depressed flow both at rest and during hyperemia and a reduced flow reserve are found in dilated cardiomyopathy and other diseases in which normal myocardial tissue is replaced by fibrous tissue.<sup>12</sup> This may, in part, reflect lower metabolic demands, but other causes, including extravascular compression secondary to poor ventricular compliance and reduced coronary perfusion pressures, have been postulated. Both lupus cardiomyopathy<sup>13</sup> and primary scleroderma myocardopathy<sup>14</sup> have been shown to have a depressed coronary vasodilator reserve, increased interstitial fibrous tissue, and myocardial vascular lesions. The latter two findings are very likely etiologically related to the first.

Diabetes mellitus is a major risk factor for atherosclerotic epicardial coronary artery disease. However, diabetes is also linked to microangiopathic abnormalities of the cardiac microcirculation, including thickening of the basement membrane, microaneurysm formation<sup>18</sup> in capillaries, and arteriolar endothelial proliferation leading to a



**Recommended treatment for myocardial ischemia without atherosclerosis consists of medical therapy for the underlying cause and a calcium blocker to maximize vasodilation of coronary resistance vessels.**

decreased luminal diameter. Microcirculatory angina due to diabetes mellitus in the absence of macrocirculatory disease has long been suspected but is still incompletely described.<sup>15</sup> Finally, severe anemia, hypoxia, and oxyhemoglobin dissociation abnormalities may result in increased resting coronary flow at the expense of reserve flow.<sup>10</sup> Even epicardial coronary artery spasm has been associated with evidence of abnormal vasodilator reserve during quiescent periods in which spasm is absent.<sup>19</sup>

### **Diagnosis**

Myocardial ischemia without atherosclerosis should be suspected in patients with classic or near-classic angina (which may vary with exertional threshold), normal epicardial coronary arteries, and negative results on provocative testing for spasm. In particular, the quality of chest discomfort is typical in the disorder, as is the response to nitroglycerin. In many such patients, electrocardiograms show abnormalities ranging from minor nonspecific ST-segment or T-wave changes to left ventricular hypertrophy with a strain pattern. Echocardiograms may be normal, as in syndrome X, but are more often abnormal, depending on the disease process. Thus, hypertensive patients with

this disorder may have left ventricular hypertrophy or dilatation or both. Similarly, left ventricular enlargement and depressed systolic function are generally found in dilated cardiomyopathy.

Results of noninvasive tests, including treadmill testing,<sup>20</sup> exercise testing with a thallium scan,<sup>21</sup> or exercise testing with dipyridamole and a thallium scan,<sup>8</sup> are often abnormal in this disorder, and results may be mislabeled as false-positive. Endomyocardial biopsy, which has been performed in only a few studies to date, has revealed no abnormalities in the intramyocardial small coronary arteries in hypertensive patients.<sup>22</sup> In contrast, an autopsy study performed in humans showed a decrease in the percent luminal diameter of intramyocardial small arteries in hypertensive hearts compared with normal hearts.<sup>23</sup> Definitive diagnosis would be obtained by measurement of lactate produced in coronary venous blood during exertion in addition to documentation of angina and electrocardiographic changes consistent with ischemia.

Since this approach is impractical, testing of coronary vasodilator reserve has come into favor as the most direct diagnostic method. Although exact criteria have not been defined, patients

who are found to have a coronary vasodilator reserve equal to or less than 2:1 in response to maximal hyperemia should be considered to have this disorder, provided that the other characteristic features are present. Patients with a flow reserve of 2:1 to 3:1, which is abnormal, may have this disorder, depending on their activity level and the presence of other morbid conditions (eg, severe hypertrophy, tachycardia, hypertension).

### **The problem in perspective**

Normal epicardial coronary arteries are found in 10% to 20% of patients presenting with chest pain believed to warrant angiography.<sup>24</sup> Although the mechanisms of chest pain in these patients are controversial, many patients presenting with classic angina have myocardial ischemia. Little information is available on follow-up of patients proven to have this disorder by invasive vasodilator reserve testing. However, follow-up of unselected consecutive patients with normal results on coronary angiography has shown an excellent survival rate (96% at 7 years<sup>24</sup>). Patients with the hypertensive form of this disorder no doubt have a worse prognosis than those with the syndrome X form. Further elucidation is important.

*continued*



## Management

Treatment of myocardial ischemia in patients with normal epicardial coronary arteries is often difficult. Chest pain, regardless of the cause, appears to elicit alterations in mood and behavior, particularly in the absence of a satisfactory diagnostic and management plan. Generally, medical therapy for the underlying cause and a calcium blocker to maximize vasodilation of the coronary resistance vessels are recommended. Nitrates may also be effective because of their vasodilatory effect on the microcirculation. In patients with left

ventricular hypertrophy from hypertension, for example, the long-term goals of medical therapy would be to control hypertension and effect regression of left ventricular hypertrophy, and a calcium blocker would be used to relieve inappropriate vasoconstriction of the coronary arterioles, if present. Further advances in treatment are likely now that technological advances allow definitive diagnosis.

## Summary

### Myocardial ischemia in the presence of normal epicardial

coronary arteries can be caused by an abnormality in the microcirculation or myocardial cell or by hypertrophy resulting in depressed coronary vasodilator reserve. Newly developed methods of assessing coronary blood flow and velocity make definitive diagnosis possible. Treatment, which may be difficult, includes therapy for the underlying cause, a calcium blocker, and nitrates. FGM

Address for correspondence: Jan L. Houghton, MD, Section of Cardiology, Medical College of Georgia, Augusta, GA 30912.

## References

1. Likoff W, Segal BL, Kasparian H. Paradox of normal selective coronary arteriograms in patients considered to have unmistakable coronary heart disease. *N Engl J Med* 1967;276(19):1063-6
2. Greenberg MA, Neuburger N, Grose R, et al. Decreased coronary reserve in syndrome X. (Abstr) *Circulation* 1981;64(Suppl IV):305
3. Marcus ML, Doty DB, Hiratzka LF, et al. Decreased coronary reserve: a mechanism for angina pectoris in patients with aortic stenosis and normal coronary arteries. *N Engl J Med* 1982;307(22):1362-6
4. Epstein SE, Cannon RO 3d. Site of increased resistance to coronary flow in patients with angina pectoris and normal epicardial coronary arteries. *J Am Coll Cardiol* 1986;8(2):459-61
5. Boudoulas H, Cobb TC, Leighton RF, et al. Myocardial lactate production in patients with anginal-like chest pain and angiographically normal coronary arteries and left ventricle. *Am J Cardiol* 1974;34(5):501-5
6. Marcus ML, Wilson RF, White CW. Methods of measurement of myocardial blood flow in patients: a critical review. *Circulation* 1987;76(2):245-53
7. Wilson RF, White CW. Intracoronary papaverine: an ideal coronary vasodilator for studies of the coronary circulation in conscious humans. *Circulation* 1986;73(3):444-51
8. Houghton JL, Frank MJ, Carr AA, et al. Experience with the intracoronary Doppler catheter in patients with clinical ischemic heart disease but normal or trivially diseased coronaries. (Abstr) *J Am Coll Cardiol* 1989;13(Suppl A):161A
9. Klocke FJ. Measurements of coronary flow reserve: defining pathophysiology versus making decisions about patient care. *Circulation* 1987;76(6):1183-9
10. Marcus ML. Effects of cardiac hypertrophy on the coronary circulation. In: Marcus ML. The coronary circulation in health and disease. New York: McGraw-Hill, 1983:285-306
11. Bruah JE Jr, Cannon RO III, Schenke WH, et al. Angina due to coronary microvascular disease in hypertensive patients without left ventricular hypertrophy. *N Engl J Med* 1988;319(Nov 17):1302-7
12. Pasternac A, Noble J, Streulens Y, et al. Pathophysiology of chest pain in patients with cardiomyopathies and normal coronary arteries. *Circulation* 1982;65(4):778-89
13. Strauer BE, Brune I, Schenk H, et al. Lupus cardiomyopathy: cardiac mechanics, hemodynamics, and coronary blood flow in uncomplicated systemic lupus erythematosus. *Am Heart J* 1976;92(6):715-22
14. Nitenberg A, Foulst JM, Kahan A, et al. Reduced coronary flow and resistance reserve in primary scleroderma myocardial disease. *Am Heart J* 1986;112(2):309-15
15. Zonerach S, Silverman G, Zonerach O. Primary myocardial disease, diabetes mellitus, and small vessel disease. *Am Heart J* 1980;100(5):754-5
16. Cannon RO 3d, Rosing DR, Maron BJ, et al. Myocardial ischemia in patients with hypertrophic cardiomyopathy: contribution of inadequate vasodilator reserve and elevated left ventricular filling pressures. *Circulation* 1985;71(2):234-43
17. Marcus ML, White CW. Coronary flow reserve in patients with normal coronary angiograms. (Editorial) *J Am Coll Cardiol* 1985;6(6):1254-6
18. Factor SM, Okun EM, Minase T. Capillary microaneurysms in the human diabetic heart. *N Engl J Med* 1980;302(7):384-8
19. Legrand V, Mancini GB, Bates ER, et al. Evidence of abnormal vasodilator reserve in coronary spasm. *Am J Cardiol* 1986;57(6):481-2
20. Levy RD, Shapiro LM, Wright C, et al. Syndrome X: the haemodynamic significance of ST segment depression. *Br Heart J* 1986;56(4):353-7
21. Legrand V, Hodgson JM, Bates ER, et al. Abnormal coronary flow reserve and abnormal radionuclide exercise test results in patients with normal coronary angiograms. *J Am Coll Cardiol* 1985;6(6):1245-53
22. Opherk D, Mall G, Zebe H, et al. Reduction of coronary reserve: a mechanism for angina pectoris in patients with arterial hypertension and normal coronary arteries. *Circulation* 1984;69(1):1-7
23. Tanaka M, Fujiwara H, Onodera T, et al. Quantitative analysis of narrowings of intramyocardial small arteries in normal hearts, hypertensive hearts, and hearts with hypertrophic cardiomyopathy. *Circulation* 1987;75(6):1130-9
24. Kemp HG, Kronmal RA, Vlietstra RE, et al. Seven year survival of patients with normal or near normal coronary arteriograms: a CASS registry study. *J Am Coll Cardiol* 1986;7(3):479-83