

# Sprayed Keratinocyte Suspensions Accelerate Epidermal Coverage in a Porcine Microwound Model

F. A. Navarro, MD,<sup>a</sup> M. L. Stoner, BSc Dip, Med Sci,<sup>b</sup> C. S. Park, MD,<sup>a</sup> J. C. Huertas, MD,<sup>a</sup> H. B. Lee, MD, PhD,<sup>a</sup> F. M. Wood, FRCS, FRACSB,<sup>b</sup> D. P. Orgill, MD, PhD<sup>a</sup>

*Boston, Massachusetts, and Perth, Western Australia*

Keratinocyte suspensions can potentially treat a variety of epidermal defects, but the mechanism of action has not been fully determined. We developed a porcine model to study the effect of sprayed cell suspensions delivered on small wounds within a meshed autograft. Paired full-thickness surgically excised wounds were covered with a fully expanded 3:1 meshed split-thickness autograft. A keratinocyte cell suspension was sprayed onto half of the wounds at a seeding density of  $2.8 \times 10^3$  cells/cm<sup>2</sup>; the remaining wounds were sprayed with cell culture medium alone. Histologic analysis at days 5 and 8 showed an increase in average epidermal thickness, confluence, keratin cysts, and blood vessels in the keratinocyte cell suspension group compared with the cell culture medium control group. Wounds sprayed with the cell suspension showed faster and better quality of epithelialization than wounds sprayed with cell culture medium alone. (*J Burn Care Rehabil* 2000;21:513-8)

Many attempts have been made to improve primary autologous skin grafting, including expansion through meshing, autologous epidermal cell suspensions, and suspension of keratinocytes in a fibrin glue matrix. Hunyadi et al<sup>1</sup> evaluated adult patients with chronic leg ulcers and burns treated with fibrin matrix with and without keratinocytes. Within 14 to 21 days, the group treated with the fibrin matrix with keratinocytes healed completely compared with the group that was treated with the fibrin matrix alone; this suggests that acceleration of closure of full-thickness skin defects is related to the presence of keratinocytes. Stark et al cultured autologous keratinocytes suspended in fibrin glue and overgrafted this with split-thickness cadaver skin.<sup>2-7</sup> Clinically, the new skin had satisfactory stability and mechanical quality. There are some

indications that the split-thickness skin allograft dermis is at least partly integrated into the new skin and may serve as a scaffold for the grafted cell culture.<sup>7a</sup> Such techniques, however, may not provide the optimal dermal thickness or control scarring.

In 1996 Fraulin et al<sup>8</sup> created a new method of delivery of epithelial cell suspensions with the use of an aerosolization apparatus in a porcine model. They showed that epithelial cells could be sprayed in a uniform manner over full-thickness wounds, remain viable, and proliferate to achieve a confluent epithelium.<sup>8</sup> However, the experimental wounds contracted at the same rate as full-thickness wounds sprayed with a solution without epithelial cells. Clinical studies by Wood and Stoner<sup>9</sup> have shown that spraying a cultured autologous keratinocyte suspension for both partial and full-thickness wounds caused by burns induces faster and more complete reepithelialization. They found in clinical studies that full-thickness wounds sprayed with keratinocytes epithelialized better when the keratinocytes were used with a widely meshed skin graft.<sup>9</sup> The mechanism for this improvement is not clear but may relate to either a more uniform dispersion of keratinocytes or a factor intrinsic to the dermis.

In this study, we investigated the effect of a keratinocyte suspension with the technique developed by

From the <sup>a</sup>Wound Healing and Tissue Engineering Laboratory, Division of Plastic Surgery, Brigham and Women's Hospital, Boston, Mass, and the <sup>b</sup>Western Australia Skin Cultured Unit, Royal Hospital, Perth, Western Australia.

Presented at the Thirty-second Annual Meeting of the American Burn Association, Las Vegas, Nev, March 14-17, 2000.

Reprint requests: Dennis Orgill, MD, PhD, 75 Francis St, Division of Plastic Surgery, Brigham & Women's Hospital, Boston, MA 02115-6195.

Copyright © 2000 by the American Burn Association.  
0273-8481/2000/\$12.00 + 0 30/1/110291

doi:10.1067/mbs.2000.110291

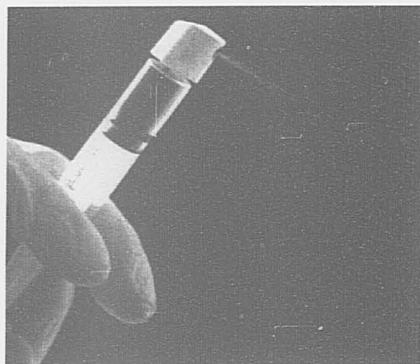


Figure 1. The spray apparatus.

Wood and Stoner<sup>9</sup> on wound healing in full-thickness wounds treated with split-thickness autograft in a pig model.

## MATERIAL AND METHODS

**Cell Spray Apparatus.** The spray apparatus consisted of a plastic actuator or nozzle (1.5 × 1.5 cm) attached to a 5-mL syringe that was used as the pump (Figure 1). Several spray devices were tested in vitro and the clinical apparatus was selected on the basis of a uniform cell distribution with high cell viability measurements after the spray. Nozzles were eliminated if the droplets were too large and just dripped onto the wound or if the fluid emitted as a jet rather than a spray mist. The mist had the advantage of being capable of covering a larger area and delivering the cells to the wound in a gentler fashion.

**Animal Model.** Female Yorkshire pigs (weight range, 30-35 kg) were housed and treated in a facility accredited by the American Association for the Accreditation of Laboratory Animal Care. National Institutes of Health *Guidelines for the Care and Use of Laboratory Animals*<sup>10</sup> were observed by the Institutional Committee for the use of animal research.

**Keratinocyte Harvest.** Pigs were placed in a Panepinto sling (Britz Heidbrink Inc, Wheatland, Wyo) and general anesthesia administered with halothane (1.5-3.5%; Halocarbon Laboratory, River Edge, NJ), oxygen (3-4 L/min), and nitrous oxide (2-3 L/min). The animals were given a 0.3-mg intramuscular injection of buprenorphine hydrochloride (Buprinex, Reckitt and Colman Products, Hull, England) at the conclusion of the procedure.

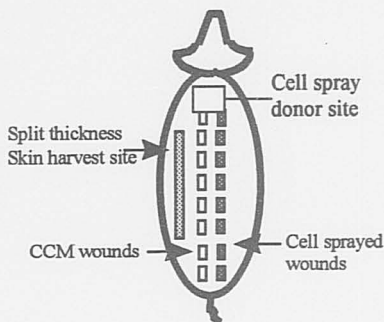


Figure 2. Schematic diagram of animal model.

The dorsal and flank areas of the pigs were shaved, scrubbed with germicide soap, and prepared with 70% isopropyl alcohol. The field was sterilely draped, and mineral oil (Roxane Laboratory Inc, Columbus, Ohio) was spread over the skin. Split-thickness skin specimens that had an area of 30 cm<sup>2</sup> in area and a thickness of 0.012 in were harvested from scapular region with a Padgett dermatome (Padgett Instrument Inc, Kansas City, Mo).

**Keratinocyte Isolation.** Skin specimens were rinsed and soaked in an antibiotic solution for 1 hour. Specimens were then placed into a petri dish that contained 0.5% trypsin EDTA (Gibco BRL, Grand Island, NY) and incubated at 37°C for 45 minutes. Specimens were then placed into dishes that contained Dulbecco modified Eagle medium/F12 (Gibco BRL) without supplements to neutralize the trypsin. The epidermis was mechanically separated from the dermis and then shredded with tissue forceps. The dermis was gently scraped to release basal cells before it was discarded. The suspension was vortexed for 1 minute, filtered through a 100-μm filter (Sigma, St Louis, Mo) and then centrifuged for 7 minutes at 1000 revolutions per minute and 4°C. The cell pellet was resuspended in 10 mL of media (Dulbecco modified Eagle medium/F12 without supplements). Cell viability was calculated with 0.4% Trypan Blue (Gibco BRL) exclusion and a hemocytometer.

**Grafting Studies.** During cell preparation, a second team working simultaneously in the operating room excised 16 paired 3 × 3 cm full-thickness wounds on the dorsum of the pig. Split-thickness skin grafts that were 0.012 in thick were taken from the left flank of the animal with a Padgett dermatome and meshed at 3:1 (Figure 2).

Fully expanded 3:1 meshed split-thickness skin grafts were applied to wounds with stainless steel sta-

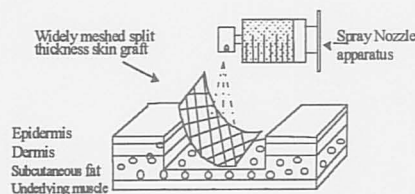


Figure 3. Diagram of microwound model.

ples (Figure 3). Eight of these wounds (on the right side) were sprayed with a keratinocytes cell suspension (KCS) by means of the 1.5-cm nozzle and a 5-mL syringe. The initial cell density was  $5.0 \times 10^4$  cells per  $\text{cm}^3$ . A final volume of 0.5 mL of KCS was sprayed in each wound ( $2.5 \times 10^4$  cells per wound); this achieved a total final cell density after spraying of approximately  $2.8 \times 10^3$  cells per  $\text{cm}^2$ . The remaining 8 wounds were sprayed with the same volume of cell culture medium without cells (CCM). A total of 48 wounds were created in 3 pigs, 24 were treated with KCS and 24 were treated with CCM.

The fluid was allowed to settle, and the wounds were covered with Surfasoft (Mediprof, Bleiswijk, Holland), a monofilament polyamide dressing, which was adhered with tincture of benzoin, followed by dry sterile gauze, elastic bandages, and stokingette.

**Biopsies.** On day 5, the animals were returned to the operating room. Photographs were taken and gross assessment of epidermal coverage and wound area were made on days 5 and 8. Full-thickness transverse biopsy specimens of muscle were transferred to cassettes in 10% formalin. They were embedded, sectioned, and stained with hematoxylin and eosin.

Two observers who were blinded to the treatment groups made macroscopic and histologic observations, and interobserver reliability was established. Epithelial thickness, thickness of the basal cell layer, percentage of epithelial coverage, quality of the dermal-epidermal junction, formation of new blood vessels, and the number of keratin cysts were measured on stained sections.

**Statistical Analysis.** Because the outcomes of interest were measured on different days, we analyzed the data with a general linear model for a single-group repeated measures design. The assumptions for this approach were (1) the individuals represented a random sample from the population of interest and (2) the values of the outcome had a multivariate normal distribution. The statistical procedure we used is called mixed-effects regression model,<sup>11,12</sup> and the




Figure 4. Colony-forming efficiency at day 10 of KCS spray onto a cell culture dish.

Table 1. In vitro selection of spray apparatus

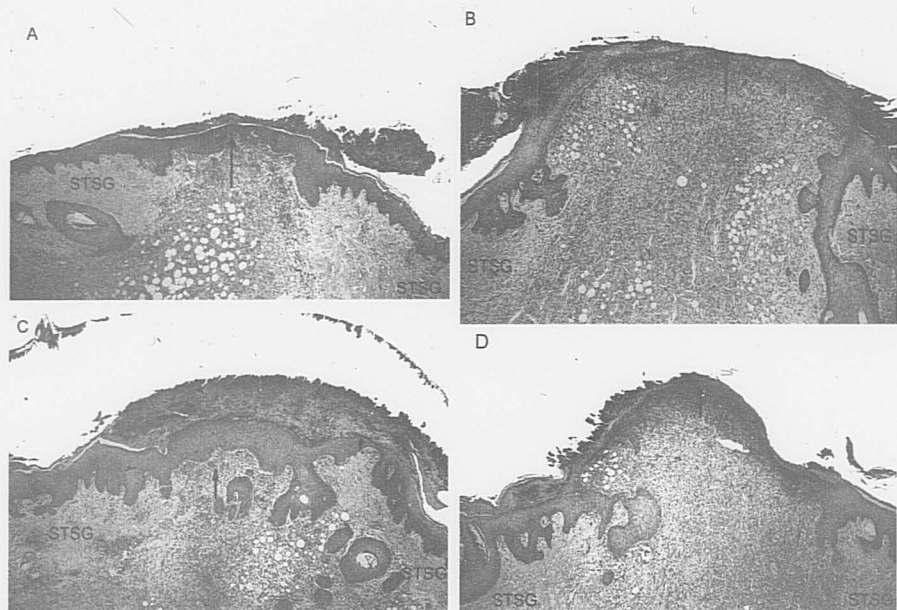
Delivery apparatus	Distance of spray (cm)	Cell viability (%)	
		Before the spray	After the spray
Atomizer	2	94	80
	5	94	74
	10	94	65
Nasal spray	2	86	75
Pump action	5	86	70
Vertical spray	10	86	84
Nozzle and syringe	2	94	94
	5	94	94
	10	94	93
Artist's air brush with pressure attached	2	86	70
	5	86	70
	10	86	70

software we used to fit the models was SAS PROC MIXED (SAS, Cary, NC).<sup>13</sup> Quantal plots were generated to assess the normality assumption of the data.

## RESULTS

The selection of the spray apparatus was initially based on a trypan blue assay (Figure 4). The in vitro tests showed the highest viabilities with the use of device C (Figure 1), and the distance sprayed had no significant difference in cell viabilities for distances between 2 and 10 cm (Table 1).

Forty-eight wounds healed rapidly without infection. Greater wound reepithelialization was observed



**Figure 5.** Photomicrographs (hematoxylin and eosin stain  $\times 5$ ). **A**, Cell spray on day 5. There was total epithelial coverage of the microwound (confluence 100%) with an epithelial thickness of  $\sim 8$  cell layers. **B**, CCM spray on day 5. There was partial epithelial coverage of the microwound (confluence 60%) with an epithelial thickness of  $\sim 12$  cell layers. **C**, Cell spray on day 8. There was total microwound epithelial coverage with an epithelial thickness of  $\sim 12$  cell layers. **D**, CCM spray on day 8. There was a confluence of 90% with a very thin epithelium of  $\sim 3$  cell layers. The arrow shows epithelial coverage at the level of the interstices. STSG, Split-thickness skin graft meshed 3:1.

**Table 2.** Summary of in vivo results

Day	Wound group	Epithelium thickness		Confluence (%)	No. of new vessels	No. of keratin cysts
		No. of total cell layers	No. of basal layers			
5	KCS	$6 \pm 0.5^*$	$1.9 \pm 0.7^\dagger$	$82 \pm 4^\ddagger$	$5.0 \pm 2.1§$	$1.0 \pm 0§$
	Control	$2.2 \pm 0.8$	$1.0 \pm 0.4$	$71 \pm 14$	$3.0 \pm 2.9$	$0.2 \pm 0.4$
8	KCS	$8.3 \pm 0.5^*$	$2.0 \pm 0.9^\dagger$	$85 \pm 15^\ddagger$	$10 \pm 2.7§$	$3.0 \pm 1.2§$
	Control	$4.0 \pm 1.8$	$1.0 \pm 0.5$	$71 \pm 20$	$6.0 \pm 1.4$	$1.2 \pm 1.7$

\* $P < .001$ .

$^\dagger P < .007$ .

$^\ddagger P < .05$ .

$§ P < .0002$  (mixed effects regression model).

macroscopically in the KCS group at both the 5th and 8th days after grafting, and on microscopy there was more complete confluence, epithelial coverage, and basal cell thickness compared with the CCM group (Figure 5; Table 2).

We also assessed the neovascularization process and keratin cyst formation; both of these parameters reflect the proliferative capability of the neoepithelium. Cell spraying appeared to have a significant effect on the number of new blood vessels and the number

of keratin cysts over time (Table 2). In wounds sprayed with the cell solution, the dermal-epidermal junction appeared to be more organized because of the presence of more undulations that resembled a mature epithelium compared with the dermo-epidermal junction found in wounds sprayed with CCM alone.

## DISCUSSION

We have previously shown that the porcine model is desirable in studies that focus on epithelialization.<sup>14,15</sup> The Yorkshire pig allows for multiple wounds with minimal wound variability; this facilitates direct comparisons between treatment groups. We tested the contribution of fresh keratinocytes with a minimal time in cell culture and found acceleration in epithelialization of full-thickness skin wounds. We presume that many of the cells sprayed onto the wound survived and proliferated, but we did not perform marker studies to prove this.

In this study, we attempted to elucidate the effect of a cell spray suspension on the healing characteristics of full-thickness wounds with split-thickness skin grafts. The epidermal coverage was much more developed as the result of a more complete confluence of the wounds sprayed with KCS than of wounds treated with CCM alone. The average number of cell layers in the neo-epithelium (interstices of the split-thickness skin graft) was greater in the experimental group. In addition, greater proliferative capability was suggested for a higher average number of basal cell layers, keratin cysts, and blood vessels in wounds sprayed with KSC.

This new animal model, in which widely meshed skin graft immobilized the cell spray within microwounds for the cell spray, allowed us to study the effect of cells without other variables. Investigators have used a number of strategies to immobilize keratinocytes. Stark et al<sup>3,4</sup> combined keratinocytes with fibrin glue. Gallico et al<sup>16</sup> reported immobilizing cultured epithelial autograft sheets with a gauze backing, and a number of other investigators have immobilized these products on synthetic or semisynthetic scaffolds.<sup>4,5</sup> A recent study in the United States has shown that an allogeneic composite "skin equivalent" speeds healing over conventional methods in venous stasis ulceration.<sup>17</sup> Although the mechanisms for this have not been elucidated, many researchers have postulated that viable cells with this composite secrete a variety of factors that stimulate wound healing.<sup>17</sup> In addition, a bilayer skin substitute seeded with neonatal fibroblasts and subsequently frozen appears in clinical trials to promote the heal-

ing of partial-thickness wounds although the cells in this preparation are dead.<sup>18</sup> This model may be helpful for the distinguishing of what aspects of cell therapy are sufficient and necessary to improve wound healing.<sup>18</sup>

This technology could be directed toward the treatment of other epidermal defects such as pigmentation disorders or skin graft donor sites. Successful repigmentation has been achieved in partial-thickness defects in certain clinical conditions,<sup>19</sup> but this has not been adequately developed for full-thickness defects.<sup>20,21</sup> Wood and Stoner<sup>9</sup> have shown that they can alter the color of the skin in selected patients with a combination of dermabrasion and spraying the wound with a mixture of keratinocytes and melanocytes. In addition, with the advent of gene transfer, this technology could also be useful in the treatment of defects with cytokines and growth factors.

We would like to thank Dr Robert Demling and Dr Elov Eriksson for their support of this project.

## REFERENCES

1. Hunyadi J, Farkas B, Bertenyi C, Olah J, Dobozy A. Keratinocytes grafting: a new means for transplantation for full thickness wounds. *J Dermatol Surg Oncol* 1988;14:75-8.
2. Grafting of burns with cultured epithelium prepared from autologous epidermal cells. *Lancet* 1981;1:75-8.
3. Kaiser HW, Stark GB, Koop J, Balcerkiewicz A, Spiller G, Kreiser HW. Cultured autologous keratinocytes in fibrin glue suspension, exclusively and combined with STS-allograft. *Burns* 1994;20:23-9.
4. Stark GB, Kaiser HW, Koop J, Horch R. Cultured autologous keratinocytes in fibrin glue to cover burn wounds. In: Schalg G, Holle J, editors. *Fibrin sealing in surgical and non-surgical fields*. Berlin: Springer-Verlag; 1995. p. 143-6.
5. Stark GB, Kaiser HW. Cologne Burn Center experience with glycerol preserved allogeneic skin; Part II: combination with autologous cultured keratinocytes. *Burns* 1994;20:534-8.
6. Horch R, Stark GB, Koop J, Spiller G. Cologne Burn Center experiences with glycerol preserved allogeneic skin; Part I: clinical experiences and histological findings. *Burns* 1994;20:523-6.
7. Horch RE, Koop J, Bananasch H, Andree C, Stark GB. Single cell suspension of cultured human keratinocytes in fibrin-glue reconstitute the epidermis. *Cell Transplant* 1998;7:309-17.
8. Cuono C, Langdon R, McGuire J. Use of cultured epidermal autografts and dermal allografts as skin replacement after burn injury. *Lancet* 1986;1:1123-4.
9. Fraulin FGO, Bahoric A, Harrop AR, Hiruki T, Clark HM. Autotransplantation of epithelial cells in the pig via an aerosol vehicle. *J Burn Care Rehabil* 1998;19:337-45.
10. Wood FM, Stoner ML. Western Australian Skin Cultured Unit: a 5-year review. Presented at the Second Biannual Meeting of the Tissue Engineering Society. 1998 Dec 4-8; Orlando, Fla.
11. Institute of Laboratory Animal Resources, National Institutes of Health. Guide for the care and use of laboratory animals. Bethesda (MD): US Dept of Health and Human Services, Public Health Service, National Institutes of Health; 1985. NIH Publication 85-23.

11. Morrison DE. Multivariate statistical methods. New York: McGraw-Hill Publishing Company; 1990. p. 100-25.
12. SAS/STAT users guide. Cary (NC): SAS Institute Inc; 1990. p. 25-30.
13. Laird N, James H. Random effects models for longitudinal data. New York: Biometrics; 1982. p. 963-74.
14. Orgill DP, Butler CE, Reagan JF. Behavior of collagen-GAG matrices as dermal replacement in rodent and porcine model. *Wounds* 1996;8:151-7.
15. Butler CE, Yannas IV, Compton CC, Correia CA, Orgill DP. Comparison of cultured and uncultured keratinocytes seeded into a collagen-GAG matrix for skin replacements. *Br J Plast Surg* 1999;52:127-32.
16. Gallico GG, O'Connor NE, Compton CC, Kehinde O, Green H. Permanent coverage of large wounds with autologous cultured human epithelium. *N Engl J Med* 1984;7:448-51.
17. Trent JF, Kirsner RS. Tissue engineered skin: apligraf, a bilayered living skin equivalent. *Int J Clin Pract* 1998;52:408-13.
- 17a. Falanga V, Sabolinski M. A bilayer living skin substitute (Apligraf) accelerates complete closure of hard to heal venous ulcers. *Wound Repair Regen* 1999;7:201-7.
18. Demling RH, Desanti L. Management of partial thickness facial burns (comparison of topical antibiotics and bio-engineered skin substitutes). *Burns* 1999;25:256-61.
19. Kumagay N, Uchikowski T. Treatment of extensive hypomelanosis with autologous cultured epithelium. *Ann Plast Surg* 1997;39:68-73.
20. Harriger MD, Warden GD, Greenhalgh DG, Kagan RJ, Boyce ST. Pigmentation and microanatomy of skin regenerated from composite grafts of cultured cells and biopolymers applied to full-thickness burn wounds. *Transplantation* 1995;59:702-7.
21. Medalie DA, Tompkins RG, Morgan JR. Characterization of a composite tissue model that supports clonal growth of human melanocytes in vitro and in vivo. *J Invest Dermatol* 1998;111:810-6.

### Availability of Journal Back Issues

As a service to our subscribers, copies of back issues of *Journal of Burn Care & Rehabilitation* for the preceding 5 years are maintained and are available for purchase from Mosby until inventory is depleted, at a cost of \$14.00 per issue. The following quantity discounts are available: 25% off on quantities of 12 to 23, and one-third off on quantities of 24 or more. Please write to Mosby, Subscription Customer Service, 6277 Sea Harbor Dr, Orlando, FL 32887, or (800) 654-2452, or (407)345-4000 for information on availability of particular issues. If unavailable from the publisher, photocopies of complete issues may be purchased from Bell & Howell Information and Learning, 300 N Zeeb Rd, Ann Arbor, MI 48106-1346, (734) 761-4700.