

Topodermatographic Image Analysis for Melanoma Screening and the Quantitative Assessment of Tumor Dimension Parameters of the Skin

Holger Voigt, M.D., and Richarda Claßen, M.D.

Background. The clinical need to identify and evaluate changes of cutaneous lesions in melanoma screening or follow-up of patients with cancer is of paramount importance. Because skin-lesion changes may be small and numerous, clinical assessment alone does not meet the requirements of quantitative assessment. Using the computer as a diagnostic tool for the image analysis of sequentially captured skin surface images has resulted in the technical problem of insufficient registration reproducibility. This paper describes the technical logistics, setup procedure, and clinical evaluation of the novel technique termed "topodermatography," which performs the quantitative videographic image analysis of skin-lesion changes over time.

Methods. Digitized measurements of skin-surface image parameters were performed using a high-speed processor with an onboard coprocessor, a high-resolution video camera, specifically designed image processing software, and a position framework for the adjustment of the patient's standing position. The topodermatographic image analysis was performed on 109 consecutive patients who were at risk for melanoma ($N = 98$), had lesions from Kaposi's sarcoma ($N = 4$), had metastatic skin deposits from melanoma ($N = 3$), and had breast cancer ($N = 4$).

Results. Skin lesion changes over time could be identified reliably within a few millimeters of diametric enlargement. In this series, a 0.51% early melanoma detection rate was assessed in 19 of 98 patients followed for 12 months. By monitoring manifest neoplastic skin lesions, tumor growth kinetics were analyzed quantitatively to determine the total area of skin involvement, thus facilitating precise response assessment.

Conclusions. Topodermatographic image analysis helps to optimize screening and follow-up procedures for patients with melanoma and populations at risk for mel-

anoma. In addition, metastatic tumor lesions on the skin can be monitored dynamically, facilitating the accurate evaluation of the impact of systemic therapy on multiple skin deposits from melanoma and nonmelanoma cancers. *Cancer* 1995;75:981-8.

Key words: computerized image analysis, topodermatography, melanoma, screening, dysplastic nevi, multiple moles, total lesion count, tumor dimension parameters, skin metastasis.

Cutaneous tumor manifestations can be detected and evaluated directly by visual perception versus those that are hidden internally. However, besides subjective inspection, quantitative assessment of multiple skin-surface alterations and their dynamic changes over time is nearly impracticable because of inadequate objective registration modalities. Concerning melanoma screening¹⁻⁴ and relative educational programs,⁵ attempts to improve assessment scrutiny and thus to extend the quantity and quality of skin-surface information have led to a variety of technical procedures including extensive manual body charting,⁶ photographic documentation (total body photography),⁷⁻⁹ epiluminescence microscopy (nevoscropy),¹⁰⁻¹³ ultrasonography,¹⁴⁻¹⁷ and, finally, introducing the computer as a technical tool assisting the clinician in diagnosing selected skin manifestations.¹⁸⁻²⁰ In oncology, the clinical need to detect, measure, and follow skin-surface changes over time or during therapy is influenced crucially by the inevitable requirement to obtain comparable information based on reproducible registration conditions. Thus far, the reproducibility of positioning skin-surface areas for digitized videographic imaging has been a major technical obstacle that has not yet been mastered successfully. Computerized image analysis systems described in the literature

From the Melanoma Research Project, Clinic Section and Research Institute, Kaltenkirchen/Holstein, Germany.

Address for reprints: Holger Voigt, M.D., Melanoma Research Project, Clinic Section and Research Institute, 14 Ortelsburger Street, D-24568 Kaltenkirchen/Holstein, Germany.

Received July 21, 1994; revision received October 21, 1994; accepted October 21, 1994.

Canfield Scientific, Inc. - Exhibit 1003
Canfield Scientific, Inc. v. Melanoscan, LLC
IPR2017-02125

Topodermatographic Image Analysis for Melanoma Screening and the Quantitative Assessment of Tumor Dimension Parameters of the Skin

Holger Voigt, M.D., and Richarda Claßen, M.D.

Background. The clinical need to identify and evaluate changes of cutaneous lesions in melanoma screening or follow-up of patients with cancer is of paramount importance. Because skin-lesion changes may be small and numerous, clinical assessment alone does not meet the requirements of quantitative assessment. Using the computer as a diagnostic tool for the image analysis of sequentially captured skin surface images has resulted in the technical problem of insufficient registration reproducibility. This paper describes the technical logistics, setup procedure, and clinical evaluation of the novel technique termed "topodermatography," which performs the quantitative videographic image analysis of skin-lesion changes over time.

Methods. Digitized measurements of skin-surface image parameters were performed using a high-speed processor with an onboard coprocessor, a high-resolution video camera, specifically designed image processing software, and a position framework for the adjustment of the patient's standing position. The topodermatographic image analysis was performed on 109 consecutive patients who were at risk for melanoma ($N = 98$), had lesions from Kaposi's sarcoma ($N = 4$), had metastatic skin deposits from melanoma ($N = 3$), and had breast cancer ($N = 4$).

Results. Skin lesion changes over time could be identified reliably within a few millimeters of diametric enlargement. In this series, a 0.51% early melanoma detection rate was assessed in 19 of 98 patients followed for 12 months. By monitoring manifest neoplastic skin lesions, tumor growth kinetics were analyzed quantitatively to determine the total area of skin involvement, thus facilitating precise response assessment.

Conclusions. Topodermatographic image analysis helps to optimize screening and follow-up procedures for patients with melanoma and populations at risk for mel-

anoma. In addition, metastatic tumor lesions on the skin can be monitored dynamically, facilitating the accurate evaluation of the impact of systemic therapy on multiple skin deposits from melanoma and nonmelanoma cancers. *Cancer* 1995;75:981-8.

Key words: computerized image analysis, topodermatography, melanoma, screening, dysplastic nevi, multiple moles, total lesion count, tumor dimension parameters, skin metastasis.

Cutaneous tumor manifestations can be detected and evaluated directly by visual perception versus those that are hidden internally. However, besides subjective inspection, quantitative assessment of multiple skin-surface alterations and their dynamic changes over time is nearly impracticable because of inadequate objective registration modalities. Concerning melanoma screening¹⁻⁴ and relative educational programs,⁵ attempts to improve assessment scrutiny and thus to extend the quantity and quality of skin-surface information have led to a variety of technical procedures including extensive manual body charting,⁶ photographic documentation (total body photography),⁷⁻⁹ epiluminescence microscopy (nevoscropy),¹⁰⁻¹³ ultrasonography,¹⁴⁻¹⁷ and, finally, introducing the computer as a technical tool assisting the clinician in diagnosing selected skin manifestations.¹⁸⁻²⁰ In oncology, the clinical need to detect, measure, and follow skin-surface changes over time or during therapy is influenced crucially by the inevitable requirement to obtain comparable information based on reproducible registration conditions. Thus far, the reproducibility of positioning skin-surface areas for digitized videographic imaging has been a major technical obstacle that has not yet been mastered successfully. Computerized image analysis systems described in the literature deal primarily with the structural analysis of selected single lesions to diagnose the primary lesion more accurately.²¹⁻²³ Extending the region of interest from one single lesion to areas including multiple or of-

From the Melanoma Research Project, Clinic Section and Research Institute, Kaltenkirchen/Holstein, Germany.

Address for reprints: Holger Voigt, M.D., Melanoma Research Project, Clinic Section and Research Institute, 14 Ortelsburger Street, D-24568 Kaltenkirchen/Holstein, Germany.

Received July 21, 1994; revision received October 21, 1994; accepted October 21, 1994.

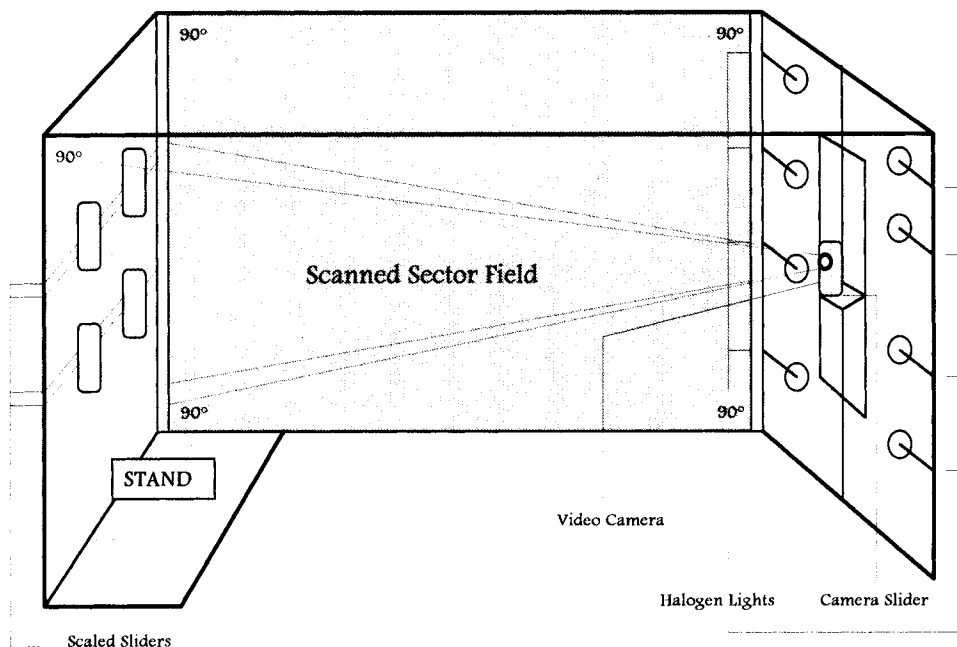


Figure 1. Topodermatographic position framework (schematic). Patient's median standing level (left), median video camera/bilateral lighting level (right), and scanned sector field (middle) between camera and preset skin-surface area.

ten almost countless lesions for simultaneous quantitative assessment is still under investigation because it suggests the need to detect multiple lesion-border contours reliably and to solve the reproducibility problem of the target registration area.²⁴ In this article, we report the results of a clinical screening study of the computerized analysis of digitized skin-surface images, introducing a newly developed technique termed "topodermatography,"²⁵ which allows patients with multiple skin lesions to be followed by quantitative videographic image processing with more reliable reproducibility.

Patients and Methods

Hardware

Digitized measurements of skin-surface image parameters were performed using a plug-in set of a high-speed processor with an on-board coprocessor, a high-resolution video camera source, a specifically designed image-processing software (Areascan 4.0), and a position framework (Fig. 1) for adjusting the patient's standing position.

Measurement Procedure

To avoid axial and transversal spinal flexion and thus to provide reliable registration reproducibility, the patient's standing position was fixed at the thoracic and iliac level by symmetrically fitting the lateral extent of the trunk shape into horizontally adjustable scaled sliders of the position framework, the positions of which were recorded and identically readjusted for serial fol-

low-up measurements. In addition, the vertical height of the video camera was adjusted on a scaled-camera slider, and its framework position was recorded. Calibration for camera setting and position reproducibility was considered adequate if the image boundaries, the framework slider position settings, and the depicted anatomic match points were identical. Images were captured three times sequentially under identical illumination conditions provided by halogen lights fixed laterally at the position framework.

Imaging System

The image processing software used was installed on a 32-bit TMS 34020 math processor/TMS 34082 math coprocessor system (Texas Instruments Inc., Dallas, TX). Embedded in an IBM (International Business Machines, Armonk, NY)-compatible personal computer on a plug-in board setup, the processing unit operates at 10 million instructions per second and 40 Mega floating point operations per second. The image processing board provides a 16-Mbyte dynamic memory and a 2-Mbyte video memory for fast handling and processing of serial high-resolution images of greater than or equal to 1024×1024 picture elements (pixels). Images were captured from a Hitachi black/white charge-coupled device camera (KP-Mlek, Hitachi Ltd., Tokyo, Japan), digitized at 8 bits as gray-level images, and were displayed at 256 levels of gray or at 256 different false colors to be selected from a set of 16.8 million colors. For comparison analysis and storage, digitized images were saved on removable hard disks.

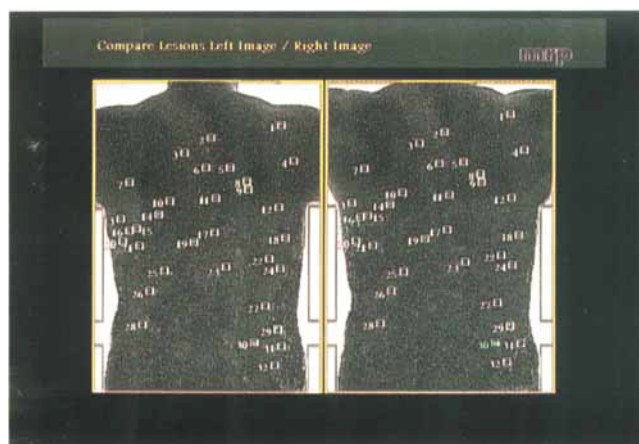


Figure 2. Topodermatographic juxtaposition monitor display. Adjustment of the binary threshold of the converted black and white images with the threshold focus adjusted at the follicular skin-surface pattern (for demonstration) and displaying the calculated total lesion count of the preset mole threshold for melanoma screening.

Image Analysis

In this investigational series, the total front (ventral) and back (dorsal) trunk areas were selected for computed videographic image analysis. Initial images of the selected target regions were captured at resolutions of 512 pixels horizontally and 768 pixels vertically, thus equaling spatial image resolutions of 1 mm per pixel. Total in-depth object illumination was given special attention to prevent any artificial shadowing possibly leading to incorrect gray-level discrimination. To detect any change of skin-surface image parameters (i.e., growth of a lesion, new lesions, change of border contours etc.), images were captured in sequence bimonthly at the same registration settings. Images captured for comparison analysis were arranged in a juxtaposition monitor display, resulting in a total display resolution of 1024×768 pixel. For mathematic calculation of image parameters, a set of preprocessing operators and digital filters was then applied in sequence.²⁶⁻²⁹ Averaging operators eliminated image noise by filtrating unwanted high-frequency image details, and median operators were applied to arrange pixel information sequentially, thereby equilibrating image data inhomogeneity. In addition, Sobel operators were used to enhance and optimize the detection of border contours as a presupposition for calculating target-lesion parameters. Finally, the target lesions for analysis were selected by image binarization and adjustment of the binary threshold (threshold focus) so that only skin lesions were depicted, exceeding the critical preset threshold focus diameter. Consequently, the total number of target objects selected for the image processing workup was defined, likewise pro-

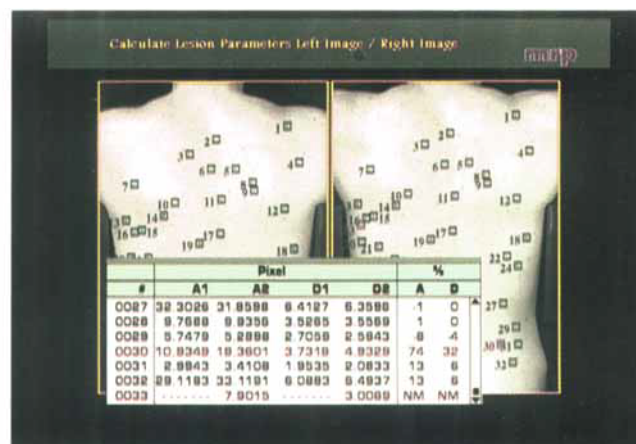


Figure 3. Topodermatographic juxtaposition monitor display. Comparison of images displaying total count of identified skin lesions. Changed lesions are highlighted (red). The area and the dimension of lesion size were calculated, compared, and significant changes were highlighted (red).

viding the opportunity to analyze different individual lesion distribution patterns in specific separate layers with distinct threshold focus adjustments (Fig. 2). Artificial objects not related to target structures, but yet impeding mathematic image processing (e.g., hair filaments, scars, wrinkles, unwanted target objects such as telangiectatic angiomas, folliculitis papules, seborrheic keratoses, etc.) were removed from the image screen. This procedure regularly takes only a few seconds and does not necessarily require the patient's presence if the image has been stored already and can be magnified for better detail differentiation, if needed. Finally, a set of specifically designed, multiple pass, search, and comparison algorithms was applied that was capable of identifying, counting, and labeling objects within a defined preset range of lesion size magnitude (0.5–30 mm). Because overlaying images for comparison analysis can provide misleading data because of axial image distortion, relational search algorithms were applied instead, recognizing and calculating the topographic image position of fixed external match points (given by the framework slider contours) and the relational positions of reference-target lesions depicted within the image boundaries. By digitized comparison, objects not detectable in the initial image (new lesions) or found missing in the sequential image (excised lesions) were labeled. In addition, by operating subpixel algorithms²⁷⁻²⁹ applied on the gray-level images, the area and the dimension of the selected objects were calculated and compared, and significant changes were highlighted (Fig. 3).

Statistical Considerations

By processing the gray-level luminance gradients at the lesion boundaries, object areas could be calculated with

an accuracy of a 0.25-pixel area equaling 0.25 mm². Setting the binary threshold focus selects the target lesions for analysis for the expected critical lesion dimension that should be detected if changed. This setting varies according to the objectives pursued, depending on the mean dimension of the target objects selected for analysis. Once defined, this setting must be maintained for the entire investigation. For mathematic reasons, enlargement of lesion-area size expressed as a percentage, especially in small lesions, may indicate misleadingly significant lesion growth, whereas the enlargement of the lesion dimension indicates only slight changes in transversal lesion magnitude. Generally, image object growth was, therefore, defined as clinically useful/significant if a small object (lesion) of 1–5 mm in greatest dimension increased by 30% of its area (corresponding to a 15% increase in dimension), or, if a larger sized object of greater than or equal to 6 mm in greatest dimension increased by 20% of its area (corresponding to a 10% increase in dimension). Because an increase in lesion-area size basically is attributable to diametric enlargement, the object dimension was, therefore, considered the most reliable and sensitive lesion parameter to be assessed. To assure measurement accuracy, test-layer plates with contoured test lesions of defined area and dimension size were inserted into the position framework before every image-capture session for calibration. Images were then captured three times sequentially to provide adequate reproducibility at short intervals (i.e., minutes). Images were included into the final analysis only if short-term reproducibility of detecting, counting, and calculating contoured lesions was found to be greater than 90%.

Patients

A total of 109 consecutive patients was investigated. Patients were prepared for image analysis only if they had a dense hair coat requiring shaving of the target registration area. In most cases, however, the application of correctional operators sufficiently filtered unwanted effects induced by crossing-hair filaments. Among the individuals investigated, 11 patients receiving non surgical therapy with skin lesions from metastatic melanoma (N = 3), Kaposi's sarcoma (N = 4), and breast cancer (N = 4) were included for the quantitative monitoring of growth kinetics over time. Patients' characteristics are shown in Table 1. Patients were considered eligible if they had multiple flat-skin lesions originating from moles (dysplastic nevi), Kaposi's sarcoma, or skin metastasis from melanoma or breast cancer. To avoid mathematic miscalculation, target lesions could not have circumferential indentations; otherwise, these lesions were excluded from the final analysis. Image captures were taken serially in bimonthly intervals, and

Table 1. Patient Characteristics

	N
Total	109
Median age (yr) (range)	32 (17–62)
Male:female	43:66
Melanoma screening: multiple/dysplastic moles	98
Melanoma screening: melanoma in history (excised)	11
Skin metastasis from melanoma	3
Cutaneous Kaposi sarcoma	4
Skin metastasis from breast cancer	4

a minimum of six images in 12 months for melanoma screening and 6 months for cancer monitoring was considered adequate for the final analysis of accuracy and reliability of the technique used. Changes of skin-surface parameters were assessed by digitized comparison of sequential images. Mathematic processing allowed changes in number, distribution, dimension, perimeter, and area size to be recorded. In this series, no analysis was drawn from possible causative factors that may have induced size changes of the lesions assessed. Histologic clarification was performed if it was diagnostically indicated or considered necessary to avoid a treatment delay in individual situations. Patients provided written informed consent for entrance in the study.

Results

Topodermatographic image analysis results are shown in Table 2. In the melanoma screening and follow-up series, of 9672 contoured lesions detected and followed for 12 months, 647 (6.69%) were identified as growing lesions showing significant size changes suspicious of early tumor growth. They included a total of 173 lesions identified as new lesions but, likewise, were processed as changed or enlarged lesions because they had no matching correlate from the previous images. After histologic clarification, a total of 49 (0.51%) lesions in 19 of 98 patients was identified as early melanomas (radial growth phase), whereas the remaining 598 (6.18%) lesions proved to be benign, yet growing melanocytic nevi. Because the target threshold focus was adjusted to detect a lesion-dimension enlargement of 1.0 mm, and because lentiginous spots thus were detected likewise, the total number of detected lesions did not indicate that they all were definitely melanocytic nevi, which was possible if the target threshold focus was adjusted toward larger dimensions. In patients with manifest skin lesions from metastatic melanoma, Kaposi's sarcoma, and breast cancer, the target threshold focus was adjusted to 2.0 mm. In this group, tumor growth kinetics could be monitored quantitatively for the total lesion count, detection of new lesions, regressed lesions, and

Table 2. Topodermatographic Image Analysis (Trunk Series): Results in 109 Individuals

	Melanoma screening	Metastatic melanoma	Kaposi sarcoma	Metastatic breast cancer
Patients (N)	98	3	4	4
Images (N)	5982	228	312	336
Target threshold focus [diameter (mm)]	1.0	2.0	2.0	2.0
Median lesion count [ventral trunk (N)]	41	—	—	—
Median lesion count [dorsal trunk (N)]	58	—	—	—
Median lesion count [target area (N)]	—	38	24	39
Median area size (pixel)	16.7432	36.6022	55.6482	45.6734
Median diameter size (pixel)	4.6238	6.8314	8.4211	7.6255
Median measurement accuracy (%)	95.2	95.6	93.2	92.0
Total analyzed lesions (N)	9672	125	91	151
New lesions (N)	173	89	0	67
Enlarged lesions (N/(%))	647 (6.69)	—	—	—
Histology: benign (N/(%))	598 (6.18)	—	—	—
Histology: early melanoma (N/(%))	49 (0.51)	—	—	—
Quantified tumor regression (N)	—	2 (partial)*	4 (partial)*	1
Quantified tumor progression (N)	—	1	0	3

* Progressed again later.

calculation of the total lesion area (melanoma: partial regression [$>50\%$ total lesion area] 2/3, progressive disease 1/3; Kaposi's sarcoma: partial regression 4/4; breast cancer: partial regression 1/4, progressive disease 3/4). Eighty-nine new lesions were identified in patients with metastatic melanoma, none in patients monitored for Kaposi's sarcoma, and 67 in those monitored for metastatic breast cancer. All patients with partial tumor regression progressed again at a later stage of follow-up.

Discussion

Melanoma screening, early diagnosis, and prevention must be emphasized in the clinical management of malignant melanoma. A practical routine workup, therefore, should consist largely of a thorough clinical skin examination. Any advances in the early detection of potential melanoma precursors or early melanomas at superficial growth stages substantially enhance definite cure rates.¹⁻³ Although of paramount importance, clinical skin inspection often is limited in length and scrutiny. In a neurophysiologic regard, recognizing structural features on the skin surface is based on the perception of luminance gradients mediated by retinal rods, whereas color perception is accomplished through retinal cone receptors. Both components are predetermined anatomically by their quantitative distribution ratio, and their superimposing cooperation is optimized functionally relative to adequate object illumination. Viewing images primarily means that pictures are sub-

divided into a multiplicity of picture elements (pixels), the number of which defines the image resolution. As is known from professional photographic procedures, brightness variations of viewed objects under illumination are critical in discriminating object contours. In biologic systems, visual perception also is influenced individually by optical refraction and cortical recognition patterns, which define the terminal cognitive resolution of viewed images. Identification of distinct structural features on the skin surface, thus, presupposes that luminance gradients can be perceived and allocated stereologically as a complex array of luminance distribution within viewed images. In transferring these physiologic conditions to a computerized image processing system and applying computed models for skin-surface analysis, brightness information must be processed quantitatively by digitizing the luminance of each picture element. In doing so, each pixel is given a binary brightness value (0 or 1). If 8-bit discrimination systems are used (charge-coupled device camera), this allocation is spread over $2^8 = 256$ intervals resulting in 256 distinguishable gray levels representing a luminance profile. As a whole, any image thus is composed of a multiplicity of specific unequivocal image information defined by pixel number (resolution) and luminance values (gray level, 0-256). Distinct structural features on the skin surface can, therefore, be depicted quantitatively as pixel-oriented brightness histograms, which are visualized fingerprints of the object's image structure. These image profiles can be captured videographically, compared, and mathematically calculated.

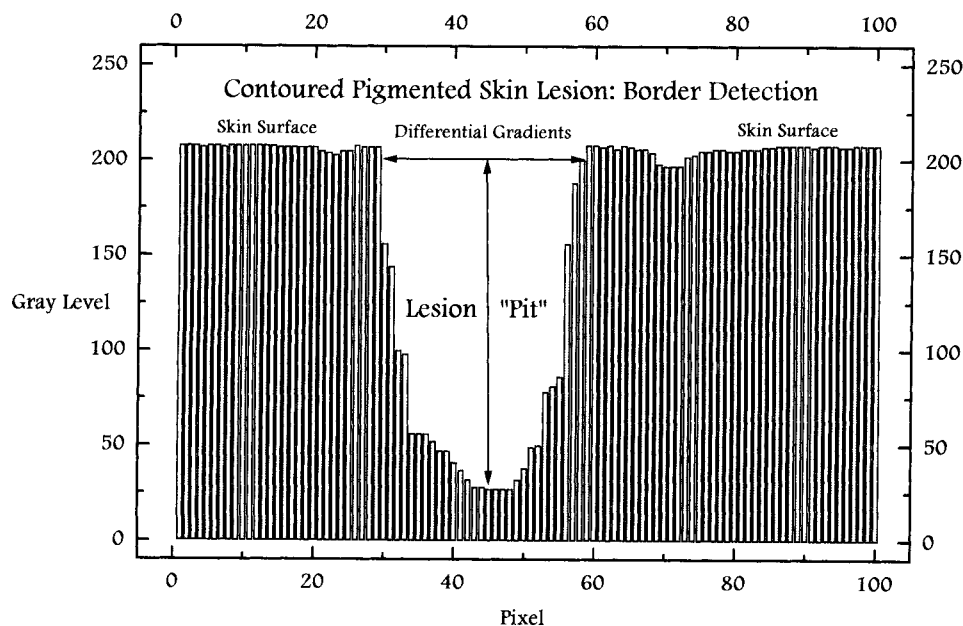


Figure 4. Border detection of pigmented skin lesions (schematic) by processing gray-level gradients over lesion pits.

A distinct lesion feature on the skin surface is defined by its boundaries that separate lesional from non-lesional skin. In luminance profiles, lesion boundaries are merely brightness decrements. Characteristically, they are basin-shaped luminance pits as a bidimensional measure of lesion size (Fig. 4). Applying this correlation to a three-dimensional object surface model, White et al. developed the terrain concept, presenting skin-surface features as three-dimensional arrangements of pits and peaks within distinct lesion boundaries. Using this model for image feature detection, the pit volume was considered an indicator of the image-feature size.³⁰

In a practical view, automated detection and measurement of multiple features on the skin surface are focused primarily on feature dimensions that are clinically relevant. For example, an initial malignant transformation of a melanocytic lesion was found to correspond clinically with a bidimensional enlargement of the diametric shape dimensions.¹⁻³ Without metric measurement, this early growth phase is almost invisible and unrecognizable to the patient. Looking daily at the same shape of a slightly changing lesion, patients often disregard minor enlargement over longer time periods. In melanoma, radial enlargement of lesion size precedes vertical tumor growth, thus indicating the early tumor growth phase in a flat lesion.⁴ Using computerized image analysis, this feature must, therefore, be detected sensitively so that curative therapy is feasible. If the image analysis system used can detect minor changes of lesion size within the dimensions of a few millimeters, it would detect and process dimension parameters of larger lesions likewise. Assessing patients with multiple/dysplastic nevi for melanoma screening

thus can be considered a technical model evaluating the reliability of digitized image analysis for monitoring multiple skin-surface features of any origin. To automatically detect discernible skin lesions and calculate lesion-dimension parameters accurately, border contours must be defined reproducibly. Although this definition must be considered arbitrary because it only approximates real detail separation, edge-finding algorithms (convolution filters) can be used with a high grade of consistency, processing gray-level-based luminance profiles at the circumferential lesion contours.^{24,31} In addition, these lesion border contours must be enhanced or complemented automatically if the luminance profiles at the perimetric lesion border do not reveal luminance gradients distinct enough to be processed for digitized measurement. This also suggests that lesional border contours must not have circumferential indentations that may lead to mathematic miscalculation. Furthermore, any impact of image artifacts induced by electronic image noise (computer system, photodetector, camera, frame grabber, etc.), inhomogeneous illumination, hair filaments, follicles, wrinkles, etc., must be eliminated or at least reduced by system calibration, application of preprocessing operators, and thresholding of the binarized images at defined registration settings. Among others, the Laplacian-of-a-Gaussian filter has been shown to meet the requirements described above for boundary detection and cutaneous lesion localization in digital images appropriately.^{24,30}

For comparison analysis, reproducible registration settings also must be provided for the patient's positioning. Because overlaying images for comparison analysis regularly results in erroneous information because of

nonlinear axial image distortion, registration reproducibility must be obtained differently. By mathematically regarding skin lesions as image points, Perednia et al. proposed the application of a point-pattern matching procedure using a three-point geometric transformation algorithm, which was found to have an average matching accuracy of 97%.³² For this purpose, the Gabriel-Graph representation technique of paired images was implemented to detect sets of appropriate match points in captured images automatically.³³ In the present study, reproducibility of image registration was, in contrast, provided by additionally using a specifically designed position framework for the patient's positioning. Consequently, any axial or transversal spinal flexion was effectively prevented. For image processing, a set of specifically designed relational search algorithms was then applied. These were able to recognize and calculate the image positions of fixed external match points (given by the frameworks slider contours and thus being identical in subsequent images) relative to the topographic positions of reference-target lesions on the skin surface depicted within the image boundaries. Calculating the interlesional distance parameters between pixel-based brightness pits, contoured skin lesions were reproducibly detected, counted, and compared, and their dimension parameters were calculated with a median registration accuracy of > 95%.

In the field of clinical application, there is to date no literature on large-scale investigations introducing computerized image analysis systems in a clinical setting to monitor multiple skin-surface features. To assess objectively the clinical parameters for the primary diagnosis of a single pigmented skin lesion, the computerized image analysis system "skinview" was introduced, which was based on image capturing and mathematic sources processing morphologic and anamnestic parameters (indicators). This process strived to supply the non- or less experienced clinician with measurement parameters, providing processed data sufficient enough to give proper assistance in diagnosing a suspicious pigmented skin lesion correctly.²² The image analysis system described by Green et al. was designed to process 16 different parameters independently to obtain precise data for diagnostic purposes.²³ Both systems were found to be capable of accumulating data sets that analyzed image-feature details of single pigmented skin lesions reproducibly, thus, likewise improving the diagnosis and early diagnosis of a primary melanoma. The topodermatographic image analysis system presented here was, in contrast, primarily focused on the requirement to capture and process detailed surface information for instant metric determination of shape changes in multiple skin lesions in defined time periods. In melanoma screening, for instance, the total mole number has been found to be

indicatively correlated with melanoma risk.^{34,35} Whenever patients present with numerous cutaneous lesions, only counting them on the accessible skin surface appears mostly impracticable. Topodermatography, however, allows to capture defined views of reference skin-surface areas automatically and to store and process images independently. Any growing lesion of concern thus may be identified and selected for further workup. The system does not give a definite diagnosis itself but optimizes the reproducible assessment of structural skin-surface changes for selective approaches to clarify identified and altered lesions. Consequently, skin lesions that had earlier been considered evaluable rather than measurable can be assessed and evaluated quantitatively. In melanoma screening, topodermatography helps not only to identify lesion changes over time, but also helps to quantify the risk burden indicated by the multiplicity of potential melanoma precursors. In a pilot series evaluating 22 patients with multiple/dysplastic nevi (>30 trunk lesions) and/or a history of melanoma, it was shown that even minor size changes could be detected reliably, finally revealing a 9.38% detection rate of early melanomas in a high-risk population.²⁵ Using a position framework for better registration reproducibility, the results of the monitoring study presented here indicate that topodermatographic image analysis provides a comprehensive, reproducible, and quantifiable diagnostic access to any skin lesion distribution relative to time changes. Because patients were entered consecutively in this monitoring trial, the patient population as a whole cannot be considered representative. Thus, no final clues can be drawn from the early melanoma detection rate in this series relative to epidemiologic prevalence.

To the authors' knowledge, this series is the first large-scale study indicating the practical feasibility of using computerized image analysis systems for melanoma screening and monitoring of patients with cancer with cutaneous deposits. Using this technique, risk lesions can be identified timely so that curative surgery can be applied without delay. Concerning costs, the topodermatographic image analysis system approximates \$60,000 in U.S. dollars, depending on the hardware used. Once installed, however, the consecutive cost/benefit ratio soon reverses favorably, and then is basically calculable relative to image-storage capacities. Topodermatography may, therefore, effectively help to optimize screening and follow-up procedures for patients with melanoma patients and populations at risk for melanoma. In addition, metastatic tumor lesions can be monitored dynamically, providing the means to evaluate the impact of systemic therapy on multiple skin deposits from melanoma and nonmelanoma cancers accurately.

References

1. Rigel DS, Friedman RJ, Kopf AW. Early detection of malignant melanoma: the role of physician examination and self-examination of the skin. *CA Cancer J Clin* 1985;35:130-51.
2. Rigel DS, Friedman RJ, Kopf AW, Weltman R, Prioleau PC, Safai B, et al. Importance of complete cutaneous examination for the detection of malignant melanoma. *J Am Acad Dermatol* 1986;14:857-60.
3. Fitzpatrick TB, Rhodes AR, Sober AJ, Mihm MC. Primary malignant melanoma of the skin: the call for action to identify persons at risk to discover precursor lesions; to detect early melanomas. In: Elwood JM, editor. *Melanoma and naevi: incidence, interrelationships and implications*. Basel: Karger, 1988: 110-7.
4. McLeod GR. Control of melanoma in high-risk populations. In: Elwood JM, editor. *Melanoma and naevi: incidence, interrelationships and implications*. Basel: Karger, 1988: 131-9.
5. MacKie RM, Doherty VR. Educational activities aimed at earlier detection and treatment of malignant melanoma in a moderate risk area. In: Elwood JM, editor. *Melanoma and naevi: incidence, interrelationships and implications*. Basel: Karger, 1988: 140-52.
6. Collison DW, Mikhail GR, Rosen GB. Data collection and analysis. In: Mikhail GR, editor. *Mohs micrographic surgery*. Philadelphia: WB Saunders, 1991: 309-28.
7. Slue W, Kopf AW, Rivers JK. Total body photographs of dysplastic nevi. *Arch Dermatol* 1988;124:1239-43.
8. Kopf AW, Rivers JK, Slue W, Rigel DS, Friedman RJ. Photographs are useful for detection of malignant melanoma in patients who have dysplastic nevi. *J Am Acad Dermatol* 1988;19:1132-4.
9. Wagner RF, Shriner DL, Glowczwski J. Full scale color total body photography provides an objective baseline for dysplastic nevus syndrome monthly patient self-examination. *Advances in the biology and clinical management of melanoma. Proceedings of the 35th Annual Clinical Conference and 24th Annual Pathology Program*; 1991 Nov 20-23; Houston (TX): 106.
10. Dhawan AP. Early detection of cutaneous malignant melanoma by three-dimensional nevoscropy. *Comput Methods Programs Biomed* 1985;21:59-68.
11. Steiner A, Pehamberger H, Wolff K. In vivo epiluminescence microscopy of pigmented skin lesions. II: diagnosis of small pigmented skin lesions and early detection of malignant melanoma. *J Am Acad Dermatol* 1987;17:584-91.
12. Soyer HP, Smolle J, Hödl S, Kresbach H, Glavanovitz P, Pachernegg H, et al. Surface microscopy: a new approach to the diagnosis of cutaneous pigmented tumors. *Am J Dermatopath* 1989;11:1-10.
13. Kenet RO, Kang S, Kenet BJ, Fitzpatrick TB, Sober AJ, Barnhill RL. Clinical diagnosis of pigmented lesions using digital epiluminescence microscopy: grading protocol and atlas. *Arch Dermatol* 1993;129:157-74.
14. Payne PA. Applications of ultrasound in dermatology. *Bioeng Skin* 1985;1:293-320.
15. Shafir R, Itzchak Y, Heyman Z, Azizi E, Tsur H, Hiss J. Preoperative ultrasonic measurements of the thickness of cutaneous malignant melanoma. *J Ultrasound Med* 1984;3:205-8.
16. Dines KA, Sheets PW, Brink JA, Hanke CW, Condra KA, Clendenon JL, et al. High frequency ultrasonic imaging of the skin: experimental results. *Ultrason Imaging* 1984;6:408-34.
17. Payne PA. Ultrasonic methods for skin characterization. *Bioeng Skin* 1987;3:347-57.
18. Cascinelli N, Ferrario M, Tonelli T, Leo E. A possible new tool for clinical diagnosis of melanoma: the computer. *J Am Acad Dermatol* 1987;16:361-7.
19. White R, Rigel DS, Friedman RJ. Computer applications in the diagnosis and prognosis of malignant melanoma. *Dermatol Clin* 1991;9:695-702.
20. Perednia DA, Gaines JA, Rossum AC. Variability in physician assessment of lesions in cutaneous images and its implications for skin screening and computer-assisted diagnosis. *Arch Dermatol* 1992;128:357-64.
21. Moss RH, Stoecker WV, Lin S. Skin cancer recognition by computer vision. *Comput Med Imag Graph* 1989;13:31-6.
22. Cascinelli N, Ferrario M, Bufalino R, Zurrida S, Galimberti V, Mascheroni L, et al. Results obtained by using a computerized image analysis system designed as an aid to diagnosis of cutaneous melanoma. *Melanoma Research* 1992;2:163-70.
23. Green A, Martin N, McKenzie G, Pfitzner J, Quintarelli F, Thomas BW, et al. Computer image analysis of pigmented skin lesions. *Melanoma Research* 1991;1:231-6.
24. Perednia DA, White RG, Schowengerdt RA. Localization of cutaneous lesions in digital images of skin. *Comput Biomed Res* 1989;22:374-92.
25. Voigt H, Claßen R, Müller RHG, Fränz TH, Ramaker J. Topodermatography: Computerized quantitative bidimensional assessment of melanoma precursors (dysplastic nevi) and metastatic skin deposits using high-resolution image analysis. *Tumor Diagnostik & Ther* 1994;15:27-31.
26. Foley JD, van Dam A. *Fundamentals of interactive computer graphics*. Reading (MA): Addison Wesley, 1982.
27. Rosenfeld A, Kak A. *Digital picture processing*. New York: Academic Press, 1982.
28. Serra J. *Image analysis and mathematical morphology*. London: Academic Press, 1982.
29. Jähne B. *Digital image processing*. Berlin: Springer-Verlag, 1991.
30. White RG, Perednia DA, Schowengerdt RA. Automated feature detection in digital images of skin. *Comput Methods Prog Biomed* 1991;34:41-60.
31. Golston JE, Moss RH, Stoecker WV. Boundary detection in skin tumor images: an overall approach and a radical search algorithm. *Pattern Recognition* 1990;23:1235-47.
32. Perednia DA, White RG. Automatic registration of multiple skin lesions by use of point pattern matching. *Comput Med Imag Graph* 1992;16:205-16.
33. White RG, Perednia DA. Automatic derivation of initial match points for paired digital images of skin. *Comput Med Imag Graph* 1992;16:217-25.
34. Holly EA, Shpall SN, Schneider J, Kelly JW, Friend N. Total body nevi count and other risk factors for melanoma. *Prev Med* 1986;15:705-10.
35. Holly EA, Kelly JW, Shpall SN, Chiu SH. Number of melanocytic nevi as a major risk factor for malignant melanoma. *J Am Acad Dermatol* 1987;17:459-68.