

Total-Body Photographs of Dysplastic Nevi

William Slue; Alfred W. Kopf, MD; Jason K. Rivers, MD, FRCPC

• A method of taking total-body photographs to document dysplastic nevi is described. A set of 24 views is taken. These 35-mm color slide transparencies are projected onto a rearview screen at the time of subsequent follow-up examinations. A comparison between the baseline photographs and the current clinical findings allows the physician to detect thin malignant melanomas in a curable stage.

(*Arch Dermatol* 1988;124:1239-1243)

Dysplastic nevi (DN) are both potential precursors of malignant melanomas (MMs) and markers for melanoma-prone individuals.^{1,2} This information has afforded the opportunity for the medical profession to identify a subset of the population at increased risk to develop this potentially fatal cutaneous neoplasm.⁴ There is a substantial body of data which indicates that, when fully resected, "early" MM (ie, thin by the Breslow measurement) has an excellent prognosis.⁵ Thus, the challenge is to identify in patients with DN those lesions that are suspicious for MM. This may pose a dilemma to the attending physician since DN often present as a constellation of widespread lesions whose number may reach into the hundreds.^{6,7} Clearly, the focus on following up such patients with DN is to identify those nevocytic nevi that acquire the clinical characteristics of MM, as well as those lesions that have recently appeared de novo on clinically unaffected skin.

Accordingly, clinicians managing patients with DN concur that regular follow-up, with total cutaneous examinations aided by baseline photographs, are very useful in caring for these individuals.^{6,8-13} To our knowledge, there has been only one previous detailed publication regarding the technique of taking total-body photographs.¹⁴ The purpose of this brief communication is to describe a different photographic method developed by the Photography Section of the Department of Dermatology at New York University Medical Center (New York City).

MATERIALS AND METHODS

A series of 23 photographs is taken using a standardized lens/skin distance of 2.5 ft. A millimeter ruler is included

in one of these photographs, which establishes a precise measurement of all lesions in all photographs. In addition, a 1:1 photograph (in which the image in the color transparency is life-size) is obtained of the largest or most unusual DN. A millimeter paper ruler is placed next to this nevus so that it is included in the close-up photograph. The order in which the photographs are taken follows the same sequential steps used for routine physical examination of the patient at follow-up visits (Table), with the exception of the scalp, posterior ears, external genitalia, perianal area, palms, and soles, ie, sites that are not easily photographed.

The film used is 35-mm Kodachrome 25 (Eastman Kodak), and the camera used for obtaining 23 of the 24 photographs is a Nikon with a 55-mm macro lens. For the close-up photography, this camera and lens combination can create a 1:2 image, that is, an image half the actual size of the lesion. To create a 1:1 image the camera is fitted with a 105-mm Micronikkor lens (Nikon) with a Pn11 extension tube (Fig 1). This results in an image on the film that is the exact size of the lesion.

It is suggested that the photographs be taken by a medical photographer, if possible. Studio lighting is used with a seamless backdrop (blue preferred). The seamless backdrop eliminates distracting clutter in the background, allowing the images to stand out. Studio lighting is necessary for uniform illumination of the subject and allows for repeated views to be taken quickly, since there is virtually no delay in recycling the lights. Since the patient is totally unclothed during the session, it is important to take the photographs as expeditiously as possible. Along with the fast recycling time of the studio lights, a motor drive is attached to the camera. This helps speed the photography session. With practice, an entire series of photographs can be taken in under three minutes. Figure 2 illustrates the series of views taken with the technique described, and Fig 3 is an actual set of such photographs.

The 35-mm color transparencies are numbered sequentially in the order in which they are viewed at the time of total cutaneous examination. These photographs are stored as a set in dust-free, plastic boxes (Zephyr Duofile [Model No. G-1], available from D. M. Carlick, New York City) manufactured for this purpose (Fig 4).

The set of total body photographs is usually taken only once, but may be repeated if the situation warrants (eg, before and after puberty). In addition, new photographs are obtained if, with time, the originals fade in quality.

COMMENT

At the time of follow-up visits, the set of photographs is reviewed sequentially. A convenient method is to use a rearview projector, such as the Kodak Ektagraphics 460, which can be used in a fully lighted room (Fig 4). Thus, as each anatomic area is examined, the corresponding baseline photograph is viewed. It is important to emphasize that, in addition to the body sites photographed, the entire cutaneous

Accepted for publication Jan 19, 1988.

From the Department of Dermatology, New York University School of Medicine, and the Skin and Cancer Unit, University Hospital, New York University Medical Center.

The results and conclusions are those of the authors, and no official endorsement by the Ontario Ministry of Health (Toronto) is intended or inferred.

Reprint requests to Oncology Section, Department of Dermatology, New York University Medical Center, 562 First Ave, New York, NY 10016 (Dr Kopf).

Anatomic Sites for Total-Body Photographs

Lateral right aspect of the face and the neck (includes top of right shoulder)
 Anterior aspect of the face and the upper-most chest
 Lateral left aspect of the face and the neck (includes top of left shoulder)
 Posterior aspect of the right arm
 Posterior aspect of the right forearm and the hand
 Lateral right aspect of the thorax, arm raised*
 Anterior upper aspect of the thorax
 Anterior right lower aspect of the thorax
 Anterior left lower aspect of the thorax
 Posterior aspect of the left arm
 Posterior aspect of the left forearm and the hand
 Lateral left aspect of the thorax, arm raised*
 Lateral aspect of the right thigh
 Anterior aspect of the thighs*
 Lateral aspect of the left thigh
 Lateral aspect of the right leg
 Anterior aspect of the legs
 Lateral aspect of the left leg
 Posterior upper aspect of the thorax
 Posterior left lower aspect of the thorax
 Posterior right lower aspect of the thorax
 Posterior aspect of the thighs*
 Posterior aspect of the legs
 Close-up view, with ruler, of selected largest or most atypical lesion

*For tall or obese patients, this area may require two photographs.

surface should be examined, including nonphotographed areas such as the scalp, intertriginous areas, and the anogenital region. Generally, these areas (which are not sun-exposed) have relatively few nevocytic nevi and, therefore, can be monitored more readily by direct visual inspection. The 24 photographs are kept as a "set" that can be conveniently stored in standard opaque plastic containers. Experience has shown that combining photographic review and clinical examination facilitates clinical recognition of significant changes (ie, those suggestive of MM), whether such changes occur in DN or de novo. Those lesions that remain quiescent and unchanged are followed up and are not removed unless there is some other indication (eg, symptoms).

The patient is also given the option to obtain a personal set of 8×10-in color enlargements for self-examination of the skin.¹⁵ These are created from the same 35-mm color transparencies that are used for rearview projection purposes.

A set of photographs will last for years, but some fading can eventually occur, at which time a new set is required. There has been no need to take photographs on an annual basis as recommended by some,¹⁶ unless the patient is developing a number of new lesions that require documentation.

In addition to the standardized set of 24 photographs, other unusual DN are sometimes documented by close-up photography that renders one-to-one (life-size) images. Photographic equipment for this purpose is readily available, affordable, and easily mastered by any physician or assistant. Polaroid cameras are easier to use for close-up pictures, but, the quality of Polaroid photographs is not



Fig 1.—At left is Nikon camera fitted with motor drive and 55-mm macro lens. This unit is used for 23 of 24 photographs. At right are Micronikkor (Nikon) 105-mm lens and Pn11 extension tube that are used for photographing the 1:1 image.

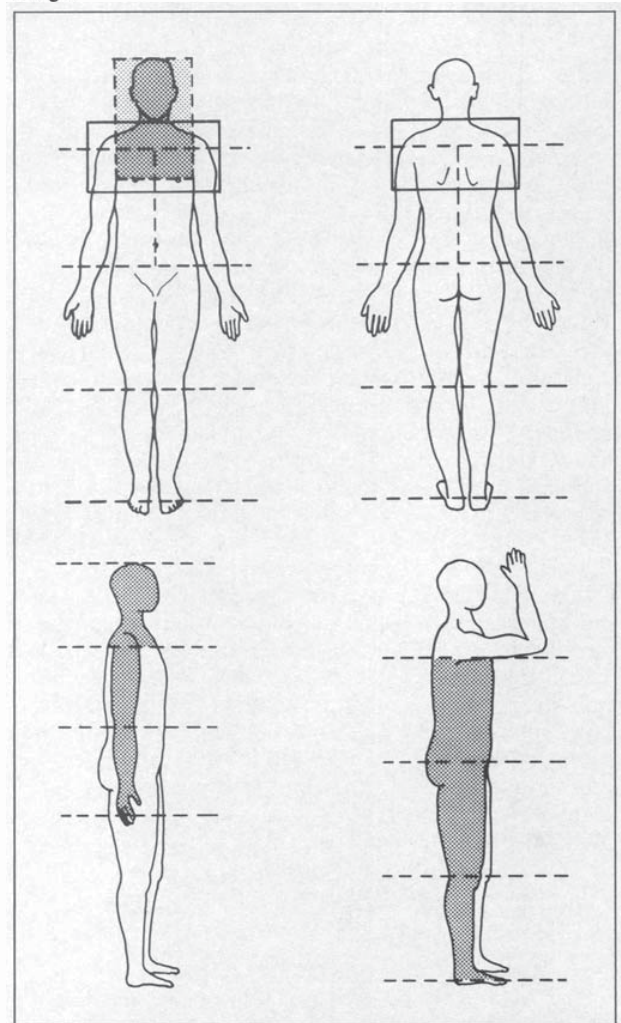


Fig 2.—Illustrations of different views taken for total-body photographs. Sites photographed are bound by dotted lines or solid-line rectangles. Top, On anterior and posterior surfaces of body, all demarcated areas (shaded and unshaded) are photographed. Bottom, On lateral aspects of body, only shaded areas are photographed.

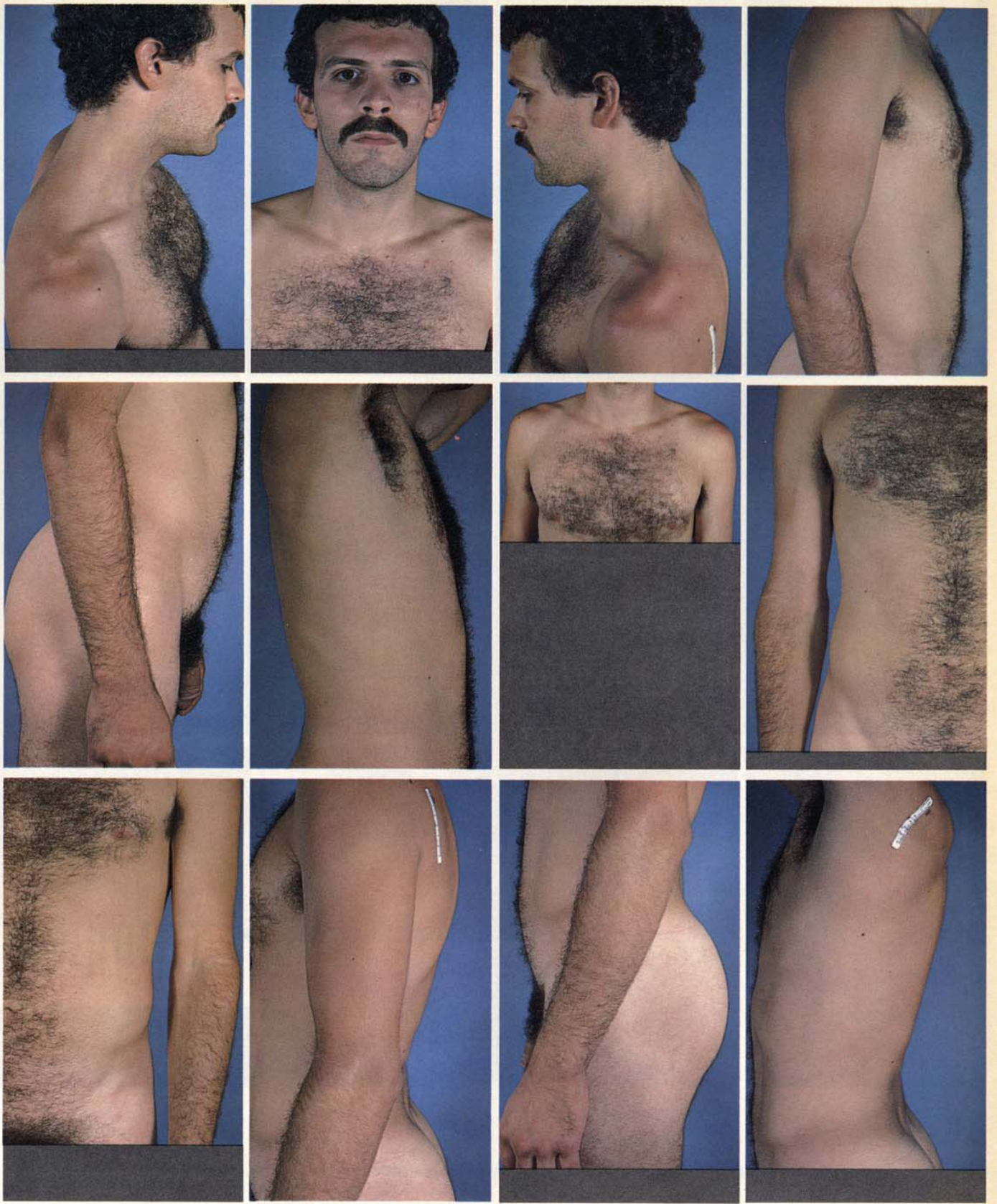

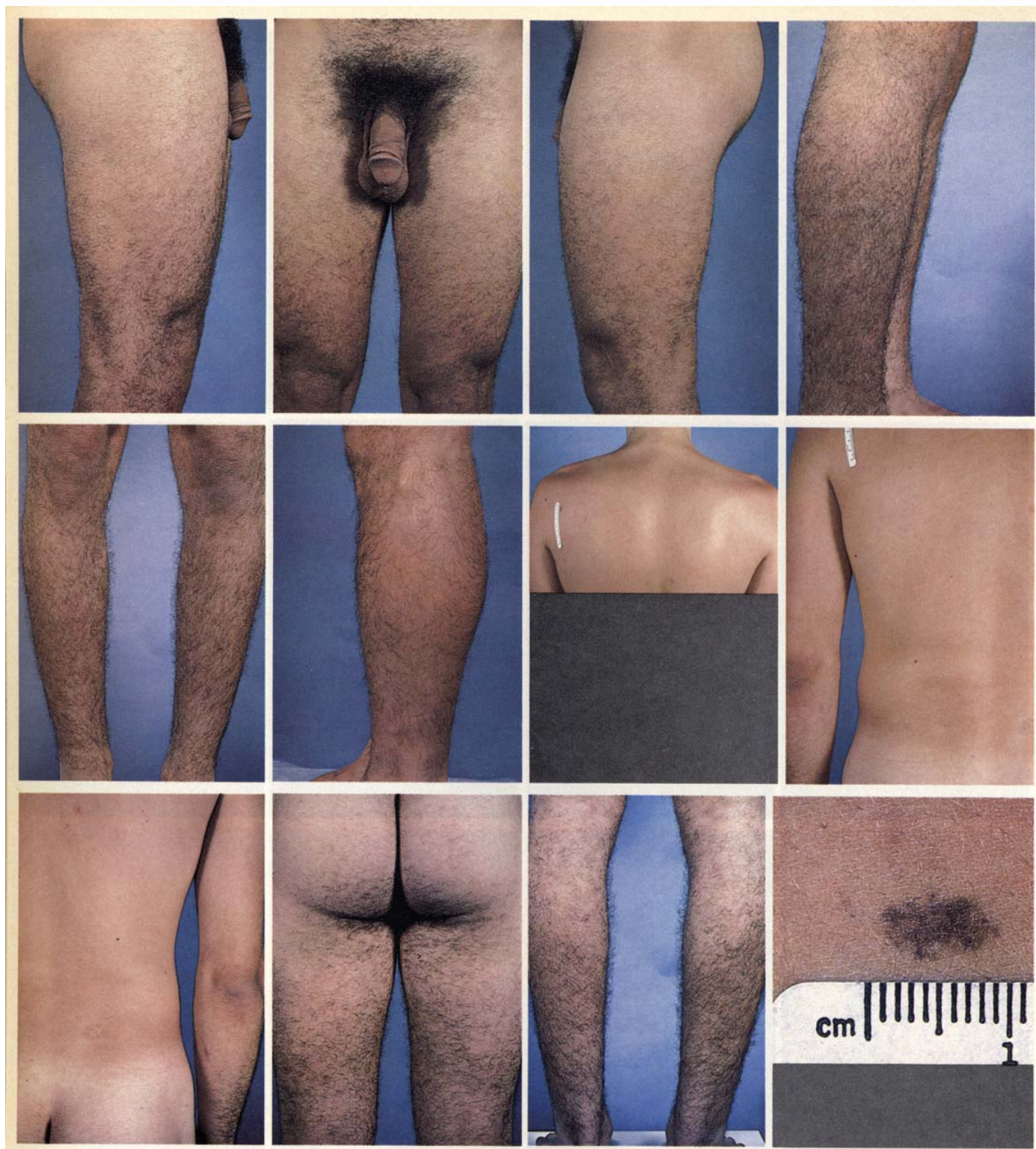


Fig 3.—Series of total-body photographs. Photographs in middle row, right center, are reduced.

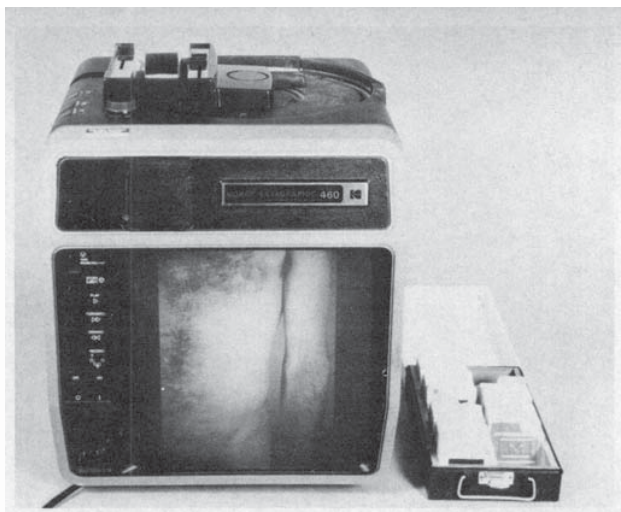


Fig 4.—Kodak Ektagraphic 460 viewer projector with stack loader. To right is storage container for set of slides.

comparable with the resolution provided by 35-mm color transparencies. Polaroid photographs are supplemented to our standardized series of total body photographs when an instant picture is required for the medical record, eg, before excisional biopsy of a pigmented lesion. This is done especially if the patient has been referred to another physician for removal of the lesion. Having a Polaroid photograph allows the surgeon to know exactly which lesion is to be excised.

In our experience, it has been possible to identify early MMs in patients with DN by this method of total-body photography and periodic examinations. Soon to be published are the results of following up 452 patients with DN by this method. A total of 16 (3.5%) of these 452 individuals developed MM during an average of 26 months of follow-up. This is greater than three times the expected lifetime risk for developing MM in whites in the United States. Ten of the 16 MMs identified on physician examination were level I (MM in situ) lesions; the remaining MMs were between 0.1 and 0.88 mm in thickness. Therefore, the anticipated cure rate of these 16 MMs should approach 100%. It should be noted that in this study only one of the 16 newly diagnosed MMs was identified by the patient, despite the fact that each patient had been instructed on self-examination of the skin and had been provided with illustrated literature on the early detection of MM. The other 15 lesions were suspected and identified by the examining physician using total-body photographs as comparison. Most of these MMs had been present on the baseline photographs and were initially diagnosed to be DN. Removal of a particular lesion was done only because the lesion had changed relative to the baseline photographs.

This method of photographic documentation of the skin allows the physician to objectively decide if a specific lesion has changed when a patient believes it has. Based on the patient's hearsay, and without photodocumentation, the physician may be inclined

to remove such a lesion, which would not be cost effective.

In sum, total-body photographs have been found most useful in the identification of thin MMs in patients who have DN, when used in conjunction with regular total cutaneous examinations by the attending physician, and patient education in the art of self-examination of the skin. The same, or modified, technique can be used for the photodocumentation of patients with other cutaneous diseases who are at an increased risk for the development of cutaneous cancers (eg, xeroderma pigmentosum and the nevoid basal cell carcinoma syndrome).

This work was supported by the Melanoma Funds and the Academic Incentive Fund of the New York University School of Medicine, Department of Dermatology; The David A. Leinbach Memorial Melanoma Fund and the Niarchos Fund of the Skin Cancer Foundation (New York City); New York University Cancer Center (Core Support grant No. P30 CA-16087); National Cancer Institute (Bethesda, Md) grant No. 2 R01 CA 1366-05; the Rudolf L. Baer Foundation for Diseases of the Skin (New York City); National Institute of Occupational Safety and Health (Bethesda, Md) grant No. R01 OH00915; the Department of Energy grant No. EY-76-C-02-3077; and the Ontario Ministry of Health, Toronto.

References

1. Greene MH, Clark WH, Tucker MA, et al: High risk of malignant melanoma in melanoma-prone families with dysplastic nevi. *Ann Intern Med* 1985;102:458-465.
2. Rhodes AR, Harriest TJ, Day CL, et al: Dysplastic melanocytic nevi in histologic association with 234 primary cutaneous melanomas. *J Am Acad Dermatol* 1983;9:563-574.
3. Clark WH, Elder DE, Guerry D, et al: A study of tumor progression: The precursor lesions of superficial spreading and nodular melanoma. *Hum Pathol* 1984;15:1147-1165.
4. Kraemer KH, Greene MH: Dysplastic nevus syndrome: Familial and sporadic precursors of cutaneous melanoma. *Dermatol Clin* 1985;3:225-237.
5. Rogers GS, Kopf AW, Rigel DS, et al: Hazard-rate analysis in stage I malignant melanoma. *Arch Dermatol* 1986;122:999-1002.
6. Greene MH, Clark WH, Tucker MA, et al: Acquired precursors of cutaneous malignant melanoma. *N Engl J Med* 1985;312:91-97.
7. Lynch HT, Fusaro RM, Treger CL, et al: The cutaneous evolution of nevi in a patient with familial, atypical, multiple-mole melanoma syndrome. *Pediatr Dermatol* 1985;2:289-293.
8. Koh HK: The patient with a pigmented lesion. *Hosp Pract* 1986;21:47-54.
9. Greene MH, Clark WH, Tucker MA, et al: Managing the dysplastic naevus syndrome. *Lancet* 1984;1:166-167.
10. Rhodes AR: Acquired dysplastic melanocytic nevi and cutaneous melanoma: Precursors and prevention. *Ann Intern Med* 1985;102:546-548.
11. Kelly JW, Crutcher WA, Sagebiel RW: Clinical diagnosis of dysplastic melanocytic nevi. *J Am Acad Dermatol* 1986;14:1044-1052.
12. Mysliborski JA: The dysplastic nevus syndrome. *Compr Ther* 1986;12:17-22.
13. Crutcher WA, Sagebiel RW: Prevalence of dysplastic naevi in a community practice. *Lancet* 1984;1:729.
14. Atkinson JM, From L, Boyer R: A new method of photodocumentation for the follow-up of dysplastic naevi. *J Audiovis Media Med* 1987;10:12-14.
15. Friedman RJ, Rigel DS, Kopf AW: Early detection of malignant melanoma: The role of physical examination and self-examination of the skin. *CA* 1985;35:130-151.
16. Elder DE, Greene MH, Bondi EE, et al: Acquired melanocytic nevi and melanoma: The dysplastic nevus syndrome, in Ackerman AB (ed): *Pathology of Malignant Melanoma*. New York, Masson Publishing USA Inc, 1981, p 210.