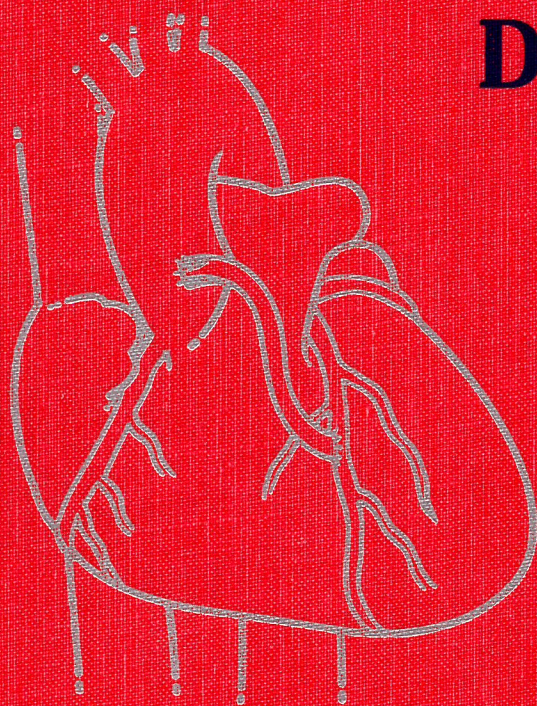


PRACTICAL ANGIOPLASTY

David P. Faxon
Editor



RAVEN PRESS

Practical Angioplasty

Editor

David P. Faxon, M.D.

Section of Cardiology

The University Hospital

Boston University Medical Center

Boston, Massachusetts 02118

Raven Press  New York

Raven Press, Ltd., 1185 Avenue of the Americas, New York, New York 10036

© 1994 by Raven Press, Ltd. All rights reserved. This book is protected by copyright. No part of it may be reproduced, stored in a retrieval system, or transmitted, in any form or by any means, electronic, mechanical, photocopy, or recording, or otherwise, without prior written permission of the publisher.

Made in the United States of America

Library of Congress Cataloging-in-Publication Data

Practical angioplasty/edited by David P. Faxon.

p. cm.

Includes bibliographical references and index.

ISBN 0-7817-0084-1

1. Angioplasty. I. Faxon, D. (David)

[DNLM: 1. Angioplasty. 2. Coronary Disease—surgery. WG 300

P8945 1993]

RD598.5P68 1993

617.4'13—dc20

DNLM/DLC

for Library of Congress

93-18672
CIP

The material contained in this volume was submitted as previously unpublished material, except in the instances in which credit has been given to the source from which some of the illustrative material was derived.

Great care has been taken to maintain the accuracy of the information contained in the volume. However, neither Raven Press nor the author can be held responsible for errors or for any consequences arising from the use of the information contained herein.

Materials appearing in this book prepared by individuals as part of their official duties as U.S. Government employees are not covered by the above-mentioned copyright.

9 8 7 6 5 4 3 2 1

CHAPTER 6

Selection of Guiding Catheters

Alice K. Jacobs

Since the advent of percutaneous transluminal coronary angioplasty (PTCA), the rapid expansion in technology has resulted in a dramatic increase in the number of available guiding catheters used to perform the procedure. With various sizes and shapes of guides to choose from, it is important to select the catheter which is most likely to result in a successful procedure and least likely to result in an associated complication. This selection process should be based upon a specific set of guidelines and principles and the information obtained from the diagnostic angiogram.

FUNCTION OF THE GUIDING CATHETER

The early guides were hollow tubes made of Teflon, tended to buckle, were difficult to manipulate, and had little ability to hold a specific shape. Therefore, they functioned only as a conduit. The overall trend in guides has gone from the larger French and stiffer catheters to smaller size, softer catheters, with larger internal lumens. With the expansion and change in equipment, the basic functions of the guiding catheter have evolved. Currently, guiding catheters form an integral part of the dilatation system.

First, to perform adequately, the guiding catheter must be able to selectively engage the ostium of the coronary artery without occluding arterial inflow. Although catheter damping is less frequently an issue in the left coronary artery, it can be problematic in the ostium of the right coronary artery. The introduction of side holes in the catheter shaft which allow continuous perfusion despite wedged engagement of the catheter has provided a partial solution to this problem.

Second, the guiding catheter functions to deliver contrast agent into the coronary artery so as to visualize the

target lesion as well as side branches. With the use of selective digital angiography to provide a "road-map" of the artery, guiding catheter contrast injection can be used less frequently. However, with the trend toward smaller-profile balloon dilatation catheters and fixed-wire dilatation catheters which preclude the use of distal contrast injections, guiding catheter injections are essential. The smaller balloon catheters and larger lumen guides optimize the angiography.

Perhaps the most important function of the guiding catheter is to provide adequate support for advancement of the dilatation catheter across the lesion. This support is obtained by deep engagement of the guiding catheter into the coronary ostium, buttressing of the catheter against the opposite aortic wall and from the intrinsic stiffness of the guiding catheter material. Although steerable guidewires and low-profile dilatation catheters have made guiding catheter support less critical in some situations, the expansion of the practice of PTCA to include distal lesions in tortuous and calcified vessels necessitates optimal support from the guiding catheter. The features of an ideal guiding catheter are listed in Table 1.

STRUCTURE OF THE GUIDING CATHETER

The guiding catheters consist of a shaft; a soft tip, which may be tapered; a radiopaque tip marker; and a hub which connects the catheter to the manifold system. The shaft of the catheter is composed of three layers: an inner Teflon lining to reduce friction between the guiding and the dilatation catheters; a mid-layer made of either epoxy and fiber braid, or a wire braid, to permit torque control; and an outer layer of polyethylene or polyurethane to provide stiffness and ability to retain preformed shape (memory) (1). In general, the "stiffer" the catheter, the better is the support, the faster is the torque response, and the more difficult is the deep seating in the coronary ostium. A longitudinal section of a representative guiding catheter is illustrated in Fig. 1.

A. K. Jacobs: Section of Cardiology, The University Hospital, Boston University Medical Center, Boston, Massachusetts, 02118

TABLE 1. Ideal guiding catheter characteristics

Easy to seat
Large lumen to deliver adequate contrast for visualization with multiple balloon systems
Coaxial engagement to maximize backup and flow, and to direct balloon into artery
Deliver accurate pressure readings
Atraumatic to coronary arteries
Small enough to subselect coronary arteries
Nonthrombogenic
Radiopaque for accurate placement
Lubricious lumen for easy balloon/wire movement
Curve retention for back-up support

TYPES OF GUIDING CATHETERS

Almost all of the coronary catheters used for diagnostic angiography (both femoral and brachial approach) are available as guiding catheters. The more commonly used catheter shapes are shown in Fig. 2. The femoral guiding catheter is 100 cm long and has a 7, 8, or 9 French outside diameter. The brachial catheter is 90 cm long and has a 9 or 8.3 French outside diameter. The inner diameter of these catheters ranges between 0.066 and 0.092 in. The soft (and occasionally tapered) tip permits larger body catheters with increased support and flow to be combined with softer tips which reduce the risk of trauma at the coronary ostium and allow deeper intubation. The guiding catheters in routine use are shown in Table 2.

Overall, there has been a trend toward reducing the size of the guiding catheters (2). The rationale for performing coronary angioplasty with smaller diameter catheters is based on the potential advantages. Smaller

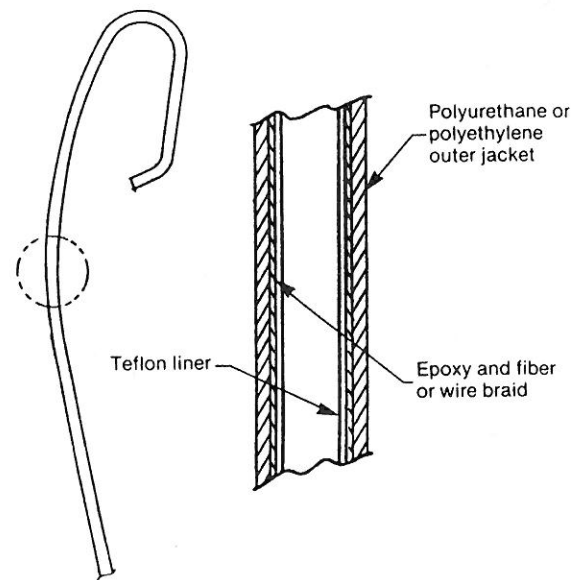


FIG. 1. Diagram of a longitudinal section of a representative guiding catheter. From Patterson et al. (7), with permission.

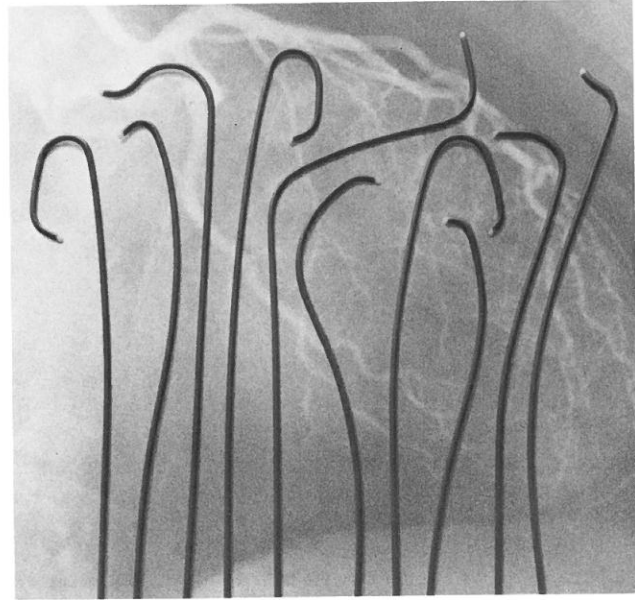


FIG. 2. The most frequently used guiding catheter curves. From left to right: left Judkins, left internal mammary, left Amplatz, left Judkins (smaller size), Arani, right bypass, left short-tip Judkins, right Judkins, hockey stick, right Amplatz.

catheters provide less pressure damping and injury to the coronary ostium, reduce the risk of vascular complications, especially in patients with peripheral vascular disease, and increase the possibility of early ambulation and hospital discharge (3). In addition, patient discomfort and arterial bleeding may be minimized due to the smaller arterial punctures. With the trend toward

TABLE 2. Femoral guiding catheters

Manufacturer	Available sizes			
	(Inner diameter, in)			
	9F	8F	7F	6F
ACS				
E.T. Hi-Flow		0.076		
Powerguide		0.080	0.070	
USCI				
Super 7			0.070	
Illumen - 8		0.080		
Illumen with flex guard		0.080		
Super 9	0.090			
Cordis				
XL Brite Tip		0.084		0.062
Brite Tip		0.078	0.072	
Medtronic				
Sherpa	0.092	0.079	0.070	
Giant Lumen	0.088	0.079	0.066	
Peak Flow		0.083		
SciMed				
Triguide		0.079	0.072	
Schneider				
Standard	0.080	0.076	0.063	
Visiguide		0.079		
Superflow	0.092	0.082	0.072	

smaller profile balloon dilatation catheters and fixed wire systems, the use of smaller guiding catheters is a logical and feasible strategy.

The concept of using small diagnostic catheters (5 and 6 French) for PTCA was first reported in 1989 (4). In a small series (5), early success rate was relatively low (79%). More recently, Feldman and colleagues (6) reported a 94% success rate in 154 patients using 6 French (6F) guiding catheters with 0.051-in lumens and 1.5 to 3.5-mm fixed-wire balloon dilatation catheters. These small guiding catheters have overcome some of the limitations of the diagnostic catheters used as guides. Resistance along the preformed curves, which is high in diagnostic catheters, is reduced in the Teflon- or silicon-coated guide. In addition, the catheter tip is not tapered, facilitating balloon-catheter movement and balloon removal.

However, the potential disadvantages of smaller size guiding catheters must be carefully considered. The lumen of these catheters is too small to permit optimal visualization or to permit the use of specialized equipment, such as stents or bail-out catheters which are necessary to manage procedure-related complications. When using a fixed-wire system which must be changed, access to the distal vessel cannot be maintained by use of a 4 French soft probe sheath since it will not pass through a 6 French guiding catheter. The ability to measure accurate pressure as well as to provide backup support is also reduced.

CATHETER SELECTION

General Considerations

There are several major anatomic determinants of the optimal approach to the procedure (brachial or femoral artery) and thereby the optimal guiding catheter. These include the degree of rotation of the ascending aorta and valve plane, the angulation of the proximal vessel from the ascending aorta, the origin of the innominate artery on the aortic arch, and the length of the aortic arch. There are three basic anatomic variations of the plane of the aortic valve, based on the angle of the valve plane with the horizontal plane. When viewed in the 30° left anterior oblique projection of the ascending aorta, the valve plane is either 0 to 30° (type I), 30 to 60° (type II),

or 60 to 90° (type III) (7), as shown in Fig. 3. In type II and III aortas, the brachial approach may be more advantageous because of a greater likelihood of a coaxial backup with a soft Stertzer brachial guiding catheter rather than with preformed guides from the femoral approach. Rarely, the angulation of the proximal vessel from the ascending aorta will influence the decision to use the brachial approach. Superior takeoff to the right coronary artery is best handled by the brachial approach, whereas inferior takeoff of the left main trunk is better approached from the femoral artery. When the innominate artery inserts more distally on the aortic arch, such as in long-standing hypertension, the advantages of the brachial approach are negated. In general, as the length of the aortic arch increases, so does the ease of femoral coaxial guiding catheter intubation.

In general, the major advantages of the brachial approach include (i) vascular access when limited by peripheral vascular disease or previous vascular surgery, (ii) improved ability to deal with specific anatomic variants (ostial left internal mammary artery stenoses, anomalous coronary artery location), (iii) improved control at the ostium of the vessel by easier torque control from the arm, particularly in the right coronary artery, and (iv) early removal of the catheter at completion of the procedure with early ambulation and potential hospital discharge. Currently, it is estimated that approximately 10% of angioplasty procedures are either more easily performed or can only be performed via the brachial approach. Most femoral guiding catheters can be used via the brachial artery.

The selection of a specific guiding catheter should be based upon several factors, the most important of which are listed in Table 3. When studying the diagnostic angiogram, careful consideration should be given to the takeoff of the proximal coronary artery from the ascending aorta and to the relationship between the diagnostic catheter and the coronary orifice. The coronary guiding catheters in general, however, can be expected to have a more gentle curve and have a shorter tip than their diagnostic counterparts.

In addition, the size and shape of the aorta, the amount of backup support needed, the length of the left main trunk, and the location of the coronary ostium are important considerations. In general, the more dilated the aorta, the more potentially problematic adequate guide support will be. The need for backup support in-

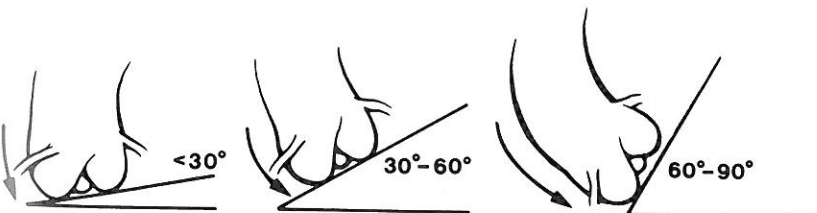


FIG. 3. Diagram of the three aortic valve plane orientations. From George et al. (7), with permission.

TABLE 3. Guiding catheter selection factors

Size and/or shape of aorta
Location of ostium
Angle of takeoff
Amount of backup support needed
Length of left main

creases in small, diffusely diseased vessels, calcified lesions, distal lesions, and lesions distal to vessel tortuosity. Backup support is facilitated by larger and stiffer guiding catheters. Short left main trunks enhance selective left coronary circumflex (LCX) or left anterior descending (LAD) coronary artery intubation whereas long left main trunks may necessitate Amplatz-type guides for lesions located in the left circumflex artery, depending on the angle of take-off from the aorta. Anomalous origins of the coronary ostia are best served by non-Judkins-type guides.

Insignificant ostial coronary artery lesions, particularly when not intended for dilatation, can be especially problematic. In either the right or left coronary artery, it is preferable to use smaller guiding catheters so as to decrease the chance of occluding arterial inflow. In addition, it is wise to choose a system which is less likely to require any backup support, such as a fixed-wire balloon dilatation catheter. In the right coronary artery, arterial inflow can be enhanced and pressure damping can be reduced with the addition of side holes to the shaft of the catheter. Side holes, however, impair adequate visualization. In the left coronary artery, although theoretically side holes would provide the same benefit, the risk of decreasing flow to the left coronary system despite maintaining normal guiding catheter pressure, may substantially increase the risk of the procedure. With any approach, it should be recognized that ostial lesions may significantly increase the risk of a major complication. This risk should be carefully considered when choosing angioplasty as the revascularization strategy.

Once the catheter is chosen, it is also important to manipulate the guide in the coronary ostium to ensure proper fit, position, and potential for backup support prior to moving the balloon and wire system into the coronary artery. After the wire and balloon are manipulated, if the guiding catheter easily disengages from the ostium, and the necessity of guide support is anticipated, it is appropriate to change the guiding catheter prior to crossing the lesion with the wire. Once the wire traverses the lesion, and if the guiding catheter does not provide the support necessary for the balloon catheter to cross the lesion, there are several alternatives. First, exchanging the dilatation catheter for a smaller balloon catheter with a lower profile may be effective. Second, it is possible to exchange the guiding catheter for one with a different shape, but this is technically difficult (it is best to change the balloon catheter and guiding catheter together

because the smaller dilatation catheter can more effectively track the wire) and usually requires two operators. Third, the wire may be withdrawn and the entire system changed, but the chance of abrupt vessel closure (particularly in a stenosis greater than 90% ± thrombus) is increased.

Specific Considerations

Use of the Left Judkins Catheter

The left Judkins guiding catheter is most often used for PTCA of the left coronary artery. Depending on the size of the catheter and the maneuvers used, this guide can be used to approach lesions located in the LAD as well as in the LCX. To select the LAD, it is necessary to push the catheter forward in the ascending aorta, moving the secondary curve inferior and the tip superior. Once engaged in the ostium, rotation of the hub in a counterclockwise direction will direct the tip anterior and superior toward the LAD (Fig. 4). A slightly smaller catheter (L_{3.5} French in a normal size root or an L_{4.0} French in a dilated root) will help to orient the catheter tip toward the LAD as well (8).

The Judkins catheter, with its tip pointing superior, is not ideally suited for approach to the LCX, which is directed posterior and inferior at its bifurcation from the left main trunk. If the diagnostic study was performed with a Judkins catheter, the angiogram should be carefully reviewed with attention toward the direction of the

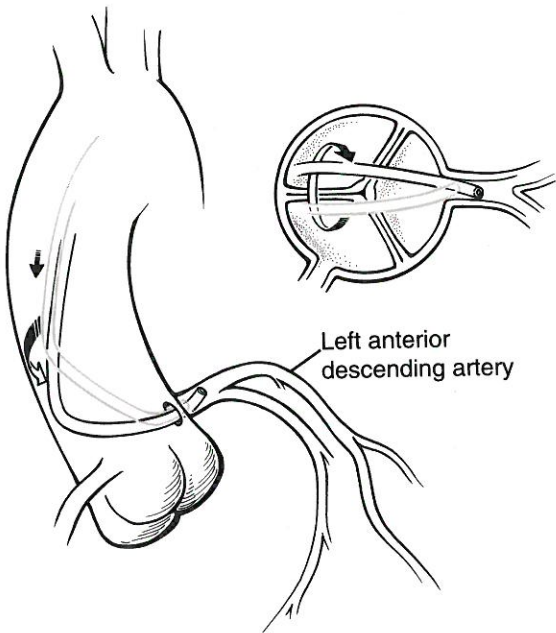


FIG. 4. Schematic view of the maneuver used to select the left anterior descending (LAD) artery with a Judkins catheter once the left main trunk is engaged. Counterclockwise rotation brings the heel of the catheter posterior and the tip anterior into the LAD.

catheter tip. To select the LCX, once the catheter is engaged in the left main trunk, it is necessary to pull the catheter back, directing the tip inferior. Rotation of the hub clockwise will direct the secondary curve anterior and the tip posterior toward the LCX ostium. A slightly larger guide (an L_{4.5} for a normal size root) or a short tip Judkins guide (Fig. 5) will also facilitate movement of the tip toward the LCX. Again, it is important to remember that the tips of the guiding catheters are slightly more relaxed in curve when compared to the same size diagnostic catheter. It is also possible to deep seat (or "Amplatz") the left Judkins catheter by a clockwise hub rotation and catheter advancement over the dilatation system (Fig. 6). This maneuver will provide backup support as well as facilitate entry into the LCX.

Use of the Right Judkins Catheter

As with the use of diagnostic catheters, seating of the right Judkins guide in the ostium of the right coronary artery (RCA) is performed by advancement of the catheter over the arch followed by clockwise hub rotation, which moves the tip anterior and inferior. As the tip drops, the catheter is pulled back, while rotating to engage the ostium. The R₄ French is the most frequently used catheter; occasionally R₅ French catheters are used in a dilated aorta or in an elongated arch. The advantages of the right Judkins catheter are that it is easy to seat and broadly applicable. However, unless deeply seated within the artery, it provides poor backup support (Fig. 7). It also provides poor cannulation of a superior takeoff from the sinus of Valsalva.

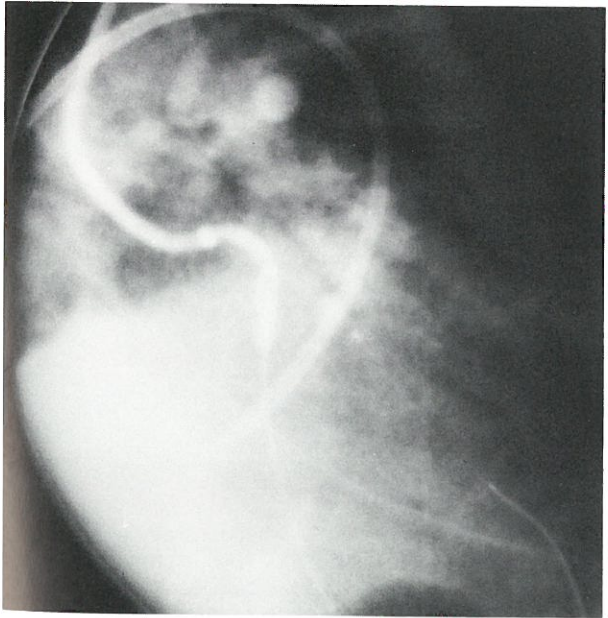


FIG. 5. Cineangiogram of a short-tip left Judkins catheter used to selectively engage the left coronary circumflex artery during PTCA.

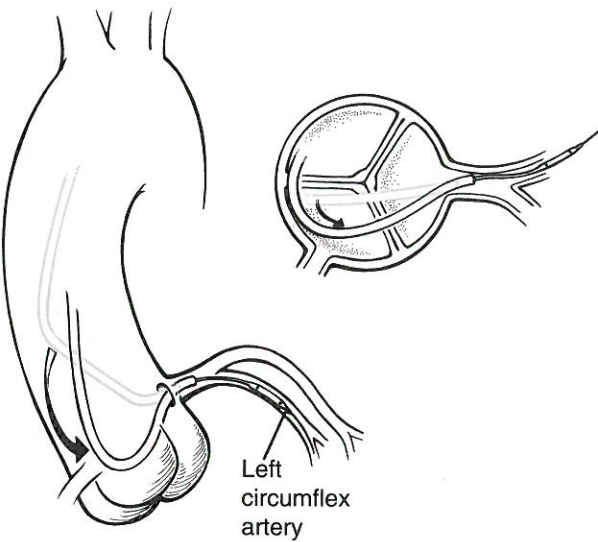


FIG. 6. Schematic view of the maneuver to "Amplatz" or selectively intubate the LCX with a Judkins guide. Once the guide is engaged in the left main trunk, clockwise rotation and advancement over the balloon dilatation system will turn the Judkins guide over into the left coronary circumflex artery.

Use of the Amplatz Catheter

The Amplatz curve can be used in the right or left coronary artery. When seated, the tip points inferiorly, making it suitable to select the LCX and to cannulate inferior takeoffs coaxially (Fig. 8). The guiding catheter

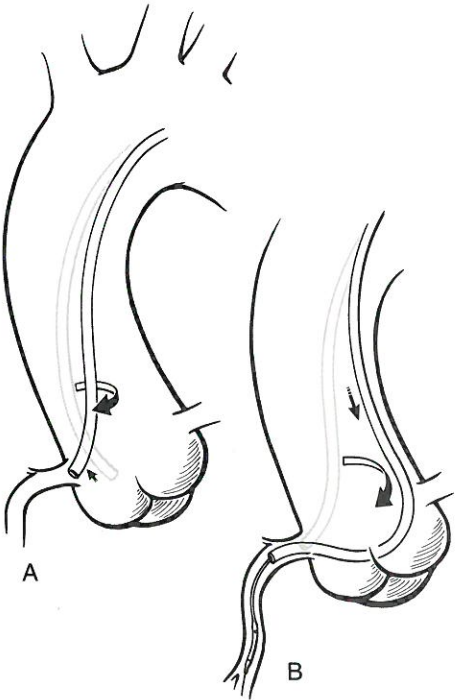


FIG. 7. Schematic view of the right Judkins guide engaged in the right coronary artery (left anterior oblique projection). Note the potential to actively intubate the proximal artery but the poor potential to buttress along the aortic wall.

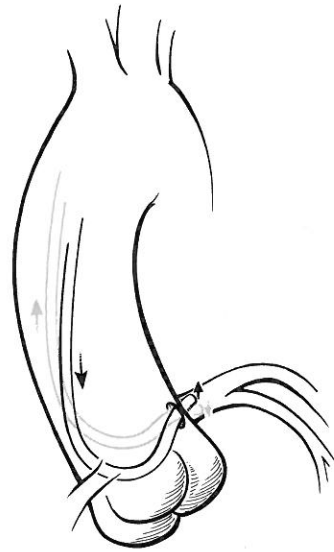


FIG. 8. Schematic view of the left Amplatz guide selectively engaged in the left coronary circumflex artery.

also has the potential to provide excellent support. The catheter is removed by advancing the shaft until the tip disengages the ostium into the aortic root. The catheter is then rotated and withdrawn. However, removal of the guiding catheter can be associated with risk; withdrawal of the catheter when the tip is engaged in the ostium facilitates movement into the coronary artery. In addition, deep intubation can create wedging and damping problems.

Technique of Deep Seating for Backup Support (Active Support)

Often, it is necessary to deep seat the guiding catheter in order to provide the necessary support (active support) to cross the lesion with the balloon dilatation catheter. This is known as "active support", whereby the guiding catheter facilitates balloon passage by advancing deeply into the coronary artery. Since this maneuver has the potential to injure the ostium of the coronary, it should be performed with soft-tip guiding catheters if possible. It is important that (i) the coronary be large enough to accept the guide, (ii) the proximal vessel be free of disease as well as excessive tortuosity, (iii) the coronary blood flow be maintained, and (iv) there be minimal resistance to the passage of the guide (9). Pressure should be monitored at the tip of the guiding catheter continuously. Pressure may damp for brief periods, but deep intubation should be performed with speed and caution. The guiding catheter should be advanced over the leading dilatation catheter to afford stabilization and tracking, in a push-pull fashion. The guidewire alone is less likely to provide support for advancement of the guiding catheter and the risk of injury to the coronary

intima would be higher. After the lesion is crossed with the balloon catheter, and following inflation of the balloon, the guide should be withdrawn. When effectively performed, deep seating of the guiding catheter provides optimal support (Fig. 9).

Buttressing the Catheter for Backup Support (Passive Support)

It is also often necessary to "bank" the guide along the opposite wall of the aorta to stabilize the catheter and provide optimal guide support (passive support with or without deep coronary intubation). This buttressing of the catheter may be facilitated by choosing a slightly oversized guide. Alternatively, a broad loop in the guid-

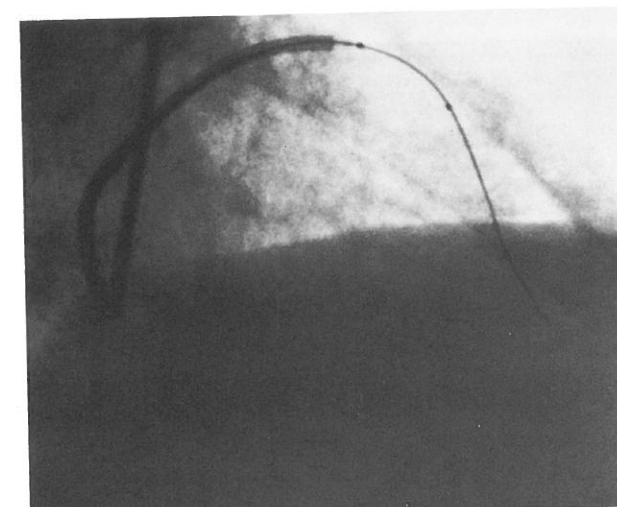
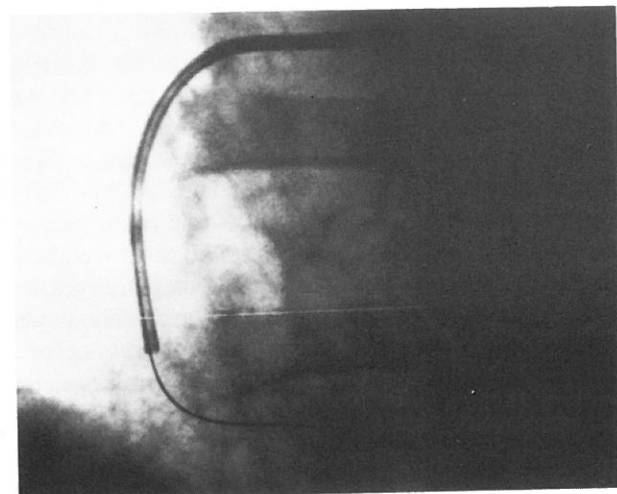


FIG. 9. Cineangiogram of active guiding catheter support. **A:** Note the deep intubation of the right coronary artery with the guiding catheter in the left anterior oblique projection. **B:** Note the deep intubation of the guiding catheter in the left anterior descending artery (over the dilating system) in the right anterior oblique projection. From George et al. (7), with permission.

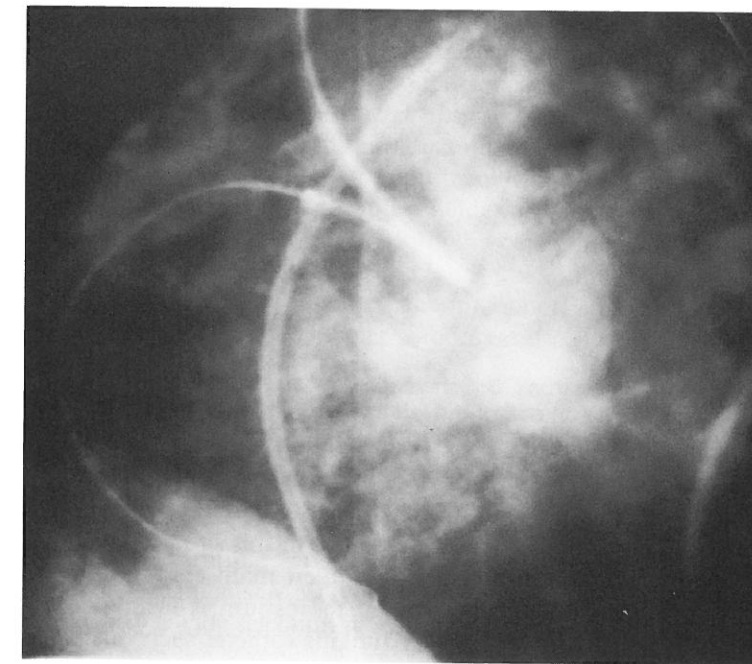


FIG. 10. Cineangiogram illustrating passive support of the guiding catheter in the right coronary artery ostium by buttressing it along the wall of the aorta.

ing catheter can be formed so as to support it against the opposite aortic wall or coronary sinuses. Once a stable loop has been formed, more pressure can be applied to the balloon catheter. This maneuver can be performed by using the Judkins (Fig. 10) or occasionally the Amplatz catheter by forceful rotation and simultaneous advancement of the guide over the dilatation catheter. However, it is more effectively performed by using a special catheter such as the Arani guide (Fig. 11).

Management of Damping

Pressure damping occurs when engagement of the guiding catheter into the ostium results in a reduction of arterial inflow. This occurs most often in the right coronary artery and in the setting of small caliber arteries or ostial lesions. If prolonged, the flow reduction can result in hypotension, bradycardia, and ventricular arrhythmias.

Management consists of using smaller guiding catheters (7 French), choosing a catheter with side holes to maintain coronary perfusion, and using a balloon dilatation system with a low profile so as to reduce the chance that backup support and deep seating of the guide will be necessary. If possible, once the coronary artery is instrumented with the guidewire and balloon catheter, the guiding catheter should be withdrawn and placed just outside the coronary ostium as often as possible throughout the procedure. It should be remembered, however, that pressure damping significantly increases the risk of the procedure.

APPROACH TO THE LEFT CORONARY ARTERY

The length of the left main coronary artery and the angle with which it takes off from the aorta are important factors in guiding catheter selection. The horizontal

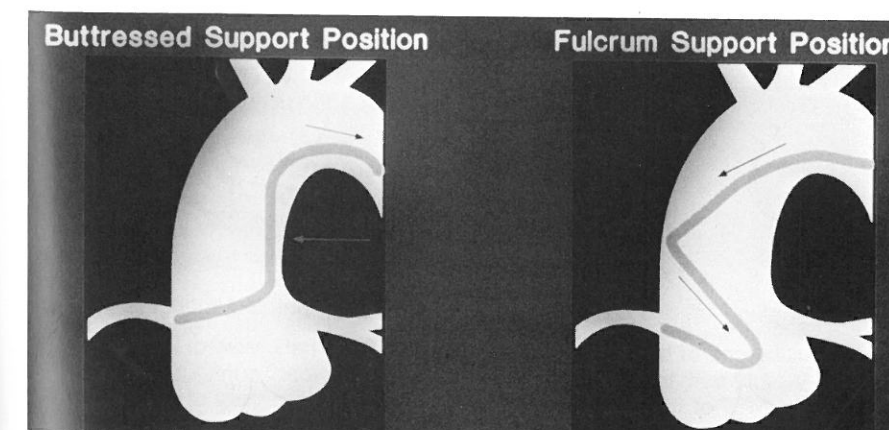


FIG. 11. Diagram of the Arani guiding catheter. Note both the fulcrum and buttress positions.

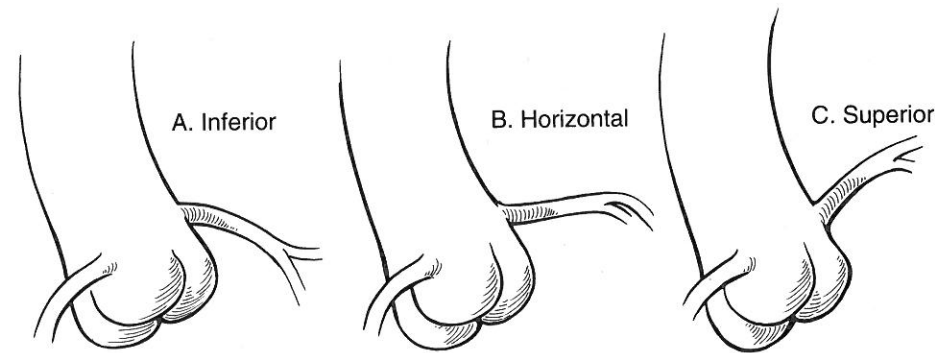


FIG. 12. A: Schematic view of an inferior takeoff of the left main trunk. B: Schematic view of a horizontal takeoff of the left main trunk. C: Schematic view of a superior takeoff of the left main trunk.

or lateral takeoff is most frequently encountered and is the least problematic (Fig. 12B). The horizontal takeoff can easily be approached with the Judkins or Amplatz guides appropriately sized for the aortic root. The Judkins guide is easy to engage and can be deep seated to provide active support. The Amplatz catheter provides excellent passive support and in a short left main, facilitates entry into the LCX. Even in a long left main where the LCX cannot be selectively cannulated, the inferior directed tip of the catheter (as opposed to the superior directed tip of the Judkins guide) is more favorable for

instrumentation of the LCX. Similarly, a short-tip left Judkins guide may be effective in this situation. For upward takeoff of the left main coronary artery (Fig. 12C), engagement of the ostium is facilitated by using a slightly smaller Judkins catheter such as an L_{3.5} French in a normal-sized root, particularly when the target lesion is located in the LAD. The most superiorly directed tip in the Judkins series is the interventional medical guiding catheter and it may be advantageous in this situation. Cannulation of a superiorly directed left main can also be accomplished with an Amplatz cath-

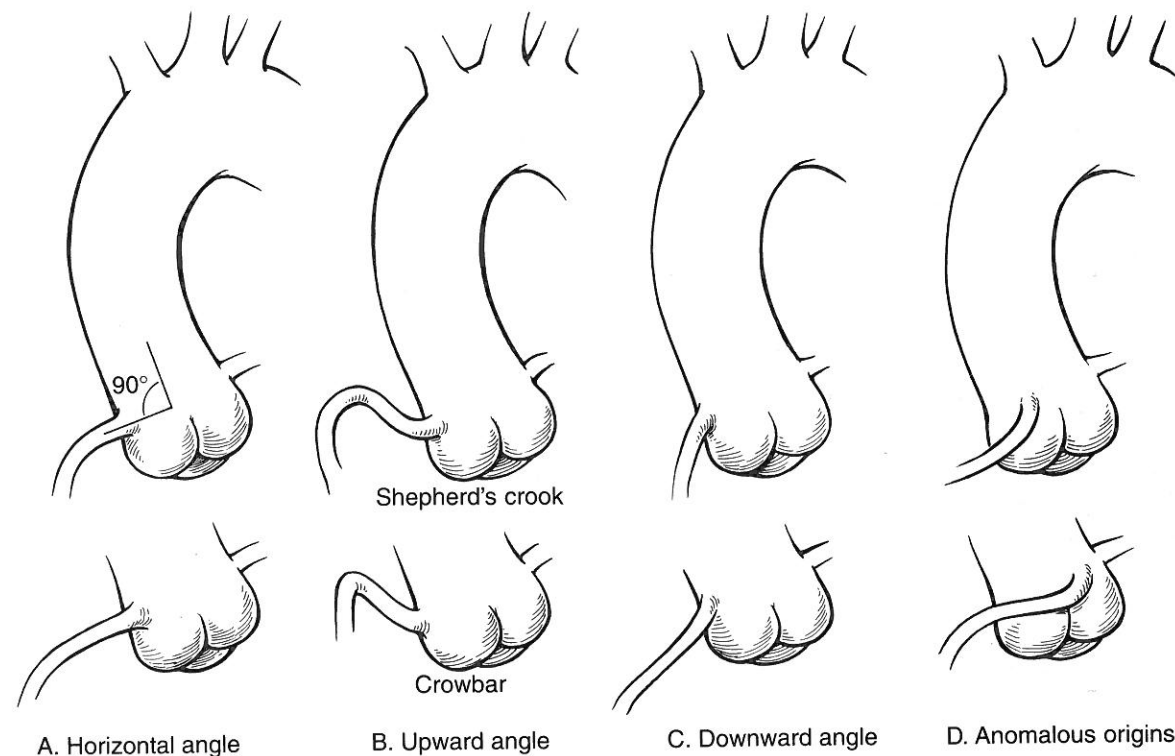


FIG. 13. A: Schematic view of a horizontal takeoff of the right coronary artery. B: Schematic view of an upward takeoff of the right coronary artery. Note both the "shepherd's crook" and "crowbar" configurations. C: Schematic view of a downward takeoff of the right coronary artery. D: Schematic view of an anomalous takeoff of the coronary artery.

eter, particularly if the catheter is advanced against the aortic sinus so as to allow the tip of the catheter to rise. In this situation, passive backup support may be less optimal. Superiorly directed catheter tips, such as the El Gamal (10) may be useful in this situation as well. Inferior takeoff of the left main trunk (Fig. 12A) can be approached using an Amplatz guide (tip points inferior when engaged) or an inferiorly directed guide such as a multipurpose catheter. The latter guide, however, provides suboptimal passive backup support unless a loop is created in the catheter to buttress it against the aortic wall.

APPROACH TO THE RIGHT CORONARY ARTERY

Approach to the RCA poses a different set of problems due to the multiple variations of the RCA origins and proximal segments. Most of these problems can be managed with a wide selection of available guiding catheters (11). There are several factors which can be examined when reviewing the angiogram prior to selection of the guiding catheter. These include the size and shape of the ascending aorta, the location of the RCA orifice in the sinus of Valsalva, the degree of anterior or posterior orientation, and the location and severity of the target lesions. Perhaps the most important factor determining guiding catheter selection, however, is the angle of the origin of the RCA and the length of the proximal segment.

Horizontal Angle

The horizontal or right-angle takeoff from the sinus of Valsalva is most frequently encountered (Fig. 13A). Since the distal tip of the right Judkins catheter is directed horizontally upon engagement of the RCA ostium, there is a favorable coaxial relationship between the catheter and the proximal coronary artery. However, if backup support is necessary or if the proximal segment is long, an alternative guiding catheter curve may be required. The Judkins catheter may, however, be deeply seated in the proximal segment so as to increase its ability to provide the active support needed. The Arani 90° (Fig. 11) guiding catheter provides excellent support in this setting, from either the buttressed or fulcrum positions (12). The Amplatz catheter also provides good passive support, and various sizes are available to fit the aortic root. Both the Arani and Amplatz guides are problematic in the setting of ostial disease since they are more difficult to engage.

Upward Angle

The upward angle of takeoff (<90° from aorta) often referred to as a shepherd's crook (13) or a crowbar may

be more difficult to cannulate in a coaxial position (Fig. 13B). In this situation, a Judkins catheter is rarely effective, unless minimal guide support is required. The shepherd's crook configuration is characterized by a very short horizontal proximal segment followed by a superiorly directed segment. The guiding catheters that best cannulate the proximal segment coaxially and provide backup support necessary to negotiate the turn inferiorly within the artery are the 90° Arani and the Amplatz curves. Both catheters aggressively cannulate the ostium. The crowbar configuration has no proximal horizontal segment and has an immediate upward takeoff. A smaller-sized Judkins catheter (R_{3.5} French) may point superior, but provides little backup support. Amplatz left curves (more superior orientation than Amplatz right curves) and 75° Arani guides are both potentially effective in this situation. Occasionally left bypass graft guides or left internal mammary artery guides (14) (most superior orientation) are effective for coaxial cannulation, but they provide little backup, which is almost always necessary to transverse the turn inferiorly. The Arani catheter is especially effective in the upward takeoff RCA (15). The double loop design permits the primary curve (75° or 90°) to be positioned either against the opposite aortic wall or against the sinus of Valsalva providing excellent backup support. The tip of the catheter may seat in the ostium or be advanced into the proximal vessel. However, the Arani is difficult to engage and aggressively cannulates the ostium.

Downward Angle

The downward takeoff (greater than 90° from the aorta) is less frequently encountered and tends to be less problematic (Fig. 13C). The downward takeoff facilitates crossing of the lesion, especially when an inferiorly oriented guiding catheter is selected. Often, the Judkins

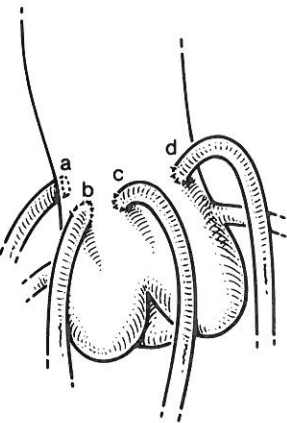


FIG. 14. Schematic view of the variable takeoff of saphenous vein grafts along the wall of the aorta. From Douglas (17), with permission.

catheter may be used, but lateral projection of the tip may be undesirable. It is sometimes possible to rotate the tip (turnover) so that it points inferiorly. However, right bypass graft, multipurpose, and right Amplatz guides all have the potential to effectively cannulate the ostium in a coaxial position due to the inferior orientation. If backup support is required, these guiding catheters need to be deeply seated, a maneuver which is usually readily performed.

Anomalous Origin

A RCA with an anomalous origin may require a significant amount of catheter manipulation prior to engaging the ostium (Fig. 13D). Origins high in the sinus (and anteriorly located) may be approached with left Amplatz curves (16). The El Gamal catheter may also be useful in this setting.

APPROACH TO CORONARY BYPASS GRAFTS

Percutaneous transluminal coronary angioplasty of conduit lesions (left internal mammary artery and saphenous vein graft) is associated with technical considerations similar to those of native coronary artery angioplasty. It is important to engage the ostium of the graft with as much coaxial alignment as possible and with a guiding catheter shape that will provide enough support to reach the lesion with the dilatation system through the long graft.

In general, saphenous vein bypass grafts have a variable and less predictable location on the aorta than the native arteries (Fig. 14) (17). Several guiding catheters have the potential to be effective, and the selection of the guide is most dependent upon the angle with which the vein meets the aorta.

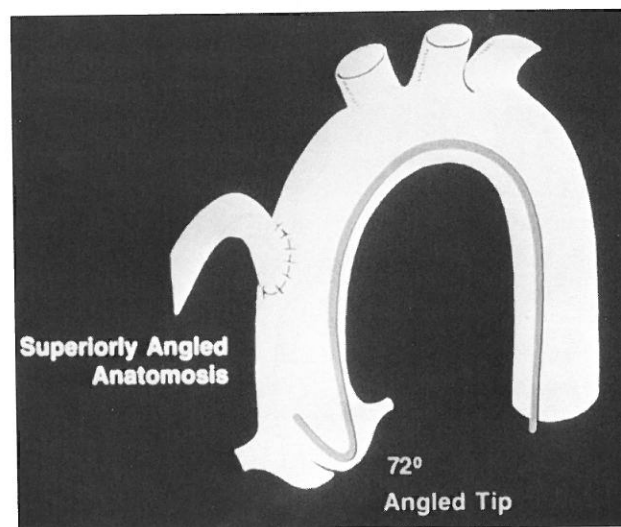


FIG. 15. Diagram of an El Gamal guide used to approach a superior takeoff of a saphenous vein graft.

Horizontal takeoff grafts can be approached with right venous bypass or right Amplatz guides. Superior takeoff is most easily cannulated with an El Gamal (Fig. 15), left venous bypass, left Amplatz or multipurpose guiding catheter. Inferior takeoff can be approached with a right Judkins, right bypass, or small right Amplatz catheter.

During PTCA of the left internal mammary artery, special care should be taken to avoid trauma to the fragile origin of the artery. Using the femoral or ipsilateral brachial approach, successful cannulation of the ostium is usually achieved with a left internal mammary artery guiding catheter.

REFERENCES

1. Patterson JA, Tilkian AG. Coronary angioplasty. In: Tilkian AG, Dailey EK, eds. *Cardiovascular procedures: diagnostic techniques and therapeutic procedures*. St. Louis, MO: CV Mosby; 1986: 328-378.
2. Kern MJ. Small-diameter guiding catheters for coronary angioplasty. *Cardio Intervention* 1992;20-24.
3. Kern MJ, Talley JD, Deligonul U, et al. Preliminary experience with 5 and 6 French diagnostic catheters as guiding catheters for coronary angioplasty. *Cathet Cardiovasc Diagn* 1991;22:60-63.
4. Salinger MH, Kern MJ. First use of a 5 French diagnostic catheter as a guiding catheter for percutaneous transluminal coronary angioplasty. *Cathet Cardiovasc Diagn* 1989;18:276-278.
5. Kern MJ, Cohen M, Talley JD, et al. Early amputation after 5 French diagnostic cardiac catheterization: results of a multicenter trial. *J Am Coll Cardiol* 1990;15:1475-1483.
6. Feldman R, Glemser E, Kaizer J, Standley M. Coronary angioplasty using new 6 French guiding catheters. *Cathet Cardiovasc Diagn* 1991;23:93-99.
7. George BS, Stertzer SH. Brachial technique to intervention. In: Topol EJ, ed. *Textbook of interventional cardiology*. Philadelphia: WB Saunders; 1990:515-534.
8. Baim DS. Percutaneous transluminal coronary angioplasty—analysis of unsuccessful procedures as a guide toward improved results. *Cardiovasc Intervent Radiol* 1992;5:186.
9. Carr ML. The use of the guiding catheters in coronary angioplasty: the technique of manipulating catheters to obtain the necessary power to cross tight coronary stenoses. *Cathet Cardiovasc Diagn* 1986;12:189-197.
10. El Gamal MIH, Bonnier JJRM, Michels HR, van Gelder LM. Improved success rate of percutaneous transluminal graft and coronary angioplasty with the El Gamal guiding catheter. *Cathet Cardiovasc Diagn* 1985;11:89-96.
11. Myler RK, Boucher RA, Cumberland DC, Stertzer SH. Guiding catheter selection for right coronary artery angioplasty. *Cathet Cardiovasc Diagn* 1990;19:58-67.
12. Arani DT. A new catheter for angioplasty of the right coronary artery and aorto-coronary bypass grafts. *Cathet Cardiovasc Diagn* 1985;11:647-653.
13. Gossman DE, Tuzcu EM, Simpfordorfer C, Beck GJ. Percutaneous transluminal angioplasty for shepherd's crook right coronary artery stenosis. *Cathet Cardiovasc Diagn* 1988;15:189-191.
14. Kulick DL. Use of the internal mammary artery guiding catheter for percutaneous transluminal coronary angioplasty of the Shepherd's crook right coronary artery. *Cathet Cardiovasc Diagn* 1989;16:190-192.
15. Arani DT, Bunnell IL, Visco JP, Conley JG. Double loop guiding catheter: a primary catheter for angioplasty of the right coronary artery. *Cathet Cardiovasc Diagn* 1988;15:125-131.
16. Mooss AN, Heintz MH. Percutaneous transluminal angioplasty of anomalous right coronary artery. *Cathet Cardiovasc Diagn* 1989;16:16-18.
17. Douglas JS Jr. Angioplasty of saphenous vein and internal mammary artery bypass grafts. In: Topol EJ, ed. *Textbook of interventional cardiology*. Philadelphia: WB Saunders; 1990:327-343.

CHAPTER 7

Selection of Balloon Catheters and Guidewires

David P. Faxon

INTRODUCTION

The growth of angioplasty, its improved success and the reduction in complications can be in large part attributed to the development of improved angioplasty catheters, guidewires, and guiding catheters. The initial fixed guidewire systems had unacceptable profiles given today's standards. In addition they were minimally directable and manipulation of the balloon catheter required aggressive rotation of the guiding catheter. While dramatic improvements in catheters have occurred, the understanding of the selection and use of the balloon catheter, guidewire, and guiding catheter is essentially in achieving a successful dilation and is as important today as it was when the procedure initially began. This chapter will discuss balloon catheters and guidewires but will also integrate the use of guiding catheters where appropriate. The extremely rapid developments in new catheters and the competitive commercial environment make it impossible for all of the data in this chapter to be completely up to date.

BALLOON CATHETER SYSTEMS

Fundamentals of Construction

Most coronary angioplasty balloons are made of four materials: polyvinyl, polyolefin copolymers, polyethylene, or polyethylene terephthalate (PET) (1). The balloon materials have distinctive inflation characteristics, ranging from moderately compliant with polyvinyl to least compliant with the PET material (Table 1). In addition to variations in compliance, the various balloons achieve a nominal size (e.g., 3.0 mm) at different inflation pressures. These two aspects are very important in the use, as

well as the choice, of balloon catheters (2). Figure 1 shows the reported compliances for various balloon catheters and illustrates the differences in performance (3-5). For instance, with a 3.0-mm PET balloon (e.g., USCI sprint) the nominal pressure to achieve 3.0 mm is 5 atmospheres, while at 10 atmospheres of pressure the diameter is only 3.16 mm. In contrast, a polyolefin catheter (e.g., SciMed skinny) has a nominal inflation pressure of 7 atmospheres increasing to 3.29 mm in diameter at 10 atmospheres. While this compliance characteristic can be used to upsize a balloon catheter by as much as 0.24 mm without the need to change to a larger balloon, it also can present potential problems. In a rigid stenosis that requires a high pressure to dilate, a compliant balloon will "dog bone" around the stenosis increasing its size proximal and distal to the stenosis, thus potentially overstretching and dissecting the adjacent normal vessel wall. In this setting an initial choice of a noncompliant balloon material would be advantageous. In addition, some investigators have reported that PET conforms better to angulated lesions, and one recent report suggests a lower dissection rate as a consequence (6). However, these observations are anecdotal and a clear clinical difference has not yet been demonstrated.

Another important characteristic of balloon material is profile, a characteristic that is independent of the catheter construction as well as balloon materials. Table I lists the deflated profiles of many of the currently available catheters. In general, the smaller the profile the easier it will be to pass a high-grade stenosis. However, other factors such as pushability and tractability also play important roles in crossing a severe stenosis. If the stenosis is not severe (e.g., <70%), then the profile is not a significant factor since the minimal lumen diameter in this circumstance is 0.8 or 0.9 mm, considerably bigger than the profile of most balloon catheters. A recent report indicated that deflated balloon profiles reported by the manufacturers are not always accurate and that the method of measurement is not uniform (7). In addition,

D. P. Faxon: Section of Cardiology, The University Hospital, Boston University Medical Center, Boston, MA 02118

TABLE 1. Physical characteristics of balloon catheters

Product	Company	Shaft diameter	Balloon Profile (inches)							Balloon material	Nominal size	Coating	Maximum guidewire	Lumen design	Rated burst (atm)	Marker placement
			1.5	2.0	2.5	3.0	3.5	4.0								
Over-the-Wire Systems																
ACS OMEGA ^(TM)	ACS [®]	2.9-3.0F	.022	.023	.025	.028	.030	.034	PE600 [®]	6	MICROGLIDE [®]	.010	Coaxial	8	Middle	
ACS PRISM ^(TM)	ACS [®]	3.3F	.029	.031	.032	.034	.035	.037	PE600 [®]	6	MICROGLIDE [®]	.014	Coaxial	8	Middle	
ACS SPECTRUM ^(TM)	ACS	3.3F	.033	.034	.036	.037	—	—	PE	12	MICROGLIDE	.014	Coaxial	18	Middle	
ACS TEN ^(TM) .010	ACS	2.8F	.024	.026	.027	.028	.030	.033	PE600	6	MICROGLIDE	.010	Coaxial	8	Middle	
HARTZLER ACX [®]	ACS	3.4-3.7F	—	.031	.032	.035	.037	.038	PE600	6	MICROGLIDE	.014	Coaxial	8	Middle	
HARTZLER ACX II [®]	ACS	3.3F	.029	.031	.032	.034	.035	.037	PE600	6	MICROGLIDE	.014	Coaxial	8	Middle	
PINKERTON ^(TM) .018	ACS	3.6F	.034	.035	.037	.039	.040	.042	PE600	6	MICROGLIDE	.018	Coaxial	6	Middle	
SULP II [®]	ACS	3.7F	—	.037	.044	.047	.051	.054	PE	6	MICROGLIDE	.014	Coaxial	6	Middle	
INTREPID ^(TM)	BAXTER [®]	3.2-3.5F	Not commercially released							POC	6	MDX Silicon ^(TM)	.018	Coaxial	8-9.3	Middle
SLINKY ^(TM)	BAXTER [®]	3.0-3.2F	—	.028	.031	.032	.036	—	POC	6	MDX Silicon	.014	Coaxial	6-9	Middle	
HELIX ^(TM)	CORDIS [®]	3.0-3.5F	—	.031	.031	.032	.033	.035	DURALYN	6-8	None	.018	Coaxial	8	Middle	
NITECH SLIDER ^(TM)	Mansfield [®]	2.9F	—	.029	.033	.035	.039	—	HDPE	6	GLIDECOAT ^(TM)	.014	Dual	10-12	Middle	
SLIDER ^(TM) .014	Mansfield	3.4F	—	.029	.033	.035	.039	.040	PE	6	GLIDECOAT	.014	Triple	10	Middle	
SLIDER ^(TM) .018	Mansfield	3.4F	—	.032	.035	.039	.041	.044	HDPE	6	GLIDECOAT	.018	Triple	10-12	Middle	
SLIDER ST ^(TM)	Mansfield	2.7F	—	.029	.033	.035	.039	—	HDPE	6	GLIDECOAT	.014	Triple	N/C/R	Middle	
14 K ^(TM)	Medtronic [®]	2.8F	Not commercially released							PE	5	ENHANCE ^(TM)	.014	Coaxial	6	Middle
THRUFLEX II ^(TM) /18K ^(TM)	Medtronic	3.5F	—	.034	.038	.042	.048	—	PE	5	ENHANCE	.018	Coaxial	16	Middle	
MICROSOFT TRAC [®]	Schneider [®]	4.3F	.031	.034	.036	.038	.042	.046	PET	4	Silicon	.014	Coaxial	16	Middle	
MICROSOFT TRAC [®] XLP ^(TM)	Schneider	3.0-3.5F	.025	.027	.029	.031	.034	—	PET	10	EXPRESSCOAT ^(TM)	.014	Coaxial	8-10	Middle	
MIRAGE ^(TM)	SCIMED [®]	2.9-3.8F	.032	.034	.035	.038	.040	.044	POC	6	XTRA ^(TM)	.018	Coaxial	8-10	Middle	
SHADOW ^(TM)	SCIMED	2.7-3.5F	.030	.031	.033	.037	.039	.042	POC	6	XTRA	.014	Coaxial	8-10	Middle	
SKINNY ^(TM) .014	SCIMED	2.7-3.5F	.027	.031	.033	.037	.040	.042	POC	8	XTRA	.014	Coaxial	9-10	Middle	
SKINNY ^(TM) .018/MVP	SCIMED	2.7-3.5F	.031	.034	.037	.039	.040	.044	POC	8	XTRA	.018	Coaxial	11.6-12.2	Middle	
STRONG ^(TM)	SCIMED	4.3F	—	.036	.038	.043	—	—	POC	6-7	None	.014	Coaxial	9	Middle	
FORCE ^(TM) /MINI-PROFILE ^(TM)	USCI [®]	3.5F	—	.031	.033	.035	.037	—	PET	5	PRO/PEL ^(TM)	.018	Dual	5	Middle	
PROFILE PLUS ^(TM)	USCI	4.3F	—	.033	.038	.039	.040	.041	PET	5	None	.018	Dual	12	Middle	
SOLO ^(TM)	USCI	3.0F	—	.029	.030	.032	.034	.036	PET	5	PRO/PEL	.014	D & O	8	Middle	
SPRINT ^(TM)	USCI	3.5F	—	.031	.033	.035	.037	.039	PET	5	PRO/PEL	.018	Coaxial	8	Middle	

Integrated Systems

HARTZLER EXCEL [®]	ACS	2.9F	—	.023	.024	.029	—	—	PE600	6	MICROGLIDE	N/A	fixed wire	8	Middle
HARTZLER LPS [®]	ACS	3.5F	.026	.026	.032	.033	.038	.038	PE600	6	MICROGLIDE	N/A	fixed wire	8	Middle
HARTZLER MICRO 600 S [®]	ACS	3.0F	—	.025	.027	.039	.031	—	PE600	6	MICROGLIDE	N/A	semi-movable	8	Middle
HARTZLER MICRO II [®]	ACS	3.7F	.033	.035	.042	.045	.050	—	PE	6	MICROGLIDE	N/A	semi-movable	8	Middle
SLALOM [®]	ACS	1.9-2.5F	—	.023	.025	.029	—	—	PE600	6	MICROGLIDE	N/A	fixed wire	8	Middle
ORION [®]	Cordis	2.4F	—	.028	.028	.030	—	—	Duralyn	8	XTRA	N/A	fixed wire	12	Middle
ACE [®]	SCIMED	1.8F	—	.022	.030	.032	.036	—	POC	7	None	N/A	fixed wire	8	Proximal
DGW [®] (1.5 mm)	SCIMED	1.7F	.018	—	—	—	—	—	POC	7	None	N/A	Coaxial	10	N/A
PROBE II [®]	USCI	1.7F	—	.019	.021	.026	—	—	PET	5	None	N/A	fixed wire	10.6	Proximal

Rapid Exchange Systems

ACS RX [®] .014	ACS	3.3F	—	.032	.034	.037	.039	.041	PE600	6	MICROGLIDE	.014	Modified D	8	Middle
ACS RX [®] .018	ACS	3.7F	.034	.035	.038	.040	.042	.046	PE600	6	MICROGLIDE	.018	Modified D	8	Middle
ACS RX ALPHA [®] .014	ACS	2.3-3.3F	.029	.030	.031	.033	.034	.035	PE600	6	MICROGLIDE	.014	Modified D	8	Middle
ACS RX ALPHA [®] .018	ACS	2.3-3.7F	—	.034	.035	.037	.038	.039	PE600	6	MICROGLIDE	.018	Modified D	8	Middle
ACS RX STREAK [®] .014	ACS	2.3-3.3F	.029	.030	.031	.033	.034	.035	PE600	6	MICROGLIDE	.014	Modified D	8	Middle
PICCOLINO FORTE [®]	Schneider	3.0-3.2F	.025	.027	.028	.031	.034	.036	PET	10-12	EXPRESSCOAT	.014	Coaxial	16	Middle
EXPRESS [®]	SCIMED	1.8-2.7/3.0F	.028	.029	.031	.035	.039	.040	POC	6	XTRA	.014	Coaxial	8-10	Middle

Perfusion Systems

ACS RX PERFUSION [®]	ACS	3.7-4.2F	—	—	.054	.055	.056	.059	PE600	6	MICROGLIDE	.018	Dual	8	M/D/P
STACK 40-S [®]	ACS	3.9F	—	—	.052	.053	.054	.055	PE600	6	MICROGLIDE	.018	Dual	8	M/D/P
STACK PERFUSION [®]	ACS	3.9-4.5F	—	.056	.057	.058	.060	.062	PE600	6	MICROGLIDE	.018	Dual	8	M/D/P

Long and Short Balloons

HARTZLER ACX II [®] -L&S	ACS	3.3F	—	.031	.032	.034	.035	.037	PE600	6	MICROGLIDE	.014	Coaxial	8	Middle
PINKERTON [®] -L&S	ACS	3.6F	—	.035	.037	.039	.040	.042	PE600	6	MICROGLIDE	.018	Coaxial	8	Middle
STACK [®] LONG-25 mm balloon	ACS	3.9-4.5F	—	—	.057	.058	.060	.062	PE600	6	MICROGLIDE	.018	Dual	8	M/D/P
SULP II [®] -L&S	ACS	3.7F	—	.037	.044	.047	.051	.054	PE	6	MICROGLIDE	.014	Coaxial	6	Middle
LONG SKINNY [®]	SCIMED	3.2-3.5F	—	.031	.034	.038	.040	.044	POC	8	XTRA	.014	Coaxial	9-10	Middle
LPS [®]	USCI	4.3F	—	.039	.047	.050	.051	.053	PVC	5	None	.018	Dual	5	Middle

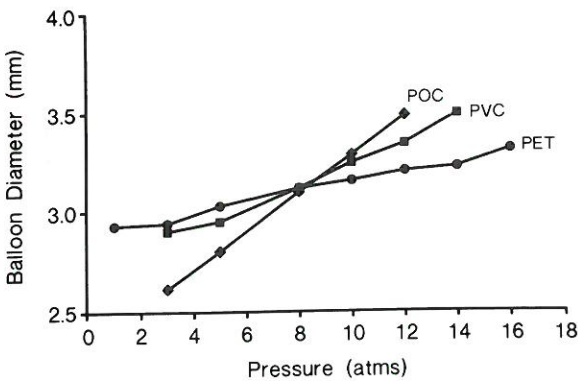


FIG. 1. Typical balloon compliance characteristics for a 3-mm angioplasty balloon. Polyolefin copolymer (POC) has the greatest change in the balloon diameter over a range of inflation pressures. While polyethylene terephthalate (PET) has the least, and polyvinyl chloride (PVC) has intermediate characteristics.

profiles can change significantly once the balloon is inflated as some balloon materials do not readily refold down to a minimal size. This is particularly true for the PET material. In order to facilitate profiles, some catheters such as the USCI sprint or probe are packaged with a small tube which is used to further reduce the profile of the catheter following debubbling. More recently balloon catheters have been made with memory in order to allow the balloon to return to the optimal deflated profile (e.g., ACS sprint).

The stiffness and size of the shaft, as well as the shaft material, influence the pushability and trackability of the catheter. The shaft is often extruded to include numerous lumens, one for the balloon lumen, one for a through lumen for the guidewire, and, in some settings, an additional lumen for perfusion or a stiffening wire. Catheters can also be made in a coaxial form (tube in a tube) where the central lumen serves as the wire lumen and the intermediate lumen serves as a balloon inflation lumen. The pushability can be further increased by the fabrication of the catheter and the use of stiffer plastic polymers. In addition, use of stiffening guidewires braids or stainless steel reinforcement have also been effective in increasing the stiffness of the catheter shaft, for example, the Stack perfusion catheter, (stiffening wires), the Medtronic Thruflex (braids and coils), and the ACS Rx alpha (stainless steel reinforcement).

Trackability is the force required to push a catheter through a tortuous vessel. It is a difficult aspect of balloon catheter performance to measure since it depends upon shaft size and flexibility, the friction against the atherosclerotic vessel wall, the balloon profile, and pushability. Recently, most manufacturers have developed coatings for their balloon catheters to reduce friction. These coatings are usually made of silicon or a similar material (e.g., microglide for the ACS catheter, propel

for USCI). Bench testing indicates a 30% reduction in friction with coatings (3).

Types of Balloon Catheters

There are four basic types of catheters: Over-the-wire, fixed-wire, monorails, and perfusion catheters (Figs. 2–6). In addition, there are a series of specialty balloon catheters for use in unusual circumstances. Each type of catheter has particular advantages and disadvantages, as listed in Table 2.

Although fixed-wire systems are the oldest catheter type, they have been completely redesigned and do not resemble their ancestors. The catheters most commonly used of this type are the USCI probe, the SciMed ACE, and ACS Slalom. The catheters are constructed with an inner guidewire that extends through the balloon catheter and beyond for a length of 2 to 2.5 cm (Fig. 2). The guidewire at the tip is usually intermediate in flexibility, ranging in size from 0.014 to 0.016 in, and the balloon is mounted directly on the outer shaft. The profile of these catheters is significantly smaller than that of the over-the-wire catheter systems (0.020–0.036 in). This smaller profile permits passage through a tighter stenosis than can be achieved with over-the-wire systems. In addition, the smaller shaft allows them to be placed into smaller guiding catheters, including the recently developed 6 French guiding catheters (8). In standard 8 French guiding angioplasty guiding catheters, the small

TABLE 2. Advantages and disadvantages of various balloon catheter types	
Advantages	Disadvantages
Fixed-wire Systems	
Small profile	Cannot easily be exchanged
Excellent visualization	Fixed guidewire at tip
Conform well to bends	Wire movement less responsive than independent wires
Easier to use	
Over-the-Wire Systems	
Larger selection of balloons	Larger profile
Exchange easier	Poorer visualization
Can measure pressure gradient	More complicated to use than fixed wire
Distal contrast injection possible	
Can use a variety of guidewires	
Monorail Systems	
Rapid lesion access	Back-bleeding
Rapid exchange	Wire and balloon can tangle
Improved visualization	
Improved pushability	

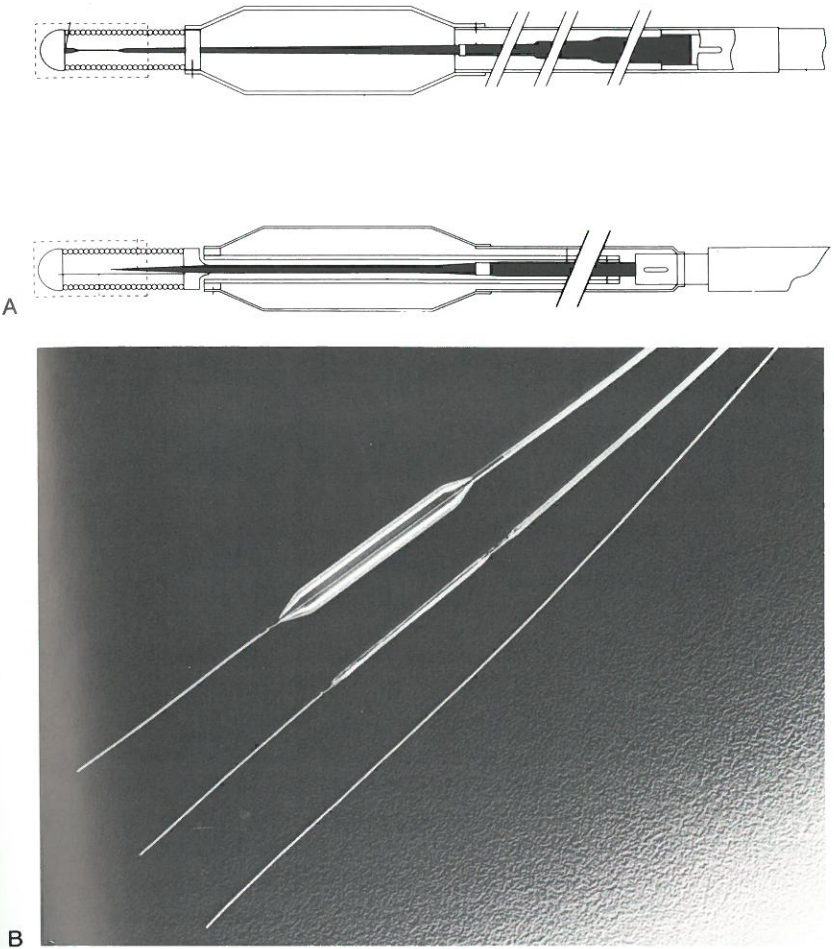


FIG. 2. Fixed-wire catheters have a central fixed guidewire that extends beyond the balloon and is attached proximally and distally to the catheter shaft. **A:** Two examples of construction, the SciMed ACE (top) and the USCI-Probe (bottom). **B:** The USCI-Probe inflated and deflated in comparison with a 0.14-in guidewire to illustrate its low profile.

profile of these catheters result in superb contrast injections and coronary visualization. One particular advantage of the fixed-wire systems is the ease with which bifurcation lesions can be dilated. Often they are coupled with one over-the-wire system in order to allow more flexibility in balloon catheter choice, as well as to permit upsizing if necessary. The disadvantages of fixed-wire catheter systems is that they cannot be easily exchanged for a larger balloon size without the necessity of recrossing the vessel. Alternatively, the balloon can be left across the stenosis and another fixed wire system passed alongside it, down into the stenosis, with removal of the initial balloon. This, however, is more cumbersome than the usual exchange process described later in this chapter. In general, however, straightforward lesions can be easily dilated with a fixed-wire system and can often be recrossed without limitations if upsizing is necessary. One alternative to exchanging with a fixed-wire system is the use of a 5 French probe sheath. Prior to introduction into the guide the fixed-wire catheter is placed within the probe sheath and extends beyond the tip. Once dilation has occurred the probe sheath can be passed through the stenosis using the fixed-wire system as a guidewire. If exchange is necessary, repassage of a larger balloon cath-

eter can be done without removal of the sheath. However, the probe sheath adds significant rigidity to the catheter and it can often kink in the exchange process. For this reason it is not routinely used. In addition, it needs to be placed over the balloon catheter prior to its insertion, making preprocedural planning important. Another limitation of fixed-wire systems is that they are less steerable and manipulatable than an independent guidewire. Finally, the 2.5-cm length to the wire beyond the tip of the balloon can often pose problems in small vessels where there is not enough room to park the tip of the guidewire while placing the balloon within the stenosis. Despite these limitations, fixed-wire systems continue to be frequently used and constitute 12% of current catheter sales (ACS, personal communications). The most commonly used balloon type is the over-the-wire catheter system. There are seven manufacturers currently in the United States, and the balloon sizes range from 1.5 to 4 mm in diameter, with a balloon length ranging from 15 to 40 mm (Fig. 3). The primary advantage of over-the-wire systems is their flexibility in the choice of guidewires and balloon sizes and types. The independent movement of both the guidewire and balloon permit enhanced tractability around tortuous

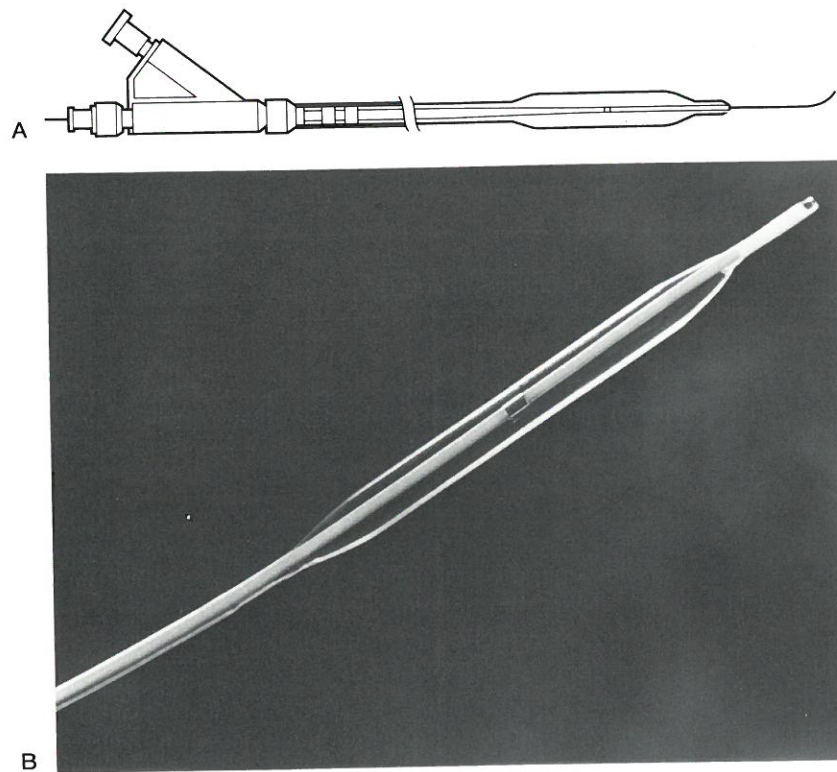


FIG. 3. Over-the-wire systems have a central lumen to allow independent movement of the wire. Various sizes and constructions are shown in Table 3. **A:** Typical balloon catheter design. **B:** ACS CX catheter.

turns, using the so-called "push-pull" technique described later. The larger lumen also allows for distal pressure measurements and contrast injections in certain catheters (e.g., ACS Pinkerton). This may be particularly useful in approaching chronic total occlusions, where distal dye injections can assure that there is proper placement of the wire and balloon within the lumen prior to angioplasty. The major disadvantages include the somewhat cumbersome exchange process, and the difficulty in visualization due to the larger shaft of the catheter which is necessary to accommodate a central guidewire. Also, the large shaft size limits the use of two balloon catheters simultaneously for bifurcation lesions unless extremely large lumen guiding catheters (e.g., Schneider 9F superflow) (0.092-in ID) are used. The balloon profile, material, trackability, and pushability are important in selection of over-the-wire systems. The details of these factors have been previously discussed (Table 1).

Monorails were first introduced by Doctor Bonzel in Europe and have since been introduced in the United States by a number of manufacturers (9). They are rapidly gaining popularity and now comprise 40% of the angioplasty market. They possess some of the characteristics of both the fixed-wire and over-the-wire systems. The distal 17 to 25 cm of the catheter has a central lumen, but this lumen exits the catheter so that the wire and shaft of the catheter are separate (Fig. 4). This permits a smaller catheter shaft, and consequently there is a larger guiding catheter lumen for injecting contrast medium and improving visibility. In addition, the smaller

shaft can be strengthened, permitting better pushability. The distal end of the catheter, where the central guidewire is placed, is similar in most aspects to the over-the-wire system and permits good tracking of the balloon over the guidewire. The main advantages of the monorail system are rapid lesion access, maximum visualization by use of a bare-wire approach, the ability to rapidly exchange the balloon, and improved pushability and trackability. Exchange can be easily done by pulling the catheter back to the entry point into the guiding catheter and then, by holding the guidewire, gradually removing the portion of the catheter with the central lumen (Fig. 5). Since the central lumen section is shorter than the length of the guidewire, addition of an exchange wire or an add-on wire is not necessary. It also permits very rapid advancement of the catheter, since the guidewire can be externally fixed in one hand while the balloon is pushed rapidly with the other. Some manufacturers have provided a peel-away central lumen which allows the guidewire to be pulled away from the catheter up to the balloon itself, further facilitating removal by shortening the distance to the catheter tip. This rapid exchange system is of some advantage when exchange of balloon catheters is anticipated, for instance, when dilating tandem lesions that require separate balloons of different sizes. It is also useful if one cannot accurately measure the diameter of the vessel prior to dilation and, therefore, exchange is anticipated. However, since the guidewire exits the back-bleeding device at the hub of the guiding catheter, wire movement is only possible when the

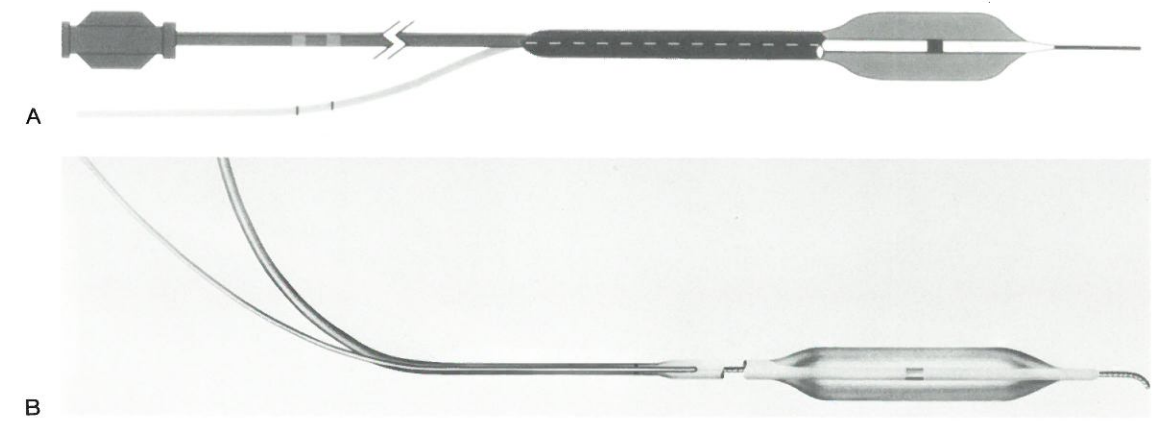


FIG. 4. The monorail systems are similar to the over-the-wire systems except that the guidewire exits the catheter 15 to 20 cm distal to the tip, a feature allowing for rapid exchange of the catheter. **A:** Design of the catheter showing the tapering of the shaft after the wire exits the catheter. The smaller more proximal shaft facilitates contrast injections during angioplasty. **B:** Exterior appearance of the monorail catheters.

adapter is open. This results in back-bleeding of blood and inaccurate measurement of blood pressure during wire motion. However, this is considered only a minor inconvenience by most operators.

Perfusion balloon catheters are over-the-wire or monorail systems that have larger central lumens with 10 proximal and 4 distal side holes to permit passage of blood through the distal end of the catheter (Fig. 6). Passive perfusion occurs during balloon inflation. With the ACS Stack perfusion balloon catheter, blood flow is approximately 60 cc/min at a blood pressure of 80 mmHg (10). Since blood flow is dependent upon blood pressure, use of these catheters in hypotensive patients may not supply a sufficient amount of blood to the ischemic territory to prevent myocardial ischemia. To achieve a large enough lumen, the profile of these catheters is the largest of all over-the-wire systems (0.053 to 0.067 mm), and the tip is significantly longer than a standard balloon catheter in order to permit sufficient side holes for perfusion.

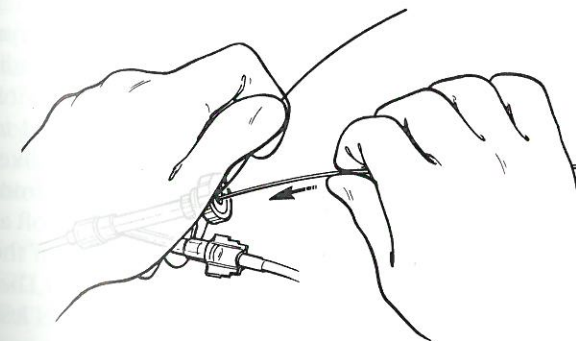


FIG. 5. Exchange of the monorail catheter can easily be accomplished by holding the guidewire in place with one hand, while advancing and withdrawing the catheter with the other. Exchange can take place without fluoroscopy, eliminating radiation exposure.

In addition, the tip often has a separate wire marker which also increases the profile of the distal tip. These factors severely limit the use of these balloon catheters to proximal stenoses in large vessels. As a result, most operators use perfusion balloon catheters as a bail-out catheter for the treatment of abrupt closure or significant dissections. Currently, smaller diameter perfusion balloon catheters with shorter tips are under development and should be available shortly. One such catheter is the ACS Stack 40-S catheter which is smaller in profile (0.052–0.055 in); however, it provides only 40 cc/min of blood perfusion at a blood pressure of 80 mmHg. This may in fact be sufficient in smaller vessels. The use of prolonged balloon inflations in order to prevent or treat coronary dissections, as well as to prevent restenosis, has undergone considerable recent investigation. Anecdotal studies have demonstrated that the Stack perfusion balloon can reduce the incidence of significant dissections requiring surgery by from 50% to 70% (11). In one recently published randomized trial of perfusion balloon angioplasty versus routinely angioplasty, a 15-min perfusion balloon inflation significantly reduced the initial incidence of dissection. However, overall there was no difference in success rate nor in the incidence of subsequent restenosis (12).

Specialty catheters also include long balloons (30–40 mm in length), angled balloons, and short balloons (10 cm). The latter two are infrequently used today but were developed primarily to prevent dissection in lesions on severe bends or extremely discrete lesions. The long balloon catheters however have been shown to be helpful in long diffuse coronary disease (e.g., >2 cm) (13). Long and diffuse disease has been associated with a two- to four-fold increase in the risk of dissection and abrupt closure (14). Several recent studies suggest that long balloons can significantly reduce this dissection rate from

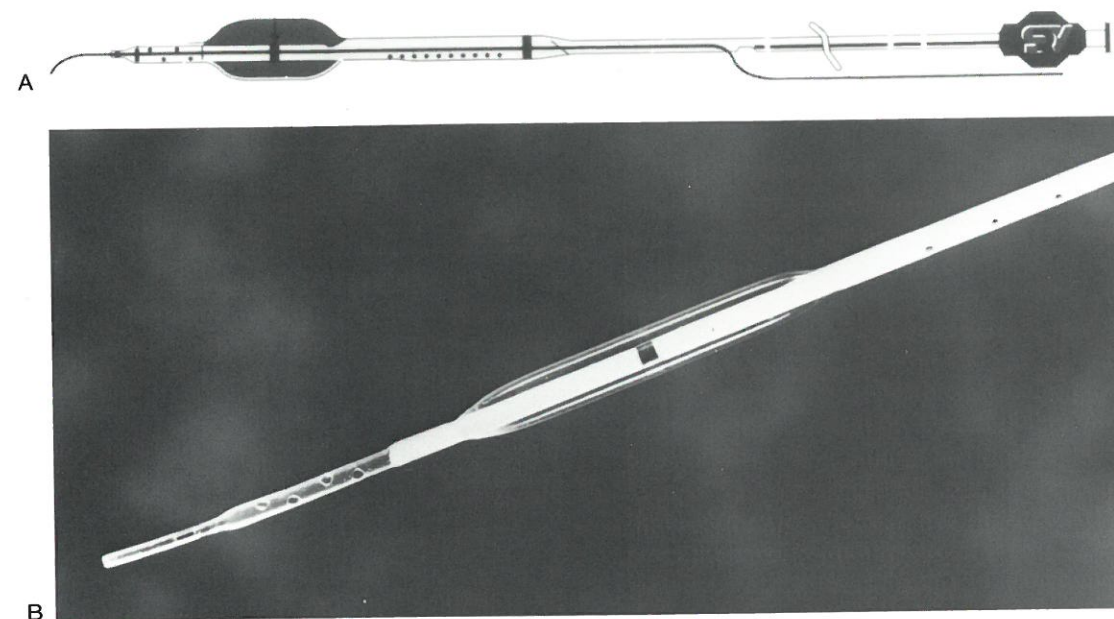


FIG. 6. Perfusion catheters allow passage of the blood to occur during balloon inflation through small holes proximal to the balloon and distal to the balloon. The need for four distal holes results in a longer tip extension beyond the balloon and a larger shaft of the catheter. **A:** The construction of currently available perfusion balloons. The catheter design can be a monorail design as shown or an over-the-wire design. **B:** An example of a Stack perfusion balloon catheter demonstrating the side holes.

18% to 9% while maintaining a high overall success rate of 90% to 95% (15).

Guidewires

Proper selection of guidewires is as important as balloon catheter selection. It needs to be integrated with the balloon catheter used as well as the lesion and vessel anatomy attempted. The guidewire is composed of three main elements: a central core wire, a shaping ribbon, and an outer spring coil (Fig. 7). The central core usually does not extend to the tip and is tapered to allow gradual decrease in wire stiffness. The shaping rhythm extends from the central core to the tip of the spring wire and is welded to the tip, both to allow shaping of the tip and also to prevent separation of the tip from the shaft of the wire. The coil is sometimes graduated in size, and the spacing between the coils can also be altered to change the stiffness of the wire. These aspects impart varying degrees of stiffness, torqueability, and shapeability to the guidewires. Most guidewires are also coated with silicon or Teflon to facilitate passage through the balloon catheter and coronary vessels.

Guidewires range in diameter from 0.10 to 0.18 in. The larger guidewires are stiffer, and more torqueable and tractable than smaller guidewires. Most current systems utilize a 0.14-in wire. The ACS 10 system is a specially designed balloon and guidewire system that utilizes a 0.010-in guidewire. The wires are 175 cm in

length, except for exchange wires which are 300 cm in length. Most standard wires are extendible, with a separate wire which is attached to the distal end in order to extend the length of the wire to the length of an exchange wire (e.g., 320 cm). The USCI system employs a distal hypotube with a crimped wire that is inserted into the hypotube. The extension wire is slightly larger than the primary wire and this can create some resistance in exchanging low profile balloons. The ACS Doc system is similar to the hypotube system made by USCI except that the hypotube is contained on the wire that is added to the primary wire. The ACS wire is slightly smaller than the USCI wire and often passes through low profile balloons and new interventional devices with greater ease.

Another difference between the USCI and ACS systems is that the distal 25 cm of the USCI wire is radiopaque, compared to only 3 cm of the ACS guidewire. However, the ACS system can be specially ordered to have a longer opaque segment. The wire stiffness is likewise variable. The very flexible or hyperflex wire from USCI or the high torque floppy wire from ACS are soft at the tip, and this allows for less traumatic passing of the guidewire through the coronary artery. However, because of the increased softness they are likewise less steerable. One exception is the 0.018-in high-torque floppy that has both flexibility and steerability but can only be used in a few balloon catheters due to its size. The mostly commonly used wires are intermediate in stiffness and include the flexwire by USCI or the Hi-

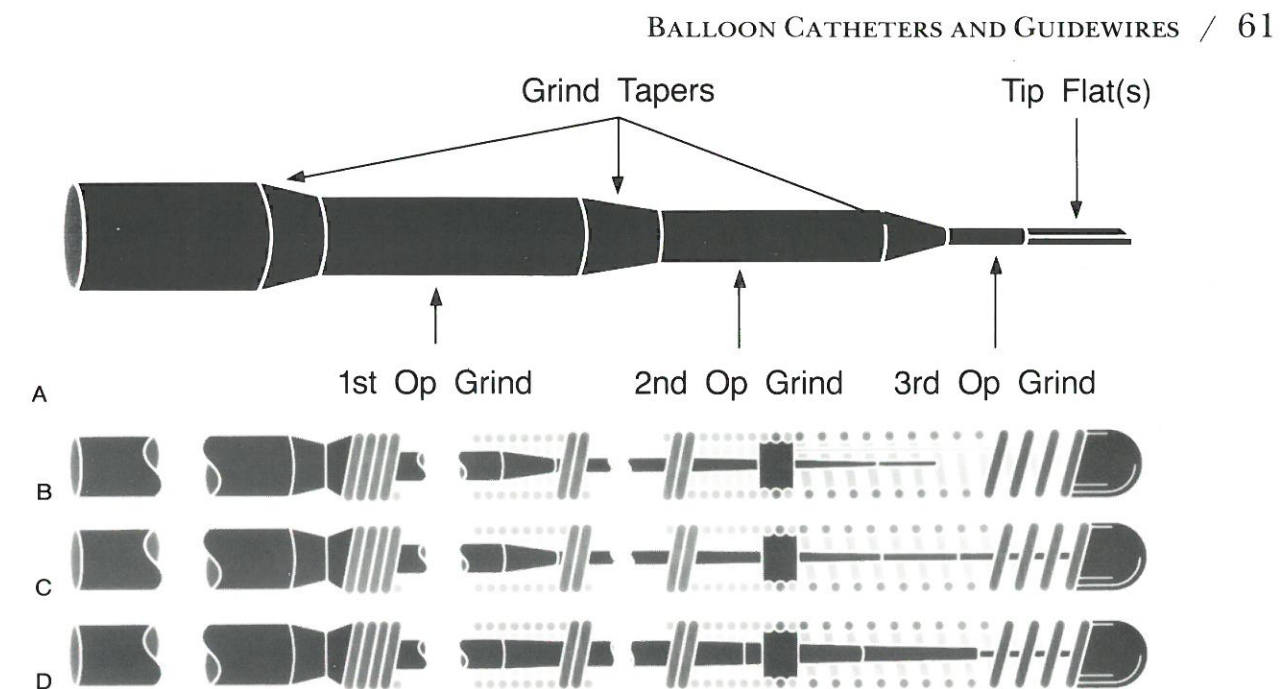


FIG. 7. A guidewire is composed of a coiled spring wire over a central wire that is gradually tapered to the tip (**A**). If the central core does not extend to the tip, a shaping ribbon extends from the core to the end of the spring wire (**B**). This type of construction results in a soft-tipped wire. If the core wire does extend to the tip, the degree of taper can influence the wire stiffness ranging from moderately stiff (**C**) to very stiff (**D**).

torque intermediate wire by ACS. These wires are intermediate in both torque control and stiffness and thus are the workhorses for most operators. The stiff guidewires are the steerable USCI or the high-torque standard by ACS. The increased stiffness is achieved by extending the core wire to the tip. While increased torque control is achieved, the increased stiffness does increase the risk of trauma to the vessel. The stiffest wire is the USCI 0.16-in standard guidewire. We reserve this guidewire for failures of the 0.014-in guidewires and primarily restrict it to vessels that are chronically totally occluded. A disadvantage of the standard steerable wires are that they tend to hold their shape less well and require frequent reshaping if extreme bends on the tip of the wire are necessary. A general rule of thumb is that a soft, very flexible wire will be able to negotiate one 90° turn. A wire with stiffness in the mid range will be able to negotiate a 90° turn and a 45° turn, and only the stiff steerable wires will be able to negotiate two 90° turns. The one exception to this rule is a very large and undiseased vessel where floppy and flexible wires often work quite well in negotiating tortuosity.

SELECTION AND USE OF BALLOON CATHETERS

General Considerations

One of the most important aspect of balloon selection is the detailed review of the cineangiogram prior to be-

ginning the procedure. The anticipated position of the guiding catheter in the coronary ostium, the type and flexibility of the guide, and the size and tortuosity of the vessels leading to the stenosis need to be carefully assessed, as well as to lesion morphology and distal vessel anatomy. The devising of a predilation strategy is best done by review of the cine film prior to the case and is often less optimally done on-line in the catheterization lab, despite the availability of high-resolution video or digital road mapping. In straightforward cases, decision can usually be made in the lab, with a high success rate. However, in more complex cases a careful review is necessary. One alternative is to develop the cineangiograms while the patient is still in the catheterization lab and to review the films prior to initiating the procedure. It is a good practice to use one type of balloon, wire, and guide for routine cases as the staff and physicians become extremely well versed in the strengths and weaknesses of a particular balloon catheter system.

In the selection of a balloon catheter it is our general practice to choose a balloon that closely approximates the adjacent nondiseased segment of the vessel. This may be difficult if the vessel tapers or has no clearly normal segment. It is also difficult to size the balloon properly at a bifurcation point, since the distal vessel is often considerably smaller than the proximal lesion. Our practice is to average the proximal and distal segments and to measure these carefully on the angiogram using a digital caliper system. Alternatively, measurements can be made with digital angiography on-line in order to properly size the

TABLE 3. Dimensions of balloons and guide

Balloon name	Max OD		Device outer											
	(French)	(Inch)	.022	.023	.024	.026	.030	.031	.032	.033	.035	.036	.038	.039
USCI Probe-III (2.0 mm–2.5 mm)	1.7	.022	.050	.051	.052	.054	.058	.059	.060	.061	.063	.064	.066	.067
ACE (1.5–2.0 mm)	1.8	.023	.051	.052	.053	.055	.059	.060	.061	.062	.064	.065	.067	.068
Long ACE (2.0 mm)	1.8	.024	.052	.053	.054	.056	.060	.061	.062	.063	.065	.066	.068	.069
USCI Probe-III (3.0 mm)	2.0	.026	.054	.055	.056	.058	.062	.063	.064	.065	.067	.068	.070	.071
ACE (2.5 mm)	2.3	.030	.058	.059	.060	.062	.066	.067	.068	.069	.071	.072	.074	.075
Orion	2.4	.031	.059	.060	.061	.063	.067	.068	.069	.070	.072	.073	.075	.076
ACE (3.0 mm), Long	2.5	.032	.060	.061	.062	.064	.068	.069	.070	.071	.073	.074	.076	.077
ACE (2.5 mm)	2.5	.033	.061	.062	.063	.065	.069	.070	.071	.072	.074	.075	.077	.078
Slalom														
Slider-ST (2.0 mm–3.0 mm), Express (1.5 mm–3.0 mm), Long ACE (3.0 mm)	2.7	.035	.063	.064	.065	.067	.071	.072	.073	.074	.076	.077	.079	.080
Ten, ACE (4.0 mm), Cobra-10	2.8	.036	.064	.065	.066	.068	.072	.073	.074	.075	.077	.078	.080	.081
Excel, Omega (1.5 mm–3.5 mm), NiTech (2.0 mm–3.0 mm), 14K (1.5 mm–3.0 mm), F-14 (1.5 mm–3.0 mm)	2.9	.038	.066	.067	.068	.070	.074	.075	.076	.077	.079	.080	.082	.083
Cobra-14 (1.5 mm–3.0 mm), Express (3.5 mm), F-14 (3.5 mm), Long ACE (3.5 mm), Micro-600, NiTech (3.5 mm), Omega (4.0 mm), Slider-ST (3.5 mm), Solo	3.0	.039	.067	.068	.069	.071	.075	.076	.077	.078	.080	.081	.083	.084
F-14 (4.0 mm), Express (4.0 mm)	3.1	.040	.068	.069	.070	.072	.076	.077	.078	.079	.081	.082	.084	.085
14K (3.5 mm)	3.2	.041	.069	.070	.071	.073	.077	.078	.079	.080	.082	.083	.085	.086
Reach-14, Slinky, Cobra-14 (3.5 mm–4.0 mm), Piccolino & Forte	3.2	.042	.070	.071	.072	.074	.078	.079	.080	.081	.083	.084	.086	.087
ACX-II, Prism, Long-Prism, RX-Alpha .014", RX-.014", Streak	3.3	.043	.071	.072	.073	.075	.079	.080	.081	.082	.084	.085	.087	.088
Synergy, Slider, .014" & Slider .018" (2.0 mm–3.5 mm)	3.4	.044	.072	.073	.074	.076	.080	.081	.082	.083	.085	.086	.088	.089
Slider-.014" (4.0 mm)	3.5	.045	.073	.074	.075	.077	.081	.082	.083	.084	.086	.087	.089	.090
Intrepid, Helix, 18K, MVP, Skinny, Long Skinny, XLP, Sprint, Force	3.5	.046	.074	.075	.076	.078	.082	.083	.084	.085	.087	.088	.090	.091
Pinkerton, Mirage (P-18), Shadow (P-14)	3.6	.047	.075	.076	.077	.079	.083	.084	.085	.086	.088	.089	.091	.092
Long ACX, RX-Alpha-.018", RX-.018", Slider .018" (4.0 mm)	3.7	.048	.076	.077	.078	.080	.084	.085	.086	.087	.089	.090	.092	.093

Shaded region indicates incompatibility with all guide catheters.

for determining balloon combinations

diameter in inches																
.040	.041	.042	.043	.044	.045	.046	.047	.048	.052	.053	.054	.055	.056	.059	.060	.062
.068	.069	.070	.071	.072	.073	.074	.075	.076	.080	.081	.082	.083	.084	.087	.088	.090
.069	.070	.071	.072	.073	.074	.075	.076	.077	.081	.082	.083	.084	.085	.088	.089	.091
.070	.071	.072	.073	.074	.075	.076	.077	.078	.082	.083	.084	.085	.086	.089	.090	.092
.072	.073	.074	.075	.076	.077	.078	.079	.080	.084	.085	.086	.087	.088	.091	.092	.094
.076	.077	.078	.079	.080	.081	.082	.083	.084	.088	.089	.090	.091	.092	.095	.096	.098
.077	.078	.079	.080	.081	.082	.083	.084	.085	.089	.090	.091	.092	.093	.096	.097	.099
.078	.079	.080	.081	.082	.083	.084	.085	.086	.090	.091	.092	.093	.094	.097	.098	.100
.079	.080	.081	.082	.083	.084	.085	.086	.087	.091	.092	.093	.094	.095	.098	.099	.101
.081	.082	.083	.084	.085	.086	.087	.088	.089	.093	.094	.095	.096	.097	.100	.101	.103
.082	.083	.084	.085	.086	.087	.088	.089	.090	.094	.095	.096	.097	.098	.101	.102	.104
.084	.085	.086	.087	.088	.089	.090	.091	.092	.096	.097	.098	.099	.100	.103	.104	.106
.085	.086	.087	.088	.089	.090	.091	.092	.093	.097	.098	.099	.100	.101	.104	.105	.107
.086	.087	.088	.089	.090	.091	.092	.093	.094	.098	.099	.100	.101	.102	.105	.106	.108
.087	.088	.089	.090	.091	.092	.093	.094	.095	.099	.100	.101	.102	.103	.106	.107	.109
.088	.089	.090	.091	.092	.093	.094	.095	.096	.100	.101	.102	.103	.104	.107	.108	.110
.089	.090	.091	.092	.093	.094	.095	.096	.097	.101	.102	.103	.104	.105	.108	.109	.111
.090	.091	.092	.093	.094	.095	.096	.097	.098	.102	.103	.104	.105	.106	.109	.110	.112
.091	.092	.093	.094	.095	.096	.097	.098	.099	.103	.104	.105	.106	.107	.110	.111	.113
.092	.093	.094	.095	.096	.097	.098	.099	.100	.104	.105	.106	.107	.108	.111	.112	.114
.093	.094	.095	.096	.097	.098	.099	.100	.101	.105	.106	.107	.108	.109	.112	.113	.115
.094	.095	.096	.097	.098	.099	.100	.101	.102	.106	.107	.108	.109	.110	.113	.114	.116

TABLE 3.

Balloon name	Max OD		Device outer											
	(French)	(Inch)	.022	.023	.024	.026	.030	.031	.032	.033	.035	.036	.038	.039
Stack 40-S (2.5 mm)	4.0	.052	.080	.081	.082	.084	.088	.089	.090	.091	.093	.094	.096	.097
Stack 40-S (3.0 mm)	4.1	.053	.081	.082	.083	.085	.089	.090	.091	.092	.094	.095	.097	.098
Stack 40-S (3.5 mm)	4.2	.054	.082	.083	.084	.086	.090	.091	.092	.093	.095	.096	.098	.099
RX Perfusion (2.5 mm–3.0 mm), Stack 40-S (4.0 mm)	4.2	.055	.083	.084	.085	.087	.091	.092	.093	.094	.096	.097	.099	.100
RX Perfusion (3.5 mm)	4.3	.056	.084	.085	.086	.088	.092	.093	.094	.095	.097	.098	.100	.101
RX Perfusion (4.0 mm), Stack Perfusion (2.0 mm–3.0 mm)	4.5	.059	.087	.088	.089	.091	.095	.096	.097	.098	.100	.101	.103	.104
Stack Perfusion (3.5 mm)	4.6	.060	.088	.089	.090	.092	.096	.097	.098	.099	.101	.102	.104	.105
Stack Perfusion (4.0 mm)	4.8	.062	.090	.091	.092	.094	.098	.099	.100	.101	.103	.104	.106	.107

Guide	ID.	Guide	ID.	Guide
ACS PowerGuide 8F	.080"	Cordis Brite-tip 8F	.079"	Medtronic Sherpa 8F
Baxter Marathon 7F	.070"	Cordis Brite-tip XL 8F	.084"	Medtronic Sherpa 9F
Baxter Marathon 8F	.079"	Medtronic Sherpa 6F	.054"	Medtronic Sherpa 10F
Cordis Brite-tip 7F	.072"	Medtronic Sherpa 7F	.072"	Medtronic PeakFlo 8F

balloon catheter. The absence of careful measurement of the vessel size results in use of multiple balloons and significantly increases the cost of the procedure. We try to size the balloon catheter so that the ratio between the balloon diameter and the vessel diameter is 1:1 to 1:1.2. In an effort to optimize the match between the balloon and the vessel diameters one should have a full selection of balloon catheters with size increments of 0.25 mm. When working between two balloon sizes, we usually round up to the next quarter size since the balloon is often not fully expanded at usual dilating pressures. An exception to this rule is in settings where the lesion is in a extreme bend, where undersizing may be desirable. A moderately compliant balloon material allows further adjustment of the balloon size by taking advantage of the change in balloon diameter at high pressures and obviates the need for a balloon exchange. However, as previously mentioned, if the stenosis is heavily calcified inflation of a compliant balloon can result in "dog boning" around the stenosis.

Setup

The balloon are packaged sterile and instructions on preparation are included. Most systems use an aspiration preparation. The ACS ACX system and Stack are prepared using a positive preparation system. This is best

done by mixing equal volumes of x-ray contrast medium and saline in a beaker and then drawing up 20 cc of the mixture in a 50-cc syringe. Negative pressure is applied directly to the hub of the balloon lumen for 1 to 2 min. A double negative preparation, which involves aspiration for 30 sec, release of pressure, and then reaspiration can also help reduce the size of the residual air bubble seen after an aspiration prep. The ACS positive preparation system is done by attaching the inflation device directly to the balloon and inflating up to 6 atmospheres. The tip of the balloon is held so that the distal lumen faces the ceiling and gradually the column of contrast is seen to enter the balloon and to expel the air through a small hole at the tip of the balloon. Pressure is continued until a small drop of contrast is evident or until 30 sec has passed, at which time the balloon is placed on neutral pressure. One disadvantage of a positive preparation is that the balloon is distended prior to its use in the patient; this alters the profile of the balloon, as well as changing the size of the balloon if the balloon material is compliant. Studies have demonstrated that the balloon size can change as much as 0.002-0.003 mm (7). Newer catheters such as the ACX Verbatum system have balloons that are molded to fold back to their previous shape and avoid the formation of wings, which characterize some balloon materials. Most commonly, balloons are prepared by the angioplasty assistant or a technician during the early stages of the angioplasty procedure,

Continued.

diameter in inches																
.040	.041	.042	.043	.044	.045	.046	.047	.048	.052	.053	.054	.055	.056	.059	.060	.062
.098	.099	.100	.101	.102	.103	.104	.105	.106	.110	.111	.112	.113	.114	.117	.118	.120
.099	.100	.101	.102	.103	.104	.105	.106	.107	.111	.112	.113	.114	.115	.118	.119	.121
.100	.101	.102	.103	.104	.105	.106	.107	.108	.112	.113	.114	.115	.116	.119	.120	.122
.101	.102	.103	.104	.105	.106	.107	.108	.109	.113	.114	.115	.116	.117	.120	.121	.123
.102	.103	.104	.105	.106	.107	.108	.109	.110	.114	.115	.116	.117	.118	.121	.122	.124
.105	.106	.107	.108	.109	.110	.111	.112	.113	.117	.118	.119	.120	.121	.124	.125	.127
.106	.107	.108	.109	.110	.111	.112	.113	.114	.118	.119	.120	.121	.122	.125	.126	.128
.108	.109	.110	.111	.112	.113	.114	.115	.116	.120	.121	.122	.123	.124	.127	.128	.130

when access and screening angiography views are obtained.

Manipulation

Angioplasty operators manipulate the equipment, using either a single- or double-operator technique. In the single-operator technique the primary operator manipulates the guiding catheter, the balloon catheter and the guidewire. The secondary operator assists in contrast injection and balloon inflation. In a double-operator technique the manipulation is divided between two operators. Usually the operator closest to the catheter entry site manipulates the guiding catheter and balloon catheter while the second operator manipulates the guidewire. This latter technique requires greater coordination between the two operators in order to avoid the inadvertent movement of one of the three components. However, the single operator technique is more difficult to learn as one needs to become facile in moving two and three components of the system simultaneously.

When using the over-the-wire or monorail systems, the guidewire is initially passed with a balloon up to the tip of the guiding catheter. Proper guiding catheter position and stability are important prior to initially crossing the lesion. The guidewire should be moved slowly forward using a still video image or digitized image as a road

map. Intermittent contrast injections guide in correct passage of the wire down the vessel and through the stenosis. The use of biplane imaging or frequent movement of the imaging tube for optimal working positions in orthogonal views is also advantageous. The feel and torqueability of the various wires must be learned in order to understand when undue pressure is being placed on the wire and vascular damage can occur. Jerking or darting motions are usually not helpful. Instead careful, slow torqueing and forward motion of the wire is most effective. Many operators move the guidewire by holding the end of the balloon catheter and moving the torqueing device to within 2 to 3 cm of the end of the back-bleeding device and then reposition the torqueing device again back on the wire each time the wire is moved forward. An alternative technique, less frequently used, is to torque the guidewire with the right hand while moving the balloon catheter through the guiding catheter with the left in order to advance the guidewire. Prior to insertion, the distal tip of the wire should be bent in order to approximate the turns necessary to traverse the vessel proximal to the lesion, as well as to cross the lesion. If these angles differ greatly, then it is best to chose an angle that is halfway between the largest and smallest angle. Too great a turn at the tip of the wire can make passage difficult, as the wire will undoubtedly select most of the side branches proximal to the lesion. On the other hand, too small a bend may make it

difficult to selectively choose the branch that needs to be assessed. For instance if there is a sharp 90° turn between the left main and the circumflex, a 90° turn will help in accessing the circumflex. However, if the lesion is concentric, then the 90° bend will make it difficult to pass through the stenosis. In this setting, a 45° bend may be optimal for both.

Once the guidewire is past the stenosis, it then should be moved to as distal a position as possible. In general, the wire should be passed at least one full balloon length beyond the lesion, or approximately 2 to 3 cm. It is best to leave the wire in the largest vessel or the vessel that you would want to salvage if a severe propagating dissection occurred. Small side branches should be avoided as these often can cause ectopy and can inadvertently bend the wire. The balloon should then be passed over the guidewire by holding the guidewire stationary, and the balloon should be on negative pressure as it advances over the guidewire into the stenosis. Again, contrast injections can facilitate proper placement. Often use of the stiffer balloon catheter causes injection of the balloon catheter from the ostium of the coronary artery and, if this occurs, the guidewire should be immediately pulled over the balloon catheter to reinsert it into a firm, stabilized position. With the balloon catheter in the coronary artery, the chance of dissecting the coronary artery, even with aggressive intubation of the coronary artery, is much less likely; but aggressive intubation should only be done if necessary to establish a firm guiding position. Care clearly needs to be made in this maneuver if the vessel tapers significantly or has proximal disease that might be inadvertently dissected by the guidewire. Once the balloon is passed into the stenosis the guidewire should then be removed to a safe and less occlusive position, if it was advanced to obtain stability. The balloon is then inflated and various inflation strategies have been used by various operators. In general most operators inflate the balloon to 2 atmospheres in order to determine that it is properly placed within the stenosis by visualization of a dumbbell. Pressure is gradually increased then to a minimal inflation pressure, namely 4 atmospheres, and then increased to the nominal pressure for the balloon size, most often 6 atmospheres. Balloon inflation times on average range from 60 to 90 sec, but longer inflations may be possible when good collaterals exist or when one is dilating a chronic total occlusion. It is currently unclear whether longer inflations result in an improved angioplasty result. More than one inflation is necessary to minimize elastic recoil. The balloon should be reinflated if there is any defect in the balloon, or if a mild defect occurs after the balloon is reinflated at very low pressure, as these signs indicate that some degree of stenosis or elastic recoil still exists. After each balloon inflation, contrast injections can help identify the change in stenosis. However, if the balloon is partially obstructing the artery and good visualization is not possible, then

the balloon should be removed and optimal views obtained in order to access the success of the procedure. We routinely obtain repeat angiographic views with the guidewire across the stenosis but the balloon withdrawn into the guiding catheter; if these views show a residual stenosis of 20% or less, without the occurrence of an intimal tear, then the guidewire is removed and the view is again repeated. It is important to repeat the views following the guidewire removal since the guidewire can partially stent significant dissections which may not be visible with it in place.

Special Anatomical Situations

Bifurcation Lesions

A detailed description of the technique for approaching and dilating bifurcation lesions is contained in Chapter 9. This situation demands careful planning in the choice of equipment. While initially bifurcation lesions were approached using two separate guiding catheters and balloon catheters, the larger lumen guiding catheters (0.80- to 0.94-in ID) will accommodate two low-profile balloon catheters. A chart of potential balloon combinations is shown in Table 3. Three potential combinations are possible: two fixed-wire systems, two over-the-wire systems or monorails, or one fixed wire and one over-the-wire. As with single lesions, the fixed-wire and monorails offer the advantages of better steerability and easier upsizing or exchange if necessary. Bifurcation lesions are associated with an increased risk of abrupt closure and dissection, and the safety of a guidewire across the lesion is an advantage. However, fixed-wire systems are easy to use and greatly speed up the time of the procedure. Thus the use of a fixed-wire system in a relatively easy straightforward lesion and an over-the-wire system in a more complex lesion are most common. The need for a double wire depends upon the takeoff and the size of the side branch. Two balloons can be inflated simultaneously if the proximal vessel is of large enough size, and the two distal vessels are at least one-third smaller than the proximal. More often, however, each individual lesion is dilated separately. If the side branch itself is not diseased and does not arise directly out of the stenosis, then it has been our practice not to place the guidewire in the side branch unless flow is reduced following initial dilation of the primary lesion. In order to be ready for this possibility a double back-bleeding device needs to be used.

Tandem Lesions

If the tandem lesions are located close to one another then a long balloon (3–4 cm) is advantageous. If the stenoses are separated by more than 4 cm, then it is advis-

able to dilate the proximal lesion before the distal lesion in order to provide continuous flow to the proximal lesion while the distal is being dilated. An alternative strategy is to use two balloons, one for the proximal lesion and one for the distal, where both are inflated at the same time. This is a particularly advantageous strategy when using fixed-wire systems, since multiple recrossing of the lesions is not necessary.

Heavily Calcified Lesions

Very low profile balloons facilitate passes through heavily calcified lesions; however, because of the high pressures required (e.g., 12–25 atmospheres) high-pressure balloon catheters should be used. The USCI probe offers a balance between very low profile and relatively high pressure tolerances. However, when even higher pressures may be anticipated, the use of a SciMed Strong balloon or other high pressure balloons that can be inflated to 20 atmospheres may be necessary.

Total Occlusions

A detailed description to the approach to total occlusions is contained in Chapter 10.

Diffuse Disease

Diffuse disease is most commonly defined as presentation of a 2-cm long segment showing at least 50% narrowing. These lesions have a significantly higher risk of abrupt closure and dissection, as well as restenosis, than discrete lesions. The use of long balloons can significantly improve the success relative to complications. Alternatively, devices such as the rotablator and excimer laser have been used effectively in this setting.

Very Large Vessels

Two different techniques have been used to tackle this problem. First, large peripheral angioplasty balloon catheters (5–7 mm in diameter) can be used to dilate straight, large vessels, particularly saphenous vein grafts. However, their flexibility and trackability are less than optimal, and an alternative technique of “kissing balloons” can be used effectively. Here, two balloons are inflated simultaneously in a fashion similar to that used in a bifurcation lesion. One disadvantage of the technique is that the two balloons result in a twice diameter in one direction but one diameter change in the other resulting in asymmetric dilations of the artery. Despite

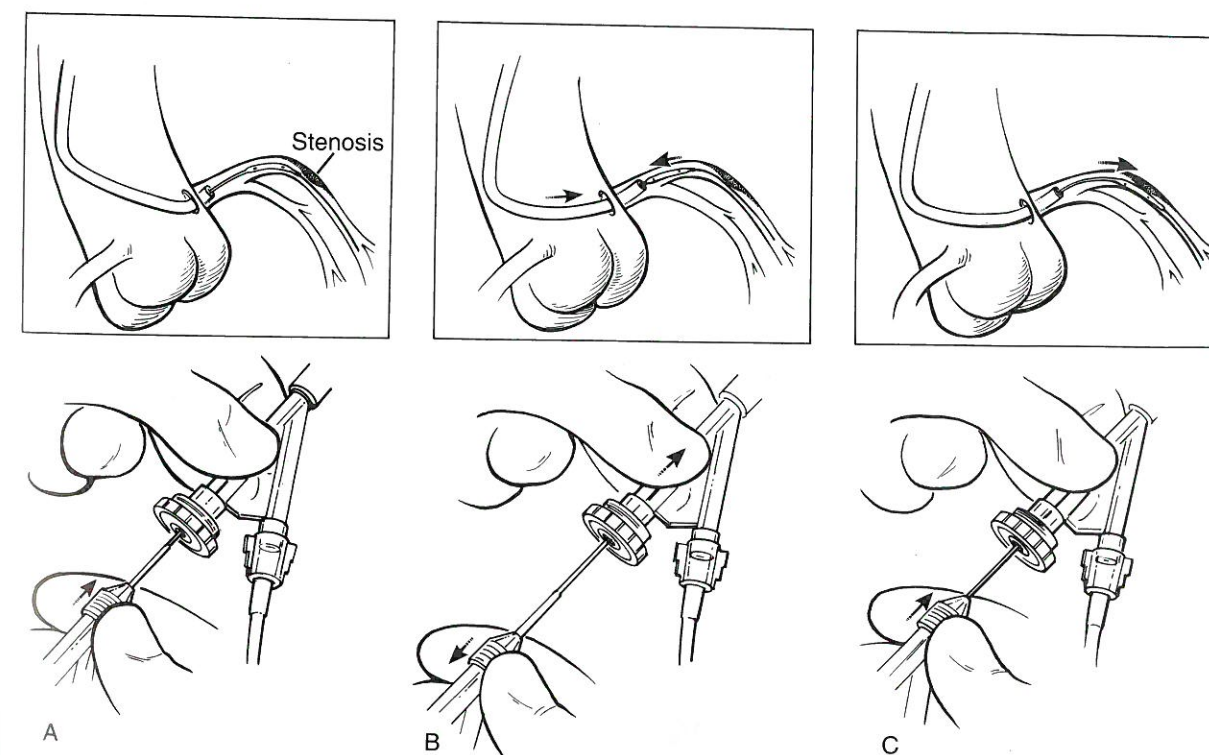


FIG. 8. The push-pull maneuver is illustrated. In order to provide a firm guide position when attempting to cross a severe stenosis (A), the guide is advanced over the balloon while pulling gently on the balloon (B). This will pull the guiding catheter into the coronary artery. Then, holding the guide catheter firmly in place, the balloon can be further pushed through the stenosis (C).

this, however, the technique is usually effective when encountering this situation.

Catheter and/or Wire Manipulation

Push-Pull Technique

Passage of the balloon through a tortuous vessel or tight stenosis can often be difficult. In this setting the guiding catheter should be pulled into the coronary ostium over the balloon and wire by placing slight tension on the balloon catheter and gently pushing forward the guiding catheter. Then, by holding the guiding catheter in place, the balloon can be moved forward while gently pulling back on the guidewire. Gradual intubation of the guiding catheter down the coronary artery and into a

firm, stable position can be sequentially done until the proper amount of force is achieved in order to cross the lesion (Fig. 8).

Wire Shaping

The tip of the guidewire should be reshaped to the size and the degree necessary to negotiate the stenosis (Fig. 9). This can be done by using a hemostat that is gently pulled over the tip of the shaping ribbon. This method, however, usually results in a large gentle curve that is often not short enough for routine use. A preferable technique is to hold the guidewire in one hand and catch the tip of the other wire between the first finger and thumb, squeezing the wire in order to create the small curve. The fingers can be rolled backward in order to make a small

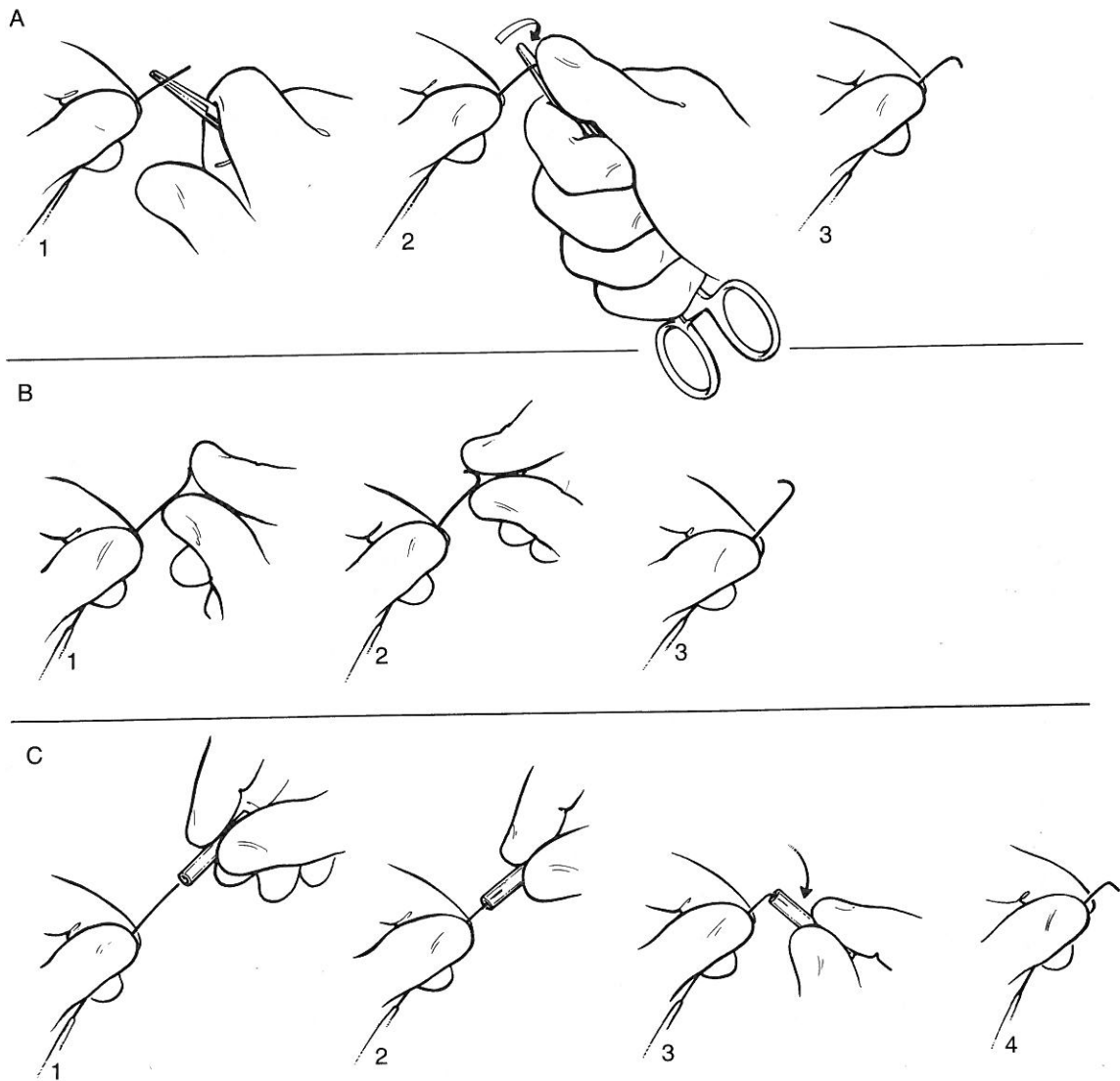


FIG. 9. The various methods commonly used to shape the guidewire are illustrated. A: Use of a hemostat or needle to shape the tip. B: Pinching the tip of the wire between the fingers. C: Use of a small plastic tube to hold the tip while it is bent.

tip at the end and, when at least some curve is generated, further bending is easier. An alternative method is to use a small plastic tube placed over the tip of the wire which then can be bent in order to trap the wire and facilitate its shaping (Fig. 9C). In some circumstances two bends are necessary; one at the tip and one 2 cm back. This secondary bend is very helpful in turning the wire into the circumflex artery or to a superiorly directed left anterior descending artery. The distance between the primary and secondary bend should be tailored to match the degree of turn and the location of the tip of the guiding catheter.

Retrieval

Rarely, guidewires or tips of balloon catheters can break off and become lodged in coronary vessels (15–17). Several techniques have been used to retrieve these fragments (Fig. 10). One technique involves use of a very flexible guidewire which is bent back and then sutured to the tip of a balloon catheter or probing sheath. The wire passing through the center of the catheter then can move either forward or backward in order to form a snare which can trap the broken fragment and pull it out. Alternatively a 300-cm exchange wire can be bent in the middle and the two wires can be passed through a larger probing sheath to form a snare. Alternatively, a high

torque floppy guidewire can be placed through a probing sheath, and the tip can be bent back and wedged into the probing sheath, likewise forming a snare in order to remove foreign material. Another technique that can be used is a passage of two separate guidewires than can be tied together at their tip to form a basket and which, once across the pertaining material, can be twisted in order to trap the material between the two wires and pull it out. Finally, material can be removed by inflating the balloon catheter at extremely low pressure (e.g., 1–2 atmospheres) and gradually pulling back. The friction of the balloon across the retained balloon or wire can help draw it back into the guiding catheter. It is essential with any of these techniques that the guiding catheter remain firmly in place in the coronary artery to avoid embolization of the material into the aorta. Once the fragment is within the guiding catheter than the entire catheter can be removed from the patient.

A more common situation is the breakage of an angioplasty wire due to entrapment of the tip within a small branch. Initially, the wire is still attached to itself through the outer coil wire. This can be recognized by a gap in the radiolucent part of the wire. In addition, it should be appreciated that this has occurred if pulling back on the wire results in no change in the tip of the guidewire within the coronary artery. Rather than continuing to pull back on the wire and further uncoil the

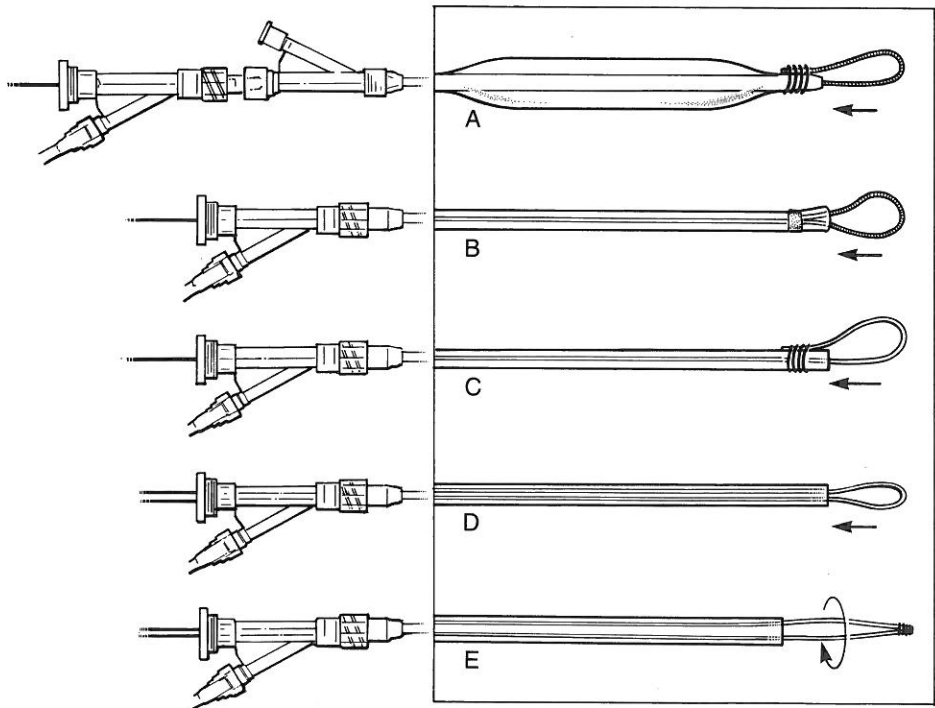


FIG. 10. The various snare devices used to retrieve broken guidewires and catheters from within the coronary system. A: A guidewire sutured back onto the balloon catheter. B: A commercially available guidewire snare catheter (retriever-18; Target Therapeutics, Fremont, CA). C: A wire is sutured to the tip of a probe sheath. D: An exchange wire is looped through the probe sheath. E: Two guidewires are sutured at the tips to create a wire basket which can be rotated and used as a snare.

outer wire risking the possibility of breakage, it is safer to gradually push the balloon catheter back over the broken wire and down over the tip of the wire. The entire balloon and wire within it can then be removed together. This method allows the tip of the balloon to help dislodge the wire and free it as well.

References

1. Avedissian MG, Kileavy EC, Garcia JM, Dear WE. Percutaneous transluminal coronary angioplasty: a review of current balloon dilation systems. *Cathet Cardiovasc Diagn* 1989;18:263-275.
2. Jain J. Effect of balloon pressure on angioplasty balloon. *Am J Cardiol* 1986;57:26-28.
3. USCI Product Information, USCI Division of BARD, Billnea, MA.
4. ACS Product Information, Advanced Catheter Systems, Clara, CA.
5. SciMed Product Information, SciMed Corp., Maple Grove, MN.
6. Berry KJ, Drew TM, McKendal L, Sharaf BL, Thomas ES, Williams DO. Balloon material as a risk factor for coronary angioplasty procedural complications. *Circulation* 1991;84:II-130.
7. Ferguson JJ, Parnis SM, Fuqua JM. Inaccuracies in manufacturer-reported PTCA balloon profiles. *Cathet Cardiovasc Diagn* 1992;25:101-106.
8. Cordis Product Information, Cordis Corp, Miami, FL.
9. Fincin L, Meier B, Roy P, Steffenino G, Rutinhausner W. Clinical experience with a monorail balloon catheter for coronary angioplasty. *Cathet Cardiovasc Diagn* 1988;14:206-212.
10. Stack RS, Quigley PJ, Collins G, Phillips HR. Perfusion balloon catheter. *Am J Cardiol* 1988;61:77g-80g.
11. Leitschuh MA, Mills RM, Larosa D, Jacobs AK, Ruocco NA, Faxon DP. Outcome after major dissection during coronary angioplasty using a perfusion balloon catheter. *Am J Cardiol* 1991;67:1056-1060.
12. Ohman EM, Marquis JF, Ricci DR, Brown R, Knudston ML, Kereiakes DJ, Samaha JK, Margolis JR, Niedermann A, Dean L, Gurbel P, Sketch M, Wilderman N, Lee K, Califf R. The effect of gradual prolonged inflation during angioplasty on inhospital long-term outcome: the results of a multicenter randomized trial. *J Am Coll Cardiol* 1992;19:33A.
13. Savas V, Puchrowicz S, Williams L, Grines C, O'Neill W. Angioplasty outcome using long balloons and high risk lesions. *J Am Coll Cardiol* 1992;19:34A.
14. Zider J, Tenaglia A, Jackman J, Fortin D, Frid D, Chung T, Cheng J, Royal S, Krucoff M, O'Conner C, Stack R. Improved acute results for PTCA of long coronary lesions using long angioplasty balloon catheters. *J Am Coll Cardiol* 1992;19:34A.
15. Hartzler S, Rutherford BD, McCohaham DR. Retained percutaneous transluminal coronary angioplasty equipment components and their management. *Am J Cardiol* 1987;60:1260-1264.
16. Serota H, Deligonul U, Lew B, Kern M, Aquire F, Vandormael M. Improved method for transcatheter retrieval of intercoronary detached angioplasty guidewire segments. *Cathet Cardiovasc Diagn* 1989;17:248-251.
17. Crone J, Morgan MJ. Complications of cardiac catheterization and angiography: prevention and management. New York: Futura Publishing Company; 1989.