
Hemopump® left ventricular support in the peripartum cardiomyopathy patient

The Hemopump® temporary cardiac assist system underwent clinical trials within the United States from 1988 to 1991. Use of the device proved life-saving in providing left ventricular assistance for failing hearts. Presentation of a case study demonstrating the effects of Hemopump support is provided along with a detailed nursing care plan. A brief discussion of peripartum cardiomyopathy is also included. Key words: cardiac assist system, Hemopump, peripartum cardiomyopathy

Nancy L. Abou-Awdi, MS, RN, CCRN, CCRC

*Research Coordinator
Transplant Services*

Kathleen A. Joseph, BSN, RN, CCRN
Clinical Educator

*Cardiovascular Recovery ICU
St Lukes Episcopal Hospital
Houston, Texas*

THE HEMOPUMP® (Johnson and Johnson Interventional Systems, Inc., Rancho Cordova, Calif) was used in clinical trials at 10 centers in the United States from 1988 to 1991 (Fig 1). It was developed as a temporary cardiac assist system to provide less invasive assistance for the failing ventricle. Its indications for use included cardiogenic shock secondary to acute myocardial infarction, failure to wean from cardiopulmonary bypass following cardiac surgery, or patients who did not fall into either of the above categories but met the hemodynamic criteria for insertion.¹

Hemodynamic criteria for use of the Hemopump were similar for that of other

ventricular assist devices (VADs), including systolic blood pressure of less than 90 mm Hg, cardiac index less than 2.0 L/min/m², and pulmonary wedge pressure (PWP) greater than 18 mm Hg. In addition, the patient must be refractory to volume and pharmacologic therapy.¹ Patients awaiting cardiac transplantation were excluded for use of the Hemopump, as were those with prosthetic aortic valves or severe aortic valve stenosis/insufficiency, severe aortic wall disease, peripheral arterial disease, blood dyscrasias, and end-stage terminal disease.

MODE OF OPERATION

The Hemopump is an interarterial axial flow system using a rotating pump. Remarkably, its operating components are encased in an area the size of a pencil eraser. Access for the system is through a large artery. The most common site for insertion is the femoral artery (Fig 2). Other sites used include the iliac, distal abdominal aorta, and thoracic ascending aorta. Insertion requires a surgical incision to expose the vessel, followed by an arterio-

J Cardiovasc Nurs 1994;8(2):36-44
© 1994 Aspen Publishers, Inc.

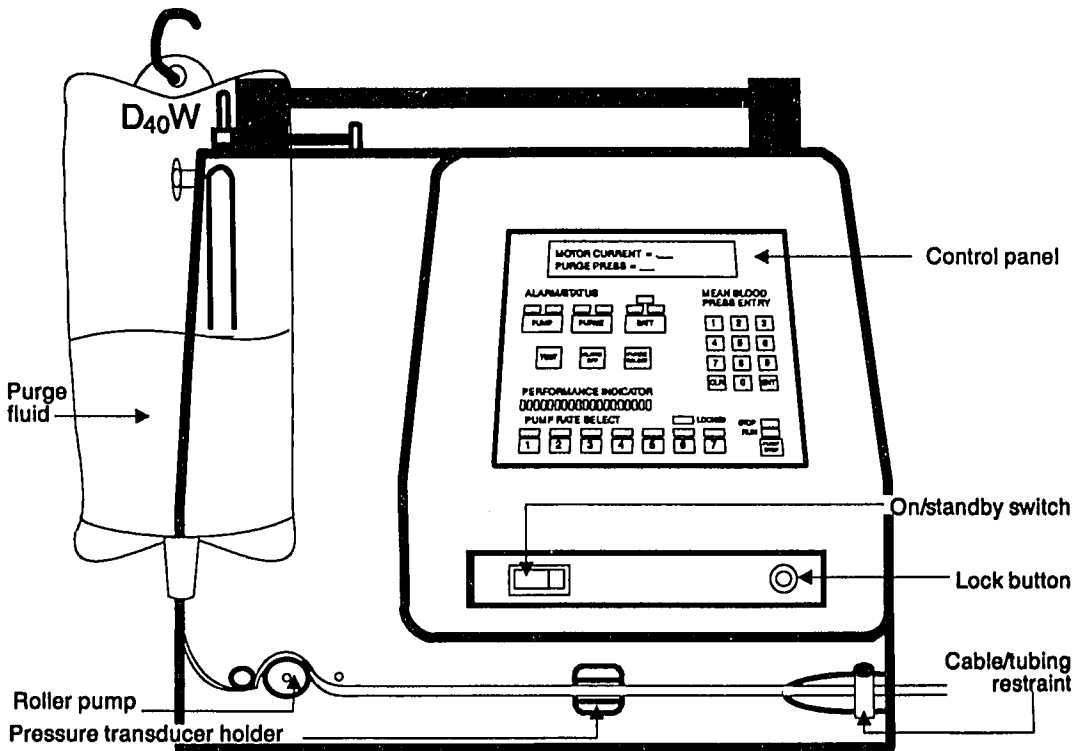


Fig 1. The Hemopump console.

tomy and anastomosis of a 12 mm Dacron graft to the artery. The Hemopump cannula and drive cable are inserted through the Dacron graft into the artery. A silicone plug at the distal end of the graft seals the unit to prevent bleeding. The pump is then advanced to the descending aorta, over the arch, traversing the aortic valve, and placed in the left ventricle (Fig 3). Fluoroscopy is usually used to guide insertion.^{2,3}

When in proper position, the Hemopump cannula is in the left ventricle, and the pump is proximal to the aortic arch. Blood is actively drawn from the left ventricle through the cannula to the pump, where the blood is mixed with dextrose 40% by rotating blades then thrust over stationary blades into systemic circulation. Rotation of the blades occurs at speeds up to 27,000 revolutions per minute (RPMs).⁴ Dextrose

40%, infused at 12 to 18 mL/h is used as a lubricant for the pump and drive cable. This is believed to reduce platelet destruction and cool the system.

Power to the pump is transmitted via a flexible drive shaft from an external motor and rotating magnet. The console provides the electrical supply to power the motor and a roller pump to deliver the purge fluid (dextrose 40%). A control panel on the console contains the controls for roller pump rate and pump speed. A display panel on the console indicates system alarm status. Two rechargeable batteries provide back-up power in case of power loss or transporting of patients.^{5,6}

The Hemopump is capable of providing a cardiac output of up to 3.5 L/min independent of cardiac function. Cardiac output support is continuous and nonpulsatile.

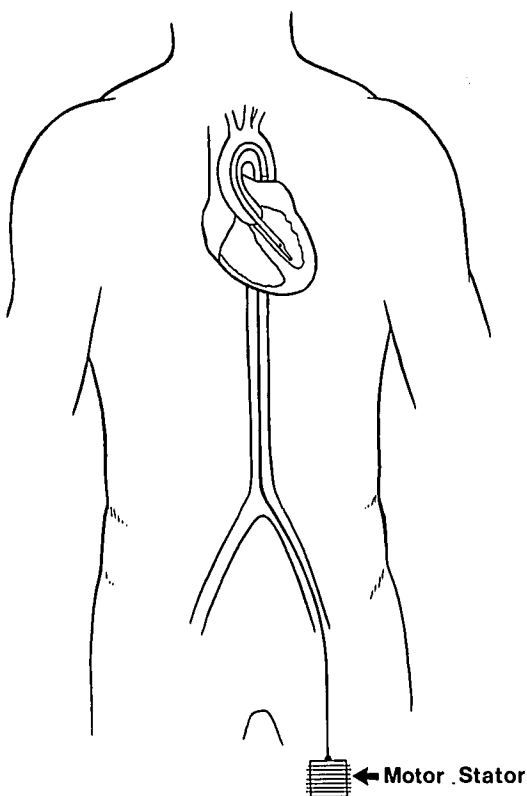


Fig 2. Femoral insertion of Hemopump.

Principles of support are to reduce ventricular preload and afterload, thereby decreasing ventricular workload and myocardial oxygen consumption allowing the heart a chance to rest, recover, and regain its pumping ability.¹

Advantages of this system over traditional VADs include percutaneous access not requiring an open thoracotomy, which reduces the risks of infection, bleeding, and prolonged anesthesia time. It can be inserted in the cardiac catheterization laboratory, which allows for rapid utilization during emergencies. Compared with intraaortic balloon pumps, the Hemopump is capable of providing complete cardiopulmonary support in the presence of cardiac instability.

The following case study presents several options for treating peripartum cardiomyopathy, including use of the Hemopump. Because this device is still investigational, it was fortunate that the patient presented here was referred to a center included in the clinical trials of the Hemopump.

CASE REPORT

A 34-year-old primigravida, at 33 weeks' gestation, began having shortness of breath that she assumed was "just a part of being pregnant." After a few days with increasing dyspnea, she went to see her obstetrician and was subsequently hospitalized. On admission, she was dyspneic with peripheral edema. Chest radiograph revealed pulmonary edema and cardiomegaly. Stabilization of her condition was accomplished with digoxin, diuretics, fluid restriction, and bed rest. On Day 5 of her hospitalization, a caesarian section was performed, which resulted in the delivery of a healthy infant at 34 weeks' gestation.

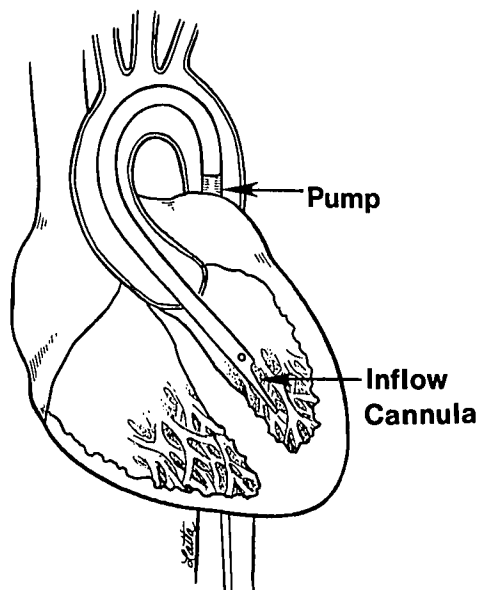


Fig 3. Placement of Hemopump in left ventricle.

Her condition again began to deteriorate on the evening of delivery as evidenced by oliguria resistant to fluid challenges. By the next morning, her condition had deteriorated substantially. She was severely dyspneic, lethargic, and hypotensive and was in metabolic acidosis. Treatment at this time consisted of inotropic support, intubation, and mechanical ventilation.

Her condition continued to deteriorate. An intraaortic balloon pump (IABP) was inserted percutaneously, and an isoproterenol infusion was added. With no improvement in her condition, she was emergently taken to the cardiac catheterization lab, where a left heart catheterization was performed revealing a cardiac index of 1.8 L/min/m² and a left ventricular ejection fraction of less than 20%. During the procedure, peripheral pulses were lost distal to the IABP site, and the IABP was removed. In spite of the addition of epinephrine and norepinephrine infusions, hypotension continued. She was placed on right heart bypass (a percutaneous, centrifugal, cardiopulmonary support system). With her condition continuing to deteriorate, a referral was made to a major cardiovascular surgical center for further evaluation and treatment.

On admission, she presented intubated and in respiratory distress, on right heart support, in hepatorenal failure, and with a disseminated intravascular coagulopathy. Admission hemoglobin was 5 mg/dL with a boggy uterus, oozing from cannulation sites and the abdominal incision. Due to excessive bleeding, she was emergently taken to the operating room. She was placed on cardiopulmonary bypass, and right heart support was removed. She was weaned from cardiopulmonary bypass and, in stable condition, returned to the cardiovascular recovery room. Numerous transfusions with various blood components were required to reverse her coagulopathy. Laboratory values for hepatic and renal function continued to worsen. Pharmacologic support consisted of dopamine, dobutamine, epinephrine, and norepinephrine infusions.

Later that evening, her condition again deteriorated in spite of maximal pharmacologic support, and an IABP was inserted percutaneously. Oliguria progressed to anuria, and continuous arteriovenous hemofiltration was started for fluid removal. Over the next several days,

With her condition continuing to deteriorate, a referral was made to a major cardiovascular surgical center for further evaluation and treatment

her condition remained labile, requiring constant titration of vasoactive pharmacologic agents and administration of blood components.

On the 12th day of her hospitalization, she developed ventricular tachycardia refractory to treatment with drugs or cardioversion. IABP support became ineffective secondary to the ventricular tachycardia, and again her hemodynamic status deteriorated. The patient was taken to the operating room, where the Hemopump was inserted directly into the abdominal aorta via an abdominal incision. Over the next several days, it became obvious that this woman's heart was not going to recover. Several attempts were made to wean the Hemopump, but hemodynamic deterioration would occur with each attempt. After about a week of support, she was evaluated for cardiac transplantation and placed on the active cardiac transplant list.

One week later, a suitable heart became available, and although her condition was not optimum for transplant, a decision was made to do the transplant. Due to her critical condition at the time of transplantation, the Hemopump was not removed when she was placed on cardiopulmonary bypass. Instead it was pulled back into the aorta and placed at the lowest setting. When the donor heart was in place, the Hemopump was again advanced into the left ventricle and returned to pretransplant settings.⁷ Weaning and removal of the Hemopump occurred over the next 2 days.

Recovery after transplant was slow but complete. Pulmonary, hepatic, and renal function returned to normal within a month posttransplant. Her course was further complicated by persistent fever. An indium scan revealed potential areas of infection in the uterus. A total abdominal hysterectomy was performed, and her fever subsided and recovery continued.

Two months posttransplant she was discharged from the hospital, and she was able to return to work part time and to motherhood full time.

DISCUSSION

Peripartum cardiomyopathy develops in the last month of pregnancy or in the first 6 months after delivery. In spite of a low incidence (between 1 in 1,500 and 1 in 4,000 pregnancies), this is a devastating event at a time when families are prepared for a blessed event. Exact etiology is unknown; however, speculations include a nutrition deficiency, small coronary vessel abnormalities, intimal thickening of intramural coronary arteries, and hormonal and autoimmune response to fetal antigens.⁸ Symptomatology consists of dyspnea, fatigue, and peripheral edema. Chest radiograph demonstrates cardiomegaly and pulmonary edema. Electrocardiographic findings include low-voltage QRS complexes, conduction defects, and dysrhythmias.⁹

Most patients (approximately 60%) are managed medically and recover completely with normal cardiac function. There is a tendency for recurrence in subsequent pregnancies; therefore, future pregnancies are not recommended.¹⁰ Patients such as the one presented are challenging for all involved in their care. Initial concerns are to deliver a viable, healthy infant, while stabilizing the mother. This is usually accomplished with fluid restrictions, digoxin, diuretics, and bed rest. Both mother and infant need continuous monitoring, and timing of delivery is essential.

Postdelivery, when this patient's condition became labile and medical therapy alone proved unsuccessful, an IABP was inserted to augment cardiac output and reduce afterload. With the loss of peripheral pulses distal to percutaneous insertion, this option was abandoned. Mechanical circulatory support was then accom-

plished with right heart bypass consisting of a centrifugal pump and oxygenator (extracorporeal membrane oxygenation, ECMO). Cannulation for this system is accomplished via the femoral artery and vein. Blood is removed from a cannula in the femoral vein, pumped through a heat exchanger to maintain temperature and a membrane oxygenator to provide dioxygen (O₂) and remove carbon dioxide (CO₂). The blood is then returned via the femoral artery. Disadvantages include the need for systemic anticoagulation and the potential for thromboembolism.^{11,12}

As this case study demonstrates, the Hemopump is capable of providing support for patients in severe left ventricular failure and of providing adequate end-organ perfusion so that irreversible damage does not occur. Although this patient's myocardial function could not be reversed, she was successfully supported to transplant and posttransplant until function of the donor heart was satisfactory.

• • •

Clinical trials for the Hemopump were approved by the Food and Drug Administration (FDA) under an investigational device exemption for use in patients with reversible left ventricular failure but not as a bridge to cardiac transplantation. This patient met criteria for insertion based on hemodynamic status and the potential for reversing her heart failure.

The Hemopump is not available in the United States for reversible heart failure; however, usage for this condition continues in Canada, Australia, and Europe for both reversible and nonreversible left heart failure. Research and development continue on the Hemopump, and future clinical trials are being planned for clinical sites in the United States. Clinical trials initi-

ated in August 1993 will evaluate a new transaortic Hemopump with the capability of providing a cardiac output of 5.0 L. It

will require implantation via a sternotomy and will be limited to patients undergoing selected cardiac surgical procedures.¹

REFERENCES

1. Rountree WD. The Hemopump temporary cardiac assist system. *AACN Clin Issues Crit Care Nurs*. 1991;2(3):562-574.
2. Duncan JM, Frazier OH, Radovancevic B, Velebit V. Implantation techniques for the Hemopump. *Ann Thorac Surg*. 1989;48:733-735.
3. Rountree WD, Barbie RN, Neichin JN, Neichin M, Johnson & Johnson HEMOPUMP temporary cardiac assist system. In: Quaal SJ, ed. *Cardiac Mechanical Assistance Beyond Balloon Pumping*. St. Louis, Mo: Mosby-Year Book; 1993.
4. Frazier OH, Nakatani T, Duncan JM, Parnis SM, Fuqua JM. Clinical experience with the Hemopump. *ASAIO Transactions*. 1989;35:604-606.
5. Rutan PM, Riehle RA, Julian TE. *Hemopump Training Course: Management of the Patient with the Nimbus Hemopump*. Rancho Cordova, Calif: Nimbus Medical; 1989.
6. Abou-Awdi NL, Rountree WD, Kelly AM, Rutan PM. New support for the failing heart. *Am J Nurs*. 1991;91(1):38-41.
7. Duncan JM, Baldwin RT, Frazier OH. Preoperative and postoperative support for patients undergoing orthotopic heart transplantation. *Ann Thorac Surg*. 1992;53:349-350.
8. Homans DC. Peripartum cardiomyopathy. *N Engl J Med*. 1985;312:1,432.
9. Alpert JS, Rippe JM. Cardiomyopathy, myocarditis, and rheumatic fever. In: *Manual of Cardiovascular Diagnosis and Therapy*. 3rd ed. Boston, Mass: Little, Brown; 1991.
10. Drummond SB. Cardiac disease in pregnancy. *Crit Care Nurs Clin North Am*. 1992;4(4):659-665.
11. Dirkes S, Dickinson S, Valentine J. Acute respiratory failure and ECMO. *Crit Care Nurse*. 1992;12(7):39-47.
12. Bavin TK, Cohen SE. Bard cardiopulmonary support system. In: Quaal SJ, ed. *Cardiac Mechanical Assistance Beyond Balloon Pumping*. St. Louis, Mo: Mosby-Year Book; 1993.

Appendix

Management of the Hemopump patient: Patient care plan

Nursing diagnosis Cardiac output, alteration in, decreased as evidenced by left ventricular dysfunction, decreased circulating fluid volume, changes in systemic vascular resistance, alterations in electrical conduction, or pump malfunction/misplacement.

Expected outcome Blood pressures; filling pressures; heart rate, rhythm, and conduction; cardiac output; systemic vascular resistance; peripheral pulses; and urine output are within acceptable limits.

Interventions

Monitor heart sounds.
Monitor point of maximal impulse (PMI).
Document cardiac dysrhythmias.
Measure pulmonary artery pressures (PAP).
Measure pulmonary wedge pressure (PWP).
Measure central venous or right atrial pressure (CVP/RAP).
Measure cardiac output and calculate cardiac index (CO/CI).
Calculate systemic vascular resistance (SVR).
Monitor body temperature.
Monitor peripheral and dependent edema.
Monitor effects of intravenous fluid therapy.
Monitor ECG changes.
Administer and monitor vasoactive drugs as indicated.
Monitor peripheral pulses.
Monitor urine output.
Monitor and assess effectiveness of the Hemopump (arterial waveform analysis).
Monitor effectiveness of Hemopump weaning.
Monitor and assess lung sounds.

Nursing diagnosis Tissue perfusion, alteration in, decreased secondary to decreased cardiac output, hypovolemia and hypotension; invasive device in vascular system

Expected outcome Adequate tissue/organ perfusion is made evident by stable blood pressure, palpable peripheral pulses, warm and dry skin, improved mentation and adequate urine output.

Interventions

Note changes in mental status.
Assess for pallor, cyanosis, mottling, and cool, moist skin.
Note presence and quality of peripheral pulses and capillary refill.
Note color, motion, and sensitivity (CMS check) of extremities.
Observe for increasing cyanosis in restrained or cannulated extremities.
Auscultate bowel sounds.
Note pain, nausea, and vomiting.
Monitor urine hourly; measure specific gravity.
Monitor lab values.

Nursing diagnosis Gas exchange, impaired, as evidenced by pulmonary congestion and decreased cardiac output; or atelectasis secondary to anesthesia, pain, interstitial edema, and immobility.

Expected outcome Improved ventilation and oxygenation are evident by arterial blood gases (ABGs) within the patient's normal limits and absence of cyanosis and/or atelectasis.

Interventions

Maintain a patent airway.

Evaluate respiratory function.

Monitor patient's respiratory rate and effort while on the ventilator.

Auscultate breath sounds.

Monitor serial ABGs.

Provide supplemental oxygen as needed.

Monitor for signs of hemothorax or pneumothorax.

Note character and amount of secretions.

Nursing diagnosis Infection, potential for, secondary to placement of invasive lines, debilitated state.

Expected outcome Afebrile, absence of chills, lungs clear with sputum of normal color and character, urine clear and odor free, incision and insertion sites clean.

Interventions

Maintain aseptic technique.

Follow established protocol for incision and insertion site care.

Follow established protocol for line care and changes.

Change purge fluid bag (D40W) while the Hemopump system is running.

Note heart rate elevation.

Note temperature elevation, diaphoresis, or chills.

Note cloudy or odoriferous urine.

Note changes in character of sputum.

Monitor laboratory values.

Obtain cultures as needed.

Administer prophylactic antibiotics with Hemopump use.

Nursing diagnosis Hemopump system malfunction, potential for, associated with electrical or mechanical failure.

Expected outcome Evidence of normal Hemopump system function.

Interventions

Monitor and record purge pressure, note fluctuations.

Monitor and record motor current level, note fluctuations.

Monitor and record seal flow, note fluctuations.

Observe for kinks in the purge assembly or sheath.

When system alarms, refer to the trouble-shooting guide in the "Directions for Use," and start appropriate trouble-shooting actions.

Avoid covering the motor in order to prevent heat buildup.

Check placement with daily chest radiograph.

Nursing diagnosis Anxiety/fear related to severity of condition, intensive care environment, and powerlessness; altered role performance; use of experimental circulatory support.

Expected outcome Patient and/or significant other(s) verbalize feelings and concerns; demonstrate reduction of level of anxiety and fear with provision of information and emotional support.

Interventions

Assess patient's anxiety level.

Assess anxiety level of significant others as able.

Maintain a quiet, controlled environment.

Provide referral to clergy, hospital social worker, or other appropriate support system.

Provide the significant other(s) with frequent information about the patient's condition.

Provide the significant other(s) with information about the machinery, other team members, and procedures.

Nursing diagnosis Nutrition, altered; less than body requirements, related to catabolism associated with major surgery; preoperative anorexia; increased nutrient requirements related to fever, blood and plasma loss, repair of damaged tissues; lack of oral intake.

Expected outcome Alternative methods of caloric intake will be started to meet metabolic requirements; baseline body weight will be maintained.

Interventions

Administer prescribed diet as soon as patient will tolerate it.

Prevent conditions that increase nutritional requirements (eg, infection, sepsis).

Monitor daily weight.

Monitor skin turgor.

Monitor muscle strength.

Monitor blood chemistries.

Have nutritional consult done by dietitian.

Nursing diagnosis Sleep pattern disturbance related to intensive care environment; fear and anxiety.

Expected outcome Orientation to environment, person, day/night as long as neurologic integrity is intact.

Interventions

Orient to day/night cycle.

Dim lights at night.

Arrange for frequent rest periods.

Establish a sense of trust, and remind the patient that he or she is being monitored even while asleep.

Observe for signs of sleep deprivation.