


W. Flameng, (Ed.)

# Temporary Cardiac Assist with an Axial Pump System



Dt. Zentralbibliothek f. Medizin  
1992 A 1708



1992

A

1708

Steinkopff Verlag Darmstadt  
Springer-Verlag New York



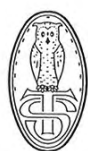1 and Ine

---

W. Flameng (Ed.)

# Temporary Cardiac Assist with an Axial Pump System

---



Steinkopff Verlag Darmstadt  
Springer-Verlag New York



(1991)

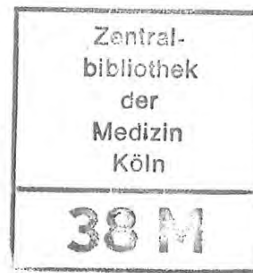
1992

7

1708

Editor:

Willem Flameng M.D.  
Department of Cardiac Surgery  
Katholieke Universiteit Leuven  
B-3000 Leuven  
Belgium



Akz Nr  
92 ZB.1872

Cover illustration:

Study of Archimedes's screw-driven  
water pump by Leonardo da Vinci,  
ca. 1475–80.  
Milan, Ambrosiana, Codex Atlanticus

Die Deutsche Bibliothek – CIP-Einheitsaufnahme

**Temporary cardiac assist with an axial pump system / W.**  
Flameng (ed.). – Darmstadt : Steinkopff ; New York : Springer,  
1991

ISBN 3-7985-0906-9 (Steinkopff)

ISBN 0-387-91413-7 (Springer)

NE: Flameng, Willem [Hrsg.]

This work is subject to copyright. All rights are reserved whether the whole or part of the material is concerned, specifically the rights of translation, reprinting, re-use of illustrations, recitations, broadcasting, reproduction on microfilms or in other ways, and storage in data banks. Duplication of this publication or parts thereof is only permitted under the provision of the German Copyright Law of September 9, 1965, in its version of June 24, 1985, and a copyright fee must always be paid. Violations fall under the prosecution act of the German Copyright Law.

Copyright © 1991 by Dr. Dietrich Steinkopff Verlag GmbH & Co. KG, Darmstadt  
Medical Editorial: Sabine Müller – English Editor: James C. Willis – Production: Heinz J. Schäfer

Printed in Germany

The use of registered names, trademarks, etc., in this publication does not imply, even in the absence of a specific statement, that such names are exempt from the relevant protective laws and regulations and therefore free for general use.

Type-setting, printing and bookbinding: Druckhaus Darmstadt  
Printed on acid-free paper

Prefa

With th  
and the  
with a  
R. K. W  
has not  
time ag  
investig  
cardiac  
say, crit  
our coll  
analyze  
side-eff  
revoluti  
Leuven

## Preface

With this book, it was not our intention to provide a complete "textbook" on axial pumps and their use as temporary cardiac assist systems. It is more a sharing of experiences with a novel left-ventricular assist system, the Hemopump, as it was developed by R. K. Wampler. This device, marketed by Johnson & Johnson Interventional Systems, has not yet been widely used and accepted in clinical practice. It was offered to us some time ago to study its applicability in the experimental setting. At the moment, it is under investigation in many centers and it is commercially available. However, as with any other cardiac assist system, the axial pump has its own advantages and limitations. Needless to say, critical analysis of such a novel device is mandatory and, therefore, we are grateful to our colleagues who were willing to contribute to this book. They present, discuss, and analyze their experimental and clinical experience with the Hemopump and focus on side-effects, deficiency and efficiency of this device which, by virtue of its simplicity is revolutionary.

Leuven, Belgium, 1991

Willem Flameng

## Contributors

H. Reul, Ph.D.

Helmholtz Institute for Biomedical Engineering at the RWTH Aachen, Pauwelstrasse 30,  
D-5100 Aachen, FRG

R.K. Wampler, M.D.

Nimbus Medical, Inc., 2890 Kilgore Road, Rancho Cordova, California 95670, USA

K.-H. Scholz, M.D.

Kliniken der Universität Göttingen, Fachbereich Medizin, Zentrum Innere Medizin  
Abt. Kardiologie, Robert Kochstrasse 40, D-3400 Göttingen, FRG

P. Wouters, M.D.

University Clinic Gasthuisberg, Department of Anesthesiology, Herestraat 49,  
B-3000 Leuven, Belgium

O.H. Frazier, M.D.

Texas Heart Institute, 1101 Bates Avenue, Suite P-306, Houston, Texas 77030, USA

U. Mees, M.D.

University Clinic Gasthuisberg, Department of Cardiac Surgery, Herestraat 49,  
B-3000 Leuven, Belgium

O. Jegaden, M.D.

Hôpital Vasculaire Louis Pradel, 59 Boulevard Pinel, F-69003 Lyon, France

D. Loisançe, Ph.D., M.D.

Centre Hospitalier Henri Mondor, Faculté de Médecine, 8 Rue du Général Sarail,  
F-94010 Créteil Cedex, France

W. Flameng, Ph.D., M.D.

University Clinic Gasthuisberg, Department of Cardiac Surgery, Herestraat 49,  
B-3000 Leuven, Belgium

## Contents

Preface . . . . .	V
Contributors . . . . .	VI

### I. Basic Aspects

Hydromechanical principles of axial pumps H. Reul (Aachen, FRG) . . . . .	3
The first co-axial flow pump for human use: the Hemopump R.K. Wampler (Sacramento, California, USA) . . . . .	11
Effect of the Hemopump in cardiogenic shock and in the early stage of regional myocardial ischemia K.H. Scholz (Göttingen, FRG) . . . . .	17
Effects of left ventricular assist using a co-axial flow pump (Hemopump) on organ blood flow during experimental cardiogenic shock P. Wouters (Leuven, Belgium) . . . . .	27

### II. Clinical Aspects

Investigational trials of the Hemopump R.K. Wampler (Sacramento, California, USA) . . . . .	39
Investigational trials of the Hemopump at the Texas Heart Institute: practical issues O.H. Frazier (Houston, Texas USA) . . . . .	47
Success and failure of the Hemopump: a critical analysis U. Mees (Leuven, Belgium) . . . . .	51
Clinical results of Hemopump support in surgical cases O. Jegaden (Lyon, France) . . . . .	61
Hemopump for supported angioplasty. J.L. Dubois-Rande (Créteil, France) . . . . .	67
Indications for the use of the Hemopump W. Flameng (Leuven, Belgium) . . . . .	73

VII

## Clinical results of Hemopump support in surgical cases

O. Jegaden

Hôpital Vasculaire Louis Pradel, Lyon, France

### Introduction

The principle of the Hemopump is to provide a temporary circulatory support in patients with acute cardiac failure. The Hemopump works by unloading the left ventricle and, therefore, by protecting the myocardium. Its mean output ranging from 2 to 4 l/min assures a satisfactory cerebral and visceral perfusion, as demonstrated in the experimental set-up (see chapter 4). In addition, the ability to implant the device without invasion of the mediastinum and surgical trauma to the heart may decrease the incidence of infection and increase the possibility of myocardial recuperation.

Generally, indications of the Hemopump are emergency situations, therefore, the surgical procedure for insertion of the device must be easy, fast, and safe: We developed the femoral insertion without graft, with guidance of the canula by a vascular guide and catheter, allowing easy placement of the tip in the left ventricle.

According to our initial experience with the Hemopump, this device provides effective left-ventricular assistance. However, some limitations of the system will determine the indications of this type of circulatory support.

### Hemopump insertion technique

The most common method of Hemopump implantation is by the left femoral artery approach. Under anesthesia, the common femoral artery is exposed and then clamped. After arteriotomy, a guide wire and a 5F catheter are passed through the distal hole of the

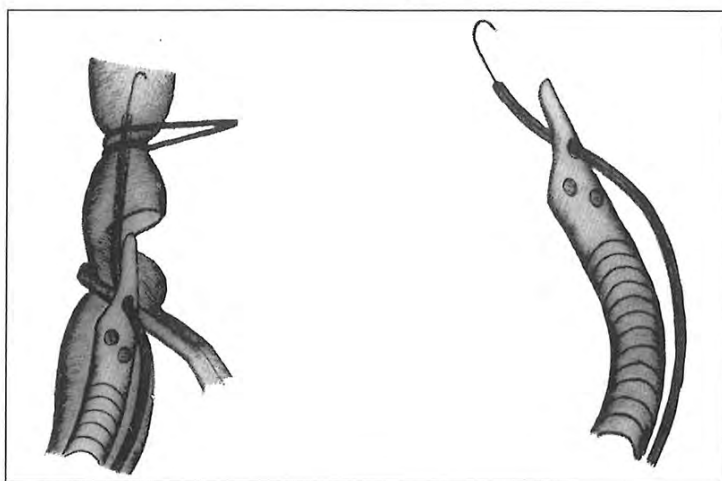


Fig. 1.

canula and introduced into the femoral artery up to the aorta (Fig. 1). Then the canula is introduced into the femoral artery and is pushed into the aorta, guided by the vascular catheter (Fig. 2). Retrograde bleeding through the canula and pumphead is avoided by a silicone occluder of the outflow port of the canula. The occluder is removed just before the drive cable is inserted into the vessel lumen. The femoral artery is then clamped with a silicone loop around the artery, and it is possible to move the Hemopump inserted with the drive cable without bleeding.

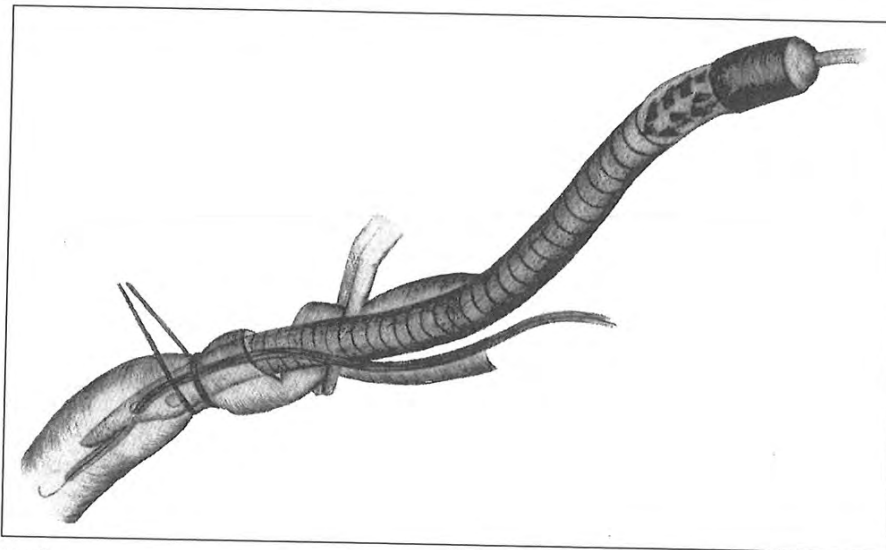


Fig. 2.

Under fluoroscopic guidance, the vascular guide is pushed up to the left ventricle, then the catheter is pushed on the guide, then the canula of the Hemopump is pushed on the catheter up to the left ventricle (Fig. 3). This guidance technique is very effective for the progression of the canula into the aorta, without false route or arterial traumatism, especially when the arteries are of marginal size. The passing through the aortic valve and

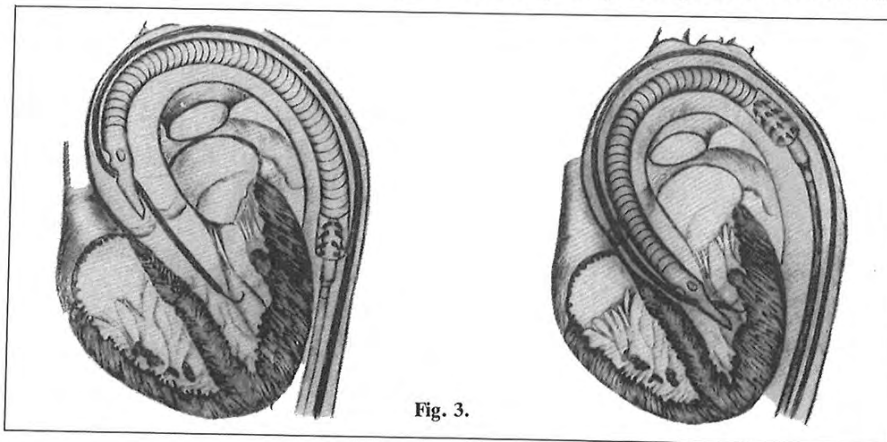


Fig. 3.

the good positioning of the canula into the left ventricle are easier to perform; the ejection of the canula out of the left ventricle is also prevented by this technique. When the position of the canula in the left ventricle is satisfactory, first the catheter is removed and then the guide.

The pump is activated as soon as the tip of the canula is in the ascending aorta. A few separate sutures are performed to close the femoral arteriotomy around the drive cable. The silicone plug fixed around the drive cable close to the artery is attached to the tissue to prevent bleeding or canula moving.

This Hemopump insertion technique is easy, safe, and fast to use in all cases, especially when fluoroscopic guidance can be avoided in a patient who has undergone sternotomy. In all other cases, fluoroscopic guidance is useful. In one case we used an echographic guidance with good result. In our opinion, this may be a good alternative.

#### **Anticoagulative therapy**

Heparin is administered intravenously to maintain an activated clotting time of 1.5 to 2 times control. If the patient had postoperative blood loss or coagulopathy, anti-coagulative therapy is omitted until hemostasis is achieved.

#### **Hemodynamic monitoring and management**

All patients are monitored with continuous electrocardiographic measurements, radial arterial lines, and a pulmonary artery catheter. Cardiac output determinations are made using the standard thermodilution techniques. All attempts are made to provide optimal pump flow, including maintenance of adequate intravascular volume and left-ventricular filling pressure, and by reducing systemic vascular resistance. Additionally, the use of inotropic agents is minimized.

#### **Hematologic studies**

All patients are carefully monitored for rheologic abnormalities. Peripheral blood smears are also routinely examined for evidence of hemolysis.

#### **Device weaning and removal**

Once the patient's heart has adequately recovered, pump speed is gradually reduced from 7 to 1. The pump is not stopped until shortly before removal. Heparin is not reversed. After removal of the device, the cannulation site is inspected for evidence of endotheal damage or thrombus formation. The arteriotomy is then repaired using separate sutures.

#### **Clinical experience**

Five patients in cardiogenic shock were treated with the Hemopump. These patients had acute myocardial infarction ( $n = 3$ ), failure to wean from CPB ( $n = 1$ ), and cardiac allograft rejection ( $n = 1$ ). Failure of femoral insertion occurred in two other patients who had diffuse arteriosclerotic disease; the indications for the use of the Hemopump was failure to wean from cardiopulmonary bypass.

#### *Acute myocardial infarction*

*Case 1:* A 64-year-old man had severe three-vessel disease. His left-ventricular ejection fraction was 66%. Percutaneous transluminal angioplasty of the left anterior descending coronary artery was attempted. Unfortunately, the procedure was complicated by left main dissection, and cardiac arrest occurred. The patient was resuscitated and a Hemopump was placed through the left femoral approach in the catheterization laboratory. As soon as the Hemopump was started, 20 min after arrest, the patient regained consciousness and became hemodynamically stable. He was transferred to the operating room and CABG was performed. The left-ventricular assistance by the Hemopump was started again to wean the patient from the cardiopulmonary bypass for better hemodynamics, and stopped after 30 min, i.e., 4 h after the initial cardiac arrest. One month later, the patient showed a small antero-septal cicatricial myocardial infarction. Nevertheless, left ventricular function remained within normal limits.

*Case 2:* A 68-year-old man had severe double-vessel disease. His left-ventricular ejection fraction was 52%. Percutaneous transluminal angioplasty of the circumflex coronary artery was attempted. The procedure was complicated by circumflex coronary artery dissection, and cardiac arrest occurred. The patient was resuscitated during 1 h before the Hemopump was used. Under left-ventricular assistance by the Hemopump, spontaneous myocardial defibrillation was observed and the patient became hemodynamically stable, but he remained unconscious because of anesthesia or cerebral ischemia; the patient had no emergency CABG. The duration of the left-ventricular assistance was 4 days: the patient regained consciousness, there was no myocardial recuperation, and an antero-lateral myocardial infarction occurred. The patient could be weaned from the Hemopump on day 4, but he died on day 6 of infection and mesenteric infarction secondary to the initial cardiac low output.

*Case 3:* In this case, the indication was a cardiogenic shock 12 h after acute antero-septal myocardial infarction in a 36-year-old woman. During the first 2 days, hemodynamic data were very good under left ventricular assistance by the Hemopump, but there was no sign of myocardial recuperation. The heart became more and more inefficient. On day 3, asystole occurred followed by a severe low cardiac output syndrome. The left-ventricular assistance by the Hemopump was not capable to support the circulation adequately at this time and we decided to implant a biventricular assistance (Abiomed) for 12 days before heart transplantation. This patient died 2 days after transplant from multi-organ failure.

#### *Failure to wean from CPB*

*Case 4:* A 46-year-old man underwent a left-ventricular aneurysm resection with a poor function of the remaining part of the left ventricle. The Hemopump was used to wean him from cardiopulmonary bypass. The duration of the left-ventricular assistance was 3 days and after myocardial recuperation, the patient could be weaned from the Hemopump with good hemodynamic result. Unfortunately, he died on day 4 of cerebral hemorrhage.

#### *Cardiac allograft rejection*

*Case 5:* A 47-year-old man developed a severe cardiac allograft rejection 2 years after a second heart transplantation performed 4 years after the first one. After cardiac arrest

and successful resuscitation, the Hemopump was implanted. Hemodynamic variables were improved during support by the device. The allograft rejection was steroid and OKT3 resistant, and the patient died from multiorgan failure, before retransplantation, and after 8 days of circulatory support by the device.

## Discussion

The duration of the Hemopump support ranged from 4 h to 8 days. The operative time required for device implantation, including confirming the position of the pump by fluoroscopy, was 25 min. All patients tolerated the implantation procedure, and none experienced surgical complications.

The hemodynamic status of each patient improved immediately after initiation of Hemopump support. There was no complication directly related to the use of the device and no drive shaft fractured.

Three of the five patients treated with the Hemopump could be weaned from the device. After removal of the device, all three patients remained hemodynamically stable. No clinical evidence of valvular damage or vascular injury was present, and no patients experienced thromboembolic episodes.

Four of the five patients treated by the Hemopump died. Two patients died after weaning from the Hemopump: one from a non-cardiac cause, and the second from organ failure secondary to the initial low output. The two other patients died because of low output during Hemopump support with a completely failing heart: one before heart retransplantation, and the second after replacement of an extracorporeal assist device followed by heart transplantation.

In fact, the Hemopump is a left-ventricular assist device, but cannot replace the left ventricle. The Hemopump seems to be a good technique of circulatory support for long duration left-ventricular assistance of a still working heart when possibility of myocardial recuperation exists: weaning from CPB, acute allograft failure. It is also a good technique for short-duration left-ventricular assistance of an inefficient heart as a bridge to emergency CABG after angioplasty failure, or as a bridge to angioplasty or CABG during acute myocardial infarction. But the Hemopump seems to be a poor technique for long-duration left-ventricular assistance of an inefficient heart when the hemodynamic output of the patient depends only on the Hemopump: In these cases, the capacity of the device in terms of high pump flows is too low, which renders the risk for irreversible multiorgan failure too high.

In conclusion, the Hemopump is a useful tool in the treatment of patients with potentially reversible cardiac failure.

## References

1. Duncan JM, Frazier OH, Radovancevic B, et al. (1989) Implantation techniques for the Hemopump. *Ann Thorac Surg* 48: 733-735
2. Frazier OH, Wampler RK, Duncan JM, et al. (1990) First human use of the Hemopump, a catheter-mounted ventricular assist device. *Ann Thorac Surg* 49: 299-304
3. Loisanec D, Dubois-Rande JL, Deleuze Ph et al. (1990) Prophylactic intraventricular pumping in high-risk coronary angioplasty. *Lancet* 335: 438-440
4. Wampler RK, Moise JC, Frazier OH et al. (1988) In vivo evaluation of a peripheral vascular access axial flow blood pump. *ASAIO Transac* 34: 450-454