

STATE-OF-THE-ART PAPER

Selection of Coronary Stents

Antonio Colombo, MD, FACC,* Goran Stankovic, MD,* Jeffrey W. Moses, MD, FACC†

Milan, Italy; and New York, New York

In clinical practice, the operator must decide which stent is most appropriate for the patient. This article focuses on the features of stent design that make a specific stent more or less suitable for a particular type of lesion or anatomy: the "average" coronary lesion, the lesion situated on a curve, the ostial lesion, the bifurcational lesion, the lesion located at the left main stem, the calcified lesion, the chronic total occlusion, the small vessel, the saphenous vein graft, acute or threatened vessel closure, and special situations such as coronary aneurysms and perforations. (J Am Coll Cardiol 2002;40:1021-33) © 2002 by the American College of Cardiology Foundation

The implantation of coronary stents is an integral part of most interventional procedures for percutaneous revascularization. The wide acceptance of coronary stenting was based on the results of the BELgian NETHERlands STENT (BENESTENT) (1) and the STent REStenosis Study (STRESS) (2) trials and was facilitated by the elimination of anticoagulant therapy after stent implantation (3-5).

The growing use of stents has stimulated the introduction of a number of different stent designs. Table 1 illustrates the characteristics of most of the stents available in 2002. The rapid increase in the number of designs makes any list quickly outdated. Some stent designs are similar, whereas others differ significantly. There are many reasons why different designs have been proposed. Besides the legal requirement to overcome a specific patent, there are concepts of physiologic mechanisms that stimulated inventors to introduce new designs. A primary concern of stent development was the need to increase flexibility to facilitate safe delivery. Manufacturers try to achieve this goal without compromising radial support and lesion coverage. Another element important for optimizing the clinical utility of a stent is its radiologic visibility.

Many of the engineering considerations in stent design were adopted to improve the global acceptability of the device, rather than making a stent design for a specific type of coronary lesion. In clinical practice, the operator must decide which stent is most appropriate for the patient. This article focuses on the features of stent design that make a specific stent more or less suitable for a particular type of lesion or anatomy.

Types of stents. Stents can be classified according to their mechanism of expansion (self-expanding or balloon-expandable), their composition (stainless steel, cobalt-based alloy, tantalum, nitinol, inert coating, active coating, or biodegradable), and their design (mesh structure, coil, slotted tube, ring, multi-design, or custom design) (Table

1). According to the manufacturers, all stents are suitable for implantation in native coronary arteries of the appropriate size. Some stents are approved for implantation in vein grafts. Few stents are specifically designed to be implanted in a particular lesion. The absolute or relative contraindications to the use of stents apply to stents in general and not to a specific stent. Possible exceptions are the Multilink Ultra Stent (Guidant, Temecula, California), which is designed for vein graft implantation with a nine-cell design, by contrast with the six-cell design of the Multilink Tetra. The JoMed polytetrafluoroethylene (PTFE)-covered stent (JoMed, Rangendingen, Germany) is specifically made for uncommon applications such as coronary ruptures, aneurysms, and degenerated saphenous vein grafts.

Different characteristics such as strut thickness, metal to artery ratio, degree of radiopacity, degree of foreshortening, and recoil of many currently used stents are shown in Table 1. All stents are now available premounted on a dedicated delivery system. The capacity of a stent to span a lesion depends not only on the diameter of the crimped stent (Table 2), but also on the amount of friction of the delivery system and stent, flaring of the distal struts during interaction with the lesion, flexibility of the stent and of the delivery balloon, and pushability of the delivery system. It is not surprising to observe a stent with a larger crossing profile cross a lesion easier than a narrower stent with less flexibility.

Two interesting findings came from the stent versus stent randomized trials: 1) the GR-II stent (Cook, Bloomington, Indiana) proved clearly inferior—as far as early complications, binary restenosis, and target lesion revascularization rate—to the Palmaz-Schatz stent (Cordis, a Johnson & Johnson Company, Warren, New Jersey) (6); and 2) the performance of the various other stents and the associated clinical outcome were not different from the Palmaz-Schatz stent. The slightly better deliverability of some stents compared with the Palmaz-Schatz stent, as seen in some of equivalency trials, has now only historical value. Stents used nowadays perform significantly better than any of the early-generation devices.

From the *Columbus Hospital, Milan, Italy; and †Lenox Hill Hospital, New York, New York.

Manuscript received February 12, 2002; revised manuscript received March 29, 2002, accepted April 17, 2002.

Abbreviations and Acronyms

IVUS = intravascular ultrasound
PTFE = polytetrafluoroethylene
PTCA = percutaneous transluminal coronary angioplasty

Based on our experience with multiple stent systems, we submit the following observations concerning the application of different stents for specific lesion subsets.

The “average” coronary lesion. Stents were initially indicated for proximal, non-angulated lesions, whereas subsequent generation stents were developed for lesions of tortuous anatomy and complex situations. Some stents are more flexible than others or have a smaller profile and therefore are more deliverable. These extra features become necessary only in selected situations. Most stents currently available are suitable for the majority of coronary lesions, with some exceptions.

The stents to be used in the “average” coronary lesion are the new slotted, tubular stents and some new designs of ring stents.

The primary goal for stenting most coronary lesions is to achieve the optimal lumen cross-sectional area without traumatizing the artery. Currently, the achievement of a large final lumen diameter is the most secure means of limiting restenosis (7). Other appropriate concerns for stent choice are adequate lesion coverage, minimal recoil, and limited plaque prolapse. In addition, because stent length is an independent predictor of restenosis, it is preferable to avoid the use of excessive metal (8,9).

The Palmaz-Schatz stent led the way but now has passed the baton to the BxVelocity (Cordis), as demonstrated in the Very Early Nimodipine Use in Stroke (VENUS) trial, a multicenter registry of the Cordis BxVelocity stent (10). It is likely that the BxVelocity stent will be replaced by the sirolimus-coated BxVelocity (11,12). The BxVelocity stent is applicable for everyday use, and there are only a few conditions in which this stent may not be satisfactory. The BxVelocity stent is available in three different patterns of cells according to the vessel size in which the stent will be implanted: six cells for vessels up to 3 mm, seven cells for vessels up to 4 mm, and nine cells for vessels up to 5 mm. The new version, BxSonic (Cordis), has the same stent mounted on an improved delivery system that is compatible with the 5F guiding catheter (lower profile proximal hypotube shaft, 1.9F vs. 2.6F shaft of the BxVelocity, and 0.5-mm balloon overhang on each side).

The heparin-coated Palmaz-Schatz stent had a low incidence of subacute stent thrombosis, with only five thrombotic events (0.4%) in 1,169 patients treated with this stent in the following trials: the BENESTENT II pilot study (13), BENESTENT II randomized study (14), and the Total Occlusion Study of Canada (TOSCA) (15), as well as in two protocols involving patients with acute myocardial infarction: the stenting in Primary Angioplasty

in Myocardial Infarction (PAMI) pilot study (16) and the stent PAMI randomized study (17). A multicenter feasibility study (use of the Hepacoat BxVelocity stent and an antithrombotic regimen of aspirin alone [HOPE]) is under way to examine the safety of the heparin-coated BxVelocity stent (Hepacoat, Cordis) in “low-risk” patients treated with antiplatelet therapy consisting of only aspirin. The initial results in 202 patients showed no acute stent thrombosis and a rate of 1% of subacute thrombosis (one patient with thrombocytosis and one with post-trauma) (18).

The Multilink Tetra stent (Guidant) has functional characteristics that are similar to the BxVelocity stent. The overall performance of these two stents is excellent, with only selected situations where the Tetra appears to be more deliverable. A unique feature of the Tetra delivery system (similar to the Ultra) is its shaft length of 143 cm, which is 3 cm longer than the BxVelocity stent, whereas all the other delivery systems are 138 or 135 cm long. Compared with the Multilink Tetra stent, the Multilink Penta stent (Guidant) has a modified link pattern, which improves flexibility and scaffolding and maintains side-branch access with the possibility to expand the cell toward the side branch up to 4 mm in diameter.

The careful observer may find more stent-to-vessel conformability with the Tetra stent, but no one knows whether this feature has any clinical consequences. Preserving the original shear stress pattern of the arterial segment may lower the amount of tissue hyperplasia (19).

The NIR stent (Medinol, Jerusalem, Israel; and Scimed, Boston Scientific, Maple Grove, Minnesota), with its new “sox” delivery system, is another important stent to be considered for the “average” lesion. The NIR stent provides excellent plaque coverage, which may be an advantage in lesions prone to plaque prolapse. Plaque may prolapse between stent struts in large vessels with a reference diameter ≥ 4 mm. The NIR stent is available with a seven-cell or nine-cell structure, which improves plaque support in large vessels, including saphenous vein grafts. The sox delivery system protects the stent while negotiating through calcified lesion or crossing another stent. These features are unique to this type of stent delivery system.

The performance of this stent was evaluated against the Palmaz-Schatz stent in the NIR Vascular Advanced North American (NIRVANA) trial randomized study (20). This trial reported a follow-up restenosis rate of 19.3% for the NIR stent and 22.4% for the Palmaz-Schatz stent. The moderate rigidity of the NIR stent discourages its use through tortuous segments and for lesions located at a severe bend. Because the NIR stent becomes rigid on deployment, this stent may produce a hinge effect that is associated with an increase in restenosis (21). Figure 1 demonstrates the hinge effect caused by the NIR stent. This lesion restenosed four months later at the distal extremity of the stent (Fig. 2). The operator should foresee this possi-

bility and select a more flexible type of stent in lesions with a small radius of curvature.

The positive features of these three stents are also related to the delivery balloon: 1) there is now near perfect retention, which has eliminated the problem of stent loss; 2) there is minimal overhang of the delivery balloon from the stent, which limits trauma and the risk of peri-stent dissection; and 3) there is low compliance, which assures a more homogeneous stent deployment (Fig. 3).

The beStent (Medtronic AVE, Minneapolis, Minnesota) and now the beStent 2, with a closer strut design, are other stents to consider. The unique feature of this stent is the presence of proximal and distal gold markers that allow very precise placement. Another positive feature of the beStent, but not the beStent 2, is the presence of a large or open cell design that facilitates access to side branches.

The Biodivysio stent (Biocompatibles, Galway, Ireland) is another sturdy device with optimal scaffolding that can be considered for most lesions. This stent is available also with an open-cell design that is suitable for lesions involving the origin of side branches. Compared with the open-cell design, the added support design has an extra strut between interlocking arrowheads, which provides greater coverage for lesions that require additional support.

The Biodivysio stent was recently evaluated against the Duet stent (Guidant) in a randomized trial (bioDIVysio STent IN randomized Control Trial [DISTINCT]). Both stents showed an excellent low restenosis rate of 19% in selected favorable lesions. The standard Biodivysio stent delivery system appears to be more rigid compared with other stents and is not ideal for very tortuous arteries. New versions of the delivery system will soon be released to overcome this potential limitation. The availability of a small-vessel design with this stent, which is very trackable and has a low profile, should be kept in mind when confronted with complex anatomy. A unique feature of the Biodivysio family is their phosphorylcholine coating, which lowers platelet adhesion to the stent struts and may be used as a platform for drug delivery.

Among the ring stents, the new S7 (Medtronic AVE) provides more plaque coverage than the S670 and has an angiographic appearance very similar to the slotted, tubular stents. This stent is appropriate for most lesions. In addition, the flexibility, conformability, and lower friction typical of the S7 ring design improves deliverability in complex anatomies or when passing through a stent. An important characteristic of the AVE delivery system is minimal balloon overhang (Fig. 3).

Among the stainless-steel stents with a good track record, the family of stents from PURA (Devon Medical, Hamburg, Germany) and the V-Flex plus (Cook) should be mentioned.

To make the choice more difficult, the interventionist is confronted with other excellent stents such as the Sorin Sirius Carbostent (Sorin Biomedica Cardio, Saluggia, Italy), with its recently refined delivery system (Sorin Syncro

Carbostent). This stent performs quite well in difficult anatomies and lesions, has platinum end markers, and is covered with a thin layer of turbostratic carbon with the intent to decrease its interaction with platelets. A recent registry report showing a restenosis rate of 11% and a bimodal distribution of the loss index (22) raises the possibility of enhanced biocompatibility of the carbon-coated stent for subjects with an allergy to metal components present in stainless steel (23). At least four other carbon-coated stents are currently available in Europe: the BioDiamond (Plasma Chem, Mainz, Germany), the Diamond Flex (Phytis, Dreieich, Germany), the MAC carbon stent (AMG, Raesfeld-Erle, Germany), and the Tenax (Biotronik, Berlin, Germany). Randomized trials are in progress to test the hypothesis that these inertly coated stents may have advantages over the stainless-steel stents.

Lesions situated on a curve ($\geq 90^\circ$) or immediately followed by a curve. Changing the natural conformation of a coronary vessel may have an unfavorable effect on flow dynamics and increase the risk of adverse events during follow-up (24).

For this reason, we prefer stents that conform to the longitudinal profile of the vessel without producing plaque prolapse in the curved segment. The traditional ring design, such as the S670, is quite conformable but may allow too much plaque protrusion when opened in a curved segment. In this respect, the new S7 is a significant improvement. Slotted, tubular stents with thin struts are also conformable (PURA AS and AL 0.07, 0.075-mm beStent, 0.075-mm Sorin Carbostent, 0.08-mm Tenax, 0.09-mm Biodivysio, and 0.09-mm JoStent). Strut thickness is not the only variable that may affect conformability; the complete stent design may be more important. For example, the NIR stent, which is thinner (0.1 mm) than the BxVelocity (0.14 mm), has lower conformability. The Tetra and Penta stents have variable strut thicknesses (0.091–0.124 mm), with excellent conformability. The NIRflex, the new version of the NIR stent, also has excellent conformability.

Ostial lesions. Ostial lesions are classified as either aorto-ostial or coronary-ostial. For aorto-ostial lesions, the slotted-tube design, preferably with strong radial support, low recoil, and radiologic visibility, is the most appropriate one (25). New ring designs such as the S670 and S7 are also appropriate in this setting.

The recent availability of stents with end markers may improve precise positioning. These stents have thin struts, so our preference is to implant them only in coronary-ostial rather than aorto-ostial locations. The strong elastic recoil inherent to the aorta favors the use of thicker struts to provide greater resistance when dealing with lesions involving the true coronary ostia or the aortic insertion of a saphenous vein graft.

When considering the gold-plated NIR Royal for an aorto-ostial lesion, the operator must balance its advantage of better visibility and more precise positioning with its disadvantage of having a higher angiographic restenosis rate

Table 1. Stent Engineering Data

Product	Manufacturer	Structure	Material	Strut (Wire)		Metal/Artery (%)*	Recoil (%)	Shortening (%)	Radiopacity	Markers	Lengths (mm)	Diameters (mm)
				Thickness (mm)	Thick (mm)							
AVE S670	Medtronic	Sinusoidal ring	Stainless steel	0.127		19	3	3	Medium	No	9, 12, 15, 18, 24, 30	3.0, 3.5, 4.0
AVE S7	Medtronic	Sinusoidal ring	Stainless steel	0.102		17-23	2	3	Medium	No	9, 12, 15, 18, 24, 30	3.0, 3.5, 4.0
beStent 2	Medtronic	Slotted tube	Stainless steel	0.085-0.095		12-17	2	0	Low	Yes	9, 12, 15, 18, 24, 30	2.5, 3.0, 3.5, 4.0
Biodivysio AS	Biocompatibles	Slotted tube	Stainless steel	0.091		19-25	2	4	Low	No	11, 15	3.0, 3.5, 4.0
Biodivysio OC	Biocompatibles	Slotted tube	Stainless steel	0.091		9-12	4	4	Low	No	15, 18, 22, 28	3.0, 3.5, 4.0
BxVelocity/Hepacoat	Cordis, Johnson & Johnson	Slotted tube	Stainless steel	0.14		15	2.5	1.7	Medium	No	8, 13, 18, 23, 28, 32	2.25, 2.5, 2.75, 3.0, 3.5, 4.0, 4.5, 5.0
BxSonic	Cordis, Johnson & Johnson	Slotted tube	Stainless steel	0.14		15	2.4	1.7	Medium	No	8, 13, 18, 23, 28, 33	2.25, 2.5, 2.75, 3.0, 3.5, 4.0
Carbostent Sirius	Sorin	Slotted tube	Stainless steel	0.075		12-17	3-5	0	Low	Yes	9, 12, 15, 19, 25	2.5, 3.0, 3.5, 4.0
Carbostent Syncro	Sorin	Slotted tube	Stainless steel	0.075		12-17	3-5	0	Low	Yes	9, 12, 15, 19, 25	2.5, 3.0, 3.5, 4.0
Cook V-Flex	Cook	Slotted tube	Stainless steel	0.07		15	21	0	Low	No	12, 16, 20, 24	2.5, 3.0, 3.5
Diamond Flex AS	Phytis	Slotted tube	Stainless steel	0.075		10-18	3-5	1	Low	No	9, 12, 16, 20, 25	2.5, 3.0, 3.5, 4.0
JoStent Flex	Jomed	Slotted tube	Stainless steel	0.09		16	4	5	Low	No	9, 16, 26, 32	2.0, 2.5, 3.0, 3.5, 4.0, 4.5
JoStent Plus	Jomed	Slotted tube	Stainless steel	0.09		16	4	5	Low	No	9, 17, 27, 33	2.0, 2.5, 3.0, 3.5, 4.0, 4.5
JoStent Graft	Jomed	Slotted tube	Stainless steel	0.20		100	2	3	High	No	9, 12, 16, 19, 26	2.5, 3.0, 3.5, 4.0, 4.5, 5.0
LP Stent	Boston Scientific	Slotted tube	Stainless steel	0.1		15	2	3-5	Low	No	8, 12, 18, 24	2.5, 3.0, 3.5, 4.0
MAC Carbon Stent	AMG	Slotted tube	Stainless steel	0.085		8-15	3	1	Low	No	9, 13, 17, 22	2.0, 2.5, 3.0, 3.5, 4.0, 4.5
Megaflex Genius	Eurocor	Slotted tube	Stainless steel	0.12		20	1	1	High	No	9, 12, 13, 15, 16, 17, 19, 23	2.5, 2.75, 3.0, 3.5, 4.0
Multilink Tetra	Guidant	Slotted tube	Stainless steel	0.091-0.124		12-20	2-3	3-4	Medium	No	8, 13, 18, 23, 28	2.5, 2.75, 3.0, 3.5, 4.0
Multilink Penta	Guidant	Slotted tube	Stainless steel	0.091-0.124		12-16	2-3	3-4	Medium	No	8, 13, 15, 18, 23, 28, 33	2.75, 3.0, 3.5, 4.0
Multilink Ultra	Guidant	Slotted tube	Stainless steel	0.127-0.101		15-25	2	5	Medium	No	13, 18, 28, 38	3.5, 4.0, 4.5, 5.0
NIR, 7 cells and 9 cells	Medinol, Boston Scientific	Multicell design	Stainless steel	0.1		11-18	3	3	Low	No	9, 16, 25, 32	2.0, 2.5, 3.0, 3.5, 4.0, 4.5, 5.0
NIR Royal	Medinol, Boston Scientific	Multicell design	Stainless steel, gold	0.1		11-18	5	3	High	No	9, 16, 25, 32	2.0, 2.5, 3.0, 3.5, 4.0, 4.5, 5.0
Express	Boston Scientific	Multicell design	Stainless steel, gold	0.132		11-17	5	5	High	No	8, 12, 16, 20, 24, 28, 32	2.25, 2.5, 2.75, 3.0, 3.5, 4.0, 4.5, 5.0
P-S 153	Cordis, Johnson & Johnson	Slotted tube	Stainless steel	0.062		18	5	8	Medium	No	8, 9, 14, 18	3.0, 3.5, 4.0
PURA-A	Devon	Slotted tube	Stainless steel	0.12		10-15	2	1-5	Low	No	7, 15	3.0, 3.5, 4.0, 4.5, 5.0
PURA Vario AL	Devon	Slotted tube	Stainless steel	0.07		10-18	3	5	Low	No	6, 10, 16, 24, 28	3.5, 4.0
PURA Vario AS	Devon	Slotted tube	Stainless steel	0.07		10-18	3	7	Low	No	6, 10, 16, 24, 28	2.5, 3.0
Teneo Tenax-XR	Biotronik	Slotted tube	Stainless steel	0.08		14-22	5	3	Low	Yes	10, 15, 20, 25, 30	2.5, 3.0, 3.5, 4.0
Tsunami	Terumo	Slotted tube	Stainless steel	0.08		18	5	5	Low	No	10, 15, 20, 30	2.5, 3.0, 3.5, 4.0
Small-vessel stents												

(continued)

Table 1. Continued

Product	Manufacturer	Structure	Material	Strut (Wire) Thickness (mm)	Metal/Artery (%) ^a	Recoil (%)	Shortening (%)	Radiopacity	Markers	Lengths (mm)	Diameters (mm)
AVE S660	Medtronic AVE	Sinusoidal ring	Stainless steel	0.127	20	2	1.5	Medium	No	9, 12, 15, 18, 24	2.5
beStent (4 crowns)	Medtronic AVE	Slotted tube	Stainless steel	0.085-0.095	12-17	1.6-2.2	0	Low	Yes	9, 12, 15, 18, 24, 30	2.5
Biodivysio SV	Biocompatibles	Slotted tube	Stainless steel	0.05	9	1	4	Low	No	10, 15, 18	2.0, 2.5
BxVelocity	Cordis, Johnson & Johnson	Slotted tube	Stainless steel	0.14	15	2.5	2	Low	No	8, 13, 18, 23, 28, 32	2.25, 2.5, 2.75
Carbostent Sirius, 4 cells	Sorin	Slotted tube	Stainless steel	0.075	12-17	3-5	0	Low	Yes	9, 12, 15, 19, 25	2.5
JoStent Flex	JoMed	Slotted tube	Stainless steel	0.09	16	4	5	Low	No	9, 16, 26, 32	2.0, 2.5
JoStent Plus	JoMed	Slotted tube	Stainless steel	0.09	16	4	5	Low	No	9, 17, 27, 33	2.0, 2.5
Multilink Pixel	Guidant ACS	Slotted tube	Stainless steel	0.099	15	4	11	Medium	No	8, 13, 18, 23, 28	2.25, 2.5
PURA Vario AS	Devon	Slotted tube	Stainless steel	0.07	10-18	3	7	Low	No	6, 10, 16, 24, 28	2.5

^aDoes not necessarily mean vessel wall coverage.

than the stainless-steel NIR (37.5% vs. 20.6%, $p < 0.001$), as reported in the NIR Ultimate Gold-Gilded Equivalency Trial (NUGGET) (26). Similar findings were reported with a gold-coated stent manufactured by a different company (27).

For aorto-ostial lesions with a reference vessel size of ≥ 4 mm in diameter, we have had a positive clinical experience with the BxVelocity, the nine-cell NIR, and the Ultra. All of these slotted-tube stents maintain good radial force, even when dilated to large diameters.

Bifurcational lesions. When approaching a bifurcational lesion, it may be preferable to have a stent with large side openings between the struts that can easily permit passage of a balloon or second stent into the side branch. Figure 4 shows several slotted-tube stents with the cross-sectional area of the cell following stent dilation and with the cross-sectional area of the same cell following the maximal opening of a balloon inflated across the cell into the side branch (28). Many slotted-tube stents are suitable for stenting a bifurcation, with the exception of the NIR stent. The closed-cell design of the NIR does not allow significant expansion of the opening toward the side branch, even after crossing and inflating a balloon. If the operator decides to use the NIR stent, the seven-cell design should be used instead of the nine-cell design.

Another option is to use a stent with a large side opening, such as the Biodivysio open-cell design or the S670. The advantage of this decision is that the initial access to the side branch is facilitated. A possible disadvantage is incomplete prolapse of one strut toward the side branch following a "kissing" balloon dilation (i.e., dilating 2 balloons simultaneously into both branches of a bifurcation). The concept of strut prolapse from the main branch toward the side branch has been pioneered by Dr. Marie Claude Morice and Dr. Thierry Lefevre and termed "stenting both branches with one stent." When the design is very open, there is less possibility for a strut to straddle across the side branch. Slotted-tube stents that best demonstrate this feature are the beStent and Carbostent, but the BxVelocity and Tetra are also adequate (Fig. 5).

Whichever stent the operator uses for a bifurcation, it is important to perform a "kissing" balloon inflation at the end of the procedure to correct the stent distortion that occurs after balloon inflation in the side branch (29). If the operator finds it appropriate to stent both branches, we recommend the modified T or V techniques.

Lesions located at the left main stem. Left main stem lesions may involve treatment of an aorto-ostial lesion and/or a lesion located in the body of the left main artery. Occasionally, there is a need to treat the distal left main stem as a bifurcational lesion.

The reference size of the left main coronary artery is favorable to stent implantation in terms of the restenosis rate. The major problem is that in an unprotected left main artery, stent restenosis may manifest either as sudden death or unstable angina rapidly followed by death. For this

Table 2. Crossing Profile

Product	Manufacturer	Crossing Profile*	
		2.5-mm Diameter	3.0-mm Diameter
AVE S670	Medtronic		1.09
AVE S660	Medtronic	0.99	
beStent 2	Medtronic	1.07	1.17
Biodivysio AS	Biocompatibles		1.07
Biodivysio SV	Biocompatibles	0.84	
BxVelocity	Cordis, Johnson & Johnson	1.07	1.17
BxSonic	Cordis, Johnson & Johnson	1.07	1.14
Carbostent	Sorin	1.02	1.04
Multilink Tetra	Guidant ACS	1.04	1.12
Multilink Penta	Guidant ACS	1.04	1.07
Multilink Pixel	Guidant ACS	0.93	
NIR with sox	Medinol, Boston Scientific	1.09	1.12
Express	Boston Scientific	1.02	1.09

*Data presented reflect measurements performed by individual manufacturers; the method used to measure and the exact site of measurements may differ among different stents.

reason, when stent implantation in an unprotected left main artery is clinically indicated, we frequently debulk the lesion with directional atherectomy to minimize the risk of restenosis (30).

Selection of the stent to be used depends on the issues discussed previously concerning ostial lesions and bifurcational lesions. The only unique aspect of left main stenting is the final size of this vessel. It is not unusual, especially if intravascular ultrasound (IVUS) is employed (31), to perform a post-stent dilation with a balloon >4 mm. For this reason, when the left main artery appears large, we recommend using slotted-tube stents that can be expanded >4 mm. The NIR nine-cell, BxVelocity, Tetra and Ultra are excellent choices. When the stent is overexpanded and it is located in the aorto-ostial position, it is important to realize that a significant foreshortening will occur. The operator should take this into account when initially placing the stent by placing the proximal end of the stent 1 to 2 mm into the aorta. In addition, if the ostium is left uncovered, the operator should not hesitate to place a second stent. The use of IVUS may be beneficial in determining the precise

position of a stent. The use of stents with no foreshortening and with markers like the beStent or Carbostent is an important consideration in this context. As a general rule, when treating an aorto-ostial lesion, it is important to avoid using a stent that is very short, such as an 8- or 9-mm stent. This recommendation becomes even more important when dealing with a lesion at the ostium of the left main artery. We have seen stents ejected from the left main stem at the time of postdilation due to their short anchoring length.

Calcified lesions. Despite the widespread notion that calcium affects stent expansion (32), there are only a few reports specifically dealing with this issue (33,34). The general view is that stent expansion in a calcified lesion will yield a smaller final lumen than will expansion in a non-calcified lesion. Adequate final expansion is usually achieved by stretching the non-calcified arc of the vessel. If an adequate final lumen size is achieved, this approach does not seem to affect restenosis. To obtain an adequate final lumen size, it is important to have a slotted-tube stent with minimal recoil and good radial strength. The NIR, BxVe-

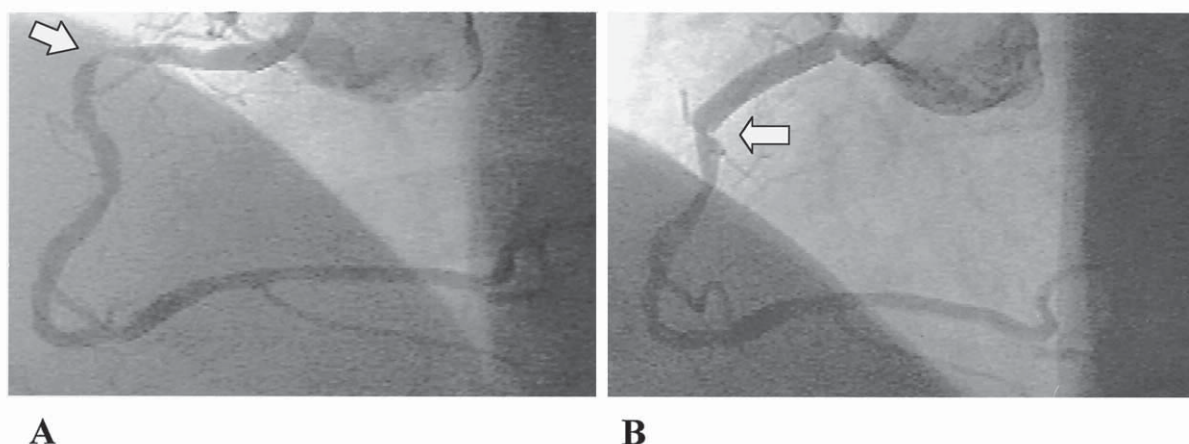


Figure 1. (A) Baseline angiogram of a lesion (arrow) in the proximal right coronary artery. (B) Angiogram after implantation of a nine-cell, 16-mm-long NIR stent. The hinge site at the end of the stent is clear (arrow).

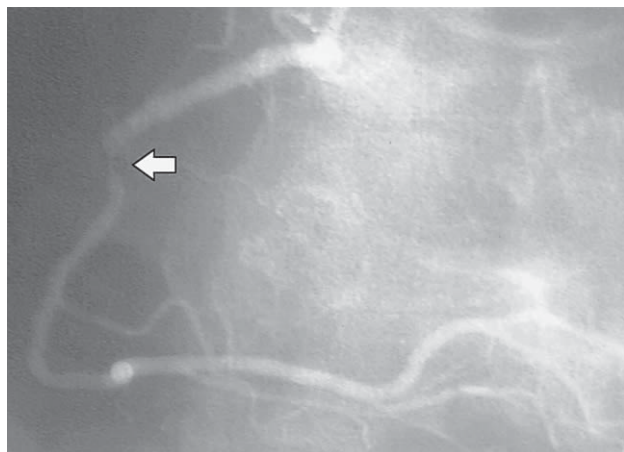


Figure 2. Four-month follow-up angiogram of the lesion in Figure 1, showing restenosis at the hinge site (arrow).

locity, Tetra, and AVE-S family stents are all reasonable choices.

In calcified lesions, the most important part of the procedure is adequate preparation of the lesion before stent implantation. The amount of calcium visible on X-ray underestimates the amount of calcium observed on IVUS. Intravascular ultrasound can also distinguish whether the calcium is in a superficial or deep location (35). Efforts to evaluate the lesion and to prepare the implantation site with rotational atherectomy or by cutting the balloon will be well rewarded. Post-dilation with a short, non-compliant balloon is another important step.

Chronic total occlusions. Stent implantation for chronic total occlusions must address two problems: 1) the amount of plaque mass in these types of lesions is large; and 2) it is not rare that passage through the occluded segment occurs by creating a false lumen with reentry.

These two elements mandate the insertion of a stent with good lesion coverage and radial support. The Palmaz-Schatz stent was used in the Stenting In Chronic Coronary Occlusion (SICCO) study (36), which reported a significant benefit of stent implantation (32% restenosis) in comparison with percutaneous transluminal coronary angioplasty (PTCA) (74% restenosis) after recanalization of chronic total occlusions. In TOSCA (15), 410 patients with non-acute native coronary occlusions were randomized to PTCA or primary stenting with the heparin-coated Palmaz-Schatz stent. With 95.6% angiographic follow-up, primary stenting resulted in a 44% reduction in failed patency (10.9% vs. 19.5%, $p = 0.024$) and a 45% reduction in clinically driven target vessel revascularization at six months (8.4% vs. 15.4%, $p = 0.03$).

In addition to various slotted-tube stents (e.g., NIR, BxVelocity), the Wallstent needs to be considered for dealing with a large vessel, especially for the right coronary artery (37).

The general rule for treating a chronic total occlusion is to use a stent with good plaque coverage with a closed-cell design, allowing minimal plaque prolapse in this setting where there is a large plaque burden.

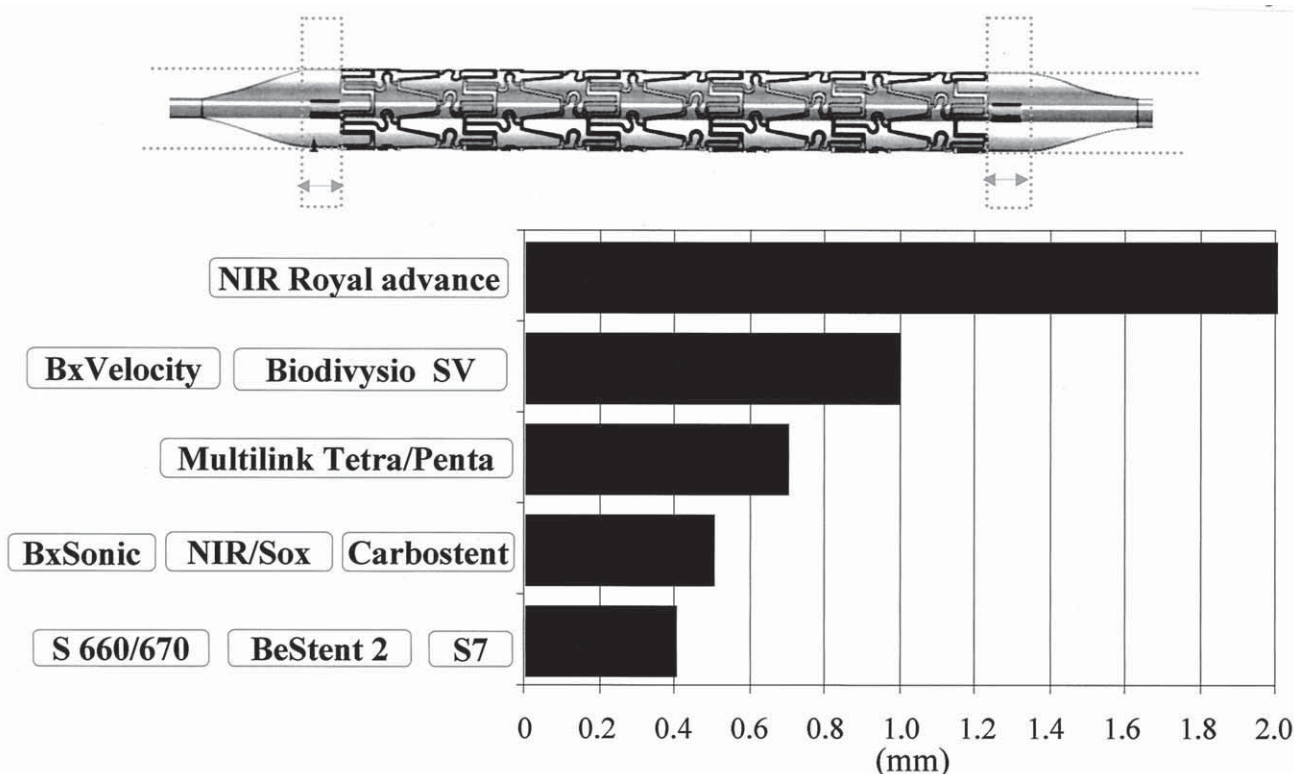


Figure 3. Length of balloon protrusion for commonly used stents.

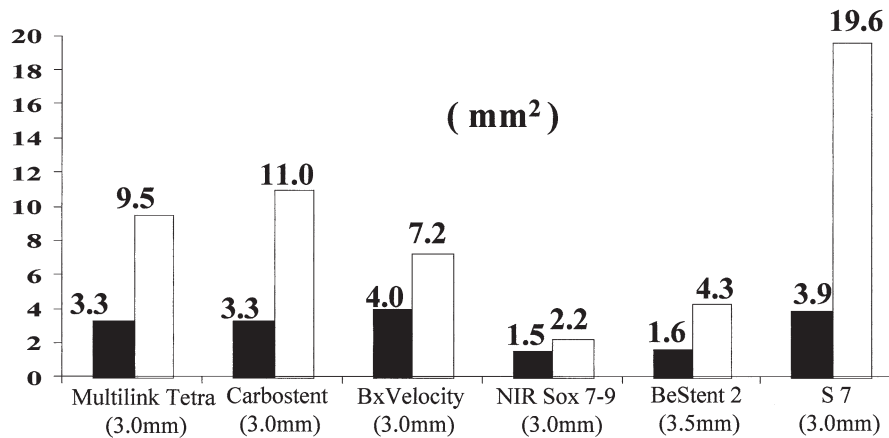


Figure 4. Area of the stent cell at nominal (solid bars) and maximal (open bars) expansion for several slotted-tube stents.

Vessels smaller than 3.0 mm in diameter. Stent implantation in small vessels is associated with a number of problems. Initially, no stents were specifically made to be expanded in small vessels with the capacity to gain optimal radial support at diameters between 2.5 and 3.0 mm. Only recently have stents become available such as the Mini Crown, beStent (4 crowns), Biodivysio SV (small vessels), six-cell BxVelocity, Multilink Pixel, 2.5-mm Carbastent four-cell, and small-vessel Pura Vario AS, which are de-

signed to fit vessels <3 mm. The most important attributes of these stents are their improved flexibility, capacity to reach distal lesions, and very thin strut structure.

The recent introduction of stents specifically designed for small vessels has allowed the performance of randomized trials without interference from the implantation of stents not dedicated to small vessels. Figure 6 summarizes the results of four recently completed studies (38–41). In three of them, the beStent-4 crown (Medtronic AVE) was used;




Figure 5. Examples of stent strut prolapse from the main branch toward the side branch after “kissing” balloon inflation (arrows). (A) The Sorin Sirius Carbastent (Sorin Biomedica Cardio, Saluggia, Italy). (B) The beStent 2 (Medtronic AVE, Minneapolis, Minnesota). (C) The BxVelocity (Cordis, a Johnson & Johnson Company, Warren, New Jersey). (D) The Multilink Tetra stent (Guidant, Temecula, California).

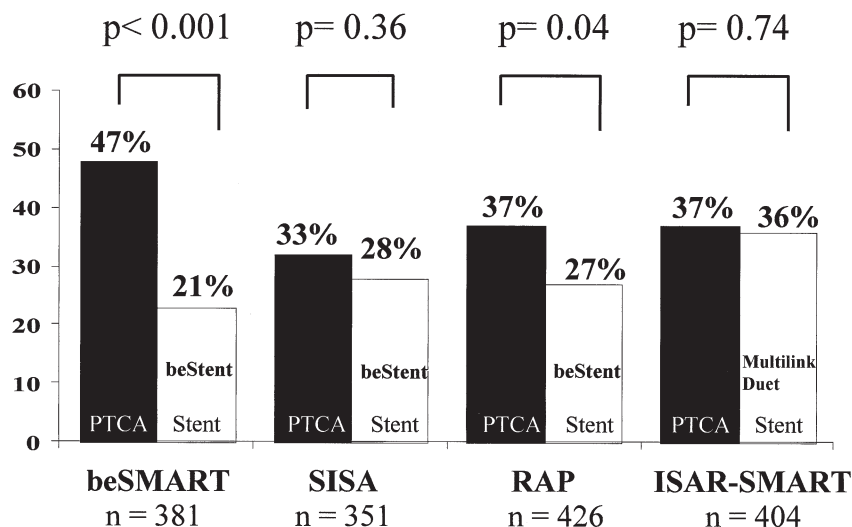


Figure 6. Restenosis rates in randomized trials of small-vessel stenting versus balloon PTCA. beSMART = BEstent in Small ARteries; SISA = Stenting In Small Arteries; RAP = Restenosis en Arterias Pequeñas; ISAR-SMART = Intracoronary Stenting or Angioplasty for Restenosis reduction in Small ARteries; PTCA = percutaneous transluminal coronary angioplasty.

in the other study, the Multilink was initially implanted and then substituted by the Duet (Guidant). In two studies, the results showed a superiority of stenting over PTCA, and in the other two studies, the restenosis rates were equivalent.

An interesting observation came from the Intracoronary Stenting and Angiographic Results: Strut Thickness Effect on REstenosis Outcome (ISAR-STREO) study (42). The authors reported a significantly lower restenosis rate in vessels larger than 2.8 mm (15.0% vs. 25.8%, $p < 0.003$) after implantation of the thin-strut (0.05 mm) Multilink stent, compared with the thicker strut (0.14 mm) Duet stent. Whether this finding also applies to small vessels needs to be evaluated.

To ensure more flexibility and easier delivery to lesions located in small vessels, we use dedicated small-vessel stents with thin struts. The Biodivysio SV and beStent (4 crowns) stents are probably the most suitable stents to be implanted on lesions located in small vessels. The stent delivery system of these stents is about 0.75 mm in profile, making them the smallest profile stent delivery system. The Sorin Carbostent is another thin-strut stent available in a small vessel size. All of these stents, with the exception of the Biodivysio SV stent, are visible under X-ray thanks to distal and proximal radiopaque markers.

The BxVelocity, with the dedicated six-cell stent, and the Multilink Pixel, a new, small-vessel stent by Guidant, are also good choices. In comparison to the other small-vessel stents, these two stents do not have thin struts and are visible under X-ray.

Saphenous vein grafts. Implanting stents in lesions located in a saphenous vein graft usually involves dealing with a lesion located in a large vessel. Because a major goal is to minimize trauma to the plaque and give maximal lesion coverage to avoid the risk of distal embolization, self-expandable stents are very useful in this setting. The

Wallstent or nitinol NIR stent is suitable, especially for long lesions in these locations.

One persisting problem with stent implantation in vein grafts is that future events may result from progression of other lesions that were not considered critical at the time of initial stent implantation in the target lesion (43). This issue will be evaluated by prospective studies comparing a strategy of focal stent implantation in the critical lesions with a strategy aimed at implanting stents also in lesions that are not angiographically critical.

Vein graft stent implantation must be performed with a stent that provides optimal lesion coverage and is available in different lengths (vein grafts require longer stents).

Other suitable stents for operators who prefer balloon-expandable stents are the Ultra version of the Multilink design specifically made for vein graft lesions (Guidant) and the nine-cell NIR stent.

The most important issue concerning stenting of vein grafts is the risk of distal embolization. Our experience is that no particular currently available stent is more likely than another to limit these complications. The recent introduction of a protective balloon on a wire system (in the Saphenous vein graft Angioplasty Free of Emboli [SAFE] [44,45] and the Saphenous vein graft Angioplasty Free of Emboli Randomized [SAFER] [46] studies) and a number of filter devices has improved the safety of vein graft interventions.

A discussion of vein graft stenting would not be complete without mentioning the PTFE-covered stent. This device has the potential to entrap the friable plaque present in vein grafts, with a positive impact on distal embolization and late restenosis (47,48). A similar device, with the covering membrane made of bovine pericardium, is currently under clinical evaluation (Fig. 7).




Figure 7. A stent with the covering membrane made of bovine pericardium.

Early and threatened closure. Stents were initially developed to treat acute closure from balloon dilation (49,50). The stents used most extensively were the Gianturco-Roubin I stent (51,52) and the Palmaz-Schatz stent (53). Higher rates of success, even in lesions of complex anatomy and long dissections, were reported with the Gianturco-Roubin II stent and with the AVE II MicroStent (54).

The ideal stent for treating a dissection with impending closure should have an easy and predictable delivery, even without an optimal guiding catheter or guidewire support. We have nicknamed this condition “the panic stent.” The Pixel, the Sonic, and the S660 are some of the most deliverable stents in complex anatomies.

Treatment of dissections may require placing a short stent distal to an already deployed stent, usually to treat a residual distal dissection not evident at the time of the first stent implantation. An incompletely sealed dissection, especially in the setting of impending closure, remains one important predictor of stent occlusion, even with the use of high-pressure dilation after stent implantation and with administration of aspirin and ticlopidine (55). Therefore, a stent with a predictable delivery and with which the operator feels confidence, is likely to be the preferred one. It will also result in a low incidence of stent thrombosis if it provides good coverage of the dissection without plaque prolapse.

Special situations. There are instances in which the operator needs to creatively modify the tools available to provide a new device capable of satisfying an unusual condition. Three of these situations are the treatment of severe focal aneurysmal dilation of a coronary artery, diffuse aneurysmal disease of vein grafts, and, occasionally, coronary perforations. The use of an autologous vein graft-coated stent is an interesting solution pioneered by Stefanadis et al. (56,57). The Tetra, BxVelocity, NIR, and other slotted-tube stents are good platforms on which the autologous vein can be mounted.

Coronary perforations are rare but need a rapid and effective treatment. The new PTFE-covered stent is now available in a premounted form and is probably the best

device to treat a coronary perforation (58) or a coronary aneurysm (59,60).

Another use for this covered stent is the treatment of aorto-ostial coronary and ostial saphenous vein graft lesions. Because of the high incidence of repeat restenosis in aorto-ostial lesions, the PTFE-covered stent should be considered among the options, even at the time of the first percutaneous procedure.

Drug-eluting stents. The goal of maximizing lumen gain with mechanical scaffolding to prevent acute and chronic recoil and to seal any dissection, coupled with the possibility to eliminate excessive tissue proliferation, gave birth to drug-eluting stents. As of early 2002, all drug-eluting stents are still investigational devices. Soon, some of them will become available for clinical use in Europe and outside the U.S.

Drug-eluting stents can be classified according to the specific stent design, presence or absence of a polymer to absorb the drug, type of polymer, type of drug, and release pattern.

Currently, the V-Flex Plus coronary stent (Cook) and the Achieve coronary stent system (manufactured by Cook and distributed by Guidant) are used to deliver paclitaxel adhered to the stent surface with no polymer. The JoMed coronary stent graft and the JoMed Flex (nanoporous ceramic coating) are also used with no polymer to deliver tacrolimus.

Stents that employ a polymer carrier for local drug delivery are the BxVelocity (Cordis) for sirolimus; the NIR Conformer (Medinol and Scimed) and the Express (Boston Scientific) for paclitaxel; the Biodivysio Matrix LO (Bio-compatibles) for dexamethasone, prednisolone, batimastat, estrogen, and angiopeptin; the Tetra (Guidant) for actinomycin D; the AVE S7 (Medtronic AVE) for *c-myc* antisense (resten-NG); and the Tsunami (Terumo Co., Tokyo, Japan) for statins. All of the aforementioned drug-eluting stents are in clinical trials with different degree of progress, with the exception of resten-NG, which has not yet been evaluated in humans. Recently, the actinomycin D and batimastat programs have been discontinued because of a lack of efficacy.

The drug-eluting stent programs under more advanced clinical evaluation are the Cypher (sirolimus) and Taxus (paclitaxel). The most important achievements of the Cypher program are: 1) a 0% rate of six-month angiographic restenosis in the RAndomized study with the sirolimus-eluting Bx VElocity balloon-expandable stent in the treatment of patients with de novo native coronary artery lesions (RAVEL) trial and sustained clinical efficacy at one-year follow-up (61); 2) persistent good vessel patency at two-year follow-up in the First-In-Man study (62); 3) a low 30-day event rate in the U.S. multicenter, randomized, double-blind study of SIRIUS-eluting stent in coronary lesions (SIRIUS) trial (63); 4) completion of a pilot in-stent restenosis study (64); 5) bifurcational and small vessels with long lesions (European SIRIUS [E-SIRIUS]), projects with




Figure 8. Drug delivery to the vessel wall with various stent designs. The **color chart** corresponds to the amount of drug concentration.

enrollment recently completed; 6) a left main stem registry and the Arterial Revascularization Therapy Study (ARTS) II registry, close to initiation; and 7) the first drug-eluting stent in the market for coronary applications (expected for April 2002).

The most important achievements of the Taxus program

are: 1) a 0% rate of six-month angiographic restenosis in the pilot Taxus I trial (65); 2) completion of enrollment and a low early event rate in Taxus II; and 3) acceptable incidence of six-month major adverse cardiac events (17%, consisting mainly of late target vessel revascularization) in the Taxus III registry for treatment of in-stent restenosis (66).

Table 3. Stent Consumer's Guide

Product	Manufacturer	Deliverability	Scaffolding	Side-Branch Access	Accurate Positioning	Large Vessels	Small Vessels
AVE S670	Medtronic	++++	+	+++	++	++	+
AVE S7	Medtronic	++++	+++	++	++	+++	+
Biodivysio	Biocompatibles	++	++++	+	+	++	++
BxVelocity/Sonic	Cordis, Johnson & Johnson	+++	+++	++	++	+++	+
JoStent graft	Jomed	+	++++	NA	++++	+++	0
Multilink Penta	Guidant	+++	+++	++	++	+++	+
NIR, 7 cells and 9 cells	Medinol, Boston Scientific	++	++++	+	+	+++	+
NIR Royal	Medinol, Boston Scientific	+	++++	+	++++	+++	+
Express	Boston Scientific	+++	+++	++	++	+++	+
AVE S660	Medtronic AVE	++++	+	+++	++	NA	+
Biodivysio SV	Biocompatibles	+++	+++	+	+	NA	++
Multilink Pixel	Guidant ACS	+++	+++	++	+	NA	++

++++ = excellent; +++ = very good; ++ = good; + = acceptable; 0 = unsuitable; NA = not applicable.

In the evolution of these special stents, we will also see new stent designs made to maximize uniform drug delivery to the vessel wall (Fig. 8).

Conclusions. Despite all of the theoretic and practical considerations provided for selecting a particular stent to treat a specific lesion, the individual experience and confidence of the operator are paramount. No rationale for choosing a specific stent for a specific lesion is yet supported by randomized trials. Nonetheless, a large number of observational studies support the views expressed in this report.

Except for the use of a stent to prevent threatened occlusion, stents are implanted with the intent to prevent restenosis. The operator should strive to reach this goal while maximizing the patient's safety. Judicious stent selection, balloon sizing, and lesion preparation to achieve an optimal final lumen dimension remain the most important goals in percutaneous coronary interventions. For those interested in seeing comparisons based on personal experience, we propose our point of view in a "consumer's guide" format (Table 3).

With the advent of drug-eluting stents, many of these considerations and recommendations may be altered. In the era of almost zero late loss, the concept of maximizing lumen gain at the time of stent implantation may not be as important as it appears today. The experience with drug-eluting stents may change the technique of stenting, but one goal that will not change and will become even more important is the reliable delivery of the stent to the lesion.

Reprint requests and correspondence: Dr. Antonio Colombo, EMO Centro Cuore Columbus, Via M. Buonarroti 48, 20145 Milan, Italy. E-mail: info@emocolumbus.it.

REFERENCES

1. Serruys PW, de Jaegere P, Kiemeneij F, et al., the BENESTENT Study Group. A comparison of balloon-expandable-stent implantation with balloon angioplasty in patients with coronary artery disease. *N Engl J Med* 1994;331:489-95.
2. Fischman DL, Leon MB, Baim DS, et al., the Stent Restenosis Study Investigators. A randomized comparison of coronary-stent placement and balloon angioplasty in the treatment of coronary artery disease. *N Engl J Med* 1994;331:496-501.
3. Colombo A, Hall P, Nakamura S, et al. Intracoronary stenting without anticoagulation accomplished with intravascular ultrasound guidance. *Circulation* 1995;91:1676-88.
4. Kastrillon GJ, Morice MC, Benveniste E, et al. Intracoronary stent implantation without ultrasound guidance and with replacement of conventional anticoagulation by antiplatelet therapy: 30-day clinical outcome of the French Multicenter Registry. *Circulation* 1996;94: 1519-27.
5. Schomig A, Neumann FJ, Kastrati A, et al. A randomized comparison of antiplatelet and anticoagulant therapy after the placement of coronary-artery stents. *N Engl J Med* 1996;334:1084-9.
6. Lansky AJ, Roubin GS, O'Shaughnessy CD, et al. Randomized comparison of GR-II stent and Palmaz-Schatz stent for elective treatment of coronary stenoses. *Circulation* 2000;102:1364-8.
7. Kuntz RE, Safian RD, Carozza JP, Fishman RF, Mansour M, Baim DS. The importance of acute luminal diameter in determining restenosis after coronary atherectomy or stenting. *Circulation* 1992;86: 1827-35.
8. Kasaoka S, Tobis JM, Akiyama T, et al. Angiographic and intravascular ultrasound predictors of in-stent restenosis. *J Am Coll Cardiol* 1998;32:1630-5.
9. Kobayashi Y, De Gregorio J, Kobayashi N, et al. Stented segment length as an independent predictor of restenosis. *J Am Coll Cardiol* 1999;34:651-9.
10. Zidar JP, Fry E, Lambert C, et al. The Venus trial: a multicenter registry of the Cordis BxVelocity stent (abstr). *Am J Cardiol* 2000;86: 17.
11. Sousa JE, Costa MA, Abizaid A, et al. Lack of neointimal proliferation after implantation of sirolimus-coated stents in human coronary arteries: a quantitative coronary angiography and three-dimensional intravascular ultrasound study. *Circulation* 2001;103:192-5.
12. Sousa JE, Costa MA, Abizaid AC, et al. Sustained suppression of neointimal proliferation by sirolimus-eluting stents: one-year angiographic and intravascular ultrasound follow-up. *Circulation* 2001;104: 2007-11.
13. Serruys PW, Emanuelsson H, van der Giessen W, et al. Heparin-coated Palmaz-Schatz stents in human coronary arteries: early outcome of the BENESTENT-II pilot study. *Circulation* 1996;93:412-22.
14. Serruys PW, van Hout B, Bonnier H, et al. Randomized comparison of implantation of heparin-coated stents with balloon angioplasty in selected patients with coronary artery disease (BENESTENT II). *Lancet* 1998;352:673-81.
15. Buller CE, Dzavik V, Carere RG, et al. Primary stenting versus balloon angioplasty in occluded coronary arteries: the Total Occlusion Study of Canada (TOSCA). *Circulation* 1999;100:236-42.
16. Stone GW, Brodie BR, Griffin JJ, et al. Clinical and angiographic follow-up after primary stenting in acute myocardial infarction: the Primary Angioplasty in Myocardial Infarction (PAMI) stent pilot trial. *Circulation* 1999;99:1548-54.
17. Grines CL, Cox DA, Stone GW, et al., the Stent Primary Angioplasty in Myocardial Infarction Study Group. Coronary angioplasty with or without stent implantation for acute myocardial infarction. *N Engl J Med* 1999;341:1949-56.
18. Leon M, Mehran R, Thomas W, et al. A multicenter study examining the safety of a heparin-coated coronary stent in low risk patients treated with an antiplatelet therapy of aspirin alone (abstr). *Circulation* 2001;104 Suppl II:II464.
19. Wentzel JJ, Krams R, Schuurbiers JC, et al. Relationship between neointimal thickness and shear stress after Wallstent implantation in human coronary arteries. *Circulation* 2001;103:1740-5.
20. Baim DS, Cutlip DE, O'Shaughnessy CD, et al. Final results of a randomized trial comparing the NIR stent to the Palmaz-Schatz stent for narrowings in native coronary arteries. *Am J Cardiol* 2001;87: 152-6.
21. Phillips PS, Alfonso F, Segovia J, et al. Effects of Palmaz-Schatz stents on angled coronary arteries. *Am J Cardiol* 1997;79:191-3.
22. Antoniucci D, Bartorelli A, Valenti R, et al. Clinical and angiographic outcome after coronary arterial stenting with the Carbestent. *Am J Cardiol* 2000;85:821-5.
23. Koster R, Vieluf D, Kiehn M, et al. Nickel and molybdenum contact allergies in patients with coronary in-stent restenosis. *Lancet* 2000; 356:1895-7.
24. Gyongyosi M, Yang P, Khorsand A, Glogar D, the Austrian Wiktor Stent Study Group and European Paragon Stent Investigators. Longitudinal straightening effect of stents is an additional predictor for major adverse cardiac events. *J Am Coll Cardiol* 2000;35:1580-9.
25. Zampieri P, Colombo A, Almagor Y, Maiello L, Finci L. Results of coronary stenting of ostial lesions. *Am J Cardiol* 1994;73:901-3.
26. Silber S, Reifart N, Morice MC, et al. The NUGGET trial (NIR Ultimate Gold-Gilded Equivalency Trial): 6 months post procedure safety and efficacy results (abstr). *Circulation* 2001;104 Suppl II:II623.
27. Kastrati A, Schomig A, Dirschinger J, et al. Increased risk of restenosis after placement of gold-coated stents: results of a randomized trial comparing gold-coated with uncoated steel stents in patients with coronary artery disease. *Circulation* 2000;101:2478-83.
28. Stankovic G, Martini G, Ferraro M, et al. An in-vitro assessment of stent geometry for bifurcation lesions after kissing balloon inflation (abstr). *Am J Cardiol* 2001;81:60G.
29. Ormiston JA, Webster MW, Ruygrok PN, Stewart JT, White HD, Scott DS. Stent deformation following simulated side-branch dilata-

- tion: a comparison of five stent designs. *Cathet Cardiovasc Interv* 1999;47:258-64.
30. Park SJ, Hong MK, Lee CW, et al. Elective stenting of unprotected left main coronary artery stenosis: effect of debulking before stenting and intravascular ultrasound guidance. *J Am Coll Cardiol* 2001;38:1054-60.
31. Hong MK, Park SW, Lee CW, et al. Intravascular ultrasound findings in stenting of unprotected left main coronary artery stenosis. *Am J Cardiol* 1998;82:670-3.
32. Hodgson JM. Oh no, even stenting is affected by calcium! *Cathet Cardiovasc Diagn* 1996;38:236-7.
33. Albrecht D, Kaspers S, Fussl R, Hopp HW, Sechtem U. Coronary plaque morphology affects stent deployment: assessment by intracoronary ultrasound. *Cathet Cardiovasc Diagn* 1996;38:229-35.
34. Moussa I, Di Mario C, Moses J, et al. Coronary stenting after rotational atherectomy in calcified and complex lesions: angiographic and clinical follow-up results. *Circulation* 1997;96:128-36.
35. Mintz GS, Popma JJ, Pichard AD, et al. Patterns of calcification in coronary artery disease: a statistical analysis of intravascular ultrasound and coronary angiography in 1155 lesions. *Circulation* 1995;91:1959-65.
36. Sirnes PA, Golf S, Myreng Y, et al. Stenting In Chronic Coronary Occlusion (SICCO): a randomized, controlled trial of adding stent implantation after successful angioplasty. *J Am Coll Cardiol* 1996;28:1444-51.
37. Ozaki Y, Violaris AG, Hamburger J, et al. Short- and long-term clinical and quantitative angiographic results with the new, less shortening Wallstent for vessel reconstruction in chronic total occlusion: a quantitative angiographic study. *J Am Coll Cardiol* 1996;28:354-60.
38. Koning R, Eltchaninoff H, Commeau P, et al. Stent placement compared with balloon angioplasty for small coronary arteries: in-hospital and 6-month clinical and angiographic results. *Circulation* 2001;104:1604-8.
39. Garcia E, Moreno R, Pasalodos J, Bethancourt A, Zueco J, Iniguez A. Stent reduces restenosis in small vessels: results of the RAP study (abstr). *J Am Coll Cardiol* 2001;37 Suppl A:1-648.
40. Doucet S, Schali J, Vrolix MCM, et al. Stent placement to prevent restenosis after angioplasty in small coronary arteries. *Circulation* 2001;104:2029-33.
41. Kastrati A, Schomig A, Dirschinger J, et al., the Intracoronary Stenting or Angioplasty for Restenosis reduction in SMall ARteries (ISAR-SMART) Study Investigators. A randomized trial comparing stenting with balloon angioplasty in small vessels in patients with symptomatic coronary artery disease. *Circulation* 2000;102:2593-8.
42. Kastrati A, Mehili J, Dirschinger J, et al. Intracoronary Stenting and Angiographic Results: Strut Thickness Effect on REstenosis Outcome (ISAR-STEREO) trial. *Circulation* 2001;103:2816-21.
43. Hartmann JR, McKeever LS, O'Neill WW, et al. Recanalization of chronically occluded aortocoronary saphenous vein bypass grafts with long-term, low-dose direct infusion of urokinase (ROBUST): a serial trial. *J Am Coll Cardiol* 1996;27:60-6.
44. Grube E, Webb J, Prpic R, et al. Clinical safety and efficacy of the PercuSurge guidewire in the Saphenous vein graft Angioplasty Free of Emboli (SAFE) study (abstr). *J Am Coll Cardiol* 2000;35 Suppl A:41.
45. Gerckens U, Muller R, Rowold S, Grube E. The Filterwire: first evaluation of a new protection catheter device for distal embolization in native coronary arteries in SVGs (abstr). *J Am Coll Cardiol* 2001;37 Suppl A:1-648.
46. Baim DS, Wahr D, George B, et al. Randomized trial of a distal embolic protection device during percutaneous intervention of saphenous vein aorto-coronary bypass grafts. *Circulation* 2002;105:1285-90.
47. Briguori C, De Gregorio J, Nishida T, et al. Polytetrafluoroethylene-covered stent for the treatment of narrowings in aortocoronary saphenous vein grafts. *Am J Cardiol* 2000;86:343-6.
48. Baldus S, Koster R, Elsner M, et al. Treatment of aortocoronary vein graft lesions with membrane-covered stents: a multicenter surveillance trial. *Circulation* 2000;102:2024-7.
49. Herrmann HC, Buchbinder M, Clemen MW, et al. Emergent use of balloon-expandable coronary artery stenting for failed percutaneous transluminal coronary angioplasty. *Circulation* 1992;86:812-9.
50. Roubin GS, Cannon AD, Agrawal SK, et al. Intracoronary stenting for acute and threatened closure complicating percutaneous transluminal coronary angioplasty. *Circulation* 1992;85:916-27.
51. George BS, Voorhees WD 3rd, Roubin GS, et al. Multicenter investigation of coronary stenting to treat acute or threatened closure after percutaneous transluminal coronary angioplasty: clinical and angiographic outcomes. *J Am Coll Cardiol* 1993;22:135-43.
52. Sutton JM, Ellis SG, Roubin GS, et al., the Gianturco-Roubin Intracoronary Stent Investigator Group. Major clinical events after coronary stenting: the multicenter registry of acute and elective Gianturco-Roubin stent placement. *Circulation* 1994;89:1126-37.
53. Schomig A, Kastrati A, Mudra H, et al. Four-year experience with Palmaz-Schatz stenting in coronary angioplasty complicated by dissection with threatened or present vessel closure. *Circulation* 1994;90:2716-24.
54. Ozaki Y, Keane D, Ruygrok P, de Feyter P, Stertzer S, Serruys PW. Acute clinical and angiographic results with the new AVE Micro coronary stent in bailout management. *Am J Cardiol* 1995;76:112-6.
55. Moussa I, Di Mario C, Reimers B, Akiyama T, Tobis J, Colombo A. Subacute stent thrombosis in the era of intravascular ultrasound-guided coronary stenting without anticoagulation: frequency, predictors and clinical outcome. *J Am Coll Cardiol* 1997;29:6-12.
56. Stefanadis C, Toutouzas P. Percutaneous implantation of autologous vein graft stent for treatment of coronary artery disease. *Lancet* 1995;345:1509.
57. Stefanadis C, Toutouzas K, Vlachopoulos C, et al. Autologous vein graft-coated stent for treatment of coronary artery disease. *Cathet Cardiovasc Diagn* 1996;38:159-70.
58. Briguori C, Nishida T, Anzuini A, Di Mario C, Grube E, Colombo A. Emergency polytetrafluoroethylene-covered stent implantation to treat coronary ruptures. *Circulation* 2000;102:3028-31.
59. Di Mario C, Inglese L, Colombo A. Treatment of a coronary aneurysm with a new polytetrafluoroethylene-coated stent: a case report. *Cathet Cardiovasc Interv* 1999;46:463-5.
60. Heuser RR, Woodfield S, Lopez A. Obliteration of a coronary artery aneurysm with a PTFE-covered stent: endoluminal graft for coronary disease revisited. *Cathet Cardiovasc Interv* 1999;46:113-6.
61. Morice MC, Serruys PW, Sousa JE, et al. A randomized comparison of a sirolimus-eluting stent with a standard stent for coronary revascularization. *N Engl J Med* 2002;346:1773-80.
62. Sousa JE, Abizaid A, Abizaid A, et al. Late (two-year) follow-up from the First-In-Man (FIM) experience after implantation of sirolimus-eluting stents (abstr). *J Am Coll Cardiol* 2002;39 Suppl A:21A.
63. Moses J, Leon M, Popma J, et al. The U.S. multicenter, randomized, double blind study of the sirolimus-eluting stent in coronary lesions early (30 day) safety results (abstr). *Circulation* 2001;104 Suppl II:II464.
64. Serruys PW, Abizaid A, Foley D, et al. Sirolimus-eluting stents abolish neointimal hyperplasia in patients with in-stent restenosis: late angiographic and intravascular ultrasound results (abstr). *J Am Coll Cardiol* 2002;39 Suppl A:37A.
65. Grube E, Silber S, Hauptmann K, et al. TAXUS 1 prospective, randomized, double blind comparison of NIRX™ stents coated with paclitaxel in a polymer carrier in de novo coronary lesions compared with uncoated controls (abstr). *Circulation* 2001;104 Suppl II:II463.
66. Grube E, Serruys PW. Safety and performance of a paclitaxel-eluting stent for the treatment of in-stent restenosis: preliminary results of the TAXUS III trial (abstr). *J Am Coll Cardiol* 2002;39 Suppl A:58A.