

UNITED STATES PATENT AND TRADEMARK OFFICE

BEFORE THE PATENT TRIAL AND APPEAL BOARD

Abiomed, Inc., Abiomed R&D, Inc., and Abiomed Europe GmbH
Petitioners

v.

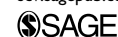Maquet Cardiovascular, LLC
Patent Owner

Case IPR2017-02151
U.S. Patent No. 9,327,068

PATENT OWNER'S EXHIBIT 2003

Advances in Perfusion Techniques: Minimally Invasive Procedures

Seminars in Cardiothoracic and
Vascular Anesthesia
2014, Vol. 18(2) 146–152
© The Author(s) 2014
Reprints and permissions:
sagepub.com/journalsPermissions.nav
DOI: 10.1177/1089253214530519
scv.sagepub.com



Kenneth Shann, CCP¹, and Serguei Melnitchouk, MD¹

Abstract

There is a growing demand from patients and referring physicians for minimally invasive cardiac surgery. Minimally invasive cardiac procedures are technically unique from conventional cardiac procedures and require a thorough understanding of the surgical, anesthetic, and perfusion strategies. Strategies include routine use of augmented venous drainage, alternative arterial and venous cannulation sites, and special cannulas designed for minimally invasive procedures. The following review describes the strategies and safety systems that should be considered when performing minimally invasive cardiac surgery.

Keywords

aortic valve replacement, cardiac surgery, cardiopulmonary bypass, minimally invasive surgery, mitral valve

Introduction

Minimally or less-invasive aortic and mitral valve procedures have become common, and compared with conventional procedures have been associated with fewer blood transfusions, improved pulmonary function, reduced post-operative pain, and shorter hospital length of stay.¹⁻⁹ A growing demand among patients and referring physicians as well as an increasing acceptance within the cardiac surgery community has driven the advancement of cardiopulmonary bypass (CPB) circuitry, cannulas, and techniques to facilitate these procedures. A variety of surgical and perfusion techniques for minimally invasive cardiac surgery have been reported.¹⁰⁻¹² It is incumbent on the clinical team to have a foundational understanding of these strategies in order to appropriately care for each individual patient. What follows is an overview of perfusion strategies for minimally invasive cardiac surgery, including circuit and cannula selection as well as management techniques.

CPB Circuit Design: Augmented Venous Drainage

Minimally invasive cardiac procedures often require smaller-caliber venous cannulas that have a higher resistance and render gravity venous drainage insufficient to allow for adequate CPB flow. For this reason augmentation of venous drainage is often required to achieve adequate CPB flow. Augmentation of venous flow can be achieved by utilizing either vacuum assisted-venous drainage (VAVD) or centrifugal-assisted venous drainage (CAVD). Figure 1 illustrates the CPB circuit configurations for VAVD and CAVD.

VAVD has been used in clinical practice for more than 15 years,¹³ but clinical teams must be familiar with its inherent risks to utilize VAVD safely and effectively.¹⁴ VAVD is performed via the application of external negative pressure (with an approved vacuum regulator, eg, the Boehringer model 3930) to a nonvented hard-shell venous reservoir. This negative pressure is ultimately imparted to the venous system of the patient and increases venous blood flow. The negative pressure is equal to the sum of gravity (–20 to –30 mm Hg depending on the height of the reservoir) combined with applied negative pressure (up to –70 mm Hg). The minimum amount of applied negative pressure should be used to achieve the required flow. To avoid blood trauma, the net negative pressure should not exceed –100 mm Hg.¹⁵ Below –120 mm Hg, the relationship between blood trauma and negative pressure is linear.

The nonvented reservoir also creates an opportunity for positive pressurization (generated through sucker and vent lines) and paradoxical venous air embolism.¹⁶ For this reason, reservoir pressure should be monitored (positive and negative), and an audible and visual alarm should be included to detect if the pressure in the reservoir becomes positive or too negative.¹⁷ In addition, most venous reservoirs incorporate a positive and negative pressure relief valve that will open if the pressure in the reservoir exceeds approximately 5 mm Hg or less than –150 mm Hg.

¹Massachusetts General Hospital Division of Cardiac Surgery, Boston, USA

Corresponding Author:

Kenneth Shann, Massachusetts General Hospital, 55 Fruit Street, Edwards 119, Boston, MA 02114, USA.

Email: kshann@partners.org

Maquet, Ex. 2003-1

IPR2017-02151

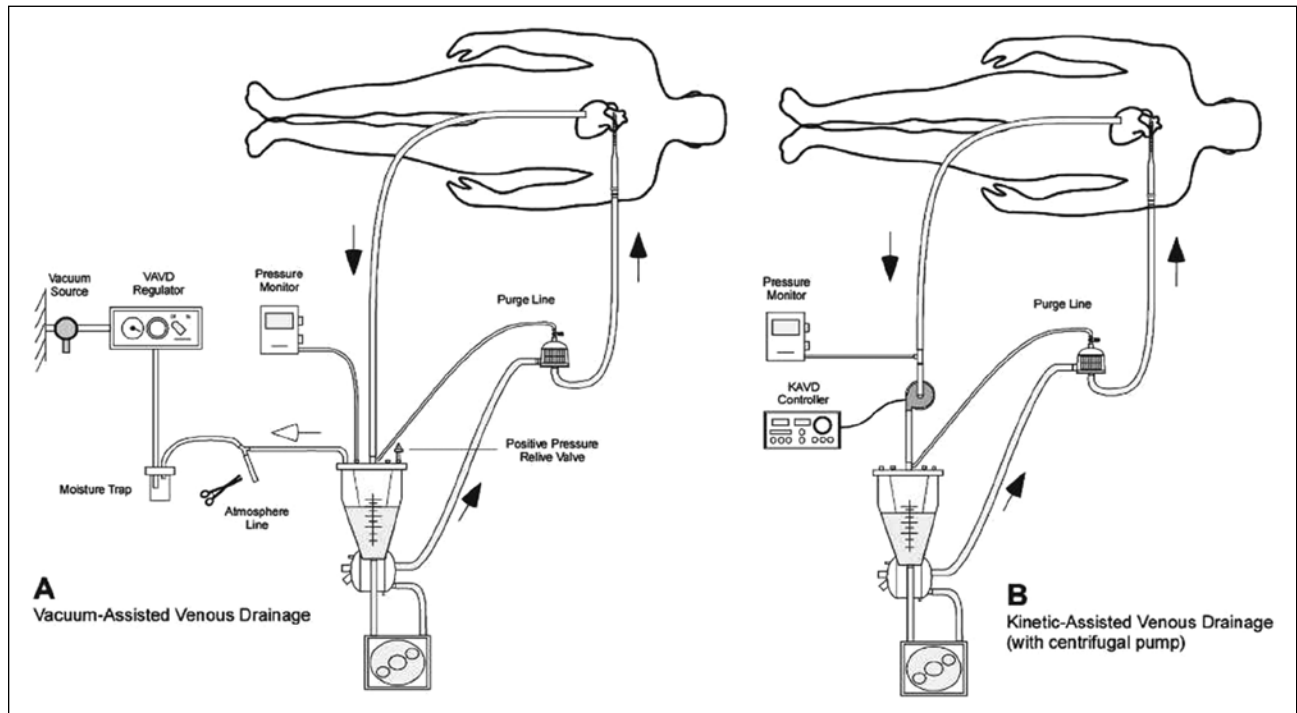


Figure 1. Schematic of VAVD and CAVD.

Abbreviations: VAVD, vacuum assisted-venous drainage; CAVD, centrifugal-assisted venous drainage.

Unlike a roller arterial pump (pictured in Figure 1), if a centrifugal arterial pump is used during VAVD, there is a risk of air entrainment via the hollow-fiber membrane oxygenator.¹⁸ Air can be transmitted across the fibers of the oxygenator if the RPMs of the centrifugal pump are lowered to the point where flow is reversed and negative pressure is imparted to the oxygenator. Incorporating a 1-way flow valve in the tubing between the venous reservoir and the oxygenator will prevent retrograde flow and the risk of negative pressure.¹⁷

Reports have illustrated that air entrained through the venous line of the CPB circuit gets through the reservoir, oxygenator, and arterial filter and can be detected in the arterial line.¹⁹⁻²¹ In the setting of venous air entrainment, relative to gravity drainage, VAVD has been shown to increase the rate of entrainment and total number of gaseous microemboli.²² Therefore, in the setting of venous air entrainment, VAVD should be minimized by minimizing the level of negative pressure. More important, every effort should be made to eliminate the source of any venous air.

CAVD is another method of augmenting venous drainage. This strategy may be considered more complicated than VAVD because it requires the perfusionist to operate 2 centrifugal pumps simultaneously. CAVD utilizes a second centrifugal pump that is placed in the venous line of the CPB circuit and is therefore also more expensive. The centrifugal pump creates negative pressure at the inlet and

actively augments venous flow. As with VAVD, CAVD in the setting of venous air entrainment has been shown to increase the volume of emboli; however, it has been suggested that CAVD breaks the emboli into smaller emboli and allows for easier passage through the CPB circuit.²³ The advantages of CAVD include the absence of the risks inherent to VAVD—namely, reservoir pressurization and oxygenator air entrainment. CAVD also provides the option to use a soft shell venous reservoir that has been shown in some studies to reduce blood activation and improve patient outcome.^{24,25}

In summary, we recommend the following to safely augment venous return during minimally invasive procedures:

- VAVD with an approved vacuum regulator—for example, Boehringer model 3930;
- total negative pressure (gravity + applied vacuum) should not be less than -100 mm Hg;
- use the minimum amount of applied negative pressure to achieve the desired flow;
- monitor venous reservoir positive and negative pressure with visual and audible alarms;
- when using a centrifugal arterial pump, incorporate a 1-way flow valve between the venous reservoir and oxygenator; and
- eliminate venous air entrainment in all clinical situations, especially during VAVD.

Table 1. Preferred Cannulation Sites by Procedure Type.^a

	Aortic Valve Replacement	Mitral Valve Repair/ Replacement	Tricuspid Valve Repair/Replacement, ASD Closure
Incision	Upper hemisternotomy Right anterior mini-thoracotomy (second or third ICS)	Right anterolateral minithoracotomy (fourth ICS) Lower hemisternotomy	Right anterolateral minithoracotomy (fourth ICS) Lower hemisternotomy
Arterial cannulation	Ascending aorta Femoral artery Axillary artery	Femoral artery Ascending aorta Axillary artery	Femoral artery Ascending aorta Axillary artery
Venous cannulation	Right atrium Femoral vein	Femoral vein (Also RIJ/SVC in concomitant RA procedures)	Femoral vein and RIJ/SVC

Abbreviations: ASD, atrial septal defect; ICS, intercostal space; RIJ, right internal jugular vein; SVC, superior vena cava; RA, right atrium.

^aBold script represents our preferred site/approach.

CPB Circuit Design: Hemodilution, Transfusion, and Oxygen Delivery

Many studies on CPB circuit size in conventional sternotomy procedures can be expanded and applied to strategies for minimally invasive procedures. Body size and gender are associated with low nadir hematocrit (HCT) and increased rates of transfusion during CPB, with women and smaller patients at greatest risk.²⁶ In addition, it was recently reported that even 1 or 2 units of red cell transfusions are associated with morbidity and mortality.²⁷ Reduction of the CPB circuit prime volume and autologous priming have been recommended to minimize the incidence of low nadir HCT and subsequent allogeneic blood transfusions.^{28,29} Several reports have illustrated that a reduction in surface area priming volume and matching the CPB circuit to the size of the patient reduces the frequency of low HCT values and subsequently reduces the incidence of allogeneic blood transfusions.³⁰⁻³³

In addition to efforts to maintain HCT, it is important to appreciate the concept of oxygen delivery (DO_2) during CPB for minimally invasive procedures. DO_2 is dependent on the combination of HCT and CPB flow rates. DO_2 can be calculated using the following formula:

$$\text{DO}_2 = \text{CPB flow indexed} \times 10 (\text{Hemoglobin} \times 1.36 \times \text{Sat}) + (\text{paO}_2 \times 0.003). \quad (1)$$

DO_2 levels below 262 mL/min/m² during CPB with moderate hypothermia have been associated with acute kidney injury.³⁴ This concept can be particularly useful in the setting of minimally invasive procedures with peripheral cannulation where higher CPB flows may be more challenging than conventional sternotomy procedures. Just as in conventional procedures, efforts to provide adequate CPB flow to maintain DO_2 levels ≥ 262 mL/min/m² may minimize the incidence of acute kidney injury.

In summary, we recommend the following strategies to minimize hemodilution and transfusion and maintain adequate DO_2 during minimally invasive procedures:

- Match the size of the circuit to the size of the patient
- 3/8" venous line with VAVD
- lower prime oxygenators and filters
- minimized tubing length
- Calculate and maintain $\text{DO}_2 \geq 262 \text{ mL/min/m}^2$.

Arterial Cannulation Considerations

The surgical procedure and strategy will dictate the arterial cannulation technique required. The options for cannulation site include ascending aorta, femoral artery, and axillary artery and are outlined in Table 1. The ascending aorta is commonly used for procedures that include an upper- or lower-hemisternotomy—for example, aortic or mitral valve procedures. The aorta can also be cannulated directly via the thoracotomy incision.³⁵

The femoral artery is often used for procedures that utilize a right anterolateral minithoracotomy incision: for example, the mitral valve, atrial septal defect, or tricuspid valve repair procedures. Recently an increased risk of neurological complications has been reported with the use of femoral retrograde perfusion versus central antegrade perfusion.³⁶ However, others have advocated for the screening of patients at risk for aortoiliac atherosclerosis with contrast-enhanced multidetector CT, with avoidance of femoral cannulation in patients with grade IV/V atheroma.³⁷

In patients who already have preoperative coronary angiography, our current strategy is to obtain multidetector CT angiography of the chest, abdomen, and pelvis in all patients older than 65 years of age or those having a significant history of smoking, hypertension, or peripheral arterial disease. Our evolving strategy is to obtain preoperative ECG-gated cardiac CT angiography coupled with a

non-ECG-gated CT angiography of the abdomen and pelvis in all patients undergoing minimally invasive mitral valve repair. This allows us to screen the majority of patients for coronary artery disease, evaluate the presence of mitral annular calcification, rule out significant aortoiliac atherosclerosis, and assess aortal dimensions with 1 noninvasive test. Coronary angiography is then obtained as an adjunctive screening test in older patients and those with significant risk factors. Similarly, the group from Cleveland Clinic advocates for CT angiography in all patients undergoing minimally invasive robotic mitral valve surgery because aortoiliac atherosclerosis and/or mitral annular calcification has changed their operative strategy in 20% of screened patients, albeit the majority of that quintile's patients were older and had other risk factors.³⁸

The axillary artery can be used for arterial access in situations where the femoral approach is prohibitive because of atherosclerosis or tortuosity. In addition, the axillary has also been used for minimal access ascending and aortic arch surgery through an upper hemisternotomy.³⁹

There are arterial cannulas that have been designed primarily for minimally invasive cardiac valve surgery. ThruPort Systems (Edwards Lifesciences; Irvine, CA) is a system of minimally invasive cannulas (<http://www.edwards.com/Products/MIVS/Pages/MIVS.aspx>) that are designed to facilitate minimally invasive intracardiac procedures. ThruPort commonly utilizes the EndoReturn femoral artery cannula that is inserted under direct vision using the Seldinger technique. For isolated mitral valve procedures, the IntraClude catheter can also be used to facilitate endovascular aortic cross-clamping, cardioplegia delivery, and aortic root venting. The IntraClude is inserted through a side arm of the EndoReturn cannula and advanced into the ascending aorta under transesophageal echocardiogram (TEE) guidance.

The ascending aorta can be cannulated for minimally invasive procedures with a variety of cannulas that have been designed for ascending aortic cannulation. At our center, we use a small caliber (7 mm) wire-reinforced diffusion cannula. There are other arterial cannulas, such as the Fem-Flex II (Edwards Lifesciences, Irvine, CA) and Bio-Medicus (Medtronic, Minneapolis, MN), that are designed for percutaneous femoral arterial cannulation using a modified Seldinger technique. Tables 2 and 3 provide reference values for the arterial cannula options we utilize.

In addition, the axillary artery can be cannulated utilizing the graft interposition technique and sewing a 8-mm Gore-Tex graft end-to-side to the artery and then inserting a 1/4" × 3/8" connector into the graft. The graft is secured to the connector with heavy sutures or umbilical tape. In summary, we recommend the following strategies for arterial cannulation during minimally invasive procedures:

Table 2. Ascending Aortic Cannula, Estimated Flow Rates.

BSA	Size	Maximum Flow (L/min)	Model	Manufacturer
≤2.0 m ²	6.0 mm	4.8	Soft-Flow	Terumo
>2.0 m ² to <2.5 m ²	7.0 mm	6.0	Soft-Flow	Terumo
≥2.5 m ²	8.0 mm	8.0	Soft-Flow	Terumo

Abbreviations: BSA, Body Surface Area

Table 3. Femoral Artery Cannula, Estimated Flow Rates.

BSA	Size	Maximum Flow (L/min)	Model	Manufacturer
≤1.3 m ²	15 Fr	2.5	Bio-Medicus	Medtronic
≤1.3 m ²	16 Fr	3.2	Fem-Flex	Edwards Life Science
1.3 m ² to 1.7 m ²	17 Fr	4.0	Bio-Medicus	Medtronic
1.3 m ² to 1.9 m ²	18 Fr	4.6	Fem-Flex	Edwards Life Science
1.9 m ² to 2.2 m ²	19 Fr	5.3	Bio-Medicus	Medtronic
>1.9 m ²	20 Fr	6.0	Fem-Flex	Edwards Life Science
>2.2 m ²	21 Fr	6.0	Bio-Medicus	Medtronic

- surgical procedure and patient disease characteristics will dictate the site of arterial cannulation and
- when considering femoral arterial cannulation, CT angiography should be utilized to screen patients at risk for aortoiliac atherosclerosis.

Venous Cannulation Considerations

The surgical procedure and strategy will also dictate the venous cannulation technique required. The options are outlined in Table 1. If an upper or lower hemisternotomy is performed, direct right atrial (RA), superior vena cava (SVC), or inferior vena cava (IVC) cannulation can be utilized. If a right thoracotomy is performed, the right femoral vein is commonly cannulated, and placement is guided via TEE. The femoral venous cannula can be advanced through the RA and into the SVC for bicaval single cannula drainage or can be placed at the junction of the IVC and RA for bicaval dual cannula drainage. SVC cannulation can also be performed percutaneously using a modified Seldinger technique through the right internal jugular (RIJ) vein or a direct SVC cannulation through the thoracotomy. In addition to the obligatory indication for bicaval cannulation in RA procedures, for example, tricuspid valve repair or atrial septal defect repair, to facilitate adequate venous drainage, some groups routinely place a percutaneous RIJ cannula in patients who exceed a body weight of 75 to 80 kg.

RIJ cannulation is most commonly performed with ultrasound guidance by the anesthesia team. Two guidewires are

placed in the RIJ vein (the distal one for the PA catheter sheath and the more proximal one for the neck cannula). A bolus of 5000 units of heparin is administered, and using the Seldinger technique with serial dilation to appropriate diameter, a 15-, 17-, or 19-Fr Bio-Medicus femoral arterial cannula is placed and advanced to the RA/SVC junction with TEE guidance. If the RIJ vein is measured on ultrasound to be larger than 1 cm, a 17- or 19-Fr cannula is commonly utilized. After RIJ cannula insertion, heparinized saline is infused slowly (5000 units of heparin in 1000 mL of normal saline) via the leur port on the cannula until full heparinization for CPB occurs. The RIJ cannula is connected to the CPB circuit via a split venous line and clamped. This clamp is removed by the perfusionist at the initiation of CPB and clamped by the perfusionist at the commencement of CPB. Because this line is typically routed outside the surgical field, teams are encouraged to be vigilant with the management of this line to avoid unintentional venous drainage before or after CPB. The RIJ cannula is removed at the end of the procedure, the purse string on the skin is tied, and pressure is applied for 15 minutes.

QuickDraw (Edwards Lifesciences; Irvine, CA) femoral venous cannulas are designed with multiple drainage holes to facilitate the ThruPort procedure but can be used for other minimally invasive procedures as well. The Remote Access Perfusion (Sorin Group Italia, Mirandola, Italy) femoral venous cannulas have a bicaval multiple drainage hole design, can be inserted percutaneously, have excellent flow characteristics, and have become our preferred cannula. These cannulas are commonly inserted in the femoral vein under direct vision using the modified Seldinger technique. They are also long enough (65 cm) to be advanced into the SVC to facilitate bicaval single-cannula drainage. Tables 4 and 5 provide reference values for the venous cannula options we utilize.

There are other femoral venous cannulas that have been designed to facilitate peripheral CPB and can be used for minimally invasive cardiac surgery, including the Fem-Flex II and Bio-Medicus. Depending on the size of the cannula, they can be placed percutaneously or under direct vision. It is common practice at our center to perform all femoral cannulation under direct vision over an Amplatz Super Stiff J-Tip guidewire (Boston Scientific Corp, Natick, MA).

In summary, we recommend the following strategies for venous cannulation during minimally invasive procedures:

- surgical procedure and patient disease characteristics will dictate the site of arterial cannulation;
- our preference is to use the 23/25Fr RAP cannula for all femoral venous cannulations;
- an IJ venous cannula (15-, 17-, 19-Fr Bio-Medicus femoral arterial) should be used for right-sided procedures and in patients >80 kg having mitral valve procedures; and

Table 4. Right Atrial Cannula, Estimated Flow Rates.

BSA	Size	Maximum Flow (L/min)	Model	Manufacturer
$\leq 1.8 \text{ m}^2$	29/37 Fr	4.5	Thin-Flex	Edwards Life Science
$> 1.8 \text{ m}^2$ to 2.5 m^2	32/40 Fr	6.0	MC2	Medtronic
$\geq 2.5 \text{ m}^2$	36/46 Fr	8.0	MC2	Medtronic

Table 5. Femoral Venous Cannula, Estimated Flow Rates.

Size	Augmented Maximum Flow (L/min) ^a	Model	Manufacturer
17 Fr	2.6	Bio-Medicus one piece	Medtronic
19 Fr	3.5	Bio-Medicus one piece	Medtronic
19 Fr	3.8	Bio-Medicus multistage	Medtronic
21 Fr	4.0	Bio-Medicus one piece	Medtronic
21 Fr	4.5	Bio-Medicus Multistage	Medtronic
22 Fr	4.6	Remote Access Perfusion (RAP)	Sorin
25 Fr	5.2	Bio-Medicus Multistage	Medtronic
23/25 Fr	5.2	RAP	Sorin

^aApproximate cardiopulmonary bypass flow with net (gravity + applied) negative pressure of -80 to -100 mm Hg.

- a protocol for safely managing the venous line connected to the IJ cannula should be developed; the IJ is commonly cannulated and connected to the venous line outside of the surgical field.

Cardioplegia Considerations

The EndoClamp catheter can be utilized to facilitate endovascular aortic cross-clamping, antegrade cardioplegia delivery, aortic root venting, and aortic root pressure monitoring during mitral valve or right-heart procedures.⁴⁰ The EndoClamp is advanced through the EndoArterial Return cannula, up the descending aorta and into the ascending aorta under TEE guidance. The EndoClamp incorporates a balloon that is inflated with saline via a separate lumen to occlude the aorta. Once the balloon is occlusive, antegrade cardioplegia is delivered through a separate lumen to arrest the heart. Strict attention must be given to the aortic root pressure, balloon pressure, right radial pressure, and TEE to confirm appropriate placement of the balloon and effective cardioplegia delivery.

The ProPlege sinus catheter and EndoVent pulmonary artery (PA) catheters are also available from Edwards to facilitate retrograde cardioplegia delivery and PA venting. These cannulas are also part of the ThruPort procedure and are inserted percutaneously via the RIJ vein.

The most common strategy for cardioplegia delivery in minimally invasive procedures is via direct cannulation of the aorta, with a long 7-Fr (14 Ga) cardioplegia needle (Sorin

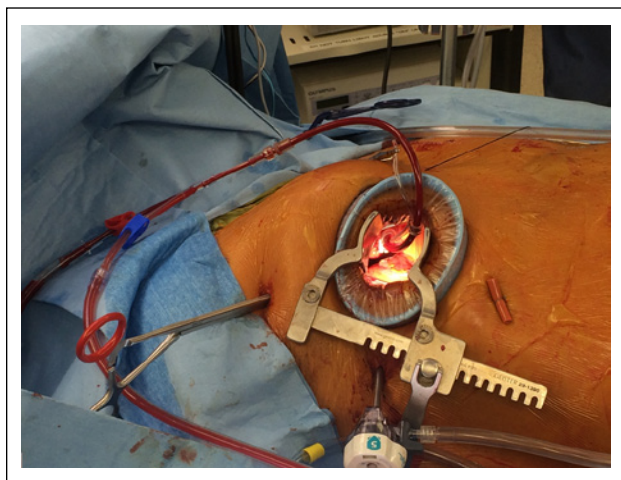


Figure 2. Setup for minimally invasive mitral valve: antegrade cardioplegia cannula, vent line, and aortic cross-clamp.

Group Italia; Mirandola, Italy). Figure 2 illustrates the surgical setup with cardioplegia/aortic root vent cannula and cross-clamp in place. The needle also allows aortic root venting to be performed. Retrograde cardioplegia catheters can also be directly inserted. At our center, we prefer not to use retrograde cardioplegia because it is difficult to assess the position of the catheter as well as to confirm the adequacy of delivery. Furthermore, a coronary sinus injury would be a significant complication in the minimally invasive setting. Antegrade delivery of cardioplegia can be either intermittent with traditional blood or crystalloid cardioplegia or a 1-dose delivery using either 2 L of Bretschneider (Custodiol)⁴¹ or 1.2 L of del Nido cardioplegia solutions.

In summary, we recommend the following strategies for cardioplegia delivery during minimally invasive procedures:

- antegrade delivery through direct aortic root cannulation, and
- single-dose cardioplegia (Custodiol or del Nido) may safely facilitate uninterrupted surgical progress.

Conclusion

Minimally invasive cardiac surgery is performed commonly with outcomes comparable to the conventional sternotomy approach. With a thorough understanding of the foundational concepts of these procedures, they can be performed safely and effectively. Each individual patient requires surgical, anesthetic, and perfusion collaboration to identify the optimal strategy for that patient's operation.

Acknowledgment

Some portions of this review were presented in a syllabus for an invited lecture at the Society of Cardiovascular Anesthesiologist's 14th Annual Update on Cardiopulmonary Bypass Conference.

Declaration of Conflicting Interests

The author(s) declared no potential conflicts of interest with respect to the research, authorship, and/or publication of this article.

Funding

The author(s) received no financial support for the research, authorship, and/or publication of this article.

References

1. Mohr FW, Onnasch JF, Falk V, et al. The evolution of minimally invasive valve surgery: 2 year experience. *Eur J Cardiothorac Surg.* 1999;15:233-238; discussion 238-239.
2. Seeburger J, Borger MA, Falk V, et al. Minimal invasive mitral valve repair for mitral regurgitation: results of 1339 consecutive patients. *Eur J Cardiothorac Surg.* 2008;34:760-765.
3. Goldstone AB, Atluri P, Szeto WY, et al. Minimally invasive approach provides at least equivalent results for surgical correction of mitral regurgitation: a propensity-matched comparison. *J Thorac Cardiovasc Surg.* 2013;145:748-756.
4. Suri RM, Burkhart HM, Rehfeldt KH, et al. Robotic mitral valve repair for all categories of leaflet prolapse: improving patient appeal and advancing standard of care. *Mayo Clin Proc.* 2011;86:838-844.
5. Johnston DR, Atik FA, Rajeswaran J, et al. Outcomes of less invasive J-incision approach to aortic valve surgery. *J Thorac Cardiovasc Surg.* 2012;144:852-858.e3.
6. Svensson LG, Atik FA, Cosgrove DM, et al. Minimally invasive versus conventional mitral valve surgery: a propensity-matched comparison. *J Thorac Cardiovasc Surg.* 2010;139:926-932.e1-2.
7. Grossi EA, Galloway AC, LaPietra A, et al. Minimally invasive mitral valve surgery: a 6-year experience with 714 patients. *Ann Thorac Surg.* 2002;74:660-663; discussion 663-664.
8. Mihaljevic T, Cohn LH, Unic D, Aranki SF, Couper GS, Byrne JG. One thousand minimally invasive valve operations: early and late results. *Ann Surg.* 2004;240:529-534; discussion 534.
9. Doll N, Walther T, Falk V, et al. Secundum ASD closure using a right lateral minithoracotomy: five-year experience in 122 patients. *Ann Thorac Surg.* 2003;75:1527-1530; discussion 30-31.
10. Gundry SR, Shattuck OH, Razzouk AJ, del Rio MJ, Sardari FF, Bailey LL. Facile minimally invasive cardiac surgery via ministernotomy. *Ann Thorac Surg.* 1998;65:1100-1104.
11. Cosgrove DM III, Sabik JF, Navia JL. Minimally invasive valve operations. *Ann Thorac Surg.* 1998;65:1535-1538; discussion 1538-1539.
12. Gillinov AM, Banbury MK, Cosgrove DM. Hemisternotomy approach for aortic and mitral valve surgery. *J Card Surg.* 2000;15:15-20.
13. Munster K, Andersen U, Mikkelsen J, Pettersson G. Vacuum assisted venous drainage (VAVD). *Perfusion.* 1999;14:419-423.
14. Wang S, Undar A. Vacuum-assisted venous drainage and gaseous microemboli in cardiopulmonary bypass. *J Extra Corpor Technol.* 2008;40:249-256.

15. Mulholland JW, Massey W, Shelton JC. Investigation and quantification of the blood trauma caused by the combined dynamic forces experienced during cardiopulmonary bypass. *Perfusion*. 2000;15:485-494.
16. Davila RM, Rawles T, Mack MJ. Venoarterial air embolus: a complication of vacuum-assisted venous drainage. *Ann Thorac Surg*. 2001;71:1369-1371.
17. Baker RA, Bronson SL, Dickinson TA, et al. Report from AmSECT's international consortium for evidence-based perfusion: American Society of Extracorporeal Technology Standards and Guidelines for Perfusion Practice. *J Extra Corpor Technol*. 2013;45:156-166.
18. Jegger D, Tevaearai HT, Mueller XM, Horisberger J, von Segesser LK. Limitations using the vacuum-assist venous drainage technique during cardiopulmonary bypass procedures. *J Extra Corpor Technol*. 2003;35:207-211.
19. Jones TJ, Deal DD, Vernon JC, Blackburn N, Stump DA. How effective are cardiopulmonary bypass circuits at removing gaseous microemboli? *J Extra Corpor Technol*. 2002;34:34-39.
20. Jones TJ, Deal DD, Vernon JC, Blackburn N, Stump DA. Does vacuum-assisted venous drainage increase gaseous microemboli during cardiopulmonary bypass? *Ann Thorac Surg*. 2002;74:2132-2137.
21. Groom RC, Quinn RD, Lennon P, et al. Detection and elimination of microemboli related to cardiopulmonary bypass. *Circ Cardiovasc Qual Outcomes*. 2009;2:191-198.
22. Willcox TW, Mitchell SJ, Gorman DF. Venous air in the bypass circuit: a source of arterial line emboli exacerbated by vacuum-assisted drainage. *Ann Thorac Surg*. 1999;68:1285-1289.
23. Rider SP, Simon LV, Rice BJ, Poulton CC. Assisted venous drainage, venous air, and gaseous microemboli transmission into the arterial line: an in-vitro study. *J Extra Corpor Technol*. 1998;30:160-165.
24. Schonberger JP, Everts PA, Hoffmann JJ. Systemic blood activation with open and closed venous reservoirs. *Ann Thorac Surg*. 1995;59:1549-1555.
25. Brown Mahoney C, Donnelly JE. Impact of closed versus open venous reservoirs on patient outcomes in isolated coronary artery bypass graft surgery. *Perfusion*. 2000;15:467-472.
26. Ranucci M, Pazzaglia A, Bianchini C, Bozzetti G, Isgro G. Body size, gender, and transfusions as determinants of outcome after coronary operations. *Ann Thorac Surg*. 2008;85:481-486.
27. Paone G, Likosky DS, Brewer R, et al. Transfusion of 1 and 2 units of red blood cells is associated with increased morbidity and mortality. *Ann Thorac Surg*. 2014;97:87-93; discussion 94.
28. Ferraris VA, Brown JR, Despotis GJ, et al. 2011 Update to the Society of Thoracic Surgeons and the Society of Cardiovascular Anesthesiologists blood conservation clinical practice guidelines. *Ann Thorac Surg*. 2011;91:944-982.
29. Shann KG, Likosky DS, Murkin JM, et al. An evidence-based review of the practice of cardiopulmonary bypass in adults: a focus on neurologic injury, glycemic control, hemodilution, and the inflammatory response. *J Thorac Cardiovasc Surg*. 2006;132:283-290.
30. McCusker K, Vijay V, DeBois W, Helm R, Sisto D. MAST system: a new condensed cardiopulmonary bypass circuit for adult cardiac surgery. *Perfusion*. 2001;16:447-452.
31. Cormack JE, Forest RJ, Groom RC, Morton J. Size makes a difference: use of a low-prime cardiopulmonary bypass circuit and autologous priming in small adults. *Perfusion*. 2000;15:129-135.
32. Beholz S, Zheng L, Kessler M, Rusche M, Konertz W. A new PRECiSe (priming reduced extracorporeal circulation setup) minimizes the need for blood transfusions: first clinical results in coronary artery bypass grafting. *Heart Surg Forum*. 2005;8:E132-E135.
33. Bronson SL, Riley JB, Blessing JP, Ereth MH, Dearani JA. Prescriptive patient extracorporeal circuit and oxygenator sizing reduces hemodilution and allogeneic blood product transfusion during adult cardiac surgery. *J Extra Corpor Technol*. 2013;45:167-172.
34. de Somer F, Mulholland JW, Bryan MR, Aloisio T, Van Nooten GJ, Ranucci M. O₂ delivery and CO₂ production during cardiopulmonary bypass as determinants of acute kidney injury: time for a goal-directed perfusion management? *Crit Care*. 2011;15:R192.
35. Iribarne A, Easterwood R, Russo MJ, Chan EY, Smith CR, Argenziano M. Comparative effectiveness of minimally invasive versus traditional sternotomy mitral valve surgery in elderly patients. *J Thorac Cardiovasc Surg*. 2012;143: S86-S90.
36. Murzi M, Cerillo AG, Miceli A, et al. Antegrade and retrograde arterial perfusion strategy in minimally invasive mitral-valve surgery: a propensity score analysis on 1280 patients. *Eur J Cardiothorac Surg*. 2013;43:e167-e172.
37. Modi P, Chitwood WR Jr. Retrograde femoral arterial perfusion and stroke risk during minimally invasive mitral valve surgery: is there cause for concern? *Ann Cardiothorac Surg*. 2013;2:E1.
38. Moodley S, Schoenhagen P, Gillinov AM, et al. Preoperative multidetector computed tomography angiography for planning of minimally invasive robotic mitral valve surgery: impact on decision making. *J Thorac Cardiovasc Surg*. 2013;146:262-268.e1.
39. Svensson LG. Progress in ascending and aortic arch surgery: minimally invasive surgery, blood conservation, and neurological deficit prevention. *Ann Thorac Surg*. 2002;74:S1786-S1788; discussion S92-S99.
40. Casselman FP, Van Slycke S, Dom H, Lambrechts DL, Vermeulen Y, Vanermen H. Endoscopic mitral valve repair: feasible, reproducible, and durable. *J Thorac Cardiovasc Surg*. 2003;125:273-282.
41. Misfeld M, Davierwala P. Crystalloid-based cardioplegia for minimally invasive cardiac surgery. *Semin Thorac Cardiovasc Surg*. 2012;24:305-307.