

# Subcutaneous Incisionless (Subcision) Surgery for the Correction of Depressed Scars and Wrinkles

DAVID S. ORENTREICH, MD  
NORMAN ORENTREICH, MD, FACP



**BACKGROUND.** A new method of subcuticular undermining for the treatment of depressed cutaneous scars and wrinkles is introduced.

**OBJECTIVE.** To define the newly coined term "Subcision" and to describe this minor surgical procedure for treating depressed scars and wrinkles.

**METHODS.** A tri-beveled hypodermic needle is inserted through a puncture in the skin surface (hence, "incisionless" surgery), and its sharp edges are maneuvered under the defect to make subcuticular cuts or "-cisions."

**RESULTS.** The depression is lifted by the releasing action of the procedure, as well as from connective tissue that forms in the course of normal wound healing.

**CONCLUSION.** This technique is useful in treating a variety of cutaneous depressions, including scars and wrinkles. *Dermatol Surg* 1995;21:543-549.

A complex problem confronts the skin surgeon who attempts to correct depressed scars and wrinkles. In light of the various causes, anatomy of depressed areas, patient type, and patient response to wounding, it is unlikely that one treatment modality will successfully improve all depressions. Therefore, the greater the number of treatment options available, the more likely the surgeon is to obtain successful correction.

The use of injectable soft tissue-augmenting implants has grown in both frequency and type. The shortcomings of currently available materials have spurred the ongoing development of techniques to correct depressed scars, wrinkles, and contours.

The term Subcision<sup>1</sup> describes a unique form of incisionless local subcuticular undermining. The word Subcision is a contraction of "subcutaneous incisionless" surgery, and is the method of cutting under a depressed scar, wrinkle, or contour using a tri-beveled hypodermic needle inserted under the skin through a needle puncture. The procedure attempts to raise the base of the defect to the level of the surrounding skin surface.

*In private practice.*

Address correspondence and reprint requests to: David S. Orentreich, MD, The Orentreich Medical Group, 909 Fifth Avenue, New York, NY 10021.

The integrity of the skin surface is compromised as with a routine needle puncture.

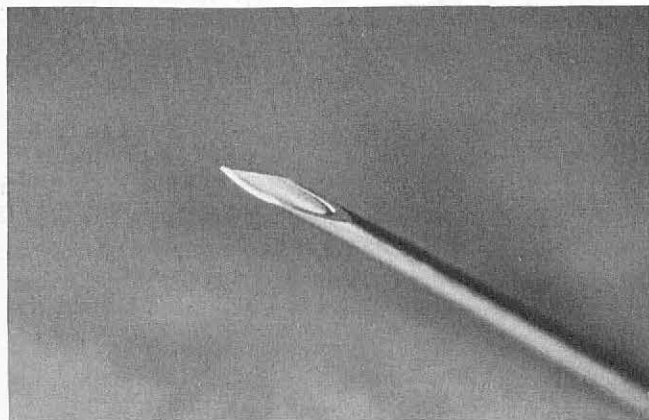
The effectiveness of Subcision for correcting various types of skin depressions depends on two distinct phenomena. First, the act of surgically releasing the skin from its attachment to deeper tissues results in skin elevation. Second, the introduction of a controlled trauma initiates wound healing with consequent formation of connective tissue which augments the depressed site.

In 1957, Spangler<sup>2</sup> reported using a Bowman iris needle to cut the fibrous strands beneath deeply depressed facial scars prior to injecting fibrin foam into the resulting cavity. In 1977, Gottlieb<sup>3</sup> pursued this approach, eventually leading to the development of Fibrel.<sup>4</sup> The Fibrel kit is equipped with a 20-gauge needle that is used to undermine fibrotic depressed scars. This undermining creates a pocket in the dermis into which the Fibrel is injected.<sup>5</sup> However, the studies evaluating Fibrel's efficacy did not include positive controls, ie, fibrotic scars treated by undermining alone.<sup>4,6</sup> In 1989, Koranda<sup>7</sup> reported the treatment of bound-down acne "crater" scars by inserting a No. 69 Beaver blade through a stab incision in the skin, sweeping through the scar tissue under the "crater," and allowing for clot formation followed by fibrosis to maintain the elevation. In 1992, Hambley and Carruthers<sup>8</sup> used an 18-gauge needle inserted through the skin to release depressed, bound-down, full-thickness skin grafts on the nose prior to micro-lipoinjection. Again, no positive controls were reported.

To the best of our knowledge, the use of subcuticular undermining to improve scars and wrinkles without the additional benefit of injectable augmenting agents has not previously been reported.

## Technique

Subcision surgery uses standard, readily available, and inexpensive materials. A sterile, disposable, 1-inch, 22-gauge, hypodermic B-D needle suffices for most cases, however, needles of different lengths and gauges are also useful. Close inspection reveals that these needles



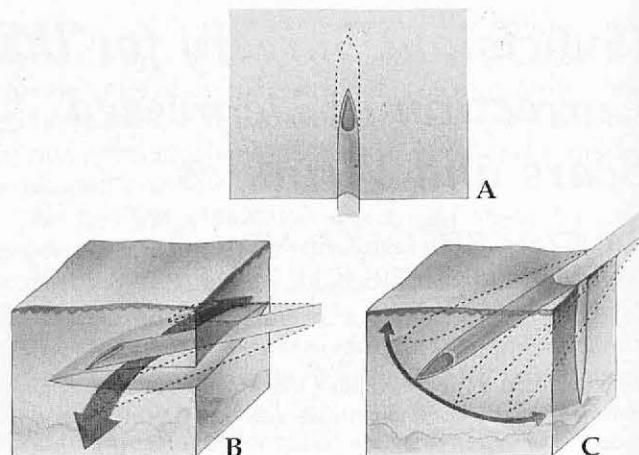
**Figure 1.** Tri-beveled hypodermic needle. Note its sharp edges.

are tri-beveled to enhance their ability to puncture skin with minimal resistance (Figure 1). During Subcision, the sharp edges are manipulated while under the skin to cut subsurface tissue. Needles as large as 16 gauge may be used to treat cellulite and large, bound-down scars such as healed surgical drain sites. Needles of 25-27 gauge (and even 30 gauge) can be used on particularly small, superficial facial scars and wrinkles, though care must be taken not to bend the finer caliber needles.

Areas to be subcised are first cleansed to remove dirt and makeup. Overhead lighting is adjusted to fully and precisely delineate the depressions, which are then outlined with a marking pen and subsequently anesthetized, typically with a 2% lidocaine with 1:100,000 epinephrine solution. Epinephrine is not used when contraindicated. A eutectic mixture of local anesthetic (EMLA) cream may be used to produce topical analgesia prior to anesthetic injection. Local anesthesia should extend for several millimeters beyond the border of a marked area to ensure pain-free entry of the Subcision needle.

How one holds the Subcision needle is a matter of personal preference, influenced by the needle size and the treatment site. Generally, one either grasps the needle by its hub, or clamps the needle in a needle holder.

After sufficient time has elapsed for maximal vasoconstriction, a needle of chosen gauge is inserted a few millimeters from the depressed site and advanced underneath it. The bevel is oriented upwards on insertion, and the angle of insertion is acute. The entry point into the skin acts as a pivot about which the needle is moved. The sharp edges of the tri-beveled needle tip are maneuvered to cut under the skin surface. The free hand acts as a guide to Subcision and is used as needed to pinch, stretch, or stabilize the treatment site. If the needle is shorter than the full length of the wrinkle or scar, multiple puncture sites are chosen depending on the size and shape of the depression.



**Figure 2.** Nomenclature. A) Lancing Subcision denotes inserting and withdrawing movements. B) Horizontal fanning Subcision denotes side-to-side movement. Note that bevel is pointing upwards. C) Vertical Subcision denotes cutting in a plane that is perpendicular to the skin surface. Note the bevel is oriented vertically.

The term "lancing" Subcision describes a simple linear inserting-withdrawing movement of the needle; this technique may be used under "crow's feet" type wrinkles or when subcising very fibrotic scars (Figure 2A).

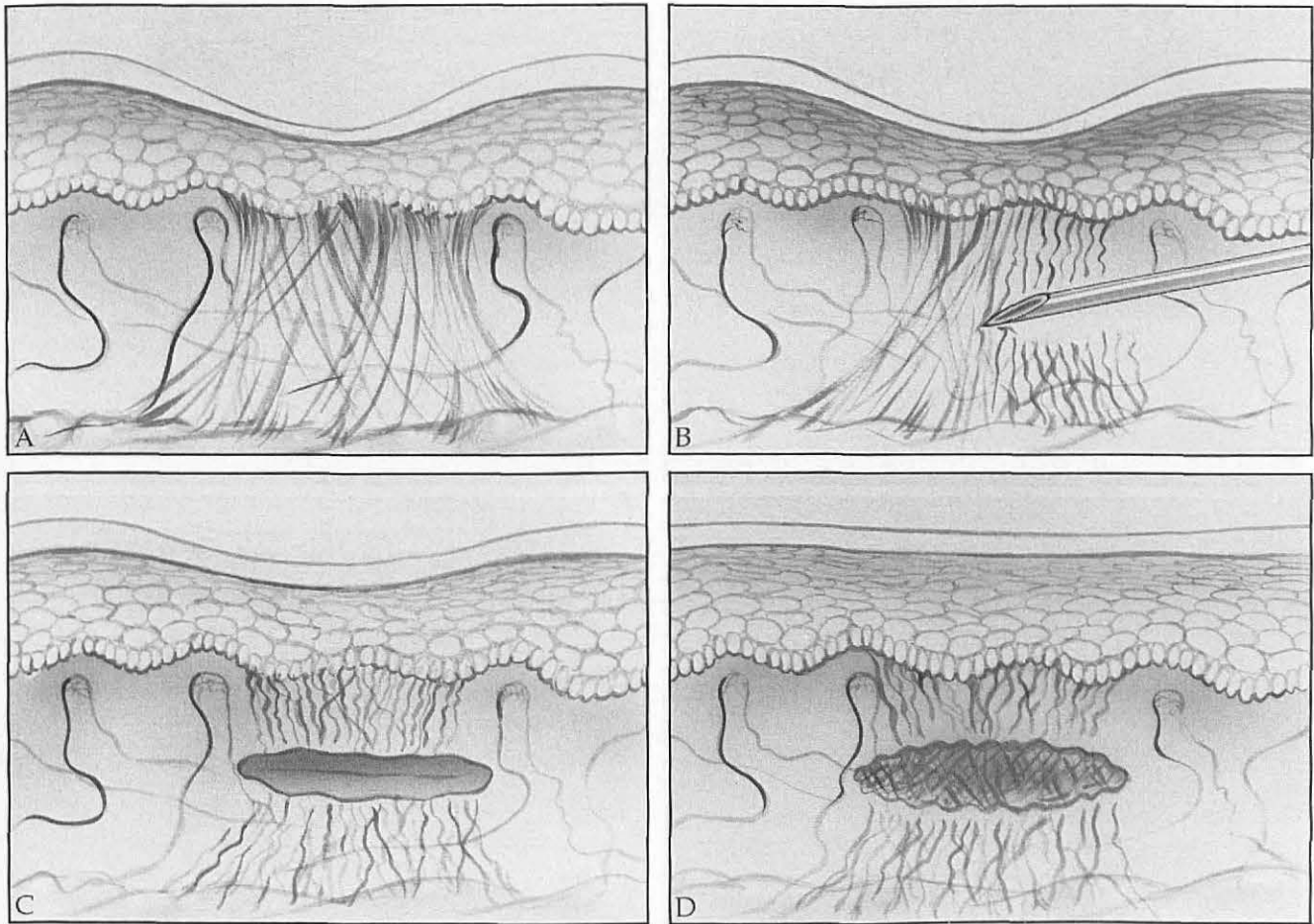
"Fanning horizontal" Subcision describes moving the needle, bevel-side up, in a horizontal plane, from side to side, back and forth, while inserting and withdrawing it in a fanlike motion (Figure 2B). After insertion, the bevel may be turned vertically to cut in a plane that is perpendicular to the skin surface when withdrawing the needle. This is termed "vertical" Subcision (Figure 2C). When used on wrinkles, vertical Subcision cuts at a right angle across superficially situated facial muscle fibers, thereby hampering the muscle's ability to wrinkle the skin.

Direct, manual pressure is applied by a medical assistant or the patient immediately after a site is treated, and pressure is maintained for several minutes to obtain hemostasis. Antibiotics are not usually prescribed unless there is a particular indication. Patients may apply makeup or Micropore tape to camouflage bruised areas.

Subcision is performed at precise, predetermined depths to ensure optimal results. The depth chosen depends on the indication, location of tethering structures, and the local micro-anatomy.

When treating depressed, bound-down scars, Subcision is usually performed in the mid- to deep-dermis. Cutting through the fibrous bands of scar tissue permits the skin surface to elevate (Figure 3). To correct distensible, depressed scars, Subcision is usually performed in the deep dermis or subdermally.

When treating facial expression lines, Subcision is subdermal in order to release facial muscle fiber and



**Figure 3.** Treatment of bound-down scars. A) Fibrous bands tether scar surface down. B) Subcision of tethered scar releases depressed area. C) Extravasated blood collects in Subcision wound. D) Wound heals with formation of new connective tissue, which further augments depressed areas.

superficial musculoaponeurotic system (SMAS) insertions into the dermis (Figure 4). Small, superficial wrinkles (such as those radiating from the lateral canthus or from the vermillion border) may be treated with upper-dermal, mid-dermal, or subdermal Subcision depending on wrinkle morphology and on the patient's response to previous Subcision.

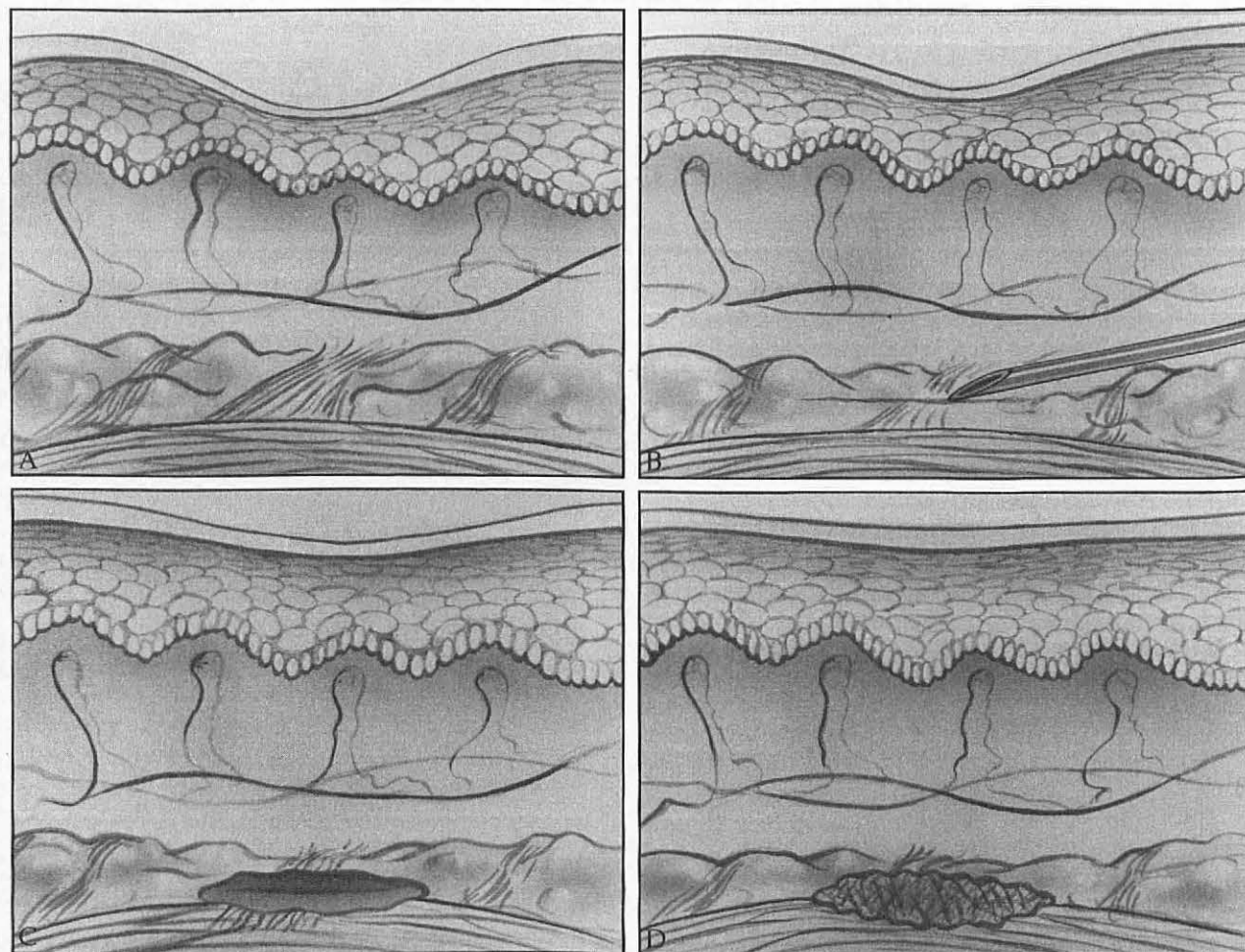
The dimpled appearance of skin on the upper legs and buttocks, commonly known as "cellulite," is partially caused by fibrous septae arising from the deep fascia investing skeletal muscles, traversing the adipose layer, and inserting into skin, thereby tethering it. These fibrous septae can be divided by Subcision in the adipose layer.

Since each individual's ability to form collagen varies, it is not possible to predict precisely how many Subcision treatments will be needed for any given defect. In general, Subcision is not a single treatment. The approximate number of Subcisions required to correct a specific depression will depend on such variables as the type of depression (Table 1), its location, the patient's

wound healing response, and the intensity of each treatment. Three to six visits suffice for the majority of cases of moderate wrinkling or scarring. Additional visits to treat other depressed sites and to re-treat partially elevated sites (or treat a hypertrophic site) are scheduled at intervals of about 1 month. Usually, 1 month between Subcisions allows sufficient time for bruising and swelling to resolve, and for connective tissue formation to plateau. Longer intervals delay the arrival at, but do not diminish the quality of, the end result.

During the first session, it is prudent to limit the number and intensity of Subcisions until the patient's response is established. On subsequent visits, more or less intensive Subcision may be performed, depending on the patient's previous response. Generally, deeply depressed sites require more intensive Subcision carried out over more treatment sessions.

Certain anatomical locations and possible areas of increased skin tension may have a greater propensity for fibroplasia;<sup>9</sup> therefore, these areas are treated less intensively, particularly during initial sessions. The



**Figure 4.** Treatment of wrinkles. A) Mimetic muscle fibers and fibrous septae from the SMAS insert directly into dermis. B) Needle maneuvered to release insertions from facial muscles and SMAS. C) Extravasated blood collects in Subcision wound. D) Wound heals with formation of new connective tissue, which further augments depressed areas.

periorbital, glabellar, labial commissure, and upper lip areas are among those that appear to have a greater predilection to hypertrophic reactions after Subcision.

Although scar correction is generally permanent, wrinkles may deepen or reform with time. Patients are

advised that follow-up treatments at 6–12-month intervals may be needed to correct either new or recurring areas of wrinkling.

## Cases

### Case 1

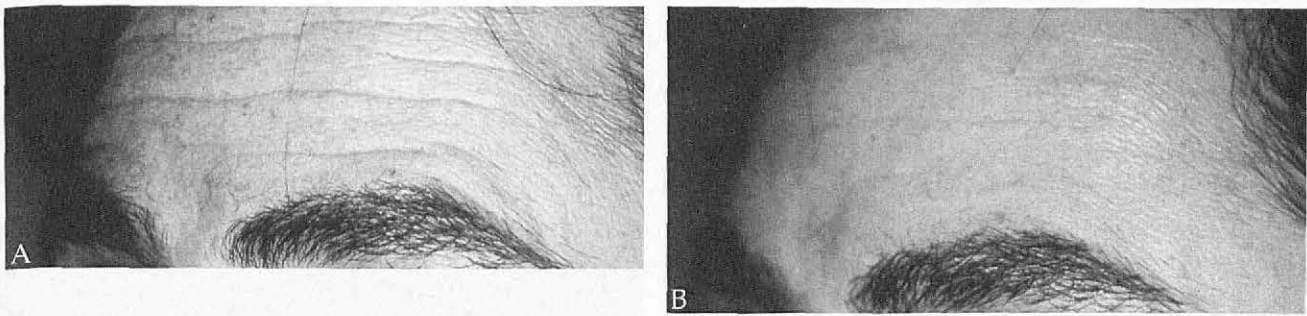
A 43-year-old man underwent Subcision of horizontal forehead wrinkles (Figure 5A). Three sessions were performed over a 3-month period. The areas were prepared as described. A 22-gauge, 1-inch needle was used. Other than expected bruising, there were no sequelae. Follow-up examination and photograph 4 months after the last session revealed satisfactory improvement (Figure 5B).

### Case 2

A 21-year-old woman presented with a depressed, bound-down, varicella scar, approximately 4 mm in

**Table 1.** Indications for Subcision

Depressed Distensile Scars
Acne
Traumatic
Surgical
Anetoderma
Depressed, Bound-Down Scars
Acne (excluding deep ice-pick scars)
Varicella
Traumatic
Surgical (eg, healed drain site)
Depressed Skin Grafts
Wrinkles
Depressed Contours (eg, Malar Groove)
Cellulite Dimples



**Figure 5.** Case 1. A) A 43-year-old man with forehead wrinkles before treatment. B) Follow-up examination 4 months after the last of three sessions of Subcision reveals satisfactory improvement.

diameter, on the left tip of her nose (Figure 6A). The area was prepared as described, and a 22-gauge needle was used to perform Subcision. Follow-up at 10 days showed one small comedo, which was expressed, and one incipient acneiform lesion, which was incised and drained. The photograph at 1 month post-Subcision shows nearly complete correction (Figure 6B).

#### Case 3

A 42-year-old woman presented with three bound-down scars, between 10 and 15 mm in length, on the lower abdomen (Figure 7A). The scars resulted from drains inserted at the time of abdominal surgery 5 years previously. The areas were treated with one session of Subcision using a 22-gauge, 1-inch needle. Follow-up at 10 weeks showed substantial correction (Figure 7B).

#### Indications

Subcision can correct a variety of depressions in the skin (see Table 1).

#### Contraindications

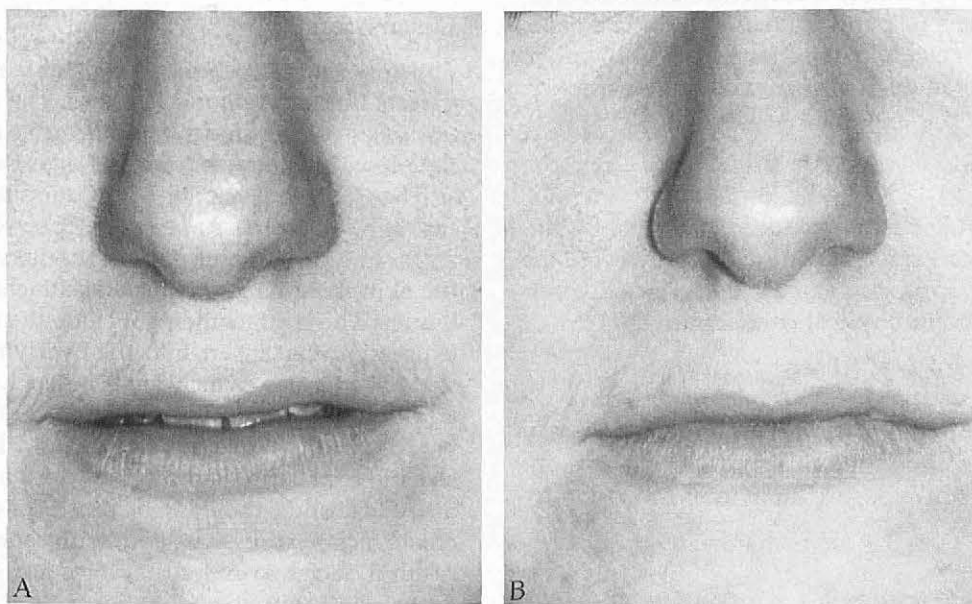##### Absolute

**ACTIVE INFECTION.** At or immediately adjacent to the site to be treated.

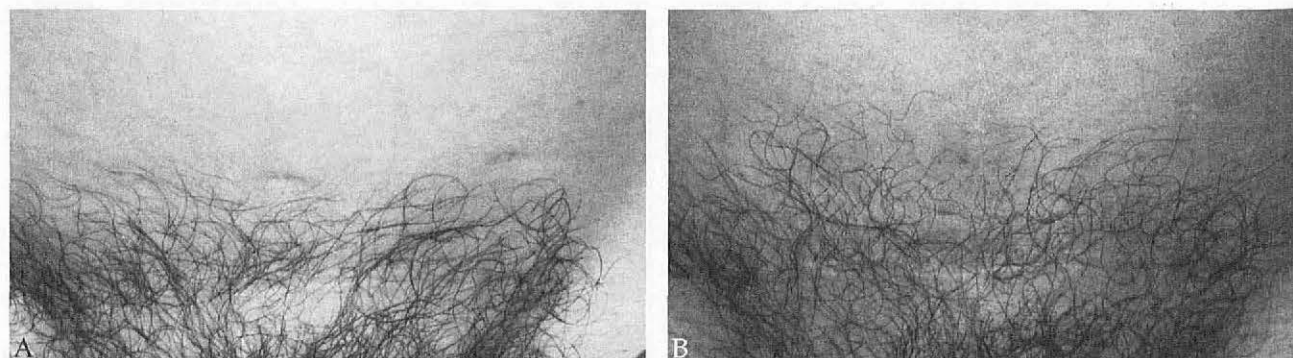
**DEEP, ICE PICK SCAR.** Ineffective; punch grafting is usually preferred.<sup>12</sup>

##### Relative

**DEPRESSED, ATROPHIC SCARS.** Although these may be successfully raised to normal skin level, appearance of



**Figure 6.** Case 2. A) A 21-year-old woman before Subcision to correct a varicella scar on left tip of nose. B) One month post-Subcision shows nearly complete correction.



**Figure 7.** Case 3. A) A 42-year-old woman with three bound-down scars of 5 years' duration, developed after healing of abdominal surgical drain sites. B) Follow-up examination at 10 weeks after one session of Subcision revealed satisfactory correction.

the surface will remain atrophic. Nevertheless, correction by Subcision may be preferable to excision or grafting.

#### **BLEEDING DIATHESIS.**

**HISTORY OF KELOID SCARRING AFTER TRAUMA OR SURGERY.** This sequela has not been observed. If either physician or patient is concerned about the possibility of keloid formation, a test site may be subcised.

### **Sequelae**

*Ecchymosis, Edema, Erythema and Tenderness*

#### *Infection*

Occasionally, localized acneiform, cyst-like lesions are observed. It is likely that subcutaneous disruption of the pilosebaceous apparatus is responsible for these lesions. These lesions respond to incision and drainage, intralesional corticosteroid injections (0.05–0.10 ml of triamcinolone acetonide, 1 mg/ml) and oral antibiotics, if needed.

#### *Altered Physical Consistency of Treated Sites*

The new connective tissue produced occasionally imparts a somewhat firmer skin texture. However, the improved overall appearance of the defect usually outweighs any change in physical consistency.

#### *Discoloration*

Temporary postinflammatory hyperpigmentation may appear in predisposed individuals. Patients are instructed to avoid sun exposure for at least 1 month after Subcision.

#### *Suboptimal Response*

Partial elevation of the defect is a common occurrence after a single Subcision. Prior to treatment, patients are

advised that multiple sessions are usually required to correct a specific defect.

#### *Excess Response*

In approximately 5–10% of cases, more fibroplasia than desired develops, and an elevated or hypertrophic response results, about 2–4 weeks postoperatively. These elevations usually have normal skin surface markings, in contrast to hypertrophic scars that appear after scalpel surgery. They respond favorably to intralesional corticosteroid injections (0.05–0.10 ml of triamcinolone acetonide, 1–5 mg/ml).

#### *Keloid Scarring*

See relative contraindications above.

### **Discussion**

The authors propose that Subcision corrects depressed defects through two mechanisms. The first is the surgical act of cutting under and releasing the tethered site; the second is new connective tissue formation.

The first mechanism is exemplified by cutting through the scar tissue under depressed, bound-down scars. In comparison, subcising facial wrinkles releases the skin from its fibromuscular attachments to deeper tissues. These attachments include the muscles of facial expression that insert into the overlying skin,<sup>10</sup> unlike skeletal muscles, which have no such attachments. In addition, numerous fibrous septae connect the SMAS (a broad, fibrous fascia enveloping and linking the muscles of facial expression) to the overlying dermis.<sup>10</sup> The SMAS transmits the mimetic muscular contractions that create facial expressions and, with repetition over time, result in facial wrinkles that form at right angles to the direction of muscle contraction.

The second proposed corrective mechanism is the creation of controlled trauma to promote new connective

tive tissue formation under the defect in the course of wound healing. After Subcision, wound healing begins with a vascular response, then subsequent phases of inflammation, granulation tissue formation, and fibroplasia. Surface reepithelialization is essentially absent, since Subcision only minimally involves the epidermis. Ground substance is produced, and collagen synthesis (peaking at 6-7 days) continue for 2-4 weeks.<sup>11</sup> Finally, long-term collagen remodeling occurs. Collagen production is possibly influenced by physical factors such as location and tension.<sup>9</sup> This, in part, may explain the occasional appearance of a localized hypertrophic reaction following Subcision (see sequelae, below). The degree of response to Subcision varies with each patient's response to wounding.

The effectiveness of Subcision demonstrates that the releasing action and the associated wound healing process can, in many instances, be harnessed to correct distensible and bound-down skin depressions without need of injectable augmentation agents.

Currently, there is no ideal injectable augmentation agent marketed in the United States. Marketed materials have one or more disadvantages including lack of persistence, risk of allergic reactions,<sup>6,13</sup> localized tissue necrosis,<sup>13</sup> and amaurosis.<sup>14,15</sup> Other procedures, such as lipoinjection and auto-collagen injection, require additional surgery at the harvesting sites.

It is possible that a majority of the long-term benefit derived from fibrin foam,<sup>16</sup> Fibrel,<sup>6</sup> or lipoinjection<sup>8</sup> after undermining may occur, not primarily as a result of the implant substance, which is eventually absorbed, but rather as a consequence of connective tissue formation resulting from the preinjection undermining to create a pocket for the implant.

The disadvantages of Subcision are bruising and, occasionally, hypertrophic reactions and acneiform lesions.

The advantages of Subcision are long-lasting scar correction and reasonably persistent correction of wrinkles. The materials required to perform Subcision are readily available and inexpensive. Furthermore, Subcision is not associated with the risk of allergic reactions or amaurosis.

In our experience, the combination of surgical release and spontaneous fibroplasia induced by Subcision is effective in treating cutaneous depressions such as scars, wrinkles, and cellulite. We find Subcision a valuable addition to the cutaneous surgeon's armamentarium of rehabilitative techniques.

## References

1. U.S. Trademark for "Subcision®." Registration No. 1,841,017. Date granted: 6/21/94.
2. Spangler AS. New treatment for pitted scars. *Arch Dermatol* 1957; 76:708-11.
3. Gottlieb S. GAP repair technique [Poster Exhibit]. Annual Meeting of the American Academy of Dermatology, Dallas, Texas, December 1977.
4. Multicenter Study. Treatment of depressed cutaneous scars with gelatin matrix implant. *J Am Acad Dermatol* 1987;16:1155-62.
5. Cohen IS. Fibrel®. *Semin Dermatol* 1987;6:228-37.
6. Millikan L, Banks K, Purkait B, Chung V. A 5-year safety and efficacy evaluation with Fibrel in the correction of cutaneous scars following one or two treatments. *J Dermatol Surg Oncol* 1991;17: 223-9.
7. Koranda FC. Treatment modalities in facial acne scars. In: JR Thomas and GR Holt, eds. *Facial Scars: Incision, Revision & Camouflage*. St. Louis: The C.V. Mosby Co., 1989:285.
8. Hambley RM, Carruthers JA. Microlipoinjection for the elevation of depressed, full-thickness skin grafts on the nose. *J Dermatol Surg Oncol* 1992;18:963-8.
9. Ketchum LD, Kelman Cohen I, Masters FW. Hypertrophic scars and keloids: a collective review. *Plast Reconstr Surg* 1974;53:140-54.
10. Salasche J, Bernstein G, Senkarik M. *Surgical Anatomy of the Skin*. Norwalk: Appleton & Lange, 1988:70,90.
11. Zitelli SA. Wound healing and wound dressings in dermatologic surgery. In: Roenigk RK, Roenigk, Jr HH, eds. *Dermatologic Surgery: Principles and Practice*. New York: Marcel Dekker, 1989:98-101.
12. Orentreich D. Punch grafting. In: Moy RL, Lask G, eds. *Principles and Techniques of Dermatologic Surgery*. McGraw-Hill, In press.
13. Hanke CW, Higley HR, Jolivet DM, Swanson NA, Stegman SJ. Abscess formation and local necrosis after treatment with Zyderm® or Zyplast® collagen implant. *J Am Acad Dermatol* 1991; 25:319-26.
14. Teimourian B. Blindness following fat injections [Letter]. *Plast Reconstr Surg* 1988;82:361.
15. Zyplast® Implant Physician Package Insert. Collagen Corporation, Palo Alto, CA. ©1985, 1987.
16. Spangler AS. Treatment of depressed scars with fibrin foam: seventeen years of experience. *J Dermatol Surg Oncol* 1975;1:65-9.