

Can Thermal Lasers Promote Skin Wound Healing?

Alexandre Capon and Serge Mordon

Lille University Hospital, Lille, France

Abstract

Lasers are now widely used for treating numerous cutaneous lesions, for scar revision (hypertrophic and keloid scars), for tissue welding, and for skin resurfacing and remodeling (wrinkle removal). In these procedures lasers are used to generate heat. The modulation of the effect (volatilization, coagulation, hyperthermia) of the laser is obtained by using different wavelengths and laser parameters.

The heat source obtained by conversion of light into heat can be very superficial, yet intense, if the laser light is well absorbed (far-infrared: CO₂ or Erbium: Yttrium Aluminum Garnet [Er:YAG] lasers), or it can be much deeper and less intense if the laser light is less absorbed by the skin (visible or near-infrared). Lasers transfer energy, in the form of heat, to surrounding tissues and, regardless of the laser used, a 45–50°C temperature gradient will be obtained in the surrounding skin.

If a wound healing process exists, it is a result of live cells reacting to this low temperature increase. The generated supraphysiologic level of heat is able to induce a heat shock response (HSR), which can be defined as the temporary changes in cellular metabolism. These changes are rapid and transient, and are characterized by the production of a small family of proteins termed the heat shock proteins (HSP). Recent experimental studies have clearly demonstrated that HSP 70, which is over-expressed following laser irradiation, could play a role with a coordinated expression of other growth factors such as transforming growth factor (TGF)- β . TGF- β is known to be a key element in the inflammatory response and the fibrogenic process. In this process, the fibroblasts are the key cells since they produce collagen and extracellular matrix.

In conclusion, the analysis of the literature, and the fundamental considerations concerning the healing process when using thermal lasers, are in favor of a modification of the growth factors synthesis after laser irradiation, induced by an HSR. An extensive review of the different techniques and several clinical studies confirm that thermal lasers could effectively promote skin wound healing, if they are used in a controlled manner.

Laser, the ‘mysterious’ light, has always fascinated people. From destruction to regeneration, science, literature, and cinema have explored the many uses of the laser. Early on, medical scientists were interested in the interaction of this light with living tissues. Almost immediately after its invention, scientists used lasers to cut or volatilize the skin.^[1-4] Volatilization is now widely used for treating numerous cutaneous lesions, from congenital nevus to malign tumors, and pathologic scars, such as keloids and hypertrophic scars.^[2-5] Laser can also be used for tissue welding of skin, microvessels, biliary and urinary ducts, and intestinal walls. In this particular application, the thermal action of the laser plays an important role and needs to be accurately controlled since the light must induce collagen bonds strong enough to support moderate tensions.^[6,7]

The last five years have been marked by important developments in skin resurfacing techniques, with the so-called ‘remod-

eling’ technique being of particular interest. Lasers are used for tissue volatilization (ablative technique) and for heating and thermal diffusion in skin resurfacing and tissue welding. After the acute phase of laser administration, the wound healing process associated with this treatment becomes apparent.^[8] The course of the wound healing after heating is a complicated function of the spatial time/temperature profile.

This paper aims to cover the different roles of thermal lasers in manipulating skin tissue, with a specific focus on their consequences on wound healing. The common aspects and special features may allow us to find an answer to the question, “Can thermal lasers promote skin wound healing?” Although the ‘low energy lasers’, usually termed as low level laser therapy (LLLT), were also proposed as an alternative to improve wound healing, they will be not considered in the paper, since the action of LLLT is based on the absence of temperature change in the tissue.^[9]

1. Thermal Action of Lasers: the Heat Shock Response

The basic tissue reaction to a laser is primarily wavelength dependent, as the wavelength of a laser beam determines the absorption mechanism and the depth of penetration (figure 1). The visible light lasers are all pigment-absorbed, the particular pigment (or chromophore) depending on the color (or wavelength) of the laser beam. Near infrared energy, such as the Neodymium:Yttrium Aluminum Garnet (Nd:YAG) at 1.06 μm , has little pigment specificity, while the 10.6 μm of the CO₂ laser is almost totally absorbed by water.^[9] In addition, the beam parameters (beam size [cm], pulse duration [s], power [W] and, consequently, fluence [J/cm²]) play a very important part in determining the final result.

When considering the laser thermal action, besides the proper selection of the wavelength in order to illuminate a given volume of tissue, the pulse duration determines the heat source generated in the tissue since the heat diffusion process leads to temperature gradients within it. When compared with other heat sources (microwaves or ultrasound), thermal heat diffusion induced by lasers is highly predictable and reproducible. In a recent paper, Reinisch clearly demonstrated that a 'scatter-limited' model was simple and efficient in calculating light and heat distribution inside the skin.^[11] The final result (or injury) can be quantified by the tra-

ditional damage measure, Ω , which is dependent on both temperature and time.^[12]

The landmark work of Moritz and Henriques clearly demonstrated that when using a thermal source, injury is heat induced, not solely temperature induced. For example, while complete and irreversible injury always occurred following exposure to 49°C for 9 minutes, injury did not occur following exposure to 49°C for 7 minutes.^[13] Consequently, non-lethal tissue effects can be obtained at high temperatures provided the heat source is maintained for a period of time less than that required to cause cell death. This generated supraphysiologic level of heat is able to induce a heat shock response (HSR). HSR can be defined as temporary changes in cellular metabolism. These changes are rapid and transient, and are characterized by the production of a small family of proteins termed the heat shock proteins (HSPs). HSP has become the paradigm par excellence for the investigation of how the metabolic activities of cells are controlled through the regulation of gene expression.^[14] Figure 2 illustrates the logarithmic relationship between duration and temperature for an equivalent HSP expression. Moreover, it is now well accepted that the HSP hyperexpression is not only a witness of the biological action of the heat generation, but also a part of the mechanism of the therapeutic action of thermal lasers. In ophthalmology, for example, through the use of a diode laser for transpupillary thermotherapy of the chorioretinal tissue (with a 50°C temperature elevation for 1 minute), an overexpression of HSP 70 has been obtained.^[15,16] Similarly, HSP hyperexpression has been also detected when using a laser on skin for a few seconds following 53°C temperature elevation.^[17]

To summarize, if thermal lasers are able to cut, vaporize, or coagulate tissue, they are able to induce a HSR. In most cases, when heat diffusion takes place inside the irradiated tissue, a supraphysiologic heated zone around the impact and denatured zone is created, and an HSR is induced (figure 3). The HSR could induce temporary changes in cellular metabolism and could be responsible for the release and production of growth factors and increase the rate of cell proliferation. This particular aspect will be discussed in section 4.

2. Incisional Scars

From the beginning of the 1970s, the CO₂ laser was used to create tissue incisions and particularly, cutaneous incisions.^[25] Numerous studies^[26-35] attempted to compare wound healing after laser incision and after classical blade incision. Most of the reports agree on two particular points: lasers allow more precise incisions, and lasers ensure immediate coagulation of the edges, decreasing consequent blood loss.^[26-28]

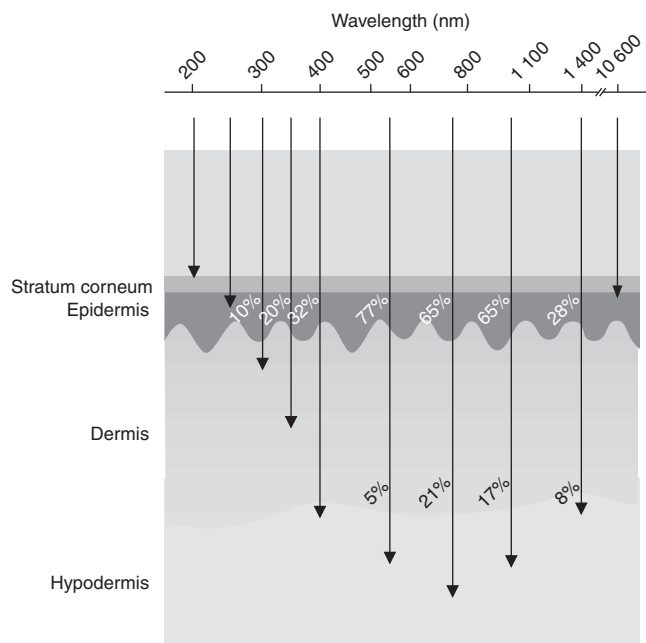


Fig. 1. Penetration depth of light (%) into skin for different wavelengths.^[10]

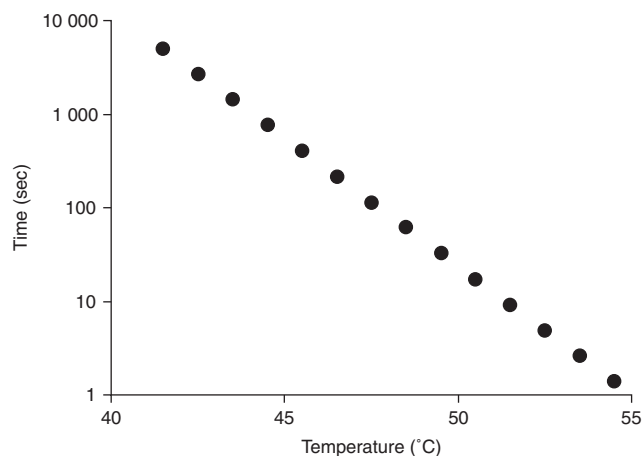


Fig. 2. Logarithmic relationship between duration and temperature for the induction of a heat shock response.^[12,14,16,18-24]

However, lasers are also associated with volatilization, and incision is induced by tissue heating, which diffuses and leads to collateral thermal damage. This is the reason why most of the studies reported slower healing and weaker tensile strength within the first days or weeks.^[26,27,29-31] Only Finsterbush and colleagues^[32] reported an increased tensile strength of the laser incised wounds, although, more importantly, a necrosis and inflammatory reaction was observed. Finally, many authors agree in their findings that there is no advantage to CO₂ or Nd:YAG laser incision; wounds healed differently but the resulting appearance was the same.^[28,33-35]

In Reid's opinion,^[36] the lack of difference in outcome between lasers and classical blade incision was a result of poor laser technique by the surgeons. Reid suggested the surgeons did not abide by the basic dosimetry rules of laser use, and in his opinion, if these rules were strictly adhered to, laser-induced wounds would heal faster and would have a much better cosmetic aspect. Reid's opinion is supported by authors reporting the benefits of using laser to perform blepharoplasty. In their hands, precise incisions, no bleeding, and almost no complications have been obtained.^[37,38]

In conclusion, using a laser to perform cutaneous incisions does not appear to be more advantageous or improve healing compared with other techniques, except maybe for eyelid surgery in the hands of well-trained surgeons.

3. Scar Revision

The scars can have different evolutions according to their origin (mechanism), their topography, or the patient. The hypertrophic phase begins approximately 3 weeks after the initial

trauma, reaches a maximum within 2 or 3 months, lasts about 2 months and then slowly decreases between 9–12 months. When this phase goes on beyond this time, the scar becomes pathologic and is called 'hypertrophic'. It remains erythematous, thick, and pruriginous but stays within the initial limits of the scar.

Keloid scars begin with an increasingly intense hypertrophy and then proliferate and exceed the initial limits of the scar. Spontaneous healing is not the rule and their treatment is unpredictable and difficult. In both keloid and hypertrophic scars there is increased vascularization as a consequence of an intense neoangiogenesis. The balance between collagen synthesis (fibroblasts stimulated by growth factors such as transforming growth factor [TGF]- β) and degradation (collagenases) is lost, and the rate of synthesis is increased.^[39] The usual treatments for these scars are unpredictable in efficacy, frequently leading to the maturation of hypertrophic scars; the recurrence of keloids is unfortunately common. These treatments include daily massages, pressotherapy with compressive clothes, silicone gel patch application, intra-keloid corticosteroid injection, intra-keloid surgical excision and radiotherapy.

Since the early 1980s, CO₂ lasers or Erbium:Yttrium Aluminum Garnet (Er:YAG) [ablative lasers] and 'vascular' flashlamp-pumped pulsed dye lasers have been proposed to complete this therapeutic armamentarium.^[39,40] For the treatment of hypertrophic scars, many authors use a flashlamp-pumped pulsed dye

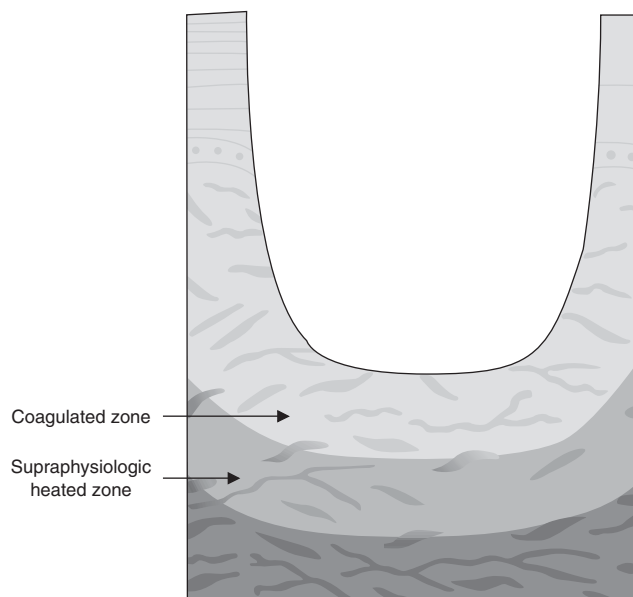


Fig. 3. When thermal lasers are used to cut, vaporize, or coagulate tissue, a supraphysiologic heated zone exists around the impact and denatured zone as a result of heat diffusion, inducing a heat shock response.

laser. The laser acts directly on the cutaneous microcirculation of the scar without any damage to the dermis and epidermis.^[41-43]

The study performed by Reiken and colleagues confirms this effect. Human hypertrophic scars implanted on nude mice stop their growth after laser irradiation, as a result of the destruction of the microcirculation.^[44]

The numerous reports of Alster and colleagues have shown a clear improvement of hypertrophic and erythematous scars leading to whitening, a change in skin texture, and the return to an almost normal skin aspect.^[41,42,45-49] These effects could be explained by the modulation with the laser of the remodeling phase of wound healing.^[49] Alster and Handrick,^[47] in agreement with Gaston and colleagues' recommendation,^[50] have suggested laser therapy as a first-intention treatment for hypertrophic scars, due to the improvement in appearance and the prevention of degradation.

Thus, many authors have reported a significant improvement in hypertrophic scars after 585nm pulsed dye laser treatment.^[51,52] Shakespeare and colleagues even suggested the systematic use of lasers for breast reduction scars, limiting the hypertrophy and accelerating their maturation.^[53]

The treatment of keloids, due to their profusion, would need an ablative CO₂ or Er:YAG laser. Laser therapy would allow a decrease in the thickness through a form of 'dermabrasion'.^[54] However, few authors suggest this technique^[55] because the aggressive nature of the procedure can make the keloid process worse.^[43,49]

CO₂ and Er:YAG lasers are usually recommended for the treatment of atrophic acne scars, with improvement resulting from the resurfacing abilities of the laser.^[56-58] There have been studies published, however, that have been less enthusiastic about using lasers for the treatment of pathologic scars. Paquet and colleagues^[59] noted the absence of the modification of keloids treated with a pulse dye laser compared with controls. Wittenberg and colleagues^[60] reported positive effects of the 585nm laser on hypertrophic scars, but these effects were not better than those obtained with silicone gel patch.

In conclusion, vascular lasers appear to improve hypertrophic scars, while CO₂ and Er:YAG are efficient in treating atrophic acne scars.

4. Laser-Assisted Skin Closure

Laser-assisted wound closure techniques appeared 15 years ago with the work of Abergel and colleagues, who used a Nd:YAG 1.06 μ m laser.^[7] It was rapidly evident that welding of skin was difficult; however, the cosmetic aspect of the scar was improved and the wound healing process was generally accelerated. In fact,

in the first few days, the initial tensile strength of the wound was weak compared with conventional sutures.^[7,61-63]

The energy required to perform cutaneous welding requires a large temperature increase, at least 60°C for 1 second.^[64] This temperature is necessary in order to obtain collagen denaturation and the crosslinking of fibrils.^[61,62,65,66] Consequences of this high temperature are tissue coagulation and necrosis as a result of burning, which slow the wound healing process and adversely affect the cosmetic outcome.

In order to solve these problems, various improvements have been suggested, such as adding an exogenous substance to the wound before applying the laser. The aim of these changes was to improve the initial tensile strength of the wound and limit the thermal damage.

Three different approaches can be distinguished.

- The addition of a substance (egg albumin, human albumin, blood etc.) which coagulates as a result of the rise in temperature, allowing 'soldering' and better tensile strength.^[67,68]
- The addition of a substance (e.g. indocyanine green) that displays a huge absorption for the wavelength emitted by the laser (e.g. diode 800nm). The conversion of the light into heat is confined to the zone where this substance is present, in this particular case the dermis.^[69]
- The combination of tissue welding optimized by one of the preceding methods with the addition of a growth factor to accelerate wound healing, such as TGF- β 1.^[70] The results obtained with this approach are interesting as the tensile strength and the cosmetic aspect are both improved.

The addition of exogenous substances to the wound is expensive, however, and the application would make the surgical procedure more laborious.^[69-75] The quantity of substance is also difficult to control and to standardize. In the future, this could be improved by using biodegradable indocyanine green-doped liquid albumin solder polymer film for reinforcement of laser-assisted incision closure.^[76-78]

It is worth noting that no clinical studies have been published yet that confirm the value of these 'soldering techniques' for either the surgical procedure or for wound healing.

More recently, an original skin closure technique assisted with a laser alone, without any additives, was developed by Capon and colleagues.^[18,19] Using a diode laser, an experimental study on hairless rats showed both accelerated healing, and an improvement of the cosmetic appearance of the scar after skin incision, leading to 'scarless healing'. In this application, the laser irradiation led to a moderate increase in tissue temperature (<50°C), insufficient to create a thermal damage, but high enough to activate HSP 70. HSP 70 are chaperone proteins that play a large role in the inflammatory reaction process and wound healing.^[17] The results observed in this experimental study showed that the healing pro-

cess occurs with regeneration (in opposition to repair), a phenomenon seen in fetal wound healing. Fetal wound healing is unique and differs from postnatal healing in that fetal skin wounds heal rapidly without scar formation. Interestingly, some authors have also reported that predominant expression of TGF- β 3, compared with TGF- β 1 and TGF- β 2, induces scarless healing.^[79,80]

Scarless healing is defined by collagen fiber-bundle deposition in a basket-weave pattern indistinguishable from the pattern of unwounded dermis.^[81] Models developed by Dallon and colleagues^[82] have suggested that the fundamental reason for the structural differences between scar and normal tissue is not the transition between fibrin and collagen matrices, or biochemical differences in the wound region, but simply that fibroblasts and/or myofibroblasts establish an alignment pattern as they migrate into the wound from the periphery. The cells enter the wound from adjacent dermis and the subcutaneous fascia. The most significant difference between normal tissue and scar tissue seems to be the orientation of the fibrous matrix.

The cutaneous wound repair process is extensively described in the literature. Fibroblast accumulation in a cutaneous wound requires phenotypic modulation of fibroblasts. In response to injury, resident fibroblasts in the surrounding tissue proliferate for the first 3 days and then, at day 4, migrate into the wounded site. Once within the wound, the fibroblasts produce type I procollagen as well as other matrix molecules and deposit these extracellular matrix molecules in the local milieu. By day 7, an abundant extracellular matrix has accumulated and fibroblasts switch to myofibroblast phenotypes replete with actin bundles along the cytoplasmic face of the plasma membrane. Wound contraction occurs as these myofibroblasts gather in the wound extracellular matrix by extending pseudopodia, attaching to extracellular matrix molecules, such as fibronectin and collagen, then retracting the pseudopodia. Once these processes have been accomplished, the fibroblasts appear to undergo apoptosis. Therefore, during cutaneous wound repair, fibroblasts appear to progress through four phenotypes:

- proliferation;
- migrating;
- synthesizing extra-cellular matrix molecules;
- expressing thick actin bundles as myofibroblasts.^[83]

Myofibroblasts could be considered to be terminally differentiated cells. The process of myofibroblast differentiation ends with the death of these cells.^[84] There are currently two main theories postulated to explain how fibroblasts may generate and transmit the force necessary to facilitate wound contraction; the cell traction (fibroblast theory)^[85] and the cell contraction (myofibroblast theory).^[86]

The fibroblast theory suggests that fibroblasts act as the agents of wound closure by exerting 'tread-like traction forces' on the extracellular matrix fibers to which they are attached, the process being analogous to the traction forces exerted by wheels on a surface. Such traction forces are shearing forces tangential to the cell surface, generated during cell elongation and spreading.^[87] This theory proposes that fibroblasts neither shorten in length nor act in a coordinated multicellular manner, but rather that the traction forces of many individual fibroblasts are responsible for wound contraction.^[88]

The myofibroblast theory suggests that these cells are responsible for the process of wound contraction, i.e. the movement of peripherally located parallel smooth muscle actin bundles contracting the myofibroblast in a smooth muscle-like fashion. The myofibroblast displays many cell-to-cell and cell-to-matrix contacts, the cells being linked together by desmosomes and gap junctions.^[89] The intracytoplasmic filaments of actin and vinculin form co-linear assemblies, each termed a fibronexus,^[90] with extracellular matrix fibrils of fibronectin and types I and III collagen via α 2 β 1 integrin receptors.^[90] These contacts provide a means by which cellular contraction pulls collagen fibrils toward the body of the myofibroblast,^[91] causing a reduction in granulation tissue area. The myofibroblast theory proposes that the coordinated contraction (cellular shortening) of many myofibroblasts, synchronized with the help of gap junctions, generates the force necessary for wound contraction.^[92] Not only the quantity of myofibroblasts, but the ratio of myofibroblasts to total cells, seems to play a key role over the time course of contraction.^[93]

Wound contraction may be brought about by a combination of these two theories. It is possible that the wound matrix is initially remodeled by the process of fibroblast traction, which is subsequently superseded by the contractile activity of myofibroblastic cells, as traction is known to proceed initially without myofibroblast cells.^[94]

An entirely different role for myofibroblasts in wound healing has been hypothesized by Ehrlich and Rajaratnam.^[85] The hypothesis is based on localization studies of myofibroblasts in a noncontracting animal wound model and in fibroblast-populated collagen lattices (an *in vitro* model for wound contraction). Ehrlich and colleagues have proposed that the presence of myofibroblasts is not associated with contraction in these two systems, therefore, their role in wound healing may be unrelated to contraction and their abundance in the wound during contraction incidental. Ehrlich and colleagues^[95] have suggested that myofibroblasts may be involved in the resolution of fibroplasia and that these altered cells are in the process of leaving the wound environment.

The technique developed by Mordon and colleagues^[96] has clearly demonstrated that laser irradiation induces a rapid myofibroblastic induction in comparison with non-irradiated tissue. This inflammation process is also mediated by growth factors. Alterations in the normal growth factor profile, by adding neutralizing antibodies to TGF- β on incisional wounds, was shown to reduce both the inflammatory response, and scar formation, without reducing the tensile strength of the wound.^[79] In addition, TGF- β has been shown to induce the synthesis of HSP 70 in cultured chick embryo cells.^[97] This HSP 70 synthesis may be the result of an increase in the demand of molecular chaperoning by the cells during the proliferation process. Figure 4 and figure 5 summarize the cascade of the wound-healing process and the role of TGF- β 1, that can be induced by an elevation of temperature.^[98-104]

More recently, Shukla and colleagues^[105] pointed out the importance of the coordinate expression of growth factors and HSP during the wound-healing process. However, the ability of any single factor to enhance the multiple aspects of wound repair to produce a clinically significant outcome may be limited.^[106] Several studies have now clearly shown that wound repair is the result of temporally coordinated local expression of multiple families of growth factors and their receptors.^[107] Two studies performed by Shah and colleagues^[79,80] have demonstrated the links between TGF- β profile and scar aspect. Since an evident decrease of scarring is observed after laser heating of the skin, it could be hypothesized that TGF- β profile is then modified.

Moreover, this fact is confirmed by Dallon and colleagues' simulations designed to elucidate the role of TGF- β in scarring.^[82,108-110] In simulations where TGF- β 3 is added to the healing wound, there is an increased cell reorientation, but the other effects of

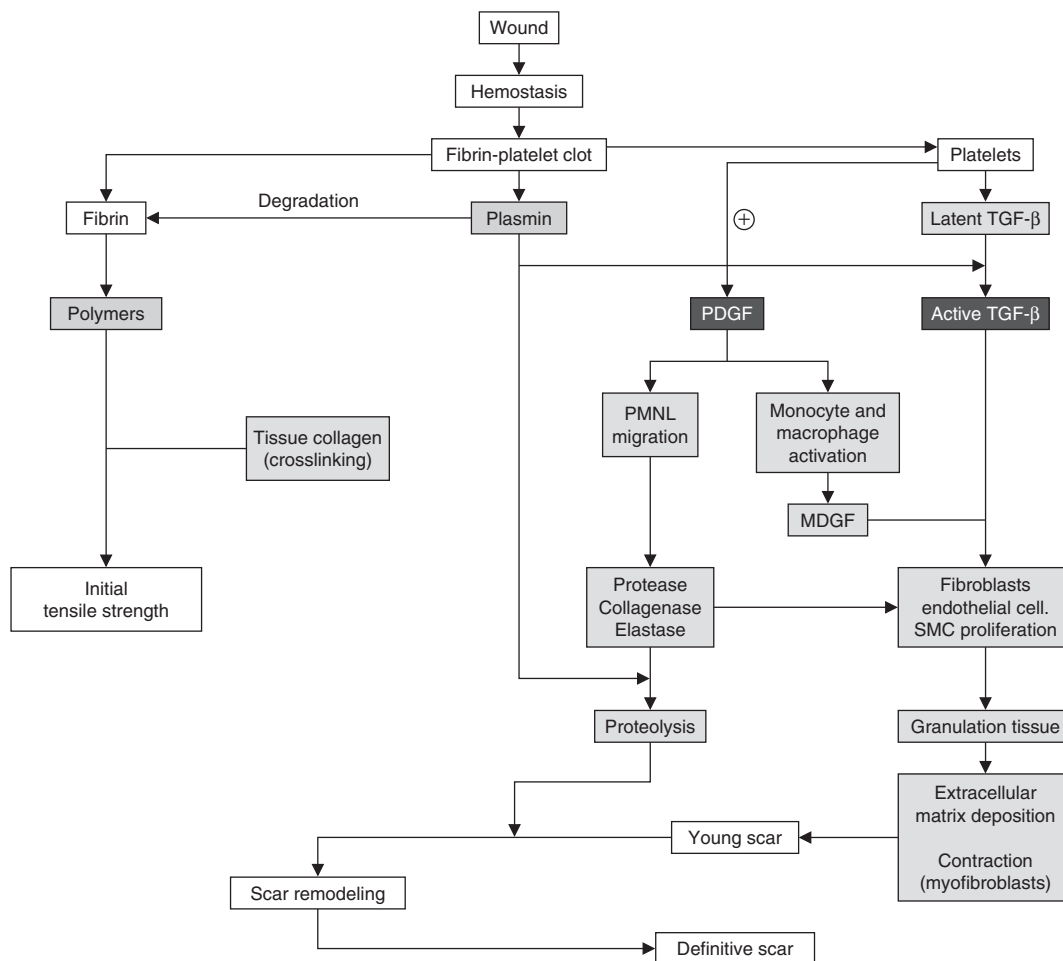


Fig. 4. Wound healing cascade.^[98,99] **MDGF** = macrophage-derived growth factor; **PDGF** = platelet-derived growth factor; **PMNL** = polymorphonuclear leukocyte; **SMC** = smooth muscle cells; **TGF- β** = transforming growth factor- β .

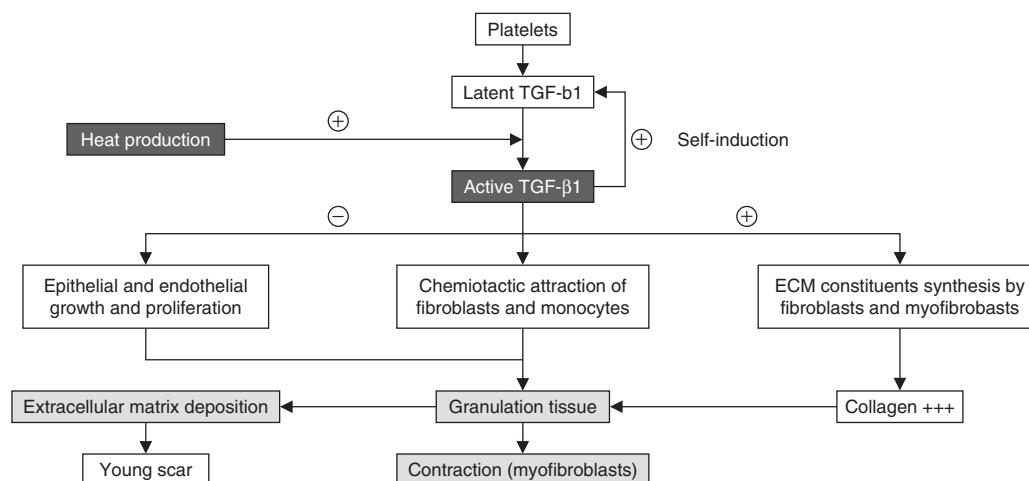


Fig. 5. Role and induction of transforming growth factor (TGF)- β 1 in the wound healing process. TGF- β 1 activation is induced by the heat shock response.^[99-104] ECM = extracellular matrix.

TGF- β (cell proliferation and speed, and collagen production) are retained. TGF- β 3 appears to be the key in the regulation of fiber alignment within scar tissue and hence, the improvement of scar aspect.

Since a modification of the temporally local expression of several growth factors is crucial, the final goal would be a manipulation of the adult wound to produce more fetal-like, scarless wound healing, as suggested by Whitby and Ferguson.^[111] It is evident that good control of the laser light, resulting in the induction of an HSR in the dermis could modify the inflammatory response and, consequently, the healing process. These preliminary observations deserve further study.

5. Resurfacing and Remodeling

Beginning in our 20s, the effects of aging start to become visible in the skin. Genetically programmed chronologic aging causes biochemical changes in collagen and elastin, the connective tissues that give skin its firmness and elasticity. As skin becomes less elastic, it also becomes drier. Underlying fat padding begins to disappear. With the loss of underlying support by fat padding and connective tissues, the skin begins to sag. It looks less supple, and wrinkles form. The skin may be itchy with increased dryness. A cut may heal more slowly.

Occurring simultaneously with genetically programmed aging, the process of photoaging may be taking place. Photoaging is the effect of chronic and excessive sun exposure on the skin. Cigarette smoking also contributes to aging effects by the biochemical changes it brings about in skin tissues. Photoaging in-

teracts with chronologic aging and may appear to hasten the process of chronologic aging. In fact, photoaging may be responsible for the majority of age-associated changes in the skin's appearance: mottled pigmentation, surface roughness, fine wrinkles that disappear when stretched, 'age' or 'liver' spots (lentigines) on the hands, and dilated blood vessels.

Laser-resurfacing techniques and, more recently, laser-remodeling techniques, have been proposed for removing the stigmata of skin aging. The aim of both of these laser techniques is to obtain healing on a regeneration mode leading to a *restitutio ad integrum*. However, important differences exist between resurfacing and remodeling.

Laser resurfacing is an alternative method to chemical peels and dermabrasion. It is very similar to a superficial burn and consequently is associated with similar adverse effects and complications.^[112-116]

Remodeling is a new procedure inducing controlled thermal damage which is spatially determined and which leads to a subsequent collagen remodeling while preserving the epidermis and avoiding the adverse effects observed after laser resurfacing.

5.1 Resurfacing

The term 'laser resurfacing' was proposed in 1989 by North American authors,^[117,118] to describe the superficial abrasion of the skin intended to correct various benign cutaneous lesions which did not exceed a few hundred microns in depth.^[119]

In laser resurfacing, a precise, thin, high-powered beam of laser energy/light removes the damaged outer layers of the skin

by vaporizing the upper layers at specific and controlled levels of penetration. The lower layers of the skin are stimulated to produce new collagen and as the new cells form during the healing process, a smoother, tighter, fresher looking skin is formed. The epidermis and the papillary dermis are the biologic targets to be reached. The water is the only shared chromophore in the epidermis (intracellular water) and the dermis (extracellular water), and CO₂ or Er:YAG lasers are used because their wavelengths are highly absorbed by water.^[120-135]

Biopsies performed before CO₂ resurfacing find a typical elastotic skin aspect. The dermis has lost its normal structure, replaced almost totally by an elastotic material deposit and only a thin band of normal collagen separates it from the epidermis. Biopsies performed 12 weeks after resurfacing show an important decrease in the elastotic dermis, and the appearance of a sub-epidermal neocollagen band called grenz zone.^[136] This neocollagen brings an indispensable support to the epidermis and fills the wrinkle.

Laser resurfacing has proven its efficacy, showing excellent results,^[137] but it requires a long recovery period, associated with adverse effects such as long-term erythema, prolonged skin discomfort and sensitiveness, high risk of postoperative scars, late-onset dyschromias, or inability to tan. Many patients scared by such prospects or too busy socially, are looking for a new technique which can improve their appearance without downtime.

5.2 Remodeling

The underlying principle of laser remodeling is to induce a controlled injury to the collagen in the dermis, while completely sparing the epidermis from damage. As dermal collagen heals and remodels under an undamaged outer layer, the skin tightens and smoothes, thus improving its appearance.

At the time of writing, there are two classes of lasers used for remodeling, visible light lasers and infrared lasers. Visible light lasers, including green and yellow light lasers adapted or modified from their original use, are used as treatments for vascular lesions. 532nm (green) and 585nm (yellow) light are strongly absorbed by oxyhemoglobin and melanin in the epidermis and upper dermis and, in theory, the heating effect in these skin layers triggers the release of various growth factors that stimulate collagen remodeling and tightening.^[138,139] Biochemical analyses^[139] performed before and 72 hours after the treatment from the interstitial liquid of suction bubbles realized on the forearm, show an increased rate of production of peptide of procollagen type III (about 84.5%; $p = 0.011$) after laser administration. Histology, performed in another study,^[138] showed a decrease in the accumulation of degenerated elastotic fibers in the dermis, the

presence of activated fibroblasts 12 weeks after the treatment, a thickening of the superficial collagen band, and an increase of the mucin quantity in the superficial dermis.

Infrared lasers, primarily at 1320nm, 1450nm, and 1540nm, produce invisible light that is absorbed primarily by water, and heats the latter in both the epidermis and dermis. These lasers use aggressive skin cooling to limit the heating effect to the dermis, creating a controlled injury to the dermal collagen, with subsequent remodeling and tightening.^[140-147]

Histological study of biopsies before remodeling has found an important dermal elastotic reorganization. Fournier and colleagues^[147] have observed, after remodeling with 1.54μm laser, a progressive disappearance of the elastotic accumulation from the first week, and a thickening of the superficial collagen band with horizontalization of the collagen fibers 2 months after a single treatment.

Goldberg^[148] has reported histologic evidence of new upper papillary dermal collagen formation in all his postauricular biopsies of ten patients, 6 months after four treatments administered within a 4-month period, with a 1320nm Nd:YAG laser. This improvement was only visible in 6 of the 10 patients 1 month after the fourth treatment, which is supportive of a long delay being necessary before there is a clear histologic improvement.

The mechanisms involved in the creation of the minimal inflammatory reaction remain poorly understood but HSPs appear to play a dominant role in the fibroblastic boost,^[17,149] as described in the previous paragraph.

6. Conclusion

This review of the literature clearly demonstrates that it is possible to give a positive answer to the question, "Can thermal laser promote skin wound healing?" For incisional scars, scar revision, laser-assisted skin closure, laser resurfacing, and laser remodeling, the laser seems to play an indisputable role in the wound-healing process. For those techniques, lasers are used to generate heat. The modulation of the effects (volatilization, coagulation, hyperthermia) is obtained by using different wavelengths and laser parameters. The heat source obtained by conversion of light into heat can be very superficial and intense if the laser light is well absorbed (far-infrared: CO₂ or Er:YAG lasers), or it can be much deeper and less intense if the laser light is less absorbed by the skin (visible or near-infrared). Lasers transfer energy, in the form of heat, to surrounding tissues and, regardless of which laser is used, a 45–50°C temperature gradient will be obtained in the surrounding skin. If a wound healing process exists, it must be a result of living cells reacting to the temperature increase. This generated supraphysiologic level of heat is able to

induce a HSR, which can be defined as the temporary changes in cellular metabolism. These changes are rapid, transient, and characterized by the production of a small family of proteins termed the HSPs.

In this context, recent experimental studies have clearly demonstrated that HSP 70, which is over-expressed following laser irradiation, could play a role with a coordinate expression of other growth factors such as TGF- β . TGF- β is known to be a key element in the inflammatory response and the fibrogenic process. The basic mechanisms remain poorly understood but fundamental considerations concerning the healing process are in favor of a modification of the growth factors synthesis after laser irradiation. For Reid,^[36] poor laser technique can lead to undesirable effects, and often to the absence of effects. We hope that, in the near future, a better knowledge of the biological rules and the mechanisms of laser on the wound-healing process will contribute to a good tool for surgeons for the improvement of skin wound healing.

Acknowledgments

The authors have no conflicts of interest directly relevant to the content of this review. The authors thank the following institutions for their support: INSERM (French National Institute of Health and Medical Research), Lille University Hospital, and University of Lille 2.

References

- Goldman L, Rockwell Jr RJ. Laser systems and their applications in medicine and biology. *Adv Biomed Eng Med Phys* 1968; 1: 317-82
- Ehrlich HP, Kelley SF. Hypertrophic scar: an interruption in the remodeling of repair: a laser Doppler blood flow study. *Plast Reconstr Surg* 1992; 90 (6): 993-8
- Alster TS, Williams CM. Treatment of keloid sternotomy scars with 585 nm flashlamp-pumped pulsed-dye laser. *Lancet* 1995; 345 (8959): 1198-200
- Sherman R, Rosenfeld H. Experience with the Nd:YAG laser in the treatment of keloid scars. *Ann Plast Surg* 1988; 21 (3): 231-5
- Alster TS, West TB. Resurfacing of atrophic facial acne scars with a high-energy, pulsed carbon dioxide laser. *Dermatol Surg* 1996; 22 (2): 151-4
- Abergel RP, Lyons R, Dwyer R, et al. Use of lasers for closure of cutaneous wounds: experience with Nd:YAG, argon and CO₂ lasers. *J Dermatol Surg Oncol* 1986; 12 (11): 1181-5
- Abergel RP, Lyons RF, White RA, et al. Skin closure by Nd:YAG laser welding. *J Am Acad Dermatol* 1986; 14 (5): 810-4
- Spadoni D, Cain CL. Facial resurfacing: using the carbon dioxide laser. *AORN J* 1989; 50 (5): 1007, 1009-13
- Oshiro T, Calderhead RG. Laser dermatology: state of the art. In: Waidelich WR, editor. *Laser optoelectronics in medicine*. Heidelberg: Springer-Verlag, 1988: 513-21
- Sliney D, Wolbarsht M. Optical radiation hazards to the skin, in safety with lasers and other optical sources. New York: Plenum Press, 1980: 161-85
- Reinisch L. Scatter-limited phototherapy: a model for laser treatment of skin. *Lasers Surg Med* 2002; 30 (5): 381-8
- Pearce J, Thomsen S. Rate process analysis of thermal damage. In: Gemert AJWMJCV, editor. *Optical-thermal response of laser irradiated tissue*. New York: Plenum Press, 1995: 561-606
- Moritz A, Henriques F. Studies of thermal injury II: the relative importance of time and surface temperature in the caucasian of cutaneous burns. *Am J Pathol* 1947; 23: 695-720
- Perdizet G. The heat shock response. In: Perdizet GA, editor. *Heat shock response and organ preservation: models of stress conditioning*. Austin (TX): RG Landes Company, 1997: 27-69
- Mainster MA, Reichel E. Transpupillary thermotherapy for age-related macular degeneration: long-pulse photocoagulation, apoptosis, and heat shock proteins. *Ophthalmic Surg Lasers* 2000; 31 (5): 359-73
- Desmettre T, Maurage CA, Mordon S. Heat shock protein hyperexpression on chorioretinal layers after transpupillary thermotherapy. *Invest Ophthalmol Vis Sci* 2001; 42 (12): 2976-80
- Souil E, Capon A, Mordon S, et al. Treatment with 815-nm diode laser induces long-lasting expression of 72-kDa heat shock protein in normal rat skin. *Br J Dermatol* 2001; 144 (2): 260-6
- Capon A, Mitchell VA, Sumian C, et al. Laser-assisted skin closure (LASC) using a 815-nm diode laser system: determination of an optimal dose to accelerate wound healing. In: Bown S, editor. *Thermal therapy, laser welding, and tissue interaction*. Bellingham (WA): SPIE, 1998: 1-12
- Capon A, Souil E, Gauthier B, et al. Laser assisted skin closure (LASC) by using a 815-nm diode-laser system accelerates and improves wound healing. *Lasers Surg Med* 2001; 28 (2): 168-75
- Cain CP, Welch AJ. Measured and predicted laser-induced temperature rises in the rabbit fundus. *Invest Ophthalmol* 1974; 13 (1): 60-70
- Priebe LA, Cain CP, Welch AJ. Temperature rise required for production of minimal lesions in the Macaca mulatta retina. *Am J Ophthalmol* 1975; 79 (3): 405-13
- Law MP. Induced thermal resistance in the mouse ear: the relationship between heating time and temperature. *Int J Radiat Biol Relat Stud Phys Chem Med* 1979; 35 (5): 481-5
- Law MP. The induction of thermal resistance in the ear of the mouse by heating at temperatures ranging from 41.5 to 45.5 degrees C. *Radiat Res* 1981; 85 (1): 126-34
- Rice LC, Urano M, Maher J. The kinetics of thermotolerance in the mouse foot. *Radiat Res* 1982; 89 (2): 291-7
- Hall RR. The healing of tissues incised by a carbon-dioxide laser. *Br J Surg* 1971; 58 (3): 222-5
- Durante EJ, Kriek NP. Clinical and histological comparison of tissue damage and healing following incisions with the CO₂-laser and stainless steel surgical blade in dogs. *J S Afr Vet Assoc* 1993; 64 (3): 116-20
- Molgat YM, Pollack SV, Hurwitz JJ, et al. Comparative study of wound healing in porcine skin with CO₂ laser and other surgical modalities: preliminary findings. *Int J Dermatol* 1995; 34 (1): 42-7
- Pearlman NW, Stiegmann GV, Vance V, et al. A prospective study of incisional time, blood loss, pain, and healing with carbon dioxide laser, scalpel, and electrosurgery. *Arch Surg* 1991; 126 (8): 1018-20
- Arashiro DS, Rapley JW, Cobb CM, et al. Histologic evaluation of porcine skin incisions produced by CO₂ laser, electrosurgery, and scalpel. *Int J Periodontics Restorative Dent* 1996; 16 (5): 479-91
- Buell BR, Schuller DE. Comparison of tensile strength in CO₂ laser and scalpel skin incisions. *Arch Otolaryngol* 1983; 109 (7): 465-7
- Taylor DL, Schafer SA, Nordquist R, et al. Comparison of a high power diode laser with the Nd:YAG laser using in situ wound strength analysis of healing cutaneous incisions. *Lasers Surg Med* 1997; 21 (3): 248-54
- Finsterbush A, Rouso M, Ashur H. Healing and tensile strength of CO₂ laser incisions and scalpel wounds in rabbits. *Plast Reconstr Surg* 1982; 70 (3): 360-2
- Norris CW, Mullarky MB. Experimental skin incision made with the carbon dioxide laser. *Laryngoscope* 1982; 92 (4): 416-9
- Nygaard IE, Squatrito RC. Abdominal incisions from creation to closure. *Obstet Gynecol Surv* 1996; 51 (7): 429-36
- Romanos GE, Pelekanos S, Strub JR. A comparative histological study of wound healing following Nd:YAG laser with different energy parameters and conventional surgical incision in rat skin. *J Clin Laser Med Surg* 1995; 13 (1): 11-6
- Reid R. Physical and surgical principles governing carbon dioxide laser surgery on the skin. *Dermatol Clin* 1991; 9 (2): 297-316

37. Brychta P, Francu M, Koupil J, et al. Our experience with transconjunctival, laser-assisted lower blepharoplasty. *Acta Chir Plast* 2000; 42 (4): 118-23
38. Seckel BR, Kovanda CJ, Cetrulo Jr CL, et al. Laser blepharoplasty with transconjunctival orbicularis muscle/septum tightening and periocular skin resurfacing: a safe and advantageous technique. *Plast Reconstr Surg* 2000; 106 (5): 1127-41
39. Henderson D, Cromwell T, Mes L. Argon and carbon dioxide laser treatment of hypertrophic and keloid scars. *Lasers Surg Med* 1984; 3: 271-7
40. Brown Jr LA, Pierce HE. Keloids: scar revision. *J Dermatol Surg Oncol* 1986; 12 (1): 51-6
41. Alster T. Pulsed dye laser gives hope to scar patients. *Clin Laser Mon* 1993; 11 (10): 155-6
42. Alster TS. Improvement of erythematous and hypertrophic scars by the 585-nm flashlamp-pumped pulsed dye laser. *Ann Plast Surg* 1994; 32 (2): 186-90
43. Berman B, Flores F. The treatment of hypertrophic scars and keloids. *Eur J Dermatol* 1998; 8 (8): 591-5
44. Reiken SR, Wolfort SF, Berthiaume F, et al. Control of hypertrophic scar growth using selective photothermolysis. *Lasers Surg Med* 1997; 21 (1): 7-12
45. Alster TS, Nanni CA. Pulsed dye laser treatment of hypertrophic burn scars. *Plast Reconstr Surg* 1998; 102 (6): 2190-5
46. Alster TS, McMeekin TO. Improvement of facial acne scars by the 585 nm flashlamp-pumped pulsed dye laser. *J Am Acad Dermatol* 1996; 35 (1): 79-81
47. Alster TS, Handrick C. Laser treatment of hypertrophic scars, keloids, and striae. *Semin Cutan Med Surg* 2000; 19 (4): 287-92
48. Alster TS, Bettencourt MS. Review of cutaneous lasers and their applications. *South Med J* 1998; 91 (9): 806-14
49. Alster TS. Laser treatment of hypertrophic scars, keloids, and striae. *Dermatol Clin* 1997; 15 (3): 419-29
50. Gaston P, Humzah MD, Quaba AA. The pulsed tuneable dye laser as an aid in the management of postburn scarring. *Burns* 1996; 22 (3): 203-5
51. Dierickx C, Goldman MP, Fitzpatrick RE. Laser treatment of erythematous/hypertrophic and pigmented scars in 26 patients. *Plast Reconstr Surg* 1995; 95 (1): 84-90
52. Goldman MP, Fitzpatrick RE. Laser treatment of scars. *Dermatol Surg* 1995; 21 (8): 685-7
53. Shakespeare PG, Tiernan E, Dewar AE, et al. Using the pulsed dye laser to influence scar formation after breast reduction surgery: a preliminary report. *Ann Plast Surg* 2000; 45 (4): 357-68
54. Nehal KS, Levine VJ, Ross B, et al. Comparison of high-energy pulsed carbon dioxide laser resurfacing and dermabrasion in the revision of surgical scars. *Dermatol Surg* 1998; 24 (6): 647-50
55. Bernstein LJ, Kauvar AN, Grossman MC, et al. Scar resurfacing with high-energy, short-pulsed and flashscanning carbon dioxide lasers. *Dermatol Surg* 1998; 24 (1): 101-7
56. Goodman GJ. Management of post-acne scarring: what are the options for treatment? *Am J Clin Dermatol* 2000; 1 (1): 3-17
57. Kwon SD, Kye YC. Treatment of scars with a pulsed Er:YAG laser. *J Cutan Laser Ther* 2000; 2 (1): 27-31
58. Mezzana P, Sonnino M, Madonna Terracina FS, et al. Treatment of atrophic scars with Er:YAG laser: our experience. *Acta Chir Plast* 2001; 43 (1): 26-8
59. Paquet P, Hermanns JF, Pierard GE. Effect of the 585 nm flashlamp-pumped pulsed dye laser for the treatment of keloids. *Dermatol Surg* 2001; 27 (2): 171-4
60. Wittenberg GP, Fabian BG, Bogomilsky JL, et al. Prospective, single-blind, randomized, controlled study to assess the efficacy of the 585-nm flashlamp-pumped pulsed-dye laser and silicone gel sheeting in hypertrophic scar treatment. *Arch Dermatol* 1999; 135 (9): 1049-55
61. Bass LS, Treat MR. Laser tissue welding: a comprehensive review of current and future clinical applications. *Lasers Surg Med* 1995; 17 (4): 315-49
62. Godlewski G, Prudhomme M, Tang J. Applications and mechanisms of laser tissue welding in 1995: review. In: Laffitte F, Hibst R, Reidenbach H-D, et al., editors. *Medical applications of lasers III*. Bellingham (WA): SPIE, 1996: 334-41
63. Garden JM, Robinson JK, Taute PM, et al. The low-output carbon dioxide laser for cutaneous wound closure of scalpel incisions: comparative tensile strength studies of the laser to the suture and staple for wound closure. *Lasers Surg Med* 1986; 6 (1): 67-71
64. Lele P. Local tumor hyperthermia in the 1990s. In: Bicher HI, McLaren IR, Pigliucci GM, editors. *Consensus on hyperthermia in the 1990s*. New York: Plenum Press, 1990: 37-46
65. Murray LW, Su L, Kopchok GE, et al. Crosslinking of extracellular matrix proteins: a preliminary report on a possible mechanism of argon laser welding. *Lasers Surg Med* 1989; 9 (5): 490-6
66. Tang J, Godlewski G, Rouy S, et al. Morphologic changes in collagen fibers after 830 nm diode laser welding. *Lasers Surg Med* 1997; 21 (5): 438-43
67. Poppas DP, Schlossberg SM, Richmond IL, et al. Laser welding in urethral surgery: improved results with a protein solder. *J Urol* 1988; 139 (2): 415-7
68. Wang S, Grubbs Jr PE, Basu S, et al. Effect of blood bonding on bursting strength of laser-assisted microvascular anastomoses. *Microsurgery* 1988; 9 (1): 10-3
69. DeCoste SD, Farinelli W, Flotte T, et al. Dye-enhanced laser welding for skin closure. *Lasers Surg Med* 1992; 12 (1): 25-32
70. Poppas DP, Massicotte JM, Stewart RB, et al. Human albumin solder supplemented with TGF-beta 1 accelerates healing following laser welded wound closure. *Lasers Surg Med* 1996; 19 (3): 360-8
71. Kayton ML, Libutti SK, Bessler M, et al. Comparison of laser-activated tissue solders and thrombin-activated cryoprecipitate for wound closure. In: Ed RRA, editor. *Laser surgery: advanced characterization, therapeutics, and systems IV*. Bellingham (WA): SPIE, 1994: 527-31
72. Chiarugi C, Martini L, Borgognoni L, et al. Technical improvements in diode-laser-assisted skin welding. In: Laffitte F, Hibst R, Reidenbach H-D, editors. *Medical applications of lasers III*. Bellingham (WA): SPIE, 1996: 407-11
73. Reali UM, Borgognoni L, Martini L, et al. Preliminary experiences on diode laser welding of skin. In: Bown SG, Escourrou J, Frank KH, et al., editors. *Medical applications of lasers II*. Bellingham (WA): SPIE, 1994: 211-5
74. Romanos GE, Pelekanos S, Strub JR. Effects of Nd:YAG laser on wound healing processes: clinical and immunohistochemical findings in rat skin. *Lasers Surg Med* 1995; 16 (4): 368-79
75. Wider TM, Libutti SK, Greenwald DP, et al. Skin closure with dye-enhanced laser welding and fibrinogen. *Plast Reconstr Surg* 1991; 88 (6): 1018-25
76. McNally KM, Sorg BS, Welch AJ. Novel solid protein solder designs for laser-assisted tissue repair. *Lasers Surg Med* 2000; 27 (2): 147-57
77. Hodges DE, McNally KM, Welch AJ. Surgical adhesives for laser-assisted wound closure. *J Biomed Opt* 2001; 6 (4): 427-31
78. Sorg BS, McNally KM, Welch AJ. Biodegradable polymer film reinforcement of an indocyanine green-doped liquid albumin solder for laser-assisted incision closure. *Lasers Surg Med* 2000; 27 (1): 73-81
79. Shah M, Foreman DM, Ferguson MW. Neutralising antibody to TGF-beta 1,2 reduces cutaneous scarring in adult rodents. *J Cell Sci* 1994; 107 (5): 1137-57
80. Shah M, Foreman DM, Ferguson MW. Neutralisation of TGF-beta 1 and TGF-beta 2 or exogenous addition of TGF-beta 3 to cutaneous rat wounds reduces scarring. *J Cell Sci* 1995; 108 (3): 985-1002
81. Scheid A, Wenger RH, Christina H, et al. Hypoxia-regulated gene expression in fetal wound regeneration and adult wound repair. *Pediatr Surg Int* 2000; 16 (4): 232-6
82. Dallon J, Sherratt J, Maini P, et al. Biological implications of a discrete mathematical model for collagen deposition and alignment in dermal wound repair. *IMA J Math Appl Med Biol* 2000; 17 (4): 379-93
83. Clark RA. Regulation of fibroplasia in cutaneous wound repair. *Am J Med Sci* 1993; 306 (1): 42-8
84. Desmouliere A, Badid C, Bochaton-Piallat ML, et al. Apoptosis during wound healing, fibrocontractive diseases and vascular wall injury. *Int J Biochem Cell Biol* 1997; 29 (1): 19-30
85. Ehrlich HP, Rajaratnam JB. Cell locomotion forces versus cell contraction forces for collagen lattice contraction: an in vitro model of wound contraction. *Tissue Cell* 1990; 22 (4): 407-17

86. Gabbiani G, Ryan GB, Majne G. Presence of modified fibroblasts in granulation tissue and their possible role in wound contraction. *Experientia* 1971; 27 (5): 549-50
87. Stopak D, Harris AK. Connective tissue morphogenesis by fibroblast traction I: tissue culture observations. *Dev Biol* 1982; 90 (2): 383-98
88. Ehrlich HP. Wound closure: evidence of cooperation between fibroblasts and collagen matrix. *Eye* 1988; 2 (2): 149-57
89. Welch MP, Odland GF, Clark RA. Temporal relationships of F-actin bundle formation, collagen and fibronectin matrix assembly, and fibronectin receptor expression to wound contraction. *J Cell Biol* 1990; 110 (1): 133-45
90. Singer II. The fibronexus: a transmembrane association of fibronectin-containing fibers and bundles of 5 nm microfilaments in hamster and human fibroblasts. *Cell* 1979; 16 (3): 675-85
91. Rudolph R. Contraction and the control of contraction. *World J Surg* 1980; 4 (3): 279-87
92. Desmoulière A, Gabbiani G. The role of myofibroblast in wound healing and fibrocontractive diseases. In: Clark RAF, editor. *The molecular and cellular biology of wound repair*. New York: Plenum Press, 1996: 391-423
93. Olsen L, Sherratt JA, Maini PK. A mechanochemical model for adult dermal wound contraction and the permanence of the contracted tissue displacement profile. *J Theor Biol* 1995; 177 (2): 113-28
94. Darby I, Skalli O, Gabbiani G. Alpha-smooth muscle actin is transiently expressed by myofibroblasts during experimental wound healing. *Lab Invest* 1990; 63 (1): 21-9
95. Hebda PA, Collins MA, Tharp MD. Mast cell and myofibroblast in wound healing. *Dermatol Clin* 1993; 11 (4): 685-96
96. Mordon S, Capon A, Fleurisse L, et al. Granulation tissue exhibits differences in alpha-smooth muscle actin expression after laser assisted skin closure (LASC). In: Anderson RRB, Kenneth E, Bass LS, et al., editors. *Lasers in surgery: advanced characterization, therapeutics, and systems XI*. Bellingham (WA): SPIE, 2001: 233-41
97. Takenaka IM, Hightower LE. Transforming growth factor-beta 1 rapidly induces Hsp70 and Hsp90 molecular chaperones in cultured chicken embryo cells. *J Cell Physiol* 1992; 152 (3): 568-77
98. Adzick NS, Lorenz HP. Cells, matrix, growth factors, and the surgeon: the biology of scarless fetal wound repair. *Ann Surg* 1994; 220 (1): 10-8
99. Amenta P, Martinez-Hernandez A, Trelstad R. Repair and regeneration. In: Damjanov I, Linder J, editors. *Anderson's pathology*. 10th ed. Philadelphia (PA): CV Mosby, 1996: 416-47
100. Cromack DT, Porras-Reyes B, Purdy JA, et al. Acceleration of tissue repair by transforming growth factor beta 1: identification of in vivo mechanism of action with radiotherapy-induced specific healing deficits. *Surgery* 1993; 113 (1): 36-42
101. Lawrence D. Transforming growth factor- β . In: Cavaillon JM, editor. *Les Cytokines*. Paris: Masson, 1993
102. Mustoe TA, Pierce GF, Thomason A, et al. Accelerated healing of incisional wounds in rats induced by transforming growth factor-beta. *Science* 1987; 237 (4820): 1333-6
103. Pierce GF, Tarpley JE, Yanagihara D, et al. Platelet-derived growth factor (BB homodimer), transforming growth factor-beta 1, and basic fibroblast growth factor in dermal wound healing: neovessel and matrix formation and cessation of repair. *Am J Pathol* 1992; 140 (6): 1375-88
104. Rifkin D, Gleizes P, Harpel J. Plasminogen/plasminogen activator and growth factor activation. Novartis Foundation Symposium: plasminogen related growth factors. New York: John Wiley and Sons, 1997
105. Shukla A, Dubey MP, Srivastava R, et al. Differential expression of proteins during healing of cutaneous wounds in experimental normal and chronic models. *Biochem Biophys Res Commun* 1998; 244 (2): 434-9
106. Rayner TE, Cowin AJ, Robertson JG, et al. Mitogenic whey extract stimulates wound repair activity in vitro and promotes healing of rat incisional wounds. *Am J Physiol Regul Integr Comp Physiol* 2000; 278 (6): R1651-60
107. Bennett NT, Schultz GS. Growth factors and wound healing II: role in normal and chronic wound healing. *Am J Surg* 1993; 166 (1): 74-81
108. Dallon JC, Sherratt JA, Maini PK. Mathematical modelling of extracellular matrix dynamics using discrete cells: fiber orientation and tissue regeneration. *J Theor Biol* 1999; 199 (4): 449-71
109. Dallon JC, Sherratt JA, Maini PK. Modeling the effects of transforming growth factor-beta on extracellular matrix alignment in dermal wound repair. *Wound Repair Regen* 2001; 9 (4): 278-86
110. Dallon JC, Sherratt JA. A mathematical model for fibroblast and collagen orientation. *Bull Math Biol* 1998; 60 (1): 101-29
111. Whitby DJ, Ferguson MW. Immunohistochemical localization of growth factors in fetal wound healing. *Dev Biol* 1991; 147 (1): 207-15
112. Langsdon PR, Milburn M, Yarber R. Comparison of the laser and phenol chemical peel in facial skin resurfacing. *Arch Otolaryngol Head Neck Surg* 2000; 126 (10): 1195-9
113. Kauvar AN, Dover JS. Facial skin rejuvenation: laser resurfacing or chemical peel: choose your weapon. *Dermatol Surg* 2001; 27 (2): 209-12
114. Monheit GD. Chemical peeling vs laser resurfacing. *Dermatol Surg* 2001; 27 (2): 213-4
115. Holmkvist KA, Rogers GS. Treatment of perioral rhytides: a comparison of dermabrasion and superpulsed carbon dioxide laser. *Arch Dermatol* 2000; 136 (6): 725-31
116. Kitzmiller WJ, Visscher M, DA Page, et al. A controlled evaluation of dermabrasion versus CO2 laser resurfacing for the treatment of perioral wrinkles. *Plast Reconstr Surg* 2000; 106 (6): 1366-72
117. Abergel RP, David LM. Aging hands: a technique of hand rejuvenation by laser resurfacing and autologous fat transfer. *J Dermatol Surg Oncol* 1989; 15 (7): 725-8
118. Spadoni D, Cain C. Facial resurfacing using the carbon dioxide laser. *AORN J* 1989; 50: 1007, 1009-13
119. David LM. Laser vermilion ablation for actinic cheilitis. *J Dermatol Surg Oncol* 1985; 11 (6): 605-8
120. Lask G, Keller G, Lowe N, et al. Laser skin resurfacing with the SilkTouch flashscanner for facial rhytides. *Dermatol Surg* 1995; 21 (12): 1021-4
121. Dover JS, Hruza GJ. Laser skin resurfacing. *Semin Cutan Med Surg* 1996; 15 (3): 177-88
122. Fitzpatrick RE, Goldman MP, Satur NM, et al. Pulsed carbon dioxide laser resurfacing of photo-aged facial skin. *Arch Dermatol* 1996; 132 (4): 395-402
123. Ross EV, Domankevitz Y, Skrobal M, et al. Effects of CO2 laser pulse duration in ablation and residual thermal damage: implications for skin resurfacing. *Lasers Surg Med* 1996; 19 (2): 123-9
124. Apfelberg DB. Ultrapulse carbon dioxide laser with CPG scanner for full-face resurfacing for rhytids, photoaging, and acne scars. *Plast Reconstr Surg* 1997; 99 (7): 1817-25
125. Grossman AR, Majidian AM, Grossman PH. Thermal injuries as a result of CO2 laser resurfacing. *Plast Reconstr Surg* 1998; 102 (4): 1247-52
126. Adrian RM. Pulsed carbon dioxide and erbium-YAG laser resurfacing: a comparative clinical and histologic study. *J Cutan Laser Ther* 1999; 1 (1): 29-35
127. Jimenez G, Spencer JM. Erbium:YAG laser resurfacing of the hands, arms, and neck. *Dermatol Surg* 1999; 25 (11): 831-4
128. Khatri KA, Ross V, Grevelink JM, et al. Comparison of erbium:YAG and carbon dioxide lasers in resurfacing of facial rhytides. *Arch Dermatol* 1999; 135 (4): 391-7
129. Schwartz RJ, Burns AJ, Rohrich RJ, et al. Long-term assessment of CO2 facial laser resurfacing: aesthetic results and complications. *Plast Reconstr Surg* 1999; 103 (2): 592-601
130. Trelles MA, Garcia-Solana L, Calderhead RG. Skin resurfacing improved with a new dual wavelength Er:YAG/CO2 laser system: a comparative study. *J Clin Laser Med Surg* 1999; 17 (3): 99-104
131. Behroozan DS, Christian MM, Moy RL. Short-pulse carbon dioxide laser resurfacing of the neck. *J Am Acad Dermatol* 2000; 43 (1): 72-6
132. Fitzpatrick RE, Rostan EF, Marchell N. Collagen tightening induced by carbon dioxide laser versus erbium: YAG laser. *Lasers Surg Med* 2000; 27 (5): 395-403

133. Goldman MP, Marchell N, Fitzpatrick RE. Laser skin resurfacing of the face with a combined CO₂/Er:YAG laser. *Dermatol Surg* 2000; 26 (2): 102-4
134. Price CR, Carniol PJ, Glaser DA. Skin resurfacing with the erbium:YAG laser. *Facial Plast Surg Clin North Am* 2001; 9 (2): 291-302
135. Rostan EF, Fitzpatrick RE, Goldman MP. Laser resurfacing with a long pulse erbium:YAG laser compared to the 950 ms pulsed CO (2) laser. *Lasers Surg Med* 2001; 29 (2): 136-41
136. Fitzpatrick RE, Bernstein E. Histological findings associated with ultrapulse CO₂ laser resurfacing: a case report [abstract]. *Lasers Surg Med* 1996; 18 (191 Suppl. 8): 34
137. Alster TS, Lupton JR. Prevention and treatment of side effects and complications of cutaneous laser resurfacing. *Plast Reconstr Surg* 2002 Jan; 109 (1): 308-16
138. Zelickson BD, Kilmer SL, Bernstein E, et al. Pulsed dye laser therapy for sun damaged skin. *Lasers Surg Med* 1999; 25 (3): 229-36
139. Bjerring P, Clement M, Heickendorff L, et al. Selective non-ablative wrinkle reduction by laser. *J Cutan Laser Ther* 2000; 2: 9-15
140. Muccini Jr JA, O'Donnell Jr FE, Fuller T, et al. Laser treatment of solar elastosis with epithelial preservation. *Lasers Surg Med* 1998; 23 (3): 121-7
141. Reinisch L, Muccini JA, Fuller T, et al. Quantitative and qualitative evaluation of skin laser [abstract]. *Lasers Surg Med* 1999; 24 (167 Suppl. 11): 41
142. Kelly KM, Nelson JS, Lask GP, et al. Cryogen spray cooling in combination with nonablative laser treatment of facial rhytides. *Arch Dermatol* 1999; 135 (6): 691-4
143. Lask GP, Lee PK, Seyfzadeh M, et al. Nonablative laser treatment of facial rhytides. In: Anderson RR, Bartels KE, Bass LS, editors. *Analysis of nonablative skin resurfacing*. Bellingham (WA): SPIE, 1997: 338-49
144. Menaker G. Treatment of facial rhytides with a nonablative laser: a clinical and histologic study. *Dermatol Surg* 1999; 25: 440-4
145. Ross EV, Sajben FP, McKinlay JR, et al. Non-ablative skin remodeling: selective dermal heating using an IR laser with surface cooling [abstract]. *Lasers Surg Med* 1999; 24 (100 Suppl. 11): 25-6
146. Mordon S, Capon A, Creusy C, et al. In vivo experimental evaluation of skin remodeling by using an Er:Glass laser with contact cooling. *Lasers Surg Med* 2000; 27 (1): 1-9
147. Fournier N, Dahan S, Barneon G, et al. Nonablative remodeling: clinical, histologic, ultrasound imaging, and profilometric evaluation of a 1540 nm Er:Glass laser. *Dermatol Surg* 2001; 27 (9): 799-806
148. Goldberg DJ. Non-ablative subsurface remodeling: clinical and histologic evaluation of a 1320 nm Nd:YAG laser. *J Cutan Laser Ther* 1999; 1 (3): 153-7
149. Mordon S, Souil E, A Capon, et al. A possible role of heat shock protein (hsp) 70 in selective dermal remodeling [abstract]. *Lasers Surg Med* 2000; 26 Suppl. 12: 1

Correspondence and offprints: Dr *Serge Mordon*, INSERM UPRES EA 2689 – IFR 114, Pavillon Vancostenobel, Lille University Hospital, 59037 Lille Cedex, France.
E-mail: mordon@lille.inserm.fr