

Volume 1, Number 2

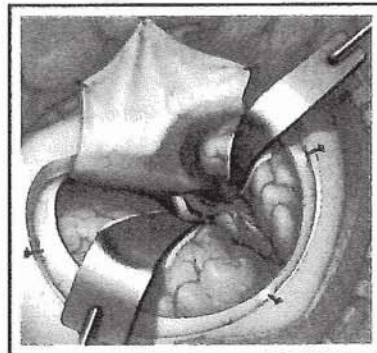
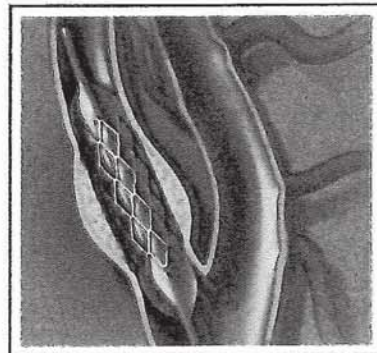
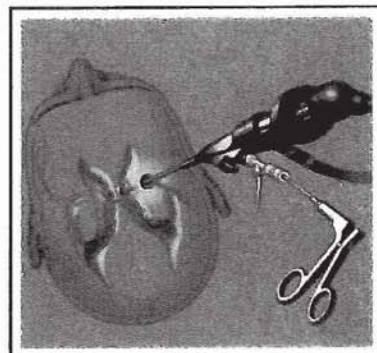
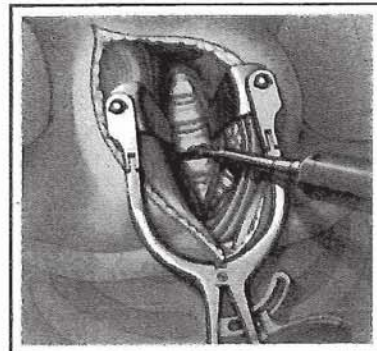
June 1998

Operative Techniques in Neurosurgery

Editor
Robert F. Spetzler

Techniques of Anterior Cervical Plating

Jonathan J. Baskin, MD, A. Giancarlo Vishteh, MD,
Curtis A. Dickman, MD, and Volker K.H. Sonntag, MD



Techniques of Anterior Cervical Plating

Jonathan J. Baskin, MD, A. Giancarlo Vishteh, MD, Curtis A. Dickman, MD, and Volker K.H. Sonntag, MD

Several pathological processes affecting the cervical spine ultimately require management with rigid internal fixation of the vertebral column. The use of anterior cervical screw-plate systems for fixation has been associated with improved fusion, greater postoperative comfort, and a more expedient return to work compared with patients who do not receive these implants. Five cervical screw-plate systems are discussed: four are widely available, and the fifth system is completing final stages of a clinical trial before its commercial release. We describe the preferences and techniques that have evolved at our institution for successful cervical fusion and fixation procedures and compare the features of the different plating systems.

Copyright © 1998 by W.B. Saunders Company

Anterior screw-plate fixation systems are an integral part of the surgical armamentarium available for facilitating vertebral interbody arthrodesis within the subatlantal (C2-7) cervical spine. Early reports that described the application of bone screws and plates along the anterior cervical spine were directed toward patients who suffered from posttraumatic cervical spine instability. Screw-plate instrumentation has now been incorporated into the management of many pathologic conditions of the vertebral column that require structural stabilization after cervical discectomy or corpectomy.

In this domain of instrumentation, product evolution and advertisement have been intense during the last decade, and several screw-plate systems for internal fixation of the cervical spine are commercially available. In pursuing the practical "ideal" of versatility, enhanced fusion rates, and ease of application, each new generation of anterior plating system has incorporated subsequent lessons derived from biomechanical research and clinical experience. Most plating systems have had demonstrated success in securing bony unions, and this article is not intended to endorse any particular system. Rather, we summarize the evolution of available screw-plate systems and describe the senior authors' (VKHS and CAD) individual philosophies and preferences for applying anterior cervical plates and techniques that promote successful arthrodesis.

From the Division of Neurological Surgery, Barrow Neurological Institute, Mercy Healthcare Arizona, Phoenix, AZ.

Address reprint requests to Volker K.H. Sonntag, MD, c/o Neuroscience Publications, Barrow Neurological Institute, 350 West Thomas Road, Phoenix, AZ 85013-4496.

Copyright © 1998 by W.B. Saunders Company
1092-440X/98/0102-0007\$8.00/0

Indications for Anterior Cervical Screw-Plate Fixation

As they provide immediate rigid fixation across the span of desired arthrodesis, anterior cervical plates function to optimize the environment for bony fusion. The proximity of this instrumentation to the fusion substrate confers multiple benefits: resistance to graft displacement, a reduced incidence of pseudarthrosis related to micromotion at the graft-vertebral body interface, and, frequently, avoidance of postoperative halo bracing. Degenerative, neoplastic, infectious or inflammatory, traumatic, and iatrogenic (postsurgical) causes of vertebral column instability, with or without concomitant neural compression, are well suited for treatment with rigid internal fixation from an anterior surgical approach.

At our institution, absolute criteria for performing internal fixation with cervical plate instrumentation include patients who have undergone any extent of formal corpectomy (single or multiple levels) or those with posttraumatic spinal instability. In the latter instance, severe mechanical incompetence (i.e., a three-column injury as defined by Denis¹) might require greater stabilization than an isolated anterior fusion and plate construct can impart. In that instance, a second surgical approach to reconstitute the posterior cervical tension band or external bracing with a halo orthosis might be deemed necessary adjuncts for promoting successful fusion. Anterior cervical discectomies accompanied by fusions that involve three or more adjacent levels are now routinely performed in conjunction with anterior instrumentation.

In general, the management of pathological processes limited to one or two motion segments does not require augmentation of the fusion construct with screw-plates, assuming that the posterior ligamentous elements remain intact. Individual patient characteristics, however, can adversely affect the anticipated success of bone healing. Malnutrition; the active use of tobacco; the presence of significant osteoporosis or other disorders that result in poor bone quality; the need for exogenous steroids; or a history of previously unsuccessful fusion efforts (at the same or different vertebral levels) often leads to managing patients with an anterior cervical plate.

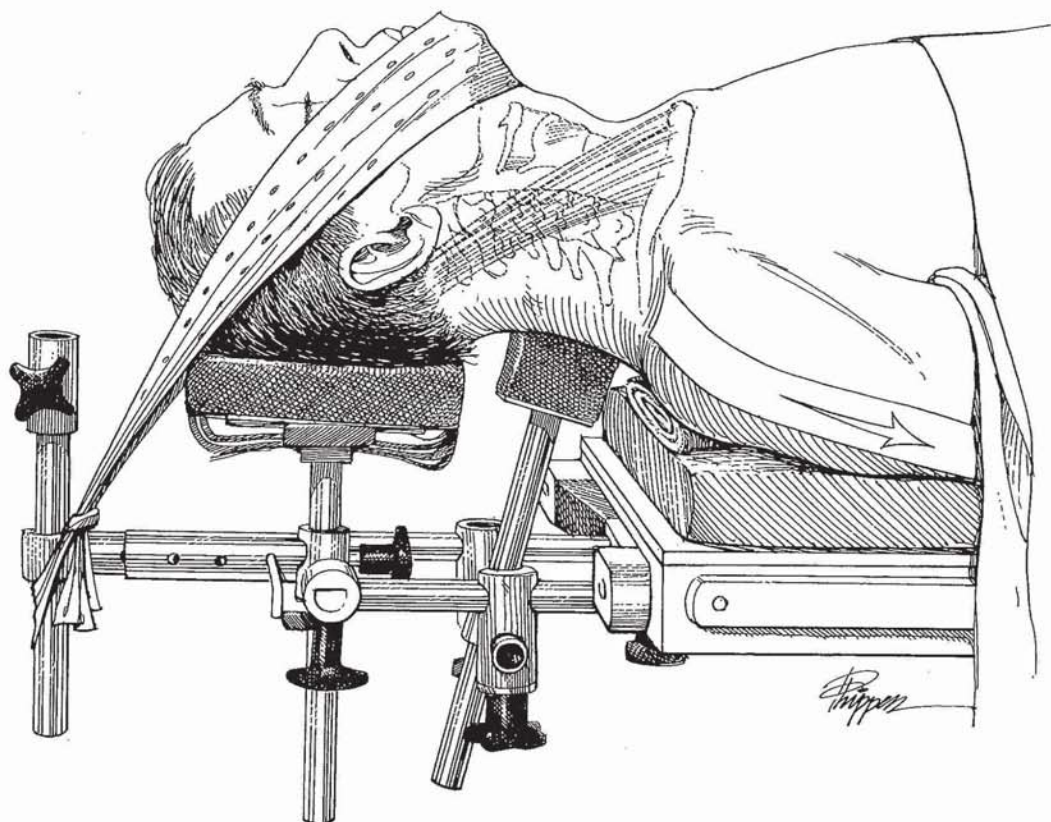
The presence of gross infection at the operative site and metal sensitivity are the primary contraindications to screw-plate insertion.

Operative Technique

Preoperative Preparation and Positioning

After informed consent for the surgical procedure has been obtained, patients are brought to the operating room wearing

Fig 1. Patient positioning with the Caspar head holder. The patient's head is maintained in a neutral position by means of an elastic chin strap. The cervical spine is carefully maintained in either a neutral or minimally extended posture to recreate the cervical lordosis. Adhesive tape is run along the lateral margin of the shoulder joint and arm and affixed to the foot of the bed to assist with intraoperative fluoroscopic visualization of the distal cervical spine. The tape should not be run directly over the clavicle to avoid a pressure injury to the brachial plexus. An intrascapular roll functions to facilitate operative access by allowing the shoulders to fall below the coronal plane of the cervical spine. Both the scalp leads for evoked potential monitoring and the endotracheal tube (not shown) would be rostral in the operative field. (Used with permission of Barrow Neurological Institute.)



antibiotic stockings. Intravenous and intraarterial access is secured, and a single prophylactic dose of antibiotic is administered about 30 minutes before the skin is incised. Intraoperatively, somatosensory and, more recently, motor evoked potentials are monitored. In patients with evidence of myelopathy or significant compromise of the vertebral canal, baseline evoked potentials are measured before the patient is intubated or positioned. Muscle relaxants are avoided during anesthesia to provide an immediate indication of neural irritation during the procedure. Patients with posttraumatic cervical instability or preexisting myelopathy related to cervical stenosis undergo fiberoptic or awake intubation. Patients with preexisting myelopathy receive a bolus dose of methylprednisolone followed by drip infusion in accordance with the NASCIS III protocol.² The infusion is discontinued postoperatively if the neurological examination is stable. General endotracheal anesthesia is induced, and a urinary catheter is placed if the procedure is anticipated to exceed 3 hours.

When the patient is positioned, bony and soft tissue prominences are carefully padded to avoid pressure sores or peripheral neuropathies. If an autograft is to be obtained from the iliac crest, the appropriate hip is elevated with a towel roll. An intrascapular towel roll, tape along the lateral aspect of the arms, and soft wrist ties that can be manipulated by the circulating nurse are helpful adjuncts that facilitate intraoperative radiographic visualization of the distal vertebral column.

We prefer the Caspar headholder (Aesculap, San Francisco, CA) to support the patient's head and cervical spine (Fig 1), even if the patient is already wearing a halo orthosis. The head is maintained in a neutral position, and the neck is maintained neutrally or extended minimally with the assistance of a chin

strap. The evoked potentials should be observed carefully for any changes, and intraoperative fluoroscopy should be available to confirm the maintenance of cervical alignment (anatomical or the best attainable) after positioning is completed. At our institution, the convenience and cost effectiveness of using cross-table fluoroscopy from the beginning of the procedure are well established compared with the relative expense and delays associated with obtaining intraoperative plain film radiography. The importance of fluoroscopy in selecting an appropriately sized cervical plate and for assessing screw trajectories, final screw positions, and alignment of the plate and vertebral column intraoperatively is self-evident.

Skin Incision

The operative approach is directed from the side that is most comfortable for the surgeon and usually corresponds to the patient's right side in a right-handed surgeon. On the right side, however, the recurrent laryngeal nerve is more susceptible to injury given its relatively anterolateral course outside the tracheoesophageal groove when compared with the left side. Consequently, some surgeons may prefer an approach directed from the patient's left side. If the patient has already undergone a cervical procedure, we pursue operative access from the ipsilateral side. Although this strategy requires contending with scar tissue and altered anatomical planes, it avoids the more daunting possibility of incurring bilateral vagal nerve branch injuries, the unilateral manifestations of which may be subtle and otherwise undetected unless specifically evaluated for after the previous procedures.

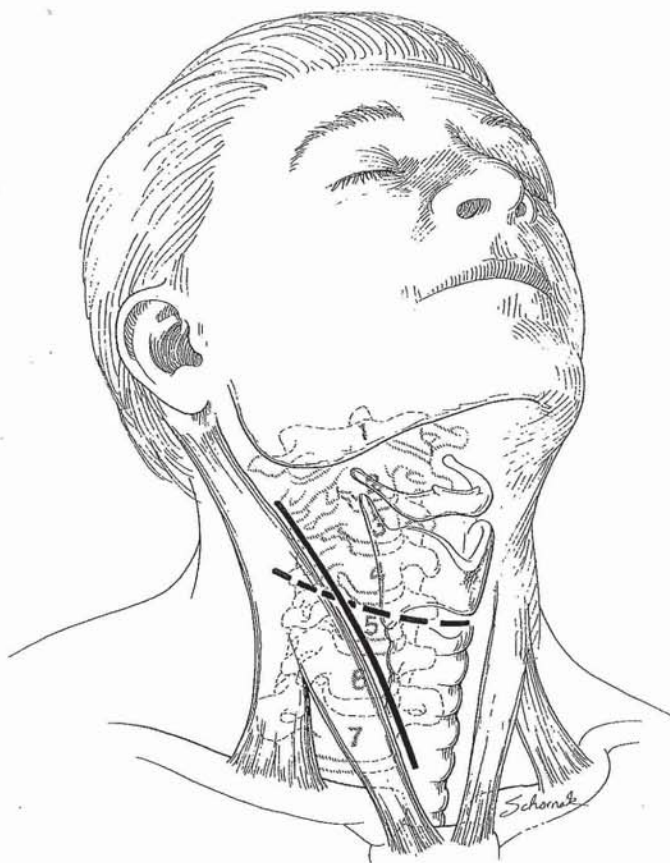


Fig 2. Orientation to the vertebral column may be estimated by palpating superficial anatomical structures. The hyoid bone sits roughly at the level of the C2-3 disc space. The top of the thyroid cartilage can be estimated as the C3-4 disc space. The inferior border of the thyroid cartilage can be estimated as the C4-5 level. The cricoid ring approximates the level of the C5-6 disc space. The C7-T1 disc space sits approximately one-finger's breadth above the clavicle. Our preference is to expose the vertebral column through a transversely oriented skin incision. Adequate extension beyond the midline or across the substance of the sternocleidomastoid muscle allows exposure comparable to that afforded by a longitudinally oriented incision along the medial border of the sternocleidomastoid muscle. Furthermore, the cosmetic result is superior. (Used with permission of Barrow Neurological Institute.)

A general orientation along the cervical spine can be estimated by external anatomical landmarks (Fig 2), but intraoperative fluoroscopy ensures more precise placement of the skin incision. Preoperative use of the fluoroscope to define the most rostral and caudal levels of exposure necessary for decompression and stabilization also assists in selection of the optimal incision orientation. A transverse incision located within a skin crease is cosmetically superior to a longitudinal incision that follows the medial border of the sternocleidomastoid muscle. When extended adequately (beyond the midline and laterally across the sternocleidomastoid muscle) and accompanied by generous undermining of the platysma muscle, the former incision rarely fails to provide sufficient access and visualization to enable multiple corpectomies to be performed with an accompanying fusion and plating procedure. However, particularly long fusion constructs or difficult patient anatomy may make the longitudinal incision more functional.

Soft Tissue Dissection and Exposure of the Vertebral Column

After the patient has been prepared and draped, the skin is sharply incised to the level of the platysma muscle. The platysma layer is traversed. Early attention to broad undermining of this subcutaneous muscle is greatly rewarded by the rostral and caudal extents of surgical exposure that can be attained. The underlying sternocleidomastoid muscle and tracheoesophageal bundle are identified, and the avascular plane between these structures is developed with careful, blunt dissection. A trajectory medial to the carotid sheath is followed, and the underlying vertebral column is palpated (Fig 3). Comparing the osteophytic topography to preoperative or intraoperative radiographs can often help orient the surgeon along the cervical column. Fluoroscopy, however, is needed to obtain definitive localization along the cervical spine. The prevertebral fascia is opened, and the ventral aspect of the anterior longitudinal ligament is cleaned of overlying soft tissue. The medial insertions of the adjacent longus colli muscles are elevated bilaterally from the vertebral column.

The insertion of self-retaining, serrated (blunt-toothed) Caspar retractor blades (Aesculap) further exposes the anterior vertebral column. Rostral-caudal exposure can be improved by adding a second Caspar retractor (blunt blades) positioned perpendicular to the first (Fig 4). Vertebral body distraction posts can also be added, but they can compromise the integrity of the vertebral body and adversely affect the quality of screw purchase and should therefore be avoided. If ultimately deemed necessary, the distraction posts may be inserted one level rostral and one level caudal to the vertebrae targeted for screw insertion.

Discectomy With or Without Corpectomy

Once orientation at the level of pathology has been confirmed, annulotomies are performed and superficial discectomies are initiated with straight and angled curettes (Fig 5A). If an interval corpectomy is necessary, a bone rongeur can be used to resect the anterior half of the vertebral body, and the Midas Rex drill (Midas Rex Pneumatic Tools, Inc., Fort Worth, TX) can be used to complete the deeper aspect of bone removal (Fig 5B). If placement of an allograft strut is planned, autologous bone from the vertebrectomy site is saved for packing the hollow center of the allograft shaft. The operative microscope is routinely used to assist with the removal of deeper bone and soft tissues to facilitate safe exposure of the dura. The epidural space is inspected and soft disc material removed if present. Posteriorly based osteophytes are resected from the vertebral bodies and foramen to ensure adequate decompression of the spinal cord and nerve roots.

When completed, the typical lateral extent of tissue removed for discectomies or corpectomies spans 20 mm. Reliable identification of the vertebral midline is crucial to ensure adequate decompression of neural tissue and to avoid vascular complications related to injury of the vertebral artery. Frequently, severe degenerative disease, traumatic disruption, or scarring from previous surgical procedures result in the loss of the otherwise apparent anatomical midline. Typically, however, several anatomical cues remain and can be used to provide reference to the midline for both decompressive maneuvers and plate positioning (Table 1). At this point during the

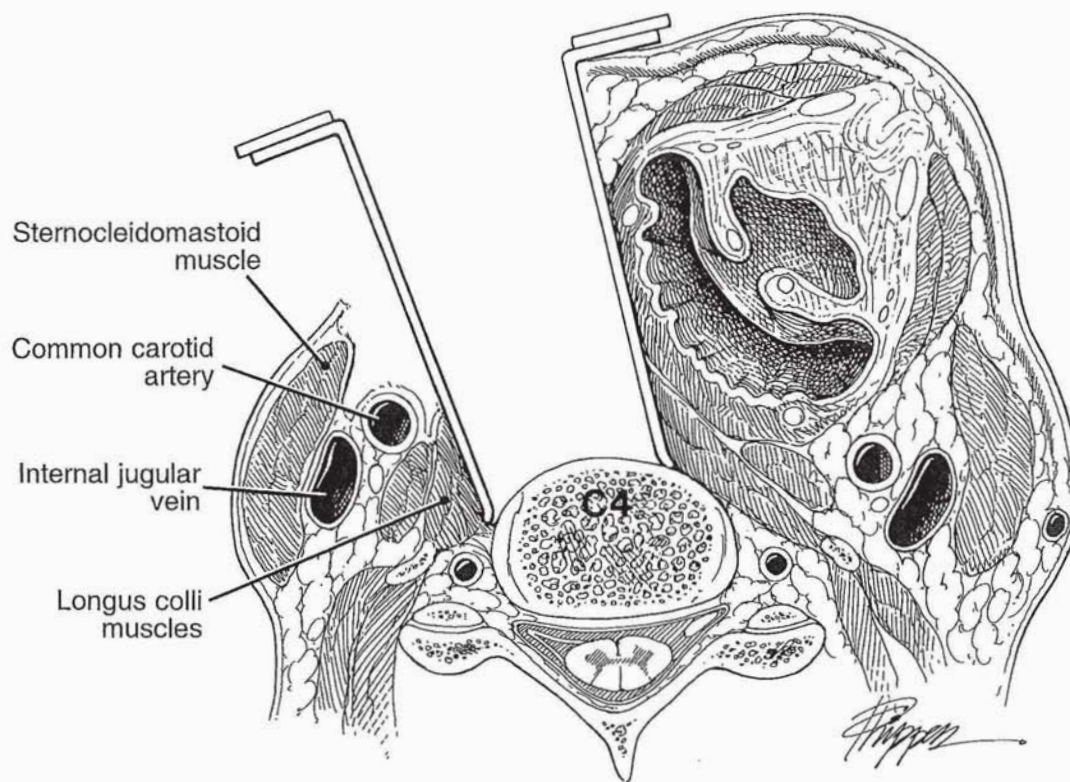


Fig 3. The relative anatomy and trajectory for an anterior transverse retropharyngeal approach to the cervical vertebral column. A plane of dissection is maintained lateral to the tracheal-esophageal bundle and medial to the carotid sheath. Bilaterally, the longus colli muscles are dissected subperiosteally to provide a submuscular pocket for seating the toothed retractor blades. Failure to seat these blades beneath the longus colli muscles properly places the esophagus and adjacent vascular structures at risk for perforation. When the vertebral column is approached anterolaterally, the tendency is to direct decompression eccentric to the contralateral side. Thus, regardless of whether the operative approach is conducted from the patient's left or right side, it is important to ensure that the ipsilateral neural foramen receives adequate attention and decompression. When anterior cervical plates are applied, the tendency is to place the plates slightly eccentric to the ipsilateral side of dissection. The plates, however, should be applied in as midline a position as possible to minimize the risk of injuring the vertebral artery and to provide as optimal a biomechanical construct as possible. (Used with permission of Barrow Neurological Institute.)

procedure, it is also worthwhile to confirm with the anesthesiologist that the patient's head has not deviated from the midline position established at the beginning of the case.

Tenets and Techniques of Grafting and Plate Fixation

Screw-plate application provides immediate rigid fixation to the cervical spine and functions analogously to an "internal" halo brace. However, only an osseous union can confer long-term stability to the vertebral column. Consequently, perhaps the most fundamental principle related to rigid internal fixation is that the presence of instrumentation cannot substitute for a carefully conceived and meticulously prepared fusion site. In the absence of an associated bony union, hardware failure is a time-dependent certainty.

We typically use the Smith-Robinson technique for interbody fusion after a cervical discectomy. Techniques to optimize the chances for successful arthrodesis (Table 2) at the operative site can be subdivided into those that

- (1) enhance the natural capacity for bone healing to occur,
- (2) minimize the extent of iatrogenically induced impediments to bone graft incorporation, and
- (3) maximize the biomechanical advantage of the hardware construct.

Enhancing the Capacity for Natural Bone Healing

Bone grafts are incorporated with the greatest success when the fusion construct is maintained under a compressive load (Wolff's law).³ Consequently, the vertical dimension of the graft material is typically sized a few millimeters larger than the measured discectomy or corpectomy defects to ensure mechanical compression of the graft within the recipient bed. At the time of graft placement, the adjacent vertebral bodies are distracted mildly through the use of either a disc space spreader, vertebral body distraction posts, or carefully directed axial traction applied by the anesthesiologist.

After the posterior half of the graft has been tamped into place, the vertebral body distraction is released and the remainder of the graft advanced. These maneuvers promote seating and avoid excessive impaction of the graft. After final positioning, graft security and an appropriate epidural margin are confirmed by palpation with a nerve hook and with fluoroscopy. All soft tissues are removed from the graft material and interfaces involved with the fusion site (end plate articular cartilage) to prevent the delayed differentiation of fibrous tissue that might hinder bone formation. The creation of smooth, apposing surfaces along the bone graft and vertebral bodies serves to improve fusion by maximizing the area of surface contact at the fusion interfaces.

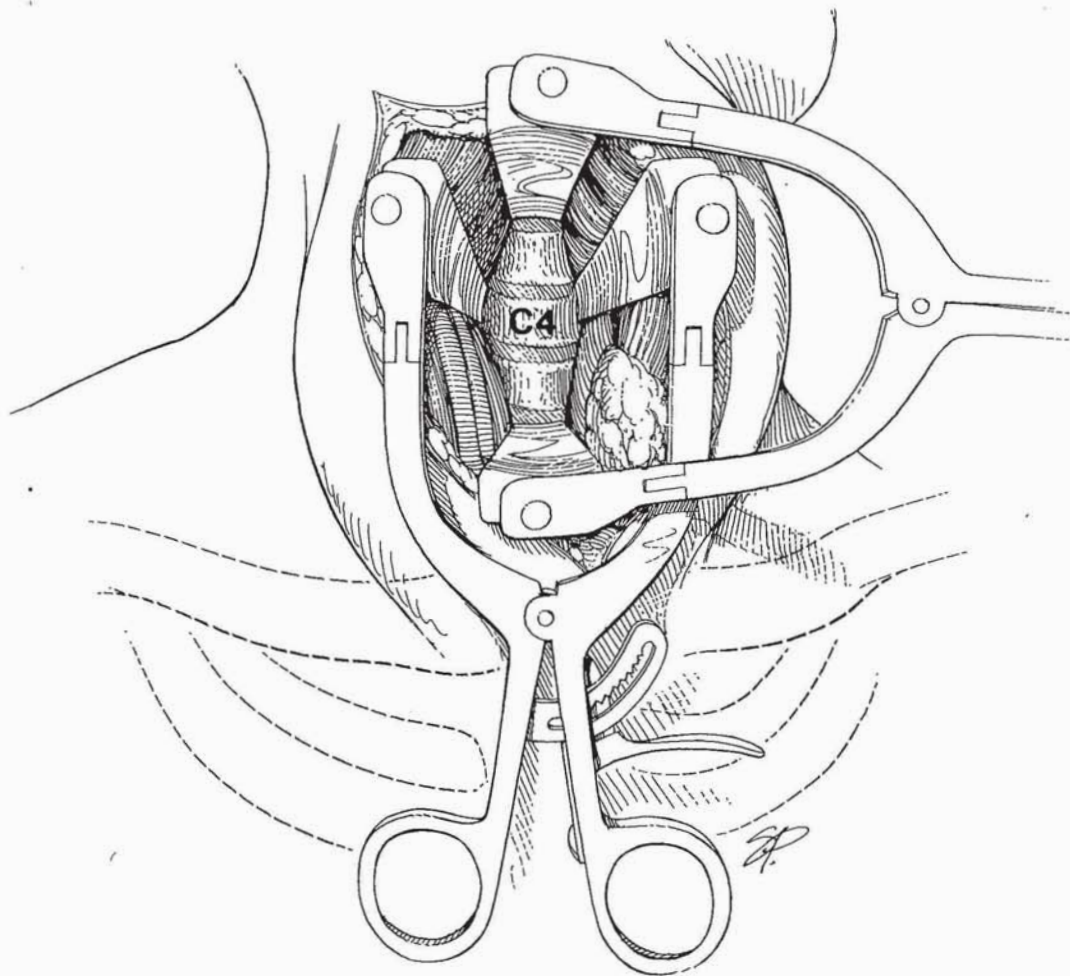


Fig 4. A second, perpendicularly oriented Caspar retractor system assists with rostral-caudal exposure of the vertebral column. These longitudinally oriented retractor blades are without teeth. Alternatively, the Caspar vertebral body distraction posts can be used to assist with retracting soft tissue in this plane. If the latter system is used, the posts are preferentially placed in the vertebral bodies rostral and caudal to those intended for screw placement. (Used with permission of Barrow Neurological Institute.)

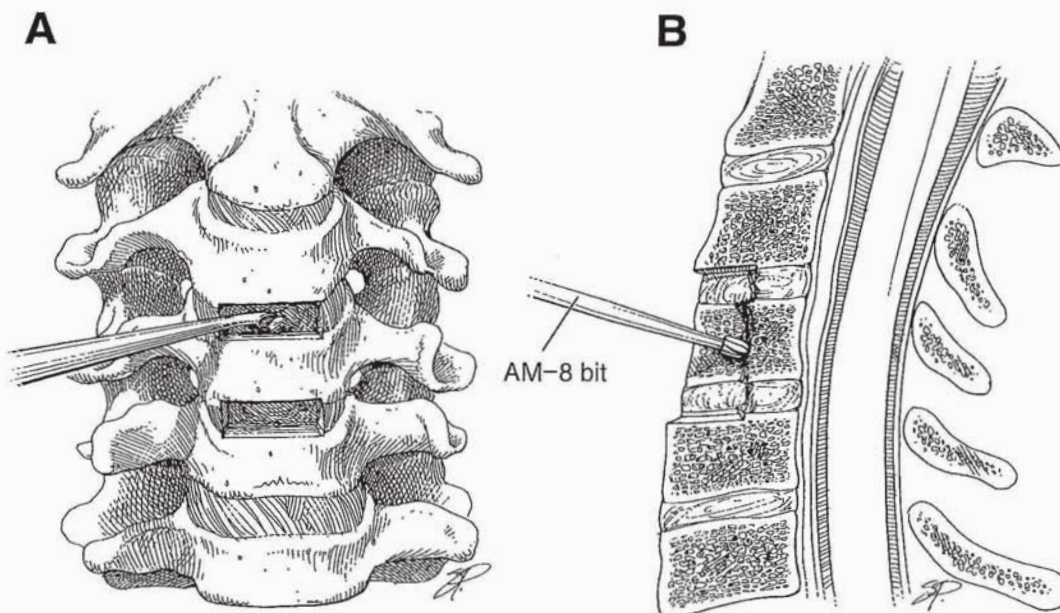


Fig 5. (A) Anterior view of partially completed C3-4 and C4-5 discectomies. The lateral extent of disc removal is the uncovertebral joints bilaterally. If a corpectomy is planned, the adjacent disc spaces are similarly first defined, and superficial discectomies are performed before the vertebral body is resected. The superficial aspect of the corpectomy can then be performed easily with either a bone rongeur or a Midas Rex drill. Typically, we prefer to use the AM-8 Midas bit to perform the corpectomy. (B) Sagittal view of a C4 corpectomy. The deeper aspects of the discectomies and corpectomy are performed under the operating microscope to insure the safe exposure and decompression of the epidural space. Once the epidural space has been identified at the level of the rostral and caudal disc spaces, the remaining posterior cortex of the interval vertebral body is removed with bone punches. (Used with permission of Barrow Neurological Institute.)

TABLE 1. Anatomical Cues Available for Maintaining Midline Orientation

Location of longus colli muscles
Location of uncovertebral joints
Curvature of vertebral body (lateral margin/waist)
Location of epidural veins and fat
Curvature of dural tube
Visualization of nerve roots
Palpation of pedicle
Location of sternomanubrial notch (angle of Louis)
Use of anteroposterior fluoroscopy

Iatrogenic Impediments to Fusion Biology

High-speed drills are convenient for denuding articular surfaces within the fusion bed and for shaping the fusion surfaces of the vertebral bodies and graft. During all drilling, consistent irrigation is needed to avoid thermal injury to the osseous tissues that can incite subsequent bone resorption and interfere with fusion. Similarly, the excessive use of monopolar cauterization to expose the vertebral column can impede healing as a result of direct thermal injury and bone devascularization. Use of monopolar cauterization for deep tissue dissection also places adjacent soft tissues (eg, esophagus, recurrent nerve) at greater risk. After discectomy or corpectomy, bone bleeding within the recipient bed can be controlled with thrombin-soaked Gelfoam (Upjohn, Kalamazoo, MI), Avitene powder (MecChem, Woburn, MA), or bone wax. However, applying these substances at the site of the proposed graft-vertebral body interface, particularly bone wax, can potentially hinder fusion.

Optimizing the Fusion and Hardware Construct

Ventral osteophytes should be removed to allow a flush application of the plate to the spinal column. However, as much of the cortical bone layer as possible needs to be retained since it contributes substantially to the individual screws' resistance to pulling out. This point is particularly important when screw-plate systems that only rely on unicortical bone purchase are implanted. In contrast to cervical fusion proce-

dures that do not include instrumentation, the graft material is not countersunk away from the ventral margin of the disc space. Instead, the anterior border of the bone plug or strut is left in line with the anterior margin of the adjacent vertebral bodies to maximize the contact surface between the plate and the entire fusion construct. For a single-level autograft or allograft, a posteriorly placed trough along the posterior aspect of one of the vertebral bodies protects against graft retropulsion and epidural compression. Autograft struts that span more than one level are secured to the plate with a bicortically anchored bone screw to prevent graft retropulsion. Typically, fibular allograft is too brittle to accept a bone screw, and posterior troughs are created at the upper and lower vertebral levels to protect against its displacement (Fig 6).

"Two-finger tightness" is the desired final screw torque to avoid "stripping" the screw hole and diminishing the screw's resistance to pulling out. If the tapped threads are stripped, options for securing the construct include substituting a larger diameter "rescue" screw, drilling a new screw hole if variable trajectory placement is possible, moving the entire plate so that a new hole for a fixed trajectory screw can be drilled, or bolstering the initial screw's purchase with methylmethacrylate. Real-time fluoroscopy is used to monitor screw placement. Its use is strongly recommended irrespective of the surgeon's experience with screw-plate fixation. If possible, the screw trajectory should capture the denser bone tissue in the subchondral region of the vertebral body while respecting the vertebral body end plate. Violation of the distal vertebral end plate not only results in a suboptimal screw purchase but also risks the incorporation of a normal motion segment within the fusion construct. Although the cervical plates can be contoured to maximize contact with the underlying vertebral column, this manipulation fatigues the implant and should be minimized. The longest screws that can be accepted by an individual patient's anatomy are used for plate fixation because they resist pulling out better than their shorter counterparts. When multisegment plating procedures are performed, the plate should be fixated at as many points as possible, particularly at the caudal levels because of the greater failure stresses transmitted to that location. Midsagittal application of the plate fosters optimal load-sharing among the fixation points.

When the recipient site is prepared for graft placement, the cortical end plates are thinned sufficiently to expose bleeding bone but are left intact to prevent settling or "telescoping" of the graft material through the adjacent vertebral bodies. This step is particularly important when implanting allograft material, whose rigidity makes this complication more common than when autograft is used, especially in patients with soft bone. Settling of the graft adds further mechanical stress to the screw-plate construct, increasing the chances for premature failure of the implant and incomplete fusion of the bone.

Proper attention to graft harvesting (autograft) or preparation (allograft) optimizes the load-bearing capabilities of these materials. We prefer to obtain iliac crest bone by means of an oscillating saw, given the reduction in compressive strength associated with tricortical bone obtained with osteotomes. Failure to reconstitute the freeze-dried allograft in saline for the recommended 30 minutes before shaping or inserting the graft compromises its structural integrity.

TABLE 2. Techniques to Optimize Fusion-Hardware Construct

Maneuver	Benefit
Insert graft under compression	Improves graft incorporation
Maximize surface of implant-bone interface	Improves graft incorporation
Remove soft tissue from fusion interface	Avoids fibrous healing
Maintain integrity of cortical end plate	Prevents telescoping of graft
Irrigate while drilling	Prevents thermal injury with impaired bone healing/resorption
Avoid contouring plate	Avoids fatiguing of implant
Avoid overtightening screws	Prevents stripping screw hole and diminishing bone purchase
Insert angulated screws	Improved pull-out strength
Use longest screws possible	Improved pull-out strength

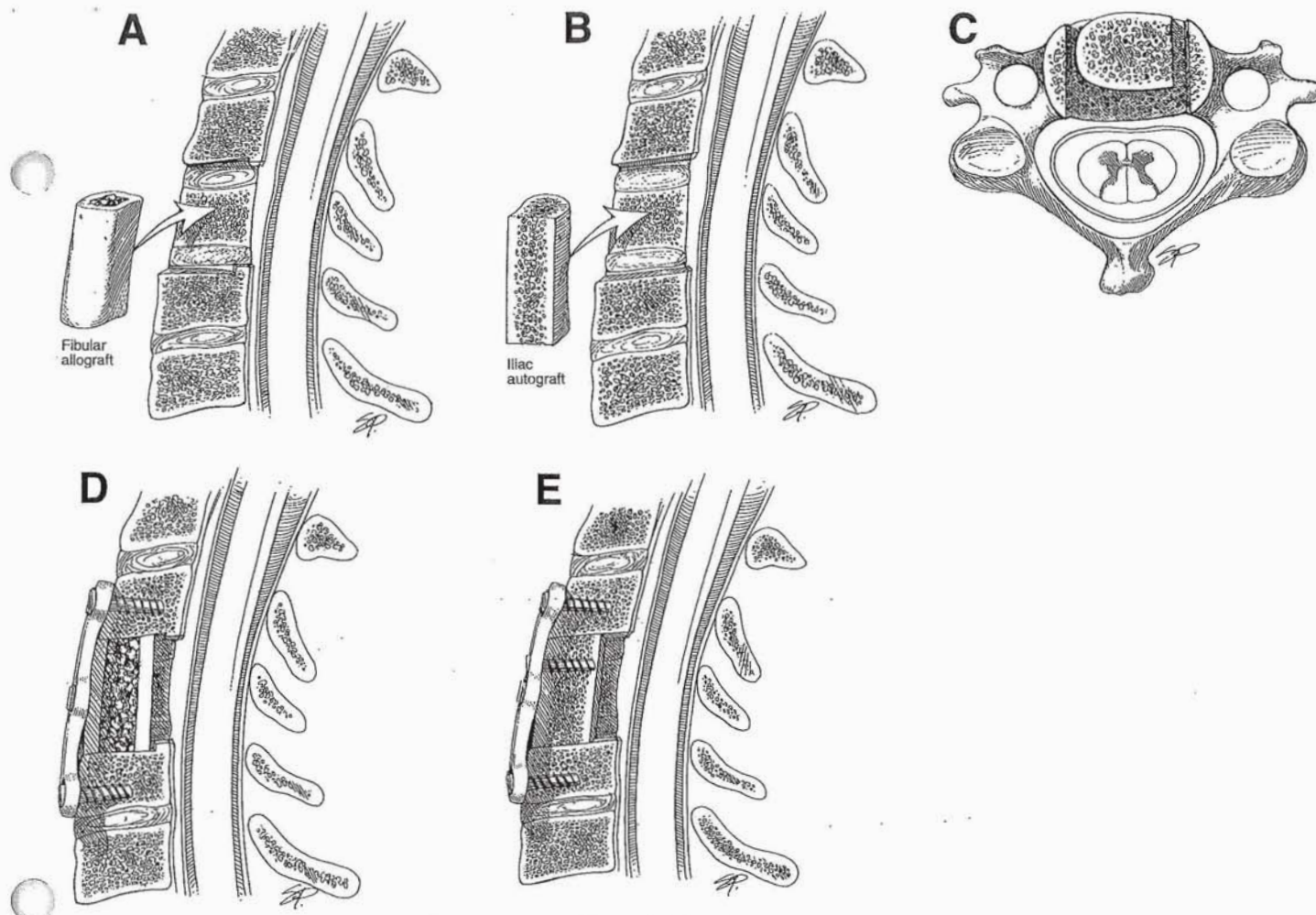


Fig 6. Sagittal views of corpectomy defects before allograft (A) and autograft (B) fusion procedures. Because a screw can be used to secure the autograft to the anterior cervical plate, posterior troughs are not necessary to prevent graft retropulsion. Conversely, the allograft material is usually too brittle to accept a screw. Consequently, rostral and caudal troughs are created within the respective vertebral bodies to protect the epidural space. The height of the troughs is 1 to 2 mm, and a concerted effort is made to maintain the integrity of the adjacent vertebral endplates in order to minimize the risk of the graft construct telescoping through the adjacent vertebral bodies. (C) Midlevel axial view through a corpectomy defect after insertion of an autologous bone graft illustrates the senior authors' (VKHS and CAD) preference for orienting autologous graft material. As placed, the cortical margins serve to buttress the anterior and middle columns while minimizing the anteroposterior diameter of the graft. This latter point provides an added margin of safety between the graft material and the epidural space. C4 corpectomy site after allograft (D) and autograft (E) fusion with plating procedures. In both cases, the graft material is not countersunk; the anterior margin of the graft material is flush with the undersurface of the plate. The allograft material is packed with autologous bone from the corpectomy site to promote fusion. A bicortical screw fixes the autograft to the cervical plates. (Used with permission of Barrow Neurological Institute.)

Closure

The operative site is finally inspected, both under direct visualization and fluoroscopically. Specific attention is directed toward the alignment of the vertebral column after fixation, the position of the graft with respect to the epidural space, and the length of the plate and position of the screws with respect to the rostral and caudal disc spaces. Midline location and vertical orientation of the plate can be assessed fluoroscopically by observing a parallel overlap of plate holes and screw trajectories on cross-table views. Bacitracin-containing saline is used to irrigate the wound, and hemostasis is obtained with bipolar cauterization. Self-retaining retractors are removed, and the trachea, esophagus, and carotid sheath are inspected with a hand-held retractor for evidence of injury. If present preoperatively, a persistent carotid pulse above and below the level of self-retaining retractor placement is confirmed.

The platysma muscle and dermis are closed as separate layers with interrupted vicryl sutures, and the skin is further reapproximated with a running subcuticular suture and Steri-strips (3M Healthcare, St. Paul, MN). We have found no need to maintain a surgical drain within the operative site, and current evidence does not support the routine use of prophylactic postoperative antibiotics in otherwise immunocompetent patients.

Orthoses and Postoperative Follow-up

The nature of the patient's preoperative pathology, the extent of their underlying mechanical instability, and the length of the fusion construct dictate the type of postoperative cervical orthosis prescribed. After screw-plate fixation, most patients are considered to be adequately stabilized if they wear a hard cervical collar when active. They are allowed to wear a soft

collar while sleeping. Immediately after surgery, plain film radiographs are obtained. They are repeated with flexion and extension views 6 weeks after surgery. If there is evidence of graft incorporation and the instrumentation appears stable on the comparative views, patients are instructed to taper their use of the hard collar and to initiate exercises to strengthen their cervical muscles. In patients who presented with a three-column traumatic disruption of their spinal column or who suffer from an underlying metabolic impediment to healing (ie, rheumatoid arthritis), use of a halo brace from the time of surgery for additional postoperative stabilization should be considered. Multilevel plate constructs are more prone to failure than their shorter counterparts. Postoperatively, patients whose procedures involved three or more corpectomies should be managed in a halo brace.

The Evolution of Screw-Plate Systems

The first reported use of screw-plate fixation of the anterior cervical spine occurred in 1964 and is attributed to Bohler.⁴ Presently, four varieties of plating systems comprise the majority of instrumentation used for internal anterior cervical fixation: Caspar (Aesculap); Synthes (Spine, Paoli, PA); Orion (Sofamor Danek, Memphis, TN); and Codman (Johnson and Johnson Professional Inc, Raynham, MA). A fifth system (Atlantis, Sofamor Danek, Memphis, TN) is completing test center trials.

From biomechanical and biological perspectives, the ideal plating system would initially provide adequate fixation to promote fusion but would facilitate delayed remodeling at the fusion site by allowing the transmission of physiological loading (limited stress shielding). Although each of the commonly available systems has its own limitations, clinical success has been achieved with each (Table 3). Each system has its own advocates and detractors, and the relative merits of one anterior cervical plate compared with another remain

largely subject to the individual surgeon's preferences and familiarity with the different instrumentation.

All of the implants are available in titanium or its alloys, the strength of which is estimated to be 90% that of steel but whose presence causes minimal artifacts on magnetic resonance imaging. The later generation plating systems offer unicortical screw purchase (eg, Synthes, Orion, Codman, Atlantis), which is technically easier to perform than bicortical screw placement (Caspar). It also poses less potential risk for dural violation and spinal cord injury. That being said, the Caspar system has enjoyed the longest period of clinical use and remains popular, with a small reported incidence of neurological complications related to screw placement. Systems that rely on a unicortical screw purchase require a mechanism for securing the screw head to the plate. The trend in product development has been for this locking feature to be incorporated within the plate itself (Codman, Atlantis) instead of as a separate component (Synthes, Orion). Fixation at the screw head-plate interface may be described as rigid (constrained system) or nonrigid (nonconstrained). Screws with variable trajectories are, by definition, nonrigidly fixed to the plate by their respective locking mechanisms. In contrast, fixed trajectory screws are rigidly coupled to the plate by locking devices. Selection of a constrained or a nonconstrained fixation construct is determined by the intrinsic instability of the pathologic condition being treated. Patients with traumatic instability are likely better served with a more rigid implant, whereas patients with degenerative instability are more likely to maintain the integrity of a nonrigid construct that permits small amounts of settling over time.

Historically, surgeons have had to choose their plating system, in part, based on a preference for placing screws through a fixed (predetermined) or variable trajectory. Although less error in screw placement is associated with fixed trajectory screws, they offer little opportunity for the surgeon to compensate for a patient's abnormal anatomy to achieve as

TABLE 3. Comparison of Anterior Screw-Plate Systems

Plate System	Year Commercially Available	Established Lordotic Curve	Required Screw Purchase	Locking Mechanism	Screw Trajectory	Constrained System	Available Plate Lengths (mm) (End-to-End)	Plate Thickness (mm)	Available Screw Dimensions (mm) Diameter (Length)	Sample 1997 Catalogue Price (\$)	
										Plate Length (mm) (\$)	Screw Diameter (mm) (\$)
Caspar	1980	No	Bicortical	None	Variable	No	26-90	1.5	3.5 (10-28) 4.5 (17-24)	28 (437.00)	3.5 (9.60)† 4.5 (30.00)†
Synthes	1991	Yes	Unicortical	Separate locking screw (available for each individual screw site)	Fixed	Yes	22-92	2.0	4.0 or 4.35 (12, 14, or 16)	28 (509.00)	4 (95.50)† 4.35 (133.00)† Locking (19.50)
Orion	1993	Yes	Unicortical	Separate cover screw (limited to rostral and caudal screw pairs)	Fixed	Yes	21.5-110	2.5	4.0 (10-24) 4.35 (11, 13, or 15)	27.5 (529.00)	4.0 (107.00)† 4.35 (114.00)† Locking (51.00)
Codman	1996	Yes	Unicortical	Integrated cam (available for each individual screw site)	Variable	No	24-110	2.7	4.5 only (10-26)	28 (458.00)	12- or 15-mm length (72.00) All other lengths (87.00)
Atlantis	1998	Yes	Unicortical	Integrated locking screw (available for all screw pairs)	Both	Both	19-110	2.5	4.0 (10-20)* 4.5 (13, 15, or 17)*	27.5 (695.00)	(118.00)‡

*Fixed or variable trajectory screw type.

†No price difference related to screw length.

‡No price difference based on screw length, diameter, or fixed or variable trajectory screw type.

optimal a screw purchase as possible, or to correct for suboptimal screw tracks or stripped tap holes. Similarly, the ability to contour fixed trajectory plates as desired is limited by the effect that bending would have on the final screw placement. The fixed systems can also be difficult to use at the extremes of cervical placement, where bony structures, such as the mandible or clavicle, can prohibit the necessary positioning of instruments for drilling and inserting screws along a predetermined pathway. These issues make variable screws attractive because they offer more diversity in placing the screws; however, they also carry a greater risk for complications related to malpositioning of the screws than systems with fixed trajectory screws. The newly developed Atlantis system is the only plating system that offers the versatility of fixed, variable, or a combination of these two screw types within a single plate. Depending on the underlying cause for instability, this system can be tailored to offer the properties of a constrained, nonconstrained, or hybrid system as detailed in the following section.

Individual Plating Systems

Caspar System

Introduced in 1982, the Caspar osteosynthetic plate (Aesculap) is the only system that requires bicortical screw purchase (Fig 7). The screw trajectory is variable (nonconstrained system), and no locking mechanism secures the screw head to the plate. It is probably the most technically difficult system to use, and the depth of posterior cortical penetration must be determined precisely to avoid compromising the epidural space. The plates are machined without contour in the sagittal plane but can be curved as desired. The slot configuration allows positioning and redirecting of the screws as necessary. The recommended screw trajectory is 15° medially and parallel to the adjacent vertebral end plate. The recommended plate length is one that extends to 2 mm from the rostral and caudal end plates of the vertebral bodies incorporated in the fusion construct.

Synthes

Introduced in 1986, this unicortical system (Synthes) has historically employed a 14-mm fixation screw with an expansile head that accommodates a separate internal 1.8-mm expansion locking screw (Fig 8). This combination rigidly secures the screw head to the plate. Fixation screws are now also available in lengths of 12 and 16 mm. Screws are inserted with a predetermined convergent trajectory (constrained system) to resist pulling out. The plate has a fixed rostral and caudal orientation; the upper screws are angled 12° rostrally to approximate the cervical lordosis, and the lower screws are directed perpendicular to the plate in the sagittal plane. Bending, which further weakens the plate's structure, should be performed away from plate holes to avoid altering the integrity of the locking mechanism. Bending also alters the fixed screw trajectory and can compromise the final trajectory of the screw. The set offers a temporary fixation pin to stabilize the plate while screw sites are drilled.




Fig 7. Caspar plate (28 mm) and screw. Bicortical screw purchase prevents the need to rigidly fixate the screw head to the plate.

Orion

The Orion contoured system (Sofamor Danek) uses a fixed trajectory screw (constrained system) that is medially convergent (6°) with 15° angulation at the top and bottom (Fig 9). Further plate bending alters the cephalad and caudal angula-




Fig 8. Synthes plate (28 mm) with fixation (left) and locking (right) screws. The fixation screws are anchored to the plate by means of an expanding head following placement of the axial anchor screw. Each fixation screw receives its own locking screw.

tions of screw placement, as with the Synthes system. A separate component locking screw increases the resistance of the bone screw to pulling out. The system also features the option of placing additional screws through a variable interval slot (4.35-mm diameter screws recommended), although screws in this location cannot be formally secured to the plate with a locking screw. Insertion of the locking screw requires an orientation that is truly perpendicular to the plate. Failure to achieve this angle, which may be particularly difficult to attain at the most rostral and caudal levels of the cervical exposure, can result in an inability to insert the locking screws. A self-limiting torque mechanism causes the locking screw driver to twist free from the screw head when the locking screw is secured appropriately. Plate sizing must allow for the fixed 15° angulation; the general recommendation is that the plate length should span just beyond the margins of the graft site to ensure that the screws do not violate the adjacent end plates.

Codman Locking Plate System

The Codman contoured titanium plate (Fig 10) offers variable trajectories for screw insertion (nonconstrained system) and has no specific rostral or caudal end. A locking cam mechanism integrated into the plate allows unicortical screw fixation. Extremes in screw angulation ($>16^\circ$) can prevent the cam system from formally engaging the screw head, but the cams can still be positioned to offer some resistance to screw backout ("lock zone" between 240° and 270° of rotation). The plate also may be bent, but the curve should be distributed evenly throughout the length of the plate and limited to the thinner, designated "bend zones" to prevent the locking cam mechanism from failing. The more commonly used 12- and 15-mm drill bits, taps, and screws are color-coded (blue and gold, respectively) to simplify use of the system. However, a wide range of screw lengths is available and can be inserted by means of the variable depth drill guide and taps included in the system kit. Only 4.5-mm diameter screws, the size that the other plating systems typically reserve for their rescue screws, are available with this system. The typical recommended screw placement is 10° medially, parallel to the orientation of the adjacent disc space. The recommended plate length is from the rostral subchondral region of the most rostral vertebral body to the caudal subchondral region of the most caudal vertebral body included in the fusion construct.

Atlantis System

With the Atlantis System (Sofamor Danek; Fig 11), fixed and variable screw trajectories are possible at any plate level (Fig 12). Specific drill guides either lock within the plate in fixed position (12° divergent in sagittal plane, 6° medially convergent) or allow angulation through an arc of approximately 31° relative to the axis of the screw hole (Fig 13A and B). A holding pin, available for hands-off stabilization of the plate during drilling, is small enough in diameter to permit a vertebral body screw to be passed along its path later in this procedure (Fig 14). The locking screw mechanism is integrated within the plate and is available for all screw sites (vertebral body and autograft strut). The locking screw screwdriver has a torque release feature that indicates sufficient tightening. Like any of the other plating systems, extremes of screw angulation may result in incomplete interfacing of the locking screw with the

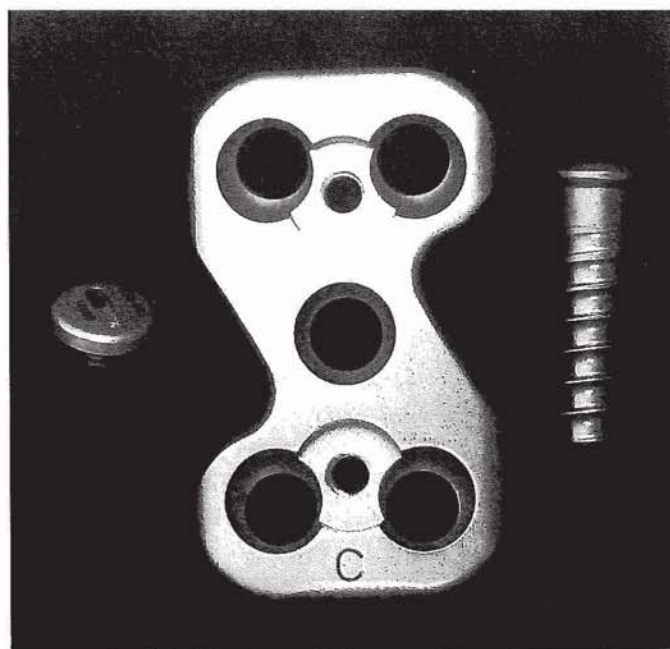


Fig 9. Orion plate (27.5 mm) with fixation (right) and locking (left) screws. Only the rostral and caudal fixation screw sites accommodate a locking screw. One locking screw straddles the two fixation screws at these levels.

fixation screw. The plate is manufactured with all of the locking screws present in the open, elevated position. Before the wound is closed, all locking screws should be recessed to minimize the profile of the fixation construct.




Fig 10. Codman plate (28 mm) with fixation screw. Note the integrated locking cam mechanism. Each fixation screw site has its own individual corresponding locking cam site.

Complications

The risks related to screw-plate stabilization of the cervical spine obviously include all of those associated with a routine anterior cervical discectomy with fusion: injury to branches of the vagus nerve (recurrent or superior laryngeal nerves), dysphagia, radicular or myelopathic injury, cerebrospinal fluid leak, infection, anterior or posterior graft migration, and postoperative hematoma. Implant failure with screw or plate dislodgement (with or without fracture of the instrumentation) would typically accompany a pseudarthrosis or fibrous union at the fusion site and would necessitate revision of the entire graft and instrumentation construct. Morbidity associated with hardware migration also includes tracheoesophageal and neurovascular injuries. It is possible to observe implant failure in the setting of a successful arthrodesis. In such a




Fig 11. Atlantis plate (27.5 mm) with variable (left) and fixed (right) trajectory fixation screws. Fixation screw heads at any location on the plate are within access of one of the integrated locking screws.

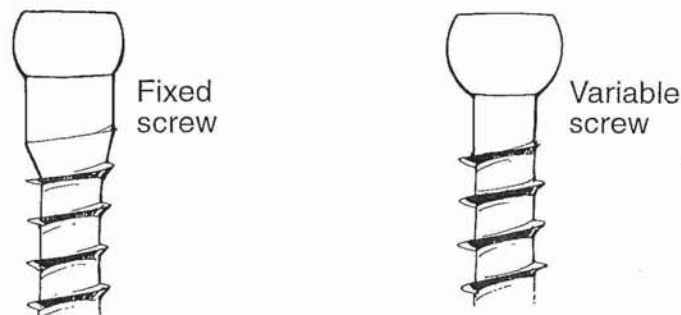


Fig 12. The fixed and variable trajectory screws of the Atlantis system. The configuration of the head and proximal shaft of the fixed screw results in a rigid or constrained interface with the Atlantis plate in contrast to the nonconstrained interface between the variable screw and the Atlantis plate. (Used with permission of Barrow Neurological Institute.)

circumstance, the need to remove the hardware is not absolute and would have to be considered in the context of the patient's related symptoms, if any.

Conclusion

Several anterior cervical plating systems are available for stabilizing and reconstructing a structurally compromised vertebral column. Regardless of what accompanying instrumentation is used, the basis for a successful arthrodesis is meticulous preparation of the bone graft and recipient bed. Rigid internal fixation of the cervical spine significantly improves fusion rates. Several available systems have had clinical success

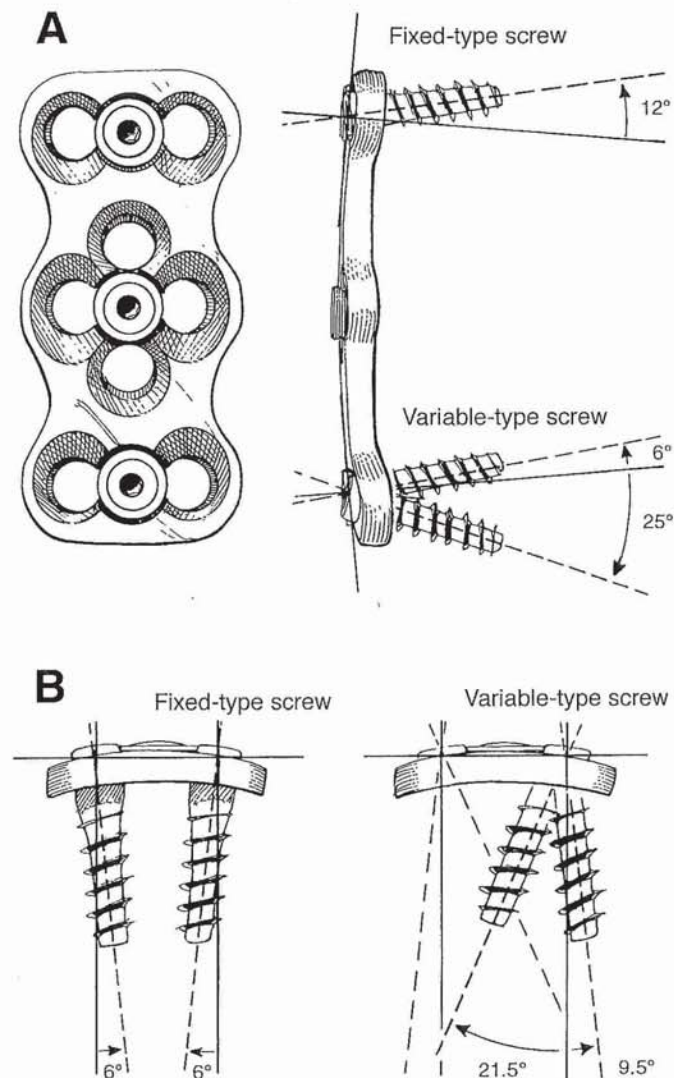
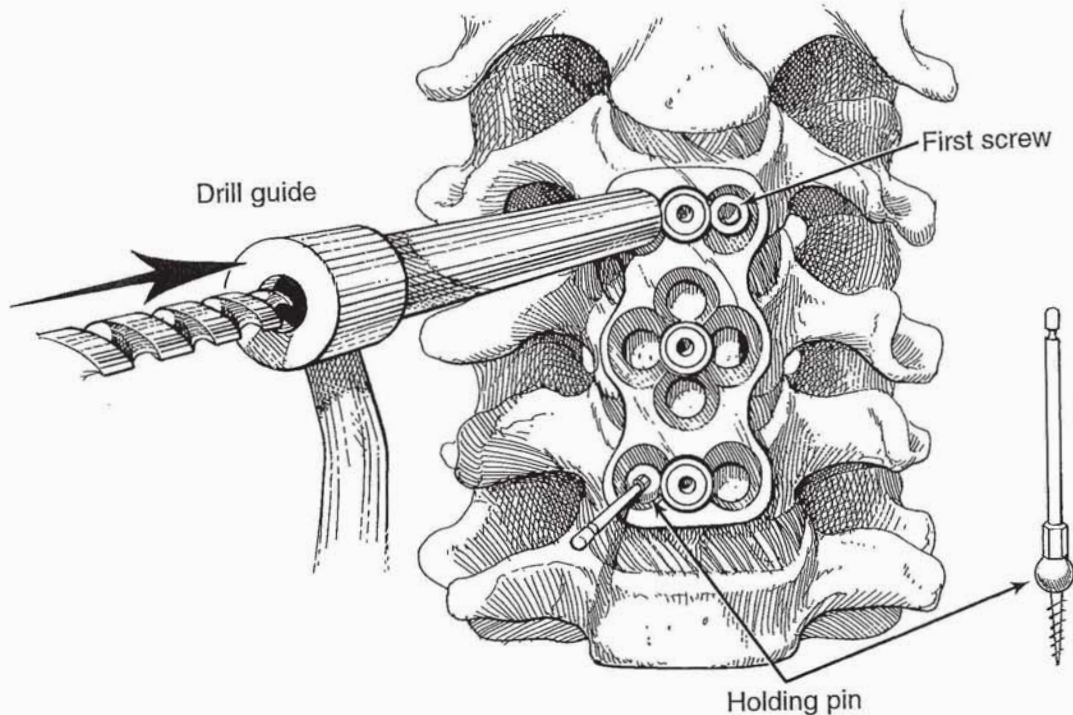


Fig 13. (A) Anterior and sagittal views of the Atlantis plate. The sagittal view shows the fixed screw trajectory angled 12° rostral to a line that is perpendicular to the plate at the rostral screw site and the range of angulation available with the variable screw at the caudal screw site. Because the screw hole is eccentric on the plate, the arc of rotation possible in the sagittal plane is 6° toward the plate relative to a line perpendicular to the plate, or 25° away from this line. (B) Axial view of the Atlantis plate showing the fixed medial (convergent) trajectory of 6° relative to a line drawn perpendicular to the plate and the angulation available with the variable screw (4.0-mm diameter) relative to the same perpendicular line. The degree of angulation possible in the axial and sagittal planes is less with the larger diameter 4.5-mm screw. (Used with permission of Barrow Neurological Institute.)

Fig 14. A holding pin is available with the Atlantis (shown) and Synthes (not shown) plating systems to stabilize the plate while other screw sites are drilled and tapped. In contrast, the plate holders offered by other systems require a surgical assistant to maintain the plate's position steady against the vertebral column. The individual plate holes in the Atlantis system can accommodate either a fixed or variable trajectory drill guide or screw. A locking screw is available for all plate-hole sites. (Used with permission of Barrow Neurological Institute.)



in achieving this purpose. The most recently developed Atlantis plating system provides surgeons the greatest flexibility by accommodating fixed and variable screw trajectories within any one plate-hole site. Consequently, rigid, nonrigid, or hybrid biomechanical constructs can be created based upon the underlying pathologic condition affecting the vertebral column (Fig 15).

A socioeconomic argument for the use of screw-plate systems is that patients who receive these implants may require shorter hospitalizations and return to work earlier than those who undergo cervical fusion procedures without plating. For patients in whom cervical immobilization with a halo orthosis would otherwise be considered necessary after a fusion procedure, internal fixation with a screw-plate system provides a more convenient and comfortable alternative. Moreover, when considering the expense of applying a halo brace and maintaining it for a prolonged period under the care of an orthotist and physician, the cost associated with rigid external fixation is significant. As experience with these implants increases, the differences in operative time between procedures that incorporate plating and those that do not continue to narrow. Later generations of screw-plate systems have become progressively easier to insert, offering the convenience of unicortical bone screw purchase and an integrated locking mechanism to prevent retropulsion of the fixation screws (Fig 16).

A fair comparison of the expense of one instrumentation system compared with another's must account for the price of the individual bone and locking screws that are necessary to secure the construct, in addition to the actual fixation plate. Individual hospital contracts with system manufacturers can dramatically influence the actual cost of inserting one system compared to another. The figures included in Table 3 reflect current manufacturers' catalogue citations. Additional surgeons' fees for performing internal fixation and the expense and radiation exposure associated with the fluoroscopy necessary to perform this procedure safely are additional variables to

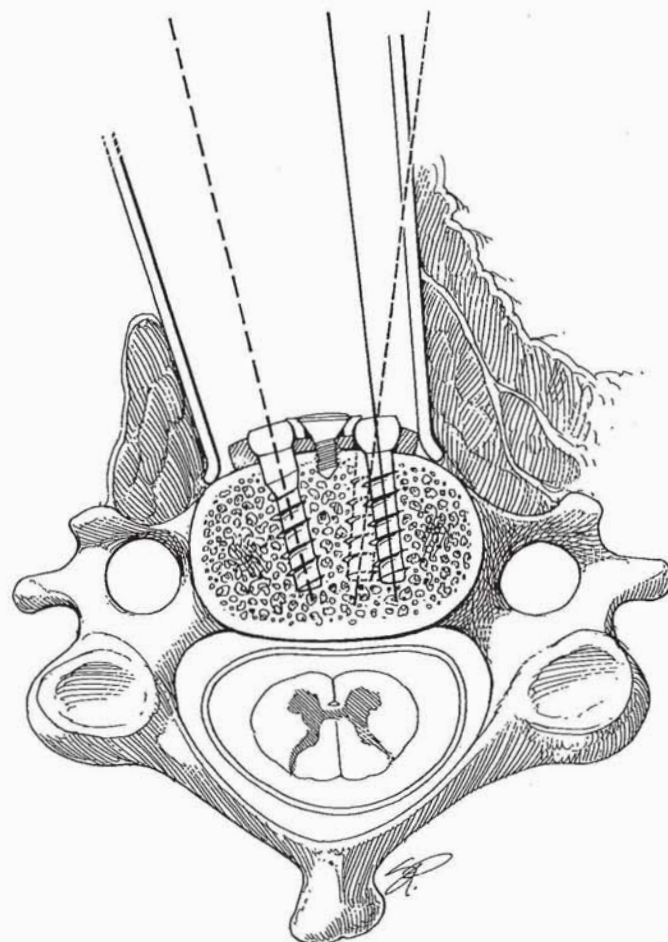


Fig 15. Atlantis plate system with a fixed trajectory screw used at one position and a variable trajectory screw at the neighboring site. This flexibility allows compensation for a patient's aberrant anatomy or for suboptimal screw positions or purchases. Consequently, the biomechanical stability of the fixation construct can be optimized. (Used with permission of Barrow Neurological Institute.)

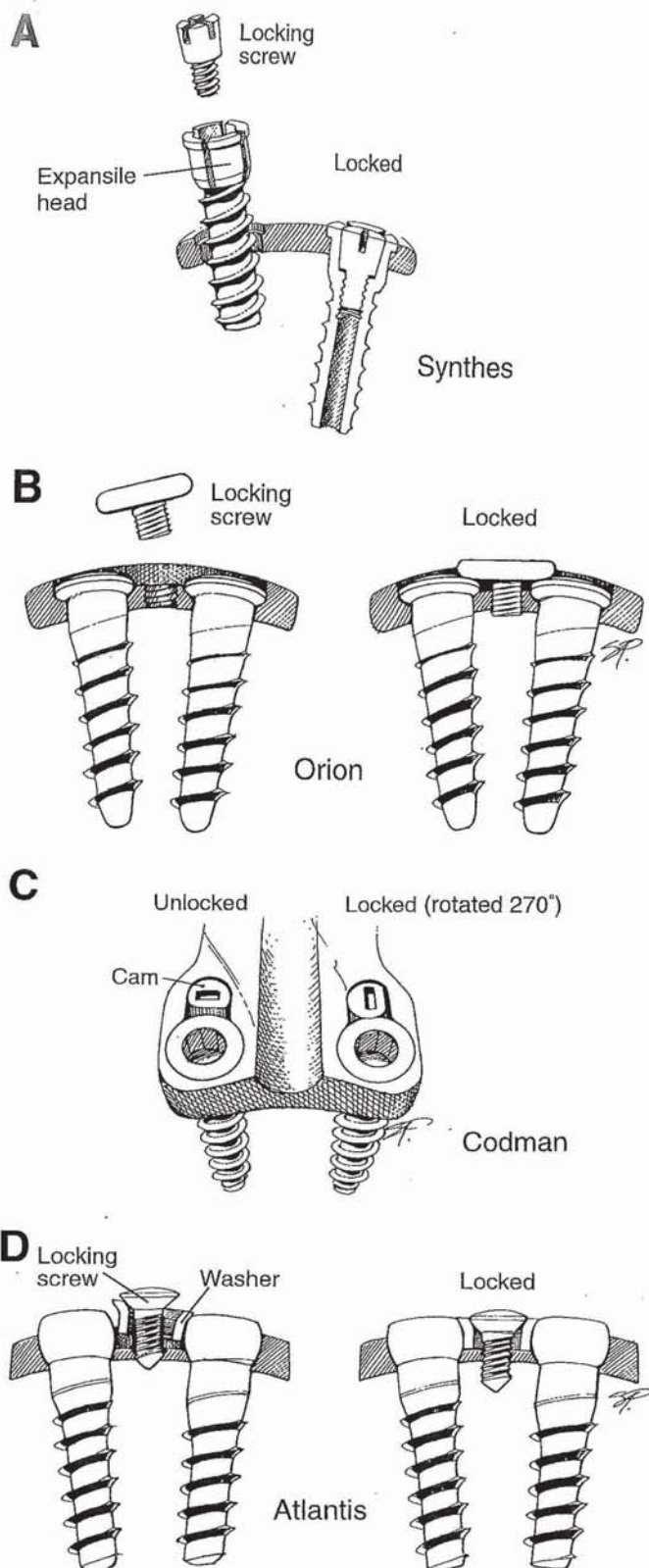


Fig 16. Comparison of the screw-locking mechanisms offered by the (A) Synthes, (B) Orion, (C) Codman, and (D) Atlantis cervical plating systems. (Used with permission of Barrow Neurological Institute.)

consider when calculating the cost-benefit ratio of screw-plate insertion.

Note

Dr. Sonntag has been primarily involved in the development of the two newest cervical plating systems (Codman and Atlantis).

References

1. Denis F: The three column spine and its significance in the classification of acute thoracolumbar spinal injuries. *Spine* 8(8):817-831, 1983
2. Bracken MB, Shepard MJ, Theodore RH, et al: Administration of methylprednisolone for 24 or 48 hours or tirilazad mesylate for 48 hours in the treatment of acute spinal cord injury randomized controlled trial. *JAMA* 277(20):1597-1604, 1997
3. Wolff J, Maquet P, Furlong R: *The Law of Bone Remodeling*. Berlin: Springer-Verlag, 1986
4. Cahill DW: Anterior cervical instrumentation. In Menezes AH, Sonntag VKH (eds): *Principles of Spinal Surgery*. New York, McGraw-Hill, 1996, pp 1105-1120



W.B. SAUNDERS
Elsevier Science

To order reprints, call: 1-215-238-5534; fax 1-215-238-6423
email: gnicholls@harcourt.com