

## Comparison of behavior in muscle fiber regeneration after bupivacaine hydrochloride- and acid anhydride-induced myonecrosis

C. Akiyama<sup>1,2</sup>, S. Kobayashi<sup>1,3</sup>, and I. Nonaka<sup>1</sup>

<sup>1</sup> National Institute of Neuroscience, NCNP, Kodaira, Tokyo 187, Japan

<sup>2</sup> Department of Pediatrics, Fukuoka University, School of Medicine,

<sup>3</sup> Department of Pediatrics, Jichi Medical School,

Received July 22, 1991/Revised, accepted December 2, 1991

**Summary.** We compared the morphologic characteristics of muscle fiber necrosis and subsequent regeneration after injury induced by intramuscular injections of bupivacaine hydrochloride (BPVC) and a variety of solutions at acid and alkaline pH (acetic anhydride, citric acid buffer, and sodium carbonate buffer). After BPVC injection the necrotic muscle fibers were rapidly invaded by phagocytic cells, followed by active regeneration and very little fibrous scar formation. The regenerating muscle fibers increased rapidly in size and attained complete fiber type differentiation and regained their initial fiber diameter within 1 month. Both alkaline and acid solutions induced muscle fiber necrosis followed by regeneration. Fiber necrosis induced by alkaline buffers and acetic anhydride solutions above pH 5.0 produced changes quite similar to that induced by BPVC. However, injection with 0.1 M acetic anhydride at pH below 4.0 resulted in coagulative necrosis of the injured muscle with very little phagocytic infiltration with poor regenerative activity and dense fibrous tissue scarring. Thus, pH 4.0 appears to be the critical pH determining the type of muscle injury and subsequent poor phagocytic and regenerative activities. This model of acidic acetic anhydride injury may lead to the identification of factors which interfere with regeneration and cause fibrous tissue scarring in human muscular dystrophy.

**Key words:** Muscle necrosis – Regeneration – Fibrosis – Bupivacaine – Acid anhydride

Skeletal muscle fibers undergo necrosis after mechanical and chemical injuries including crush, ischemia, cold or heat injuries, and injections of local anesthetics and snake toxins [1, 8]. The necrotic fibers are then invaded and cleared by phagocytic cells followed by an active regenerative process. The mechanism to activate satel-

lite cells, which play an important role in muscle fiber regeneration, is not yet known.

One might ask what environmental factors are necessary to induce phagocytosis, and what the fate of necrotic fibers may be if phagocytosis is less active. To answer these questions we injected various chemicals at different pH into rat muscles and examined the behavior of necrotic and regenerative processes by means of muscle histochemistry with morphometric analysis and electron microscopy. We found that acid anhydride (AA) solution at a pH less than 4.0 caused extensive myonecrosis, with no apparent phagocytic activity and poor regeneration. On the other hand, bupivacaine hydrochloride (BPVC; Marcaine), a local anesthetic, caused necrosis with marked phagocytic activity followed by rapid muscle fiber regeneration [3, 5, 13–16, 20, 23]. We, therefore, carried out a study comparing muscle degenerative and regenerative processes after injury with BPVC and AA to identify factors which promote or inhibit muscle fiber regeneration.

### Materials and methods

Male Wistar rats weighing 200–250 g were used. The right soleus (red) and tibialis anterior (TA; white), muscles were surgically exposed under general anesthesia and various chemical solutions, listed in Table 1, were injected directly into the muscles with a thin gauge needle. The chemical solutions included 0.5 ml 0.5 % BPVC, 0.1 M sodium carbonate at pH varying from 9.0 to 11.0, 0.1 M citric acid at pH 5.0–3.0, 0.1 M AA at pH 3.0, 0.1 M AA solution whose pH was adjusted between 3.0 and 6.0 with 0.1 M NaOH, and 0.5 %–5 % AA in 0.85 % saline. The contralateral soleus and TA muscles of each rat received saline in the same manner and served as controls. In each trial, 2–3 rats were examined.

To study the necrotizing process, the soleus muscles were taken from 2 each of 64 rats at 15 and 30 min, and 1, 2, 6, 12, 24, and 48 h after the injections of BPVC, and 0.1 M AA at pH 3.0, 4.0 and 5.0, respectively. Each muscle was examined by histochemistry and electron microscopy. For electron microscopy, the soleus muscle specimen was fixed in 0.1 M sodium cacodylate-buffered glutaraldehyde solution at pH 7.4 for 3–4 h. The tissue was washed in the same buffer solution, post-fixed in 1 % OsO<sub>4</sub> and embedded in epoxy resin after dehydration in serial alcohol solutions.

Offprint requests to: C. Akiyama (address see <sup>1</sup> above)

**Table 1.** Myotoxic agents

Chemicals	pH	Myonecrosis (48 h)	Phagocytosis (48 h)	Regeneration (10 days)
0.5 % bupivacaine hydrochloride	6.5	+++	+++	F
0.1 M sodium carbonate buffer	9.0, 11.0	+	+++	F
0.1 M citric acid buffer	5.0, 3.0	+++	++	M
0.1 M acetic anhydride buffer	3.0	+++	-	P
0.1 M acetic anhydride + NaOH	3.0	+++	-	P
	4.0	+++	-	P
	4.1	++	++	M
	4.3	+	++	M
	5.0	+	+++	F
0.5 %, 1 %, 3 %, 5 %, acetic anhydride (<pH 3.0)	3.0	+++	-	P

-, none; +, localized; ++, moderate; +++, marked; F, fair; M, moderate; P, poor

To study muscle fiber regeneration, the soleus and TA muscles were taken from 5 animals each at 2, 3, 7, 10, 15, 20, and 30 days after injection from the two groups treated with BPVC and 0.1 M AA at pH 3.0 (total = 70 rats). In 2–3 rats from each of the remaining groups listed in the Table 1, the treated muscles were examined at 2 and 10 days after the injection.

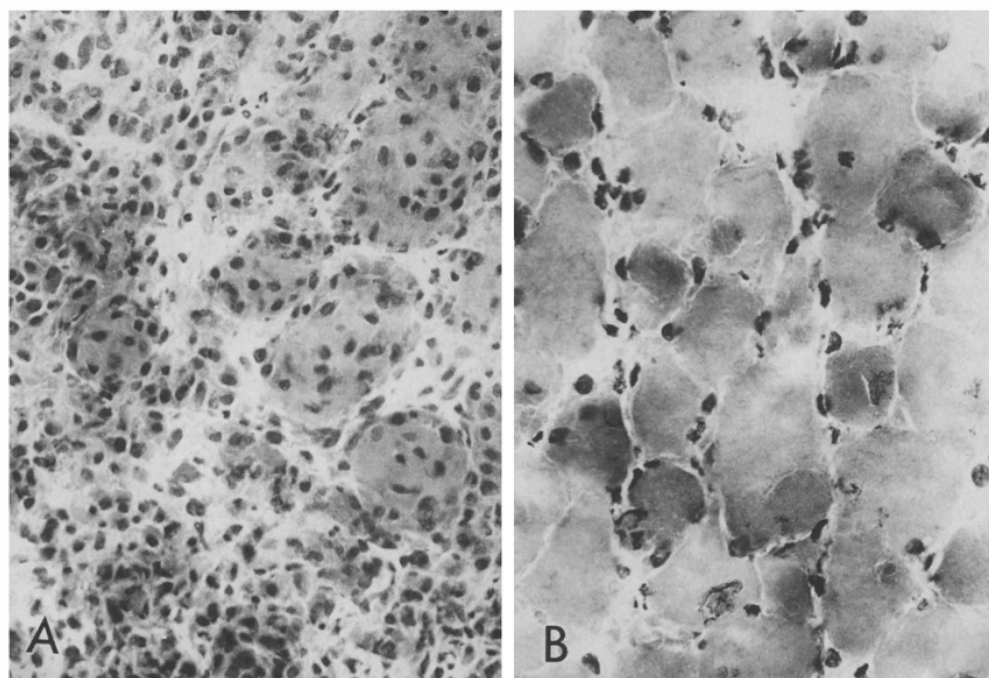
The soleus and TA muscles were immediately frozen in isopentane cooled in liquid nitrogen. Serial frozen sections were stained with hematoxylin and eosin (H&E), modified Gomori trichrome, and a battery of histochemical methods including NADH-TR, routine ATPase and ATPase with preincubation at pH 4.5 and 4.3, acid phosphatase, nonspecific esterase (NSE), and acridine orange (AO). To measure muscle fiber diameters and to

determine fiber types, 100–200 fibers in each muscle were analyzed in photographs from serial frozen sections printed at a final magnification of  $\times 660$ .

## Results

### *Muscle fiber necrosis*

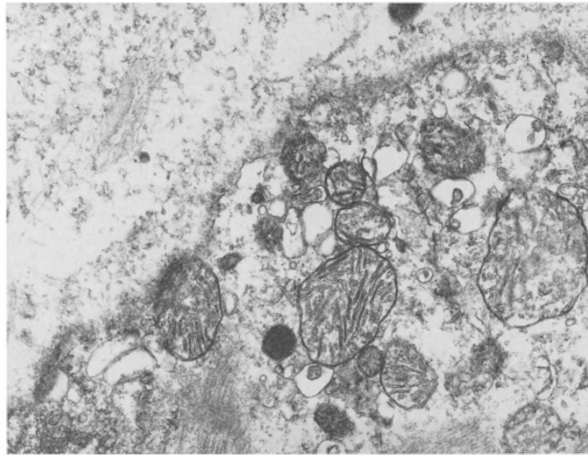
As shown in Table 1, various chemicals (especially BPVC and acidic solutions below pH 4.0) caused muscle fiber necrosis. Immediately after BPVC injection,



**Fig. 1.** Soleus muscles 48 h after bupivacaine hydrochloride (BPVC) (A) and acid anhydride (AA) at pH 3.0 (B) injections. Numerous necrotic fibers are invaded by phagocytic cells in the BPVC-treated muscle (A). Although the contour of fibers is

preserved, myofibrillar networks have disappeared and myonuclei were granulated (B). Note no macrophage invasion in extra- and intracellular spaces (B). A, B H&E,  $\times 240$

almost all the muscle fibers in the treated soleus and TA underwent massive necrosis characterized by opaque fibers and empty sarcolemmal tubes, with foci of hypercontraction bands on longitudinal sections. The necrotic fibers were invaded by acid phosphatase-positive macrophages within 12 h after the injection. At 24 and 48 h, the necrotic fibers and the extracellular space were filled with numerous mononuclear phagocytic cells as well as some polymorphonuclear leukocytes (Fig. 1A).



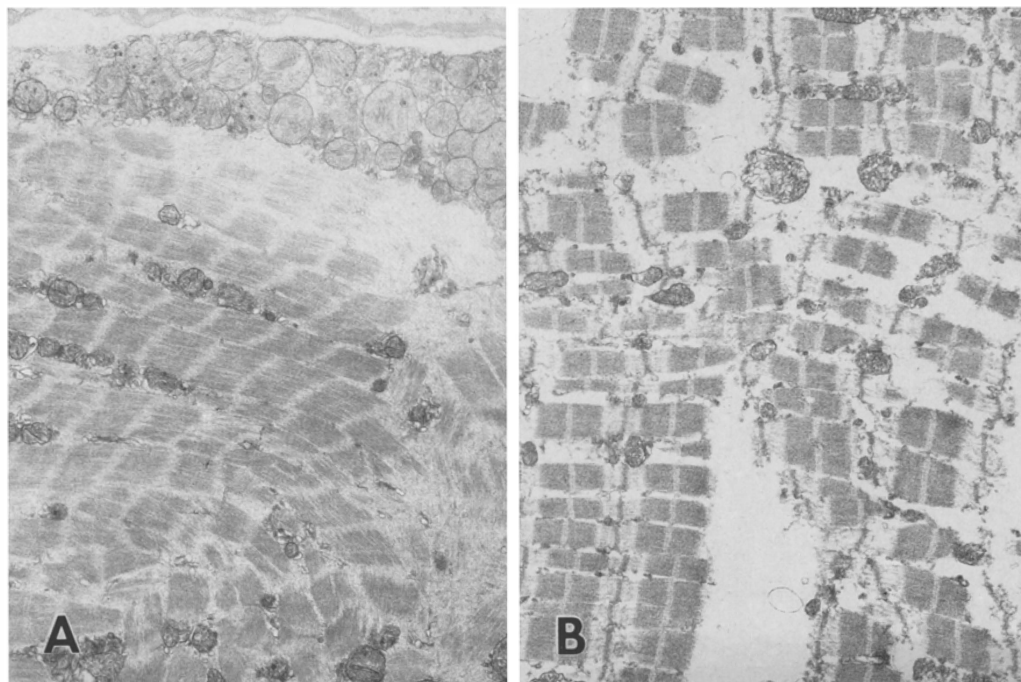
**Fig. 2.** An electron micrograph of a necrotic fiber 15 min after AA at pH 5.0 injection. The myofibrils are disrupted and organelles swollen. The sarcolemma has focally disappeared.  $\times 24\,000$

Almost all the muscle fibers treated with citric acid and sodium carbonate buffers, AA and AA buffers showed extensive necrosis. The appearance of the necrotic fibers treated with citric and sodium carbonate buffers was similar to those seen in BPVC-treated soleus muscles.

On the other hand, in the muscle injected with AA below pH 4.0 and AA buffer at pH 3.0 the necrotic muscle fibers had faintly staining cytoplasm with loss of the intermyofibrillar networks and myonuclei. Muscle fiber necrosis after 0.5 %, 1 %, 3 %, and 5 % AA injections had a similar appearance. In the muscles treated with such strong acidic solutions, the contour of necrotic fibers remained unchanged with little phagocytic activity even 24 and 48 h after injection (Fig. 1B). The blood vessels and peripheral nerve bundles in the interstitium were not clearly identifiable.

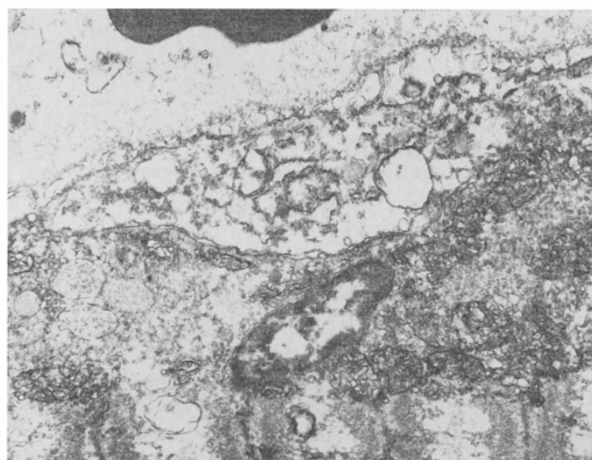
#### *Electron microscopy of necrotic fibers*

Fifteen minutes after BPVC and 0.1 MAA at pH 4.0 and 5.0 injections, electron microscopy revealed disruption of the myofibrils with the formation of hypercontraction bands, and the sarcoplasmic reticulum appeared to be dilated (Fig. 2). There was focal loss of plasmalemma. At 2 h, myofibrils were fragmented at the level of the Z-line (Fig. 3A). The basal lamina and satellite cells were well preserved at all stages. At 48 h, many phagocytic cells were found in the extra- and intracellular spaces, and satellite cells were activated.

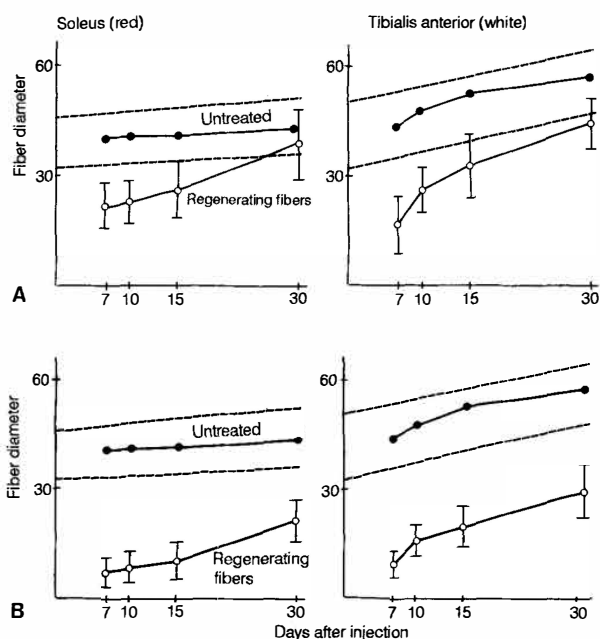


**Fig. 3.** Soleus muscle 2 h after AA at pH 5.0 (A) and at 3.0 (B) injections. Myofibrils are fragmented from a selective Z-line dissolution (A). The myofibrils are fragmented at various levels of the sarcomeres including the Z-line, A and I bands (B). A, B  $\times 6\,000$

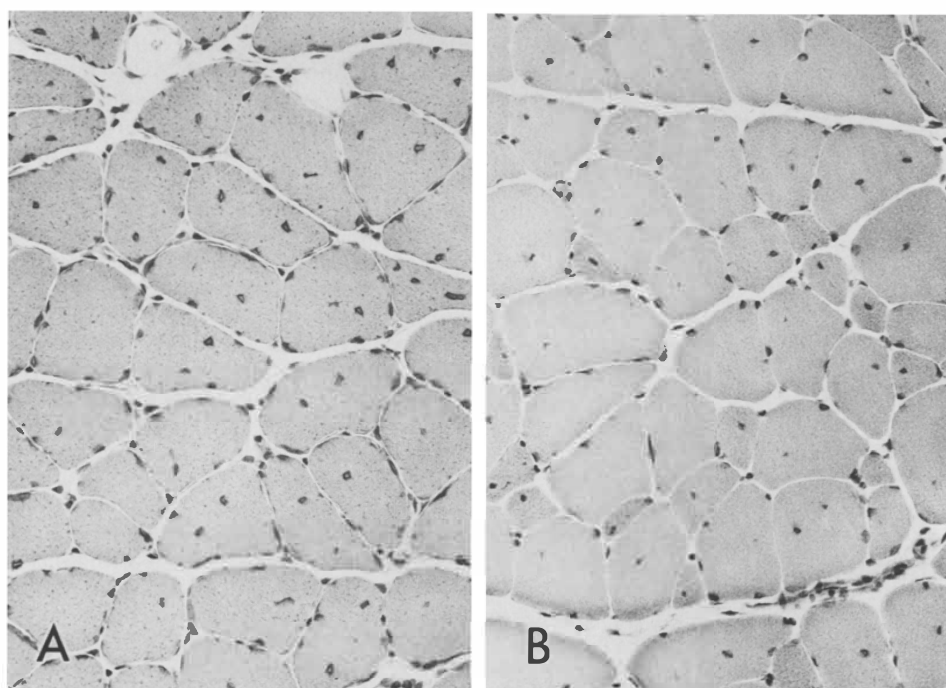
In the muscle treated with 0.1 M AA at pH 3.0, there was disruption of both the basal lamina and plasma membrane 15 min after the injection. There was degeneration of both muscle fibers and satellite cell nuclei with loss of chromatin granules (Fig. 4). At 2 h, the myofibrils were fragmented at different levels of the myofibrils



**Fig. 4.** Soleus muscle 15 min after AA at pH 3.0 injection. The basal lamina and plasma membrane have disappeared. Satellite cells are also degenerated.  $\times 12\,000$



**Fig. 5.** Although the regenerating fibers (—○—) treated with BPVC (**A**) rapidly recovered and regained their initial size in both soleus (red) and tibialis anterior (white) muscles, when treated with AA solution at pH 3.0 (**B**) they showed markedly delayed recovery. One standard deviation of the mean control (untreated) fiber diameter (—●—) is indicated by dotted lines



**Fig. 6 A, B.** At 30 days after BPVC injection. Centrally placed nuclei are seen in almost all of the regenerating fibers in both soleus (**A**) and tibialis anterior (**B**) muscles. H&E,  $\times 240$

including the Z-line, A and I bands (Fig. 3B). Even 48 h after the injection, no phagocytic cells had appeared and the fragmented myofibrils remained unchanged from those at 2 h.

Muscle fiber degeneration in the soleus muscles treated with these three different chemicals is summarized in Table 1.

### *Muscle fiber regeneration*

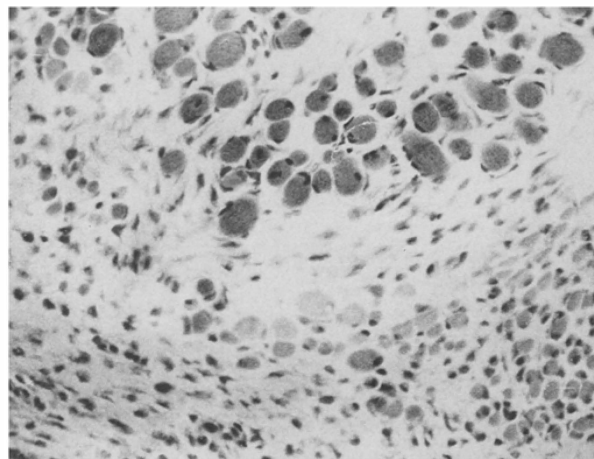
In BPVC-treated TA and soleus muscles, small caliber regenerating fibers with basophilic cytoplasm and centrally placed vesicular nuclei appeared in a pool of mononuclear cells 72 h after the injection on H&E.

After 7 days, numerous regenerating fibers characterized by basophilic cytoplasm, vesicular nuclei and prominent nucleoli were clearly identifiable. The regenerating fibers regained their initial diameter within 30 days, but the recovery of the white muscle was slightly slower than that of the red muscle (Fig. 5). At 30 days, almost all of the regenerating fibers still retained their centrally placed nuclei (Fig. 6).

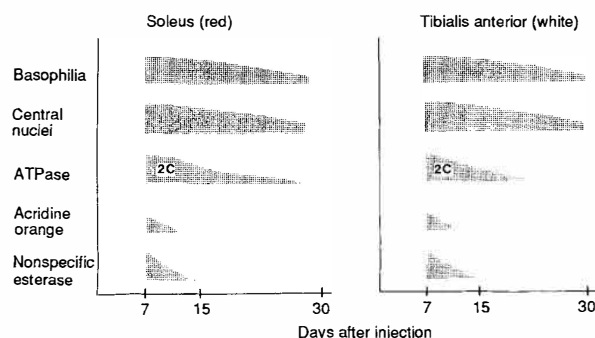
As expected from the behavior of myonecrosis, there was a marked delay in muscle fiber regeneration in necrotic muscles treated with strong AA solution below pH 4.0. Seven days after the injection, there were only a few small fibers with histologic characteristics of regenerating fibers and numerous necrotic fibers with very little phagocytic activity remained. Fifteen days after AA injection, regenerating fibers were still of small caliber and they were embedded in the fibrotic tissue scar (Fig. 7).

### *Histochemical characteristics of regenerating fibers*

The histochemical characteristics of regenerating fibers in soleus and TA muscles treated with BPVC are



**Fig. 7.** Soleus muscle 30 days after AA at pH 3.0 injection. The regenerating fibers are small with variation in fiber size. Note increased fibrous tissue proliferation. H&E,  $\times 240$



**Fig. 8.** Except for slightly delayed muscle fiber type differentiation on ATPase staining, there are no histochemical differences in regenerating fibers between white and red muscle

summarized in Fig. 8. At 3 days, small regenerating fibers already showed strong orange fluorescence with AO staining, and high enzyme activities for NSE, acid phosphatase and NADH-TR. AO-positive fibers were no longer found at 15 days. The activities of acid phosphatase and NSE returned to normal by 15 days. Regenerating fibers initially had the characteristics of undifferentiated type 2C fibers by ATPase staining, and they began to differentiate at 10 days in TA and at 15 days in soleus. Fiber type differentiation was completed by 20 days in TA and by 30 days in soleus (Fig. 8).

### **Discussion**

There have been a number of reports indicating that regenerative activity of muscle fibers following necrosis is best studied in BPVC-induced muscle injury, because BPVC preferentially damages the muscle membrane but spares the basement membrane, blood vessels and peripheral nerves [3, 20, 23]. Red muscle fibers are more susceptible to BPVC damage than white [3]. The regenerating fibers are almost uniform in size, and the total regenerative process is readily reproducible [20].

To determine the histologic profiles of necrotic and regenerating fibers after myonecrosis in both red and white muscles, we injected BPVC into the rat soleus (red) and TA (white) muscles. The behavior of muscle fiber regeneration in the present study is quite similar to that seen in chicken muscle treated with BPVC [21].

To identify the factors which reduce regenerative capacity we injected various alkaline and acid solutions into the rat muscles. Except for strong acidic solutions including AA below pH 4.0 and AA buffer solution at pH 3.0, all solutions induced myonecrosis with phagocytosis followed by rapid regeneration, as seen in BPVC-treated muscles. Our study confirmed that 0.1 M AA below pH 4.0 induced myonecrosis, but interfered with factors which stimulate phagocytic activity. Less active phagocytosis appeared to inhibit muscle fiber regeneration, whereas massive phagocytosis in BPVC-injured muscle induced rapid fiber regeneration, sug-

gesting that persistence of necrotic material inhibits the following regeneration [12].

The basal lamina and satellite cells in muscles treated with BPVC and AA at pH 5.0 were well preserved, with preferential damage to the muscle membrane and dissolution of the myofibrils at the Z-line, probably induced by a certain proteolytic process. On the other hand, in muscles treated with strong acidic solution below pH 4.0, all intracellular organelles, satellite cells, and blood vessels were damaged, and myofibrils were disrupted at various levels of the sarcomere. The process of muscle fiber damage induced by the strong acidic solution is not proteolytic in nature but causes coagulation of the protein. Following coagulative necrosis of muscle fibers, phagocytosis is limited, regenerative activity is reduced, and dense interstitial fibrosis follows. The necrotizing process in BPVC- and pH 5.0 AA-injured muscles was similar to that seen in various muscle diseases including progressive muscular dystrophy [4, 6, 9, 19, 22].

Muscle fiber regeneration in muscle treated with alcohol/oil emulsion was slower than that in BPVC-treated muscles [10], fibrous tissue was increased in amount, and most muscle fibers in the regenerating region were still small 6 weeks after injury. Fibrous tissue proliferation also occurs after crush injury [18], after repeated injections of chlorpromazine [7] and even local anesthetics [2, 5]. Thus, delayed regenerative velocity may induce interstitial fibrous tissue proliferation or vice versa.

In progressive muscular dystrophy, the disease progresses without interruption despite an active regenerative process because muscle fiber degeneration is not fully compensated by muscle fiber regeneration. Certain environmental factors, including interstitial fibrosis which impairs the blood supply to individual regenerating fibers, are probably responsible for reducing the regenerative capacity [17]. As suggested from the present study, the slow regenerative velocity might induce further interstitial fibrosis. This vicious cycle seems to be responsible for progression in progressive muscular dystrophy.

## References

- Allbrook D (1981) Skeletal muscle regeneration. *Muscle Nerve* 4:234-245
- Basson MD, Carlson BM (1980) Myotoxicity of single and repeated injections of mepivacaine (Carbocaine) in the rat. *Anesth Analg* 59:275-282
- Benoit PW, Belt WD (1970) Destruction and regeneration of skeletal muscle after treatment with a local anesthetic, bupivacaine (Marcaine). *J Anat* 107:547-556
- Bonilla E, Schotland DL, Wakayama Y (1978) Duchenne dystrophy: focal alterations in the distribution of concanavalin A binding sites at the muscle cell surface. *Ann Neurol* 4:117-123
- Bradley WG (1979) Muscle fiber splitting. In: Mauro A (ed) *Muscle regeneration*. Raven Press, New York, pp215-232
- Bradley WG, Fulthorpe JJ (1978) Studies of sarcolemmal integrity in myopathic muscle. *Neurology* 28:670-677
- Brumback RA, Empting L, Susag ME, Staton RD (1982) Muscle fibrosis associated with intramuscular chlorpromazine administration. A preliminary report. *J Pharm Pharmacol* 34:526-528
- Carlson BM (1973) The regeneration of skeletal muscle - a review. *Am J Anat* 137:119-150
- Carpenter S, Karpati G (1979) Duchenne muscular dystrophy. Plasma membrane loss initiates muscle cell necrosis unless it is repaired. *Brain* 102:147-161
- Dhoot GK, Perry SV (1982) Changes in the forms of the components of the troponin complex during regeneration of injured skeletal muscle. *Muscle Nerve* 5:39-47
- Grim M, Rerabkova L, Carlson BM (1988) A test for muscle lesions and their regeneration following intramuscular drug application. *Toxicol Pathol* 16:432-442
- Grounds MD (1987) Phagocytosis of necrotic muscle in muscle isografts is influenced by the strain, age, and sex of host mice. *J Pathol* 153:71-82
- Hall-Craggs ECB (1974) Rapid degeneration and regeneration of a whole skeletal muscle following treatment with bupivacaine (Marcaine). *Exp Neurol* 43:349-458
- Hall-Craggs ECB, Seyan HS (1975) Histochemical changes in innervated and denervated skeletal muscle fibers following treatment with bupivacaine (Marcaine). *Exp Neurol* 46:345-354
- Jirmanova S, Thesleff S (1972) Ultrastructural study of experimental muscle degeneration and regeneration in the adult rat. *Z Zellforsch* 131:77-97
- Jones GH (1982) Protein synthesis in bupivacaine (Marcaine)-treated, regenerating skeletal muscle. *Muscle Nerve* 5:281-290
- Lipton BH (1979) Skeletal muscle regeneration in muscular dystrophy. In: Mauro A (ed) *Muscle regeneration*. Raven Press, New York, pp 31-40
- McGeachie JK, Grounds MD (1987) Initiation and duration of muscle precursor replication after mild and severe injury to skeletal muscle of mice. *Cell Tissue Res* 248:125-130
- Mokri B, Engel AG (1975) Duchenne dystrophy: electron microscopic findings pointing to a basic or early abnormality in the plasma membrane of the muscle fiber. *Neurology* 25:1111-1120
- Nonaka I, Takagi A, Ishiura S, Nakase H, Sugita H (1983) Pathophysiology of muscle fiber necrosis induced by bupivacaine hydrochloride (Marcaine). *Acta Neuropathol (Berl)* 60:167-174
- Nonaka I, Fujita T, Sugita H (1984) Regenerative capability of skeletal muscle in chicken muscular dystrophy. *Muscle Nerve* 7:400-407
- Schmalbruch H (1975) Segmental fibre breakdown and defects of the plasmalemma in diseased human muscles. *Acta Neuropathol (Berl)* 33:129-141
- Sokoll MD, Sonosson B, Thesleff S (1968) Denervation changes produced in an innervated skeletal muscle by long-continued treatment with a local anesthetic. *Eur J Pharmacol* 4:179-187