
Photodynamic therapy for acne vulgaris: A critical review from basics to clinical practice

Part II. Understanding parameters for acne treatment with photodynamic therapy

Fernanda H. Sakamoto, MD,^{a,b} Luis Torezan, MD,^c and R. Rox Anderson, MD^a
Boston, Massachusetts, and São Paulo, Brazil

Photodynamic therapy requires a photosensitizer, oxygen, and activating light. For acne, pilosebaceous units are “target” structures. Porphyrins are synthesized in vivo from 5-aminolevulinic acid (ALA), particularly in pilosebaceous units. Different photosensitizers and drug delivery methods have been reported for acne treatment. There are a variety of porphyrin precursors with different pharmacokinetic properties. Among them, ALA and methyl-ester of ALA (MAL) are available for possible off-label treatment of acne vulgaris. In addition, various light sources, light dosimetry, drug incubation time, and pre- and posttreatment care also change efficacy and side effects. None of these variables has been optimized for acne treatment, but a number of clinical trials provide helpful guidance. In this paper, we critically analyze clinical trials, case reports, and series of cases published through 2009. (J Am Acad Dermatol 2010;63:195-211.)

Learning objectives: After completing this learning activity, participants should be able to analyze photodynamic therapy using 5-aminolevulinic acid and its derivatives for acne treatment, predict the effectiveness and outcomes of photodynamic therapy using different parameters and/or different porphyrin-related photosensitizers, and assess and manage the side effects of porphyrin-based photodynamic therapy for acne.

Key words: adverse effects; 5-aminolevulinic acid; lasers; light; methyl 5-aminolevulinate; photodynamic therapy; porphyrins; therapeutics.

Over the past decade, several papers have been published about photodynamic therapy (PDT) using 5-aminolevulinic acid (ALA) or methyl-aminolevulinate (MAL) for acne vulgaris. Despite the enthusiasm for new treatment alternatives, it is clear that there is no consensus

about treatment parameters to target of acne sebaceous glands.

PDT drug delivery methods, choice of photosensitizer, skin preparation, light sources, and light dosimetry/irradiance may affect efficacy and side effects. Understanding the science behind treatment methods may increase efficacy and long-term acne remission. This review is a critical analysis of all clinical papers on the subject of PDT for acne. Table I summarizes the clinical studies, case reports, and series of cases published through 2009 regarding PDT for acne.

5-AMINOLEVULINIC ACID VERSUS 5-AMINOLEVULINIC ACID DERIVATIVES

Key points

- 5-aminolevulinic acid (ALA) and ALA derivatives have different mechanisms of cell uptake and transport
- While ALA is hydrophilic, most ALA derivatives are hydrophobic

From the Wellman Center for Photomedicine,^a Massachusetts General Hospital, Harvard Medical School, Boston, and the Departments of Dermatology at the Universidade Federal de São Paulo,^b Escola Paulista de Medicina (UNIFESP-EPM), and the Faculdade de Medicina da Universidade de São Paulo (FMUSP),^c São Paulo, Brazil.

Funding sources: None.

Conflicts of interest: The authors, editors, JAAD CME council members, and peer reviewers have no relevant financial relationships.

Reprint requests: Richard Rox Anderson, MD, Wellman Center for Photomedicine, Massachusetts General Hospital, 55 Fruit St, BHX 630, Boston, MA 02114. E-mail: rranderson@partners.org. 0190-9622/\$36.00

© 2010 by the American Academy of Dermatology, Inc.

doi:10.1016/j.jaad.2009.09.057

Biofrontera Exhibit 1006
Biofrontera Inc. et al. v. DUSA Pharmaceuticals, Inc.
IPR2022-00056

Photodynamic therapy for acne vulgaris: A critical review from basics to clinical practice

Part II. Understanding parameters for acne treatment with photodynamic therapy

Fernanda H. Sakamoto, MD,^{a,b} Luis Torezan, MD,^c and R. Rox Anderson, MD^a
Boston, Massachusetts, and São Paulo, Brazil

Photodynamic therapy requires a photosensitizer, oxygen, and activating light. For acne, pilosebaceous units are “target” structures. Porphyrins are synthesized in vivo from 5-aminolevulinic acid (ALA), particularly in pilosebaceous units. Different photosensitizers and drug delivery methods have been reported for acne treatment. There are a variety of porphyrin precursors with different pharmacokinetic properties. Among them, ALA and methyl-ester of ALA (MAL) are available for possible off-label treatment of acne vulgaris. In addition, various light sources, light dosimetry, drug incubation time, and pre- and posttreatment care also change efficacy and side effects. None of these variables has been optimized for acne treatment, but a number of clinical trials provide helpful guidance. In this paper, we critically analyze clinical trials, case reports, and series of cases published through 2009. (J Am Acad Dermatol 2010;63:195-211.)

Learning objectives: After completing this learning activity, participants should be able to analyze photodynamic therapy using 5-aminolevulinic acid and its derivatives for acne treatment, predict the effectiveness and outcomes of photodynamic therapy using different parameters and/or different porphyrin-related photosensitizers, and assess and manage the side effects of porphyrin-based photodynamic therapy for acne.

Key words: adverse effects; 5-aminolevulinic acid; lasers; light; methyl 5-aminolevulinate; photodynamic therapy; porphyrins; therapeutics.

Over the past decade, several papers have been published about photodynamic therapy (PDT) using 5-aminolevulinic acid (ALA) or methyl-aminolevulinate (MAL) for acne vulgaris. Despite the enthusiasm for new treatment alternatives, it is clear that there is no consensus

about treatment parameters to target of acne sebaceous glands.

PDT drug delivery methods, choice of photosensitizer, skin preparation, light sources, and light dosimetry/irradiance may affect efficacy and side effects. Understanding the science behind treatment methods may increase efficacy and long-term acne remission. This review is a critical analysis of all clinical papers on the subject of PDT for acne. Table I summarizes the clinical studies, case reports, and series of cases published through 2009 regarding PDT for acne.

5-AMINOLEVULINIC ACID VERSUS 5-AMINOLEVULINIC ACID DERIVATIVES

Key points

- 5-aminolevulinic acid (ALA) and ALA derivatives have different mechanisms of cell uptake and transport
- While ALA is hydrophilic, most ALA derivatives are lipophilic, making it easier for passive cell transport. However, ALA derivatives

From the Wellman Center for Photomedicine,^a Massachusetts General Hospital, Harvard Medical School, Boston, and the Departments of Dermatology at the Universidade Federal de São Paulo,^b Escola Paulista de Medicina (UNIFESP-EPM), and the Faculdade de Medicina da Universidade de São Paulo (FMUSP),^c São Paulo, Brazil.

Funding sources: None.

Conflicts of interest: The authors, editors, JAAD CME council members, and peer reviewers have no relevant financial relationships.

Reprint requests: Richard Rox Anderson, MD, Wellman Center for Photomedicine, Massachusetts General Hospital, 55 Fruit St, BHX 630, Boston, MA 02114. E-mail: rranderson@partners.org. 0190-9622/\$36.00

© 2010 by the American Academy of Dermatology, Inc.

doi:10.1016/j.jaad.2009.09.057

need an extra step of metabolism to be converted into ALA and then into porphyrins

- **In general, high-dose photodynamic therapy with long incubation, high fluence red light activation works similarly for both ALA and ALA derivatives**
- **Oral administration of ALA has been reported for acne treatment, but can be associated with systemic side effects and generalized phototoxicity**

In the United States and South America, 5-ALA is available in 20% hydroalcoholic solution and marked as Levulan Kerastick (Dusa Pharmaceuticals, Wilmington, MA) for treatment of actinic keratosis followed by blue light exposure. Methyl aminolevulinate hydrochloride is the methyl-ester of ALA (MAL) in a cream formulation. MAL is marketed as Metvix (produced by Photocure ASA, Oslo, Norway, and marketed by Galderma SA in Europe, Australia, and South America for the treatment of actinic keratosis and, depending on the country, for treating Bowen disease and superficial basal cell carcinoma) or as Metvixia (in the United States, marketed by Galderma SA for the treatment of actinic keratosis with red light exposure). It is labeled either as 16% or 16.8% concentration in different countries, depending whether the hydrochloride is included in molecular weight. Lower concentrations of MAL (2, 4, and 8%) are being tested in phase I and phase II clinical trials for acne treatment, but no publications are available thus far. More recently, the hexyl-ester of ALA has been approved in Europe for bladder cancer treatment (Hexvix 85-mg powder for intravesical use; produced by Photocure ASA, Oslo, Norway, and

marketed by Galderma SA), but this compound has not yet been studied for acne. Other derivatives are not yet marketed.

Mechanisms of ALA cell uptake involve transmembrane channels and active transport. ALA is a naturally occurring amino acid with a balance of hydrophilic and lipophilic properties that allows

diffusion in and out of biomembranes.¹ ALA is a largely hydrophilic zwitterion (a neutral molecule carrying both positively and negatively charged groups) which facilitates plasma membrane penetration.² ALA esters were developed to increase drug penetration by adding aliphatic alcohols to the carbohydrate chains and modifying the alkyl chain length, and to formulate new, patentable molecules. However, if a highly lipophilic drug is added to a lipophilic vehicle (cream or ointment), it tends to be retained in the vehicle rather than partitioning into skin, and uptake is reduced.¹ Those ALA derivatives with long lipophilic side chains may also suffer delay in uptake because of retention in stratum corneum and/or a higher molecular weight.¹ Figure 1 summarizes the lipophilic properties of ALA and its derivatives.¹ Ultimately, only the ethyl, propyl, and methyl esters of ALA have successfully improved porphyrin formation upon topical application to intact skin in vivo.^{1,3} Some studies using the topical hexyl ester of ALA in skin failed, possibly because it was used within a lipophilic vehicle, suggesting that a hydrogel vehicle may

be more appropriate for the more lipophilic esters.¹

In addition to differences in uptake related to physicochemical properties, it was also observed in different cultured cell lines that uptake of ALA and its various esters follow different active transport pathways. 5-ALA is a beta amino acid that enters cells in part via active transport mechanisms, such as PEPT1

CAPSULE SUMMARY

- Porphyrin precursors (5-aminolevulinic acid [ALA] or esters of ALA) delivered topically or orally have been studied for photodynamic therapy (PDT) of acne.
- PDT for acne has not been optimized, including topical preparation, dose-response, conditions for metabolism to porphyrins, and light exposure.
- Ester derivatives of ALA, such as methyl-ester of ALA (MAL), are converted into ALA after uptake to skin. Different biodistributions occur among ALA derivatives because of lipophilicity and cell membrane transport mechanisms.
- Porphyrin precursors require an incubation period for metabolism. Longer incubation times (≥ 3 hours) are associated with long-term acne remission.
- When used with high-dose conditions (long incubation time, high fluence red light exposure), ALA PDT and MAL PDT have been shown to produce similar effects for acne treatment.
- For PDT activation, continuous wave, high intensity red light sources have deeper penetration and are more likely to produce sebaceous gland destruction compared with blue light or pulsed light sources.
- Topical ALA PDT or MAL PDT is often painful, causes inflammatory side effects, and may cause residual photosensitivity.

Table I. Publications between 2000 and 2008 of 5-aminolevulinic acid and methyl aminolevulinate hydrochloride photodynamic therapy for the treatment of acne vulgaris

	Hongcharu, 2000 ¹⁸	Itoh, 2000 ⁴⁰	Itoh, 2001 ²³	Goldman, 2003 ³⁵	Pollock, 2004 ⁴¹	Gold, 2004 ²⁶	Taub, 2004 ²⁷	Kimura, 2004 ¹⁵	Hong, 2005 ⁴²
Drug	20% ALA topical	20% ALA topical	20% ALA topical	20% ALA topical	20% ALA topical	20% ALA topical	20% ALA topical + salicylic acid peeling over 4 weeks	Oral ALA 10 mg/kg	20% ALA topical (only in acne spots)
Control group?	Yes; blinded assessment	Yes (compared to rest of the face that was not treated); not blinded assessment	No; not blinded assessment	No (compared to blue light only group), not blinded assessment	Yes (same patients received treatments and controls); not blinded assessment	No; not blinded assessment	No; not blinded assessment	No; not blinded assessment	Yes (split-face ALA-PDT vs controls); blinded assessment (?)
No. of patients/ acne location	22/Back	1/Face	13/Face	22 (12 blue light vs 10 ALA-PDT)/Face	10/Back	15	18	51/Body	8/Face
Acne type	Inflammatory, mild to moderate	Inflammatory	3 Comedonal (NI); 10 inflammatory	Inflammatory, mild to moderate	Inflammatory, mild to moderate	Inflammatory, moderate to severe	Inflammatory, moderate to severe	Intractable (?)	Inflammatory, mild to moderate
Pretreatment	70% Isopropyl alcohol	Not mentioned	Not mentioned	2% Salicylic acid cleanser	Not mentioned	Cetaphil cleanser	Acetone scrub and alcohol scrub	Not mentioned	70% Isopropyl alcohol
Time of incubation	3 hrs under occlusion	4 hrs under occlusion, light covered	4 hrs under occlusion, light covered	15 min	3 hrs under occlusion	1 hr	15-30 min, not standardized	4 hrs	4 hrs under occlusion, light covered
Light sources	Broad-spectrum (550-700 nm), 150 J/cm ²	Pulsed excimer dye laser (635 nm), 5 J/cm ²	Broad-spectrum (600-700 nm) halogen lamp at 17 mW/cm ² , 13 J/cm ²	Blue 417 ± 5 nm, 10 mW/cm ² , 3.6 J/cm ²	Diode laser (635 nm), 25 mW/cm ² , 15 J/cm ²	IPL (430-110 nm), 3-9 J/cm ² + heat	Blue (417-420 nm) OR blue 417 ± 5 nm (1.8-4.2 J/cm ² at 10 mW/cm ²) OR IPL (400-980 nm), 18-25 J/cm ² + radiofrequency 18-20 J/cm ² , no standardized fluences	Metal halide (540-800 nm), 69.2 mW/cm ² , 60-80 J/cm ²	Halogen lamp red (630 ± 63 nm), 30 mW/cm ² , 18 J/cm ²
No. of PDT sessions	Two randomized groups: 1 vs 4 sessions (1-wk apart)	1	1	2	3 (1-wk apart)	4 (1 wk apart)	2-4 (4-8 wks apart), not standardized	2 (2-4 wks apart)	1
Total follow-up time	20 wks after the last treatment	32 wks	24 wks after the last treatment	2 wks	3 wks	12 wks	4-32 wks, not standardized	12 wks	24 mos

Continued

Table I. Cont'd

	Hongcharu, 2000 ¹⁸	Itoh, 2000 ⁴⁰	Itoh, 2001 ²³	Goldman, 2003 ³⁵	Pollock, 2004 ⁴¹	Gold, 2004 ²⁶	Taub, 2004 ²⁷	Kimura, 2004 ¹⁵	Hong, 2005 ⁴²
Efficacy rate [†]	Four sessions better than 1. After 20 wks, reduction of ~50% of acne after 4 sessions ($P < .05$). ~30% reduction with only one session. Global acne improvement, sebum reduction, and autofluorescence statistically significant compared to other control sites	Complete remission, with no new lesions	100% of patients with some improvement; 13/13 patients with no new lesions after 1 mo; 5/13 without new lesions after 3 mos and 6 mos all patients had new lesions	68% (PDT) reduction of inflammatory lesions vs 40% (blue light) and 62% reduction of NI lesions. 32% (ALA-PDT) vs 25% (blue only) improvement in severity of acne	Reduction of acne count from 11.6 lesions to 3.6 at the end of the study; NI lesions not evaluated	20% of patients had no improvement with treatment; 80% of patients showed 71.8% of improvement; NI lesions not mentioned	27% of patients had no improvement with treatment. Results not comparable because of the lack of standardization	7.8% no changes; 31.4% improvement; 60.8% marked improvement. Average lesion count reduction was 18%	41.9% (treated) vs 15.4% (control) reduction of inflamed lesions. Statistical difference when compared
Recurrence			New lesions after 3-6 mos				11% recurrence in 1 or 2 mos; results not comparable because of the lack of standardization		Most patients noted a increase in new lesions after 6 months

Continued

	Santos, 2005 ²⁹	Wiegell, 2006 ¹²	Wiegell, 2006 ¹³	Horfelt, 2006 ¹⁴	Alexiades-Armenakas, 2006 ²⁸	Rojanamat, 2006 ³⁰	Akaraphanth, 2007 ³³	Ycung, 2007 ³¹	Hörfelt, 2007 ³⁹
Drug	20% ALA topical	16.8% MAL	20% ALA vs 16.8% MAL	16.8% MAL	20% ALA topical + conventional treatment or chemical peels	20% ALA topical	10% ALA topical only in acne spot	16.8% MAL topical; all patients used 0.1% adapalene gel during the entire study	20% ALA topical
Control group?*	No (split-face: IPL alone vs IPL + ALA); not blinded assessment	Yes; blinded assessment	No (split-face); blinded assessment	Yes (split-face); blinded assessment	No (all patients received some treatment); all patients continued conventional therapies; not blinded assessment	No (not randomized split-face study); not blinded assessment [‡]	No (same patients received blue light alone and blue light + ALA in a nonrandomized split-face study); not blinded assessment	No (IPL alone vs MAL + IPL vs control in a randomized, split-face study); blinded assessment	Not blinded assessment
No. of patients/ acne location	13/Face	36 (21 treatment vs 15 control)/ Face	15/Face	30/Face	19/Face; 1 ALA + blue vs 14 ALA + LP PDL vs 2 LP PDL only vs 2 conventional treatments (4 patients of ALA + LP PDL group received 35% glycolic acid or 20% trichloroacetic acid peeling)	14/Face	20/Face	23/Face	14/Face: 9 cheek, 5 back
Acne type	Inflammatory and NI	Inflammatory	Inflammatory	Inflammatory, moderate to severe	Inflammatory and NI lesions, mild to severe	Inflammatory	Inflammatory, moderate to severe	Inflammatory	Mild to severe
Pretreatment	Not mentioned	Curettage + occlusive dressing	Not mentioned	Nodular and cystic lesions were pricked with 1-2 mm cannula	Cetaphil cleanser	Soap and water	Washing	Washed with soap followed by alcohol scrub	Not mentioned
Time of incubation	3 hrs	3 hrs under occlusion	3 hrs under occlusion, light covered	3 hrs under occlusion	45 min	30 min under occlusion	1 hr	30 min	3 hrs under occlusion

Continued

Table I. Cont'd

	Santos, 2005 ²⁹	Wiegell, 2006 ¹²	Wiegell, 2006 ¹³	Horfelt, 2006 ¹⁴	Alexiades-Armenakas, 2006 ²⁸	Rojanamatit, 2006 ³⁰	Akaraphanth, 2007 ⁴³	Yeung, 2007 ³¹	Hörfelt, 2007 ³⁹
Light sources	IPL (cutoff filter, 560 nm), double pulse 26-34 J/cm ²	Noncoherent red (635 nm), 37 J/cm ²	Noncoherent red (630 nm), 37 J/cm ² , 34 mW/cm ²	Noncoherent red (635 nm), 37 J/cm ²	LP PDL (595 nm, 7.0-7.5 J/cm ² , 10 ms, 10-mm spot size), DCD 30/30 blue (417 ± 5 nm), 10 mW/cm ²	IPL (cutoff filter, 560-590 nm), double pulse 25-30 J/cm ²	Blue LED (415 ± 5 nm), 40 mW/cm ² , 48 J/cm ²	IPL (530-750 nm), single pass, double pulse, 10-ms delay, pulse 2.5 ms, 7.0-9.0 J/cm ²	Noncoherent red (600-730 nm), 50 mW/cm ² , 50 or 30 J/cm ² (cheek); 50 or 70 J/cm ² (back)
No. of PDT sessions	2 (2 wks apart)	2	1	2 (2 wks apart)	1-6 sessions (4 wks apart), no standardized protocol	3 (3-4 wks apart)	4 (1 wk apart)	4 (3 wks apart)	1
Total follow-up time	8 wks	12 wks	12 wks	12 wks	5-52 wks, no standardized protocol	12 wks	11 wks (16 wks of the beginning of the treatment)	12 wks	10 wks (cheeks); 20 wks (back)
Efficacy rate [†]	ALA + IPL sites: 23% poor response, 77% good or excellent results vs IPL only: 77% poor, 23% good results.	68% reduction of inflammatory lesions vs 0% in controls (<i>P</i> = .0023 [control]); 92% improvement (<i>P</i> = .64); NI lesions: no improvement.	Mean of 59% reduction of inflammatory lesions for both MAL and ALA. NI lesions: no difference. 75-83% clinical improvement.	54% (PDT) vs 20% (control) reduction of inflammatory lesions (<i>P</i> = .0006); NI lesions: reduction with no statistically significant 40% (PDT) vs 20% (control) clinical improvement.	ALA + LP PDL group: clearance ~40-100%, but 4 patients had additional chemical peels and maintained conventional treatment during the study. Clearance of 32-33% (LP PDL-only) vs 17-20% (conventional); results not comparable because of the lack of standardization.	All patients improved; 87.7% (IPL + ALA) vs 66.8% (IPL only) reduction of inflammatory lesion (no statistical difference).	71.1% (blue light + ALA) vs 56.7% (IPL only) reduction of inflammatory lesion (with no statistical difference, <i>P</i> = .092). Reduction in NI lesions was 80.5% (blue + ALA) vs 71.3% (blue only) with no statistical difference. No significant difference in the lipid level.	65% (PDT-group) vs 23% (IPL group) vs 88% (control group) reduction of inflammatory lesions (no statistical difference); NI lesions: decrease of 38% PDT group vs 44% IPL vs increase of 15% in control group.	100% showed some improvement; high and low light doses showed similar clinical improvement, the latter with lower side effect rates.

Recurrence	New lesions starting from 1-13 mos
ALA, 5-Aminolevulinic acid; CW, continuous wave; DCD, dynamic cooling device; IPL, intense pulsed light; LP, long pulse; MAL, methyl aminolevulinate hydrochloride; NI, noninflammatory; PDL, pulsed dye laser; PDT, photodynamic therapy; ?, unknown.	
*Controls were defined as areas of the patients or groups of patients followed during the same time of the clinical trial that did not receive PDT treatment nor any drug or light irradiation.	
†Efficacy rate at the end of the study.	
‡Although patients were assessed by a nontreating dermatologist, the split-side of the face was not randomized, because IPL alone was always performed on the left side, and ALA + IPL was always performed on the right side of the face.	

transporter (in rat pancreatoma cells),⁴ PEPT2 transporter (in kidney cells),⁵ carrier systems transporting the beta amino acids (β -transporters), and gamma-aminobutyric acid (GABA; in the human adenocarcinoma cell line WiDr).^{6,7} It is unknown whether and to what extent different active transport mechanisms account for the striking biodistribution of ALA among different cell types in human skin. However, ALA esters were suggested to enter cells mainly by passive diffusion or endocytosis.⁸ MAL does not seem to be taken up by β -transporters, but by an active transport mechanism involving transporters of nonpolar amino acids, when studied in colon adenocarcinoma cells.⁹

Even though in vitro porphyrin accumulation had been shown to be more effective for some ALA esters in comparison to ALA, when injected into mice, ALA derivatives resulted in a lower porphyrin concentration in the tumor compared to equimolar amounts of ALA, suggesting blood vessel retention of ALA derivatives.¹⁰ Oral administration of ALA alkyl esters also show no advantage over 5-ALA, because these are quickly degraded in the gastric acidic environment.¹

The development of new ALA derivatives is promising, but the optimal photosensitizer for acne treatment is not yet defined, and clinical results are still pending for most of the ALA derivatives. Among all ALA derivatives, only MAL has been studied and introduced for treatment of acne outside the United States, but is not yet cleared by the US Food and Drug Administration for this indication.

There may be important differences between MAL and ALA in practice. The role of occlusion after application has not been specifically tested for either of these topical medicines (hydroalcoholic solution vs. cream). While ALA is a water-soluble amino acid, MAL is a more lipid-soluble derivative. In theory, MAL may partition more easily into the lipid-rich milieu of sebum, but this has not been specifically tested. Depending on pH, the two molecules have different charges. The extra metabolic step of ester hydrolysis is also necessary to convert MAL to ALA, which appears to occur mainly in the intracellular space; tissue—cytoplasmic esterases in particular—must hydrolyze the methyl ester to form ALA in situ, which is then converted to porphyrins. The heme synthetic pathway is complex, involving multiple cytoplasmic and mitochondrial steps that are sensitive to substrate concentrations. Differences in the vehicles, uptake, charge, partitioning, and metabolism plus the higher molecular weight of MAL may delay its onset of photosensitization compared with ALA, but this has also not been determined. A study comparing ALA and MAL for actinic keratosis has

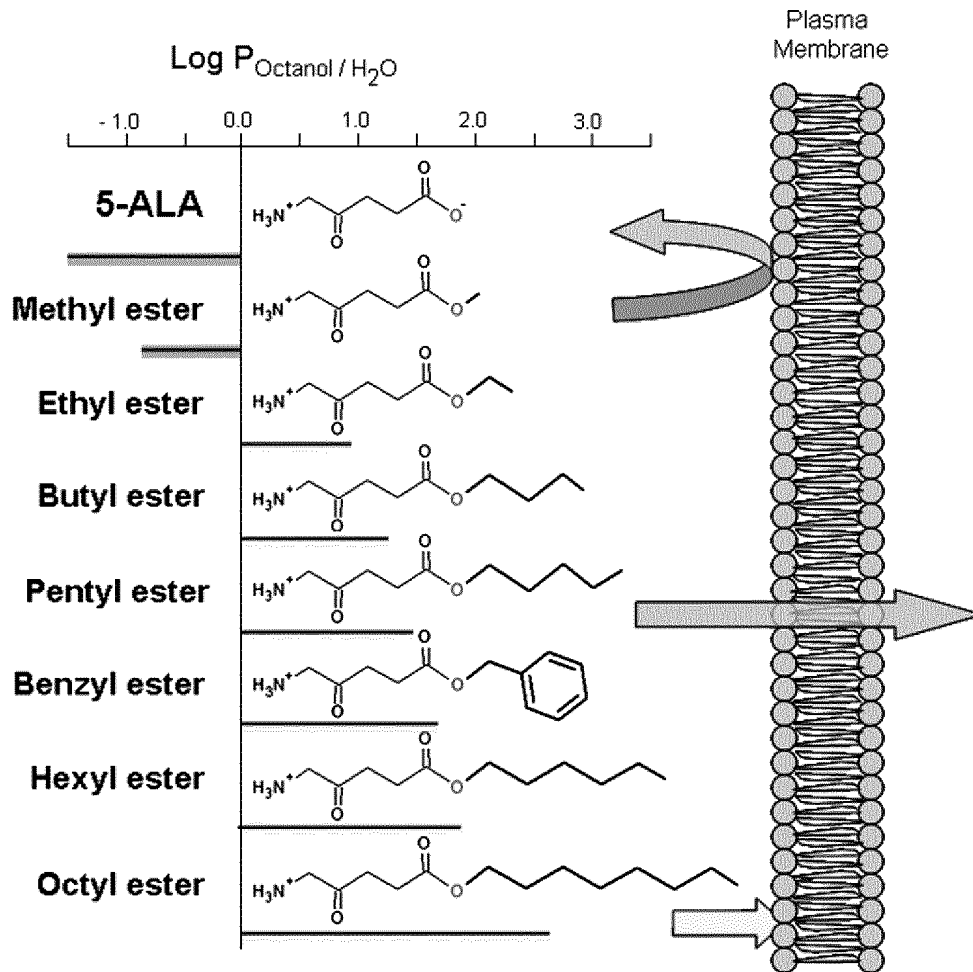


Fig 1. Uptake of 5-aminolevulinic acid (ALA) and its derivatives depends on the partition between the aqueous and lipophilic environments, molecular weight, and specific transmembrane transport. $\log P_{\text{octanol}/\text{H}_2\text{O}}$ describes partitioning between octanol (lipophilic) and water (hydrophilic) media. ALA and its methyl ester have negative values, meaning that they are hydrophilic. For them, passive diffusion through cell membranes is difficult, and uptake occurs by specific receptors. All the other esters shown are more lipophilic. Intermediate lipophilicity allows most of them to cross biologic membranes, but the largest octyl ester of ALA is inhibited from cell uptake. (Modified with permission from Lange.¹)

shown that ALA is more efficient for porphyrin formation, although MAL was more selective for the lesions.¹¹ Similar comparative studies for sebaceous glands were not performed. Neither of the drug formulations has been specifically optimized for use in acne treatment; it is likely that both could be improved.

Comparative efficacy

Similar studies of “high-dose” (long incubation time and high fluence red light exposure) have also verified similar efficacy when the MAL was used for acne therapy.¹²⁻¹⁴ Wiegell and Wulf^{12,13} reported a significant 68% reduction in inflammatory lesions after 12 weeks of treatment, and a control group did not improve.

The same group compared topical 20% ALA with 16% MAL in a randomized, split-face, blindly assessed study followed for 12 weeks after one PDT session (3 hours of incubation followed by irradiation of red light).¹³ There was 59% average reduction of inflammatory lesions with no statistical difference between the two drugs. Pain during treatment was similar for both photosensitizers, but was more intense after 24 hours in the ALA sites. This was felt to be consistent with more intense and homogeneous porphyrin fluorescence found in the ALA-treated areas, suggesting that ALA may cause greater porphyrin synthesis in the epidermis. One hypothesis is that MAL is more selective for sebaceous gland uptake because of its lipophilic properties. However, this is speculative, and it is not yet known whether

the two agents induce different porphyrin distributions under various application conditions. It is equally plausible that faster uptake and metabolism of ALA into protoporphyrin IX may explain its more intense fluorescence and greater side effects in this study.

Potentially, a shorter period of incubation or a lower ALA concentration would produce the same intensity and distribution of porphyrins as MAL, with the same side effect rates and efficacy for the treatment of acne. A larger clinical study comparing these drugs in a dose response manner is needed. At present, they appear to be largely equivalent.

Oral or topical photosensitizer?

While using oral ALA, Kimura et al¹⁵ observed a 92% rate of improvement of acne according to nonblinded observers. The oral administration of ALA can lead to systemic adverse effects not unlike acute variegate porphyria, acute intermittent porphyria, or the δ -ALA dehydratase deficiency porphyria in which systemic ALA levels are elevated.¹⁶ Those include generalized photosensitivity requiring prolonged photoprotection, hepatotoxicity, nausea, and vomiting,¹⁷ although only nausea was observed in Kimura et al's study,¹⁵ in which the ALA dose was limited to 10 mg/kg. Similar to topical application of ALA,¹⁸ an acneiform eruption occurring 3 to 4 days after treatment was also observed after oral ALA administration¹⁵ and red light exposure for PDT. Because of these side effects and lack of an approved formulation, oral ALA remains experimental and is rarely used outside of Japan.

WHICH LIGHT SOURCES, AND WHAT DOSIMETRY AND IRRADIANCE?

Key points

- **Deeper penetrating (red) light wavelengths are more likely to reach and activate porphyrins in sebaceous glands**
- **Continuous, high-intensity red light sources, including lasers, broad spectrum, and light-emitting diode sources, have shown best results in long-term follow-up studies using either ALA or MAL for photodynamic therapy of acne**
- **There is no consensus about optimal light dosimetry and irradiance**

Photons, the fundamental quanta of light, interact with matter by scattering and absorption. Both of these interactions limit the penetration of light into skin.^{19,20} In the visible light spectrum, scattering and absorption generally decrease with increasing wavelength. Longer wavelengths (red) therefore

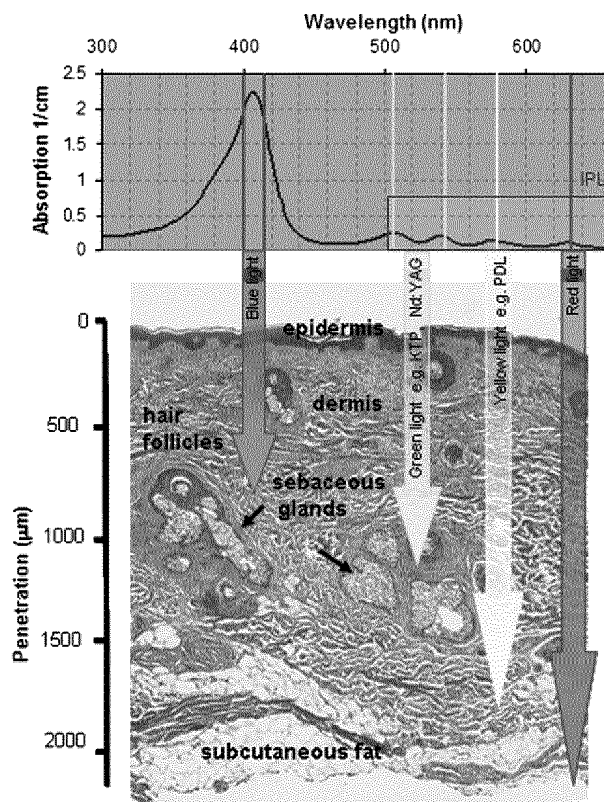


Fig 2. Porphyrin absorption bands exist from 300 to 650 nm and can be excited by numerous sources, which have a range of clinical utility. The figure shows wavelength-dependent penetration of light into human skin, with arrows indicating the approximate 50% optical penetration depth. *IPL*, Intense pulsed light (source); *KTP*, potassium-titanyl-phosphate; *Nd*, neodymium; *PDL*, pulsed dye laser; *YAG*, yttrium-aluminum-garnet.

penetrate deeper than shorter (blue) wavelengths, a phenomenon also known as the Tyndall effect.^{19,20} Facial sebaceous glands are part of the follicular unit and are located approximately 0.5 to 1.0 mm from the cutaneous surface.²¹ Because of the deep location of sebaceous glands, stimulation of the photosensitizer for acne treatment requires light sources with wavelength(s) sufficiently long and with sufficient irradiance to induce photodynamic effects on the targets²² (Fig 2).

Porphyrins are tetrapyrrole molecules, with a maximum absorption band in the blue light spectrum, the Soret band (405–415 nm). Somewhat weaker absorption bands, so-called Q-bands, are located in the green (~506 nm to ~540 nm), yellow (572–582 nm), and red spectra (628–635 nm). Although the strongest porphyrin absorption is in the blue spectrum, blue light penetrates poorly into dermis in vivo. In contrast, red light is a deeply penetrating wavelength region that can effectively drive PDT reactions throughout the dermis to more

than 2 mm deep. Continuous wave (CW) broad spectrum^{18,23} or noncoherent¹²⁻¹⁴ red light sources have shown best results in long-term follow-up studies using either ALA or MAL for the treatment of acne.

The use of pulsed sources have been successfully described for the treatment of superficial targets, such as superficial actinic keratosis,²⁴ although potential differences in the mechanisms of action between CW and pulsed light sources for PDT are still unclear.²⁵ One enigma is that all of the oxygen available in skin during a millisecond-domain light pulse is probably insufficient for PDT, and yet single pulses from intense pulsed lights (IPLs) or pulsed dye lasers (PDLs) are claimed to be effective for PDT of actinic keratosis and acne. Perhaps the burst of singlet oxygen generated during a high fluence light pulse is somehow more effective than steady production during continuous light exposure. Alternatively, the photochemistry may be primarily affected. Oxygen depletion during a high-irradiance pulse could lead to other non-oxygen-dependent reactions of the porphyrin triplet states. It is also possible that in practice, inadvertent exposure to sunlight or other environmental light after the patient leaves the dermatology office is in part responsible for the reported efficacy of pulsed-source PDT. The few studies using pulsed light sources for the treatment of acne lack controls,²⁶⁻²⁸ have short follow-up period,²⁹ or show no statistical difference compared to controls.^{30,31}

There is no consensus on the optical dosimetry for PDT of acne. As in ultraviolet light phototherapy, the primary units of dosimetry are wavelength range of the source (measured in nm), irradiance (in W/cm² or mW/cm², the rate at which energy is delivered per unit area of skin), fluence (in J/cm², the total energy delivered per unit area of skin), and exposure time (seconds or for the pulsed sources used thus far, milliseconds). As with classical phototherapy, fluence is equal to the irradiance multiplied by the exposure time. For continuous sources, the PDT exposure time in seconds is calculated by dividing the desired fluence by the irradiance of the source. Pulsed light sources in dermatology were developed for selective photothermolysis^{20,32,33} and as such are capable of inducing selective thermal damage to blood vessels, hair follicles, and/or pigmented lesions. Exposure time for most pulsed sources is fixed on a millisecond time scale, and the desired fluence is delivered in a single pulse. Sources used for PDT include light-emitting diodes (LEDs), filtered incandescent or arc lamps, slide projectors, fluorescent lamps, IPLs (filtered xenon flashlamps), lasers, and sunlight. The only source specifically cleared by the

US Food and Drug Administration for ALA PDT of actinic keratosis is a moderate irradiance, U-shaped blue fluorescent lamp (Blu-U; DUSA Pharmaceuticals, Wilmington, MA) that may be insufficient for highly effective acne treatment with permanent results.³⁴ Of the other sources, red (~635 nm) LED arrays are probably the most accurate, intense, robust, and sufficiently wide-area sources for facial acne PDT (eg, Aktelite CL 128; Photocure ASA, Oslo, Norway, and Omnilux [Photo Therapeutics, Cheshire, UK]). However, it should be noted that Kennedy et al's original description of ALA PDT for basal cell carcinomas³⁵ used a common slide projector, and a similar source was used in Hongcharu et al's original study of PDT for acne.¹⁸

Unless the tissue is hypoxic, the rate at which singlet oxygen is produced during PDT, and the stinging pain felt by the patient, is related to the product of the source irradiance times the local porphyrin concentration. Pain can be reduced by reducing the source irradiance, and a fan blowing cool air on the skin also helps.

In an optical dose-response study for the treatment of nevoid basal cell carcinomas (BCCs) using different light fluences at 633 nm wavelength, Oseroff et al³⁶ reported higher response rates up to 200 J/cm² of red light, delivered at an irradiance of 150 mW/cm². A follow-up study by the same group³⁷ compared different red light irradiances to deliver 200 J/cm². If ~40 mW/cm² was applied until photobleaching of porphyrin (as measured by fluorescence) had reached 10% of its initial value, at which point the treatment was continued at 150 mW/cm² until the treatment fluence of 200 J/cm² was delivered, this initial low irradiance reduced pain without compromising efficacy. A similar approach is likely to be helpful for high fluence, continuous red light PDT of acne, the only optical dosimetry clearly shown to produce substantial, long-lasting improvement.

Only two studies have shown biopsy specimens confirming long-term sebocyte damage, one using 550 to 700 nm at 150 J/cm²,¹⁸ and the other using 600 to 700 nm at 13 J/cm².²³ These fluences are more than one order of magnitude apart; only the higher fluence study showed a prolonged suppression of sebum secretion. A small unblinded dose-response pilot study by Horfelt et al³⁸ suggested that 30 to 70 J/cm² showed similar efficacy after 10 weeks, but with reduced side effects at the lower fluence; however, no biopsies were performed. In overview, the evidence regarding optical dosimetry for ALA PDT of acne suggests that two fluence-dependent mechanisms may account for efficacy. At low fluences—and apparently with pulsed sources and blue

light sources—superficial and limited PDT occurs, which is less painful, has fewer side effects, and achieves a modest and temporary improvement. This may occur by effects on bacteria, inflammation, and/or follicular keratinization. At high fluences with red light delivered in several treatment sessions, greater and much more prolonged efficacy can be achieved, along with greater inflammatory and pigmentary side effects, associated with profound reduction of sebaceous gland function. It is plausible that the latter high-fluence approach may rival oral retinoids, the only other treatment known to reduce sebaceous gland function. This will remain a conjecture, however, until PDT is optimized and well controlled prospective clinical trials are undertaken.

SKIN PREPARATION

Key points

- **Skin preparation affects the uptake of topical drugs. Various skin preparations have been used in different clinical studies of photodynamic therapy for acne, which creates a confounding variable when comparing the results**
- **When using ALA, degreasing skin might help drug penetration. Lipophilic esters might not require skin cleansing, yet no comparative studies have been performed**
- **Skin occlusion may increase drug uptake**

Presumably, skin preparation affects uptake of ALA or MAL, as it does other topical medications. The drug should be applied uniformly to the treatment area. Otherwise, linear streaks or other patterns of erythema, edema, or hyperpigmentation may result after light exposure.

Skin preparation has not been mentioned in eight of the case reports and experiments using porphyrin precursors for PDT.^{12,13,15,23,29,38-40} Cleansing with 70% isopropyl alcohol,^{18,41} 2% salicylic acid,³⁴ mild skin cleansers,^{26,28} acetone scrub, or alcohol²⁷ have all been described before the application of ALA. Simple pretreatment cleansing with soap and water⁴² followed by alcohol scrubbing (the type of alcohol was not specified)³¹ were also used. Curettage of lesions¹² and pricking of nodulocystic acne with a cannula¹⁴ were also described. Curettage followed by ALA or MAL photodynamic therapy is used in Europe as a treatment for BCC.

Depending on the vehicle and lipophilicity of the drug, degreasing the skin surface might help drug penetration, although to date no specific clinical comparison of pretreatment care has been reported for either ALA or MAL.

Occlusion is known to reduce transepidermal water loss, hydrating the stratum corneum and generally enhancing drug penetration, especially for hydrophilic molecules such as ALA.^{43,44} Of the 18 publications, 10 recommended occlusion for their patients during drug incubation.^{12-14,18,23,39-42} Of note, the desired route of ALA or MAL uptake for acne therapy may be directly into hair follicles rather than through the stratum corneum. Occlusion could perhaps lead to a less selective distribution of porphyrins; therefore, follicular uptake can be rapid and depends largely on the solvent(s) into which the drug is compounded. At neutral pH, ALA is an ion that can be driven into human skin rapidly by iontophoresis.⁴⁵ Iontophoresis may affect the distribution of ALA and therefore porphyrin synthesis in skin, but this hypothesis has also not been studied, and iontophoresis has not been used in any studies of ALA PDT for acne treatment.

SIDE EFFECTS

Key points

- **Pain, acute inflammatory skin reactions, and transient skin tanning are the most common side effects of ALA PDT or MAL PDT**
- **Patients should be advised to avoid bright light exposure after treatment because of persistent phototoxicity up to 48 hours**
- **Pain is worse at the beginning of light irradiation and can be reduced by using cooling fans and water spritzing**
- **Allergy to ALA or ALA derivatives is rare**

Side effects of ALA PDT or MAL PDT with topical use for acne treatment are apparently related to the accumulation of porphyrins in the epidermis. Also, the intensity of side-effects is related to light source and light dosimetry. High-dose red-light PDT has more evidence of long-term efficacy, but it is also associated with higher rates of side-effects. In general, the risk of permanent side effects, such as ulceration and scarring caused by ALA or MAL PDT, is extremely low, but inflammatory and pigmentary side effects are common. Scarring is very rare^{18,23,34,40} and has only been reported once.¹³ Adverse effects include moderate to severe pain during treatment (common), erythema (common, typically reported to last 3-5 days, but occasionally up to 4 weeks), edema (common, typically 1-4 days after treatment), formation of blisters (rare), sterile pustular eruption (starting on the second or third day posttreatment, lasting typically 3 days, after high fluence red light PDT), and crusts (30% of patients, starting on the second to fourth posttreatment day), purpura, acute transient acne flare (3-4 weeks

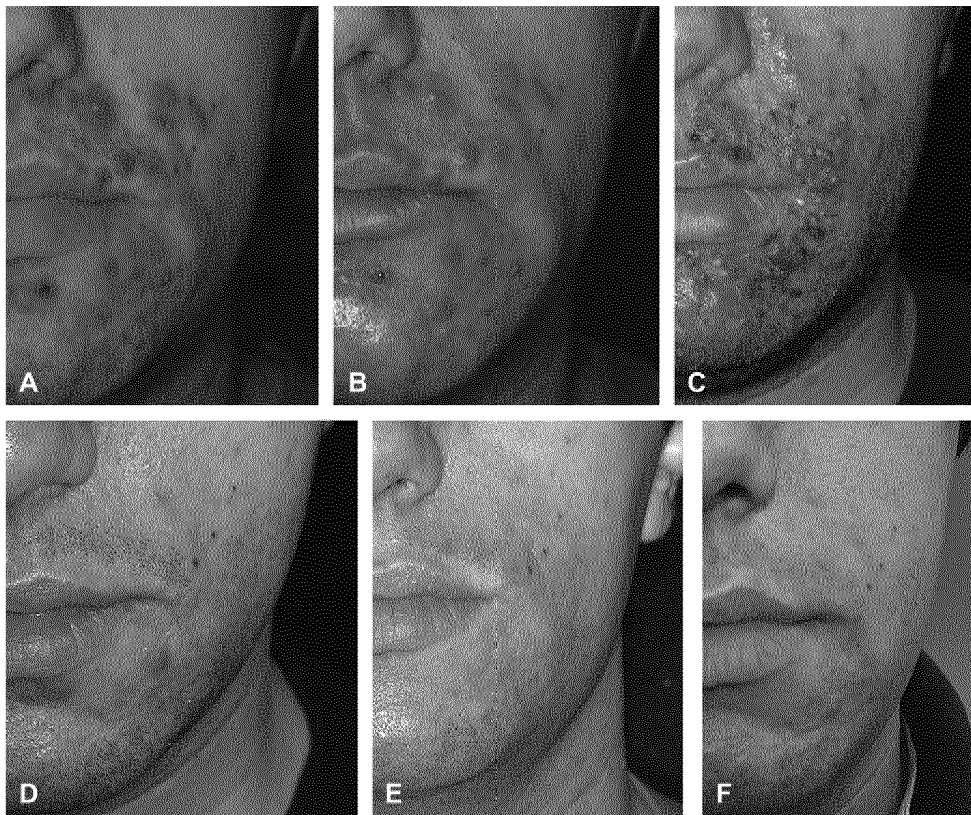


Fig 3. Improvement of inflammatory acne and cicatricial lesions after topical application of 20% 5-aminolevulinic acid (ALA) for 3 hours of incubation under occlusion and 200 J/cm² of 633 nm red light (Omnilux; Photo Therapeutics, Cheshire, UK) at 100 mW/cm². **A**, Before treatment. **B**, Immediately after the first session. **C**, Two days after the first session. **D**, Seven months after the first session and before the second session. **E**, Ten months after the first session, 3 months after the second session. **F**, One year and 2 months after the first session, after total of four sessions. Note the important inflammatory reaction after high dose red light ALA photodynamic therapy, with no long lasting side effects. (Courtesy R. Rox Anderson, MD.)

posttreatment), exfoliation (4-10 days), contact hypersensitivity/irritation (rare, lasting ~10 days), post-inflammatory hyperpigmentation for 4 weeks to 3 months,^{18,23,40,12,42} and induction of herpes simplex eruptions in predisposed patients. For those, antiviral prophylaxis is recommended. The side effects may affect the patient's social life and comfort. Covering the treated areas with make-up or missing work/school for 1 to 7 days after treatment is often necessary (Fig 3), depending on the dosimetry used.

Pain is a practical problem during treatment with continuous sources at high irradiance, such as LEDs, lasers, and fluorescent and filtered lamps. Pain is much less with pulsed sources, but these may be much less effective. Pain usually begins as a tingling sensation within a minute of light exposure, reaches a maximum within several minutes, and then subsides as the porphyrin is photobleached. Cessation of light exposure generally relieves the pain within seconds, which is consistent with direct neural stimulation. Pain can be a cause for discontinuation of

treatment. For unknown reasons, the pain during PDT is greatly minimized by spritzing cool water and by applying strong ventilation with a fan.^{12,14,31} In our practice (unpublished data), the use of a skin cooling device (Zimmer; MedizinSystems, Irvine, CA) and lowering the room temperature to 20 °C have helped patients deal with the pain. The photochemistry of PDT is not inhibited by skin cooling, but porphyrin synthesis is potentially inhibited at temperatures <20 °C.^{46,47} Patients should be kept warm during the incubation period between drug application and light exposure. Pain during light exposure can also be reduced by lowering the source irradiance.

The use of topical anesthetics to reduce pain, applied during the incubation time, is difficult because of mixing the anesthetic and ALA, which may form a precipitate salt. In addition, the use of topical anesthetics after the ALA incubation time has been shown not to be effective in a randomized placebo controlled study for the treatment of scalp

actinic keratosis.⁴⁸ Injection anesthesia can be performed, but epinephrine should not be included. Despite the lack of a specific study, clinical experience strongly suggests that the efficacy of PDT is inhibited when epinephrine is used (unpublished observations), and in general photodynamic processes in skin are inhibited by simple ischemia.^{49,50} It is well established that PDT is an oxygen-dependent process that is limited by vasoconstriction and hypoxia.²²

Complete healing is normally seen 1 week after treatment, but erythema and hyperpigmentation similar to a “tan” can persist up to 4 weeks after the treatment, especially in darker skin types. Surprisingly, the postinflammatory hyperpigmentation often reported with laser-based treatments has never been described following ALA PDT, including in Asian skin.²³ One hypothesis for this is related to the mechanisms of cell death involved. Thermal damage from laser treatments causes acute cell necrosis, while oxidative damage from PDT tends to induce apoptosis.^{23,51}

Anecdotal recommendation of the use of sunscreens after treatment in order to prevent sun-related side effects³⁴ is not supported, because porphyrins are present in the skin up to 24 to 48 hours after drug application, and sunscreens do not effectively block the visible light wavelengths. Physical inorganic sunscreen containing 15% titanium dioxide, 6.8% zinc oxide, and 3.2% iron oxide may produce blue light protection (up to 37 J/cm²) after 18 hours of drug application,⁵² but other visible wavelengths were not tested for phototoxicity. Therefore, intense visible light avoidance is recommended during this period. “Sunless tanning” creams containing dihydroxyacetone are mildly protective for porphyrin-mediated photosensitivity, have the advantage of lasting for about the same duration as ALA-induced skin photosensitivity, and help to camouflage the acute skin reaction (unpublished observation).

Allergy to ALA is exceedingly rare, and perhaps nonexistent because ALA is naturally present in all cells. Allergy to ALA derivatives is rare. Allergic reactions have been reported while using topical MAL for treatment of various skin conditions with positive patch test, with a possible correlation to drug concentration.⁵³⁻⁵⁵ Severe contact dermatitis with intense pain was observed after drug and light irradiation in those patients. The allergen was apparently the methyl-ester of ALA itself rather than a component of the topical formulation. Peanut oil (arachis oil) did not show any reaction in a patient with positive test to MAL.⁵⁵ Of 667 patients treated in 2006 in Copenhagen with MAL PDT, four patients

(0.6%) were suspected to have an allergic reaction. Of these, three (0.4%) had positive patch test reactions against MAL, and ALA patch test reactions were difficult to analyze, because ALA’s acidity also caused an irritant reaction.⁵⁶ Urticaria was reported in 12 of 1353 patients (0.9%) treated with MAL between 2002 and 2007.⁵⁷ In contrast, only one paper has described allergic contact dermatitis with positive patch test using 20% topical ALA,⁵⁸ and two reports of photocontact urticaria after ALA PDT^{59,60} were found in the literature to date. There are no reports of hypersensitivity reactions after ALA PDT for acne.

HOW LONG BETWEEN DRUG APPLICATION AND LIGHT IRRADIATION?

Key points

- After drug application, time should be allowed for penetration and metabolism to porphyrins before beginning light exposure
- Long incubations (≥ 3 hours) followed by red light exposure have shown evidence of long-term acne remission for both ALA PDT and MAL PDT

In an attempt to minimize the epidermal adverse effects and reduce the time spent with patients in the office, some reports have suggested shortening the time between ALA application and light exposure (called “short-contact PDT”) from hours to 10 to 30 minutes and have suggested the use of lower fluences or other light sources, including IPL, PDL, and blue light, among others.^{26-30,34,42} Despite optimistic case reports published by a handful of authors, these studies are uncontrolled, retrospective case series, and/or combine PDT in an uncontrolled way with microdermabrasion or chemical peels that would individually improve acne, use poorly characterized light sources,²⁷ feature poor statistical analysis, and/or have a short follow-up time of only a few weeks. No improvement is reported in about 20% to 30% of the treated patients.²⁶⁻²⁸ The lack of quantitative endpoints or blind assessment and the absence of control groups or untreated control skin sites make it impossible to exclude observer bias, placebo effects, or random individual variations as an explanation for the outcomes. Furthermore, many of these studies analyze sun-exposed areas, such as the face, without controlling sun or other light exposures after treatment, thereby causing confusion about whether PDT performed in the office or the prolonged photosensitizing effect of ALA with environmental light is responsible for efficacy. PDT reactions induced by ambient light can occur 24 to 48 hours after drug application.²⁵ While in a practical sense it may be advantageous to

use natural light for enhanced efficacy, this hypothesis has not yet been tested. In an attempt to reproduce the results using such various protocols, Yeung et al³¹ analyzed three patient groups: those treated with an IPL (530-750 nm), those treated with IPL and an ALA methyl-ester (30-min incubation), and a control group without treatment. There was no statistical difference between the treated and the control groups.³¹

The reported efficacy of these short-contact and/or alternative light source protocols for ALA PDT or MAL PDT is much less than those initially described in well controlled studies using long application (3-4 hours) and high fluence red light. Consequently, there is some scientific skepticism about such modalities. These office-based practice adaptations of PDT have apparently reduced the efficacy and duration of benefit of acne treatment, led to confusion over treatment parameters, and contributed to a lack of therapeutic consensus. The clinical motivation for these studies must be respected, however—a faster, better tolerated form of PDT that fits the routine of a busy dermatology practice and maintains high efficacy is clearly needed.

SUMMARY AND FINAL CONSIDERATIONS

Key points

- **Clinical results depend on the way PDT treatment is performed, including skin preparation, which drug is applied and for how long, whether skin occlusion is used, light source, and light treatment parameters**
- **By manipulating these variables, PDT can be performed in a wide variety of methods**
- **PDT for acne treatment has not been optimized. Basic, preclinical, and clinical research may lead to substantial improvement and to a knowledge of how this treatment fits into the broader armamentarium**

The search for prolonged or permanent results akin to oral retinoid therapy but with minimal side effects is still a challenge. ALA PDT and MAL PDT are indeed very promising, from the point of view that these are the only modalities (other than oral retinoids) that have been shown to inhibit sebaceous gland function and to produce prolonged remission of acne vulgaris. Using high fluence red light after long incubation periods (≥ 3 hours) and for multiple sessions, PDT has apparently similar efficacy to the clinically and histopathologically proven use of oral isotretinoin in inflammatory acne^{12,18,23} (Fig 3). However, treatment using long application time and high fluence red light also causes pain and inflammatory and pigmentary side effects.

A direct comparison of ALA PDT or MAL PDT with oral isotretinoin is lacking. For patients with severe acne, it is unknown whether the efficacy and side effects of PDT are preferable to the efficacy and intense dryness, systemic side effects, and risk of birth defects from treatment with oral retinoids. Is a series of several painful PDT sessions with a drug costing more than \$100 per dose—in an off-label treatment not routinely covered by medical insurance—better than taking isotretinoin with all its attendant legal issues, blood tests, and side effects? In practice, the answer depends on both individual patients and practices. PDT with topical porphyrin precursor drugs can be a good therapeutic alternative in countries where oral isotretinoin is prohibited (such as Japan); in patients with acne refractory to conventional therapies, those with multiple bacterial antibiotic resistance, or those who are unable or unwilling to use oral isotretinoin; in women who intend to get pregnant; or in any patient who cannot tolerate isotretinoin. It is important to note, however, that neither ALA PDT nor MAL PDT has been studied for use in pregnant women (pregnancy category C; there are no adequate well controlled studies in pregnant women). PDT for acne is an “off-label” indication in the United States, where PDT is presently approved only for actinic keratosis.

Porphyrins are naturally found in humans and appear to be relatively safe compared with systemic retinoids and many antibiotics. Even in patients with various forms of porphyria, a lifetime of endogenous PDT does not, apparently, cause skin cancer. Toxicity or mutagenesis risks from PDT are improbable and have never been described. Some patients may also benefit aesthetically from ALA PDT or MAL PDT for acne, which has been associated with reduction of skin oiliness, “pore” (sebaceous follicle) size, and skin texture improvement.⁶¹ On the other hand, beneficial effects of PDT have not been observed for comedonal acne.^{13,14}

CLINICAL RESEARCH STRATEGY: ANSWERABLE AND IMPORTANT QUESTIONS

While it is clear that high-dose, long contact time, and high fluence light exposure is highly effective for acne treatment, none of those factors (drug dose, contact time, or light fluence) have been systematically studied in a dose-response fashion. Evidence to date from studies of both retinoids and PDT suggests that prolonged remission of acne requires suppression of sebaceous gland function. Potentially, sebum secretion could provide a quantitative surrogate measurement^{18,62,63} to rapidly optimize PDT for acne therapy before definitive clinical trials. This

strategy has apparently not yet been taken. In addition, there appears to be at least two mechanisms responsible for improvement after PDT. While suppression of sebaceous gland function accounts for long-term benefit, the (probably several) mechanisms for temporary improvement are unknown. The history of acne drug development includes excellent quantitative pharmacologic, microbiologic, and pathophysiologic studies, the methodology of which could be applied to optimize "low-dose" PDT.

Finally, different acne severities deserve different solutions. For patients with severe, recalcitrant, scarring acne who cannot take oral retinoids, even a painful and expensive office-based procedure that works well would be seen as miraculous. For most patients with mild to moderate nonscarring acne, office-based procedures are unlikely to compete with conventional over the counter and prescription treatments. The paucity of well designed studies using short contact PDT and pulsed light sources—ideas that are largely aimed at clinical practicality in the office setting—does not mean these ideas should be abandoned. But does PDT have to be an office-based procedure? It is now, for historical reasons—ALA PDT was first developed as an alternative to surgery, for treating cancer—and that mentality has dominated its development. The fact that sunlight alone improves acne, in the absence of any ALA, strongly suggests that "ambulatory PDT" with a low concentration of ALA could be practical. Who knows how little ALA is needed to improve the already useful action of sunlight (which, as noted above, does not require any harmful ultraviolet light wavelengths)? If sunlight is acting mainly by antimicrobial effect, even low-dose ALA is likely to improve the effect of sunlight. *P. acnes*, a facultative microaerophilic organism, depends on high levels of heme synthesis and is directly accessible to topical ALA. There is plenty of blue, green, yellow, and red light irradiance in sunlight at the porphyrin absorption bands to activate PDT. Furthermore, during light exposure, PDT predictably "turns itself off" because of photobleaching as discussed above. When the porphyrin content is safely low enough (as would be the goal for ambulatory PDT), the need for controlled light dosimetry is removed. Could ALA be mixed at low concentration with a sunscreen preparation, for those who want to treat acne while jogging on a sunny day? We make these speculations for academic interest, and do not suggest trying this until proper clinical studies are performed!

REFERENCES

1. Lange N. Pharmaceutical and biological considerations in 5-aminolevulinic acid in PDT. In: Hamblin MR, Mroz P, editors. *Advances in photodynamic therapy basic, translational, and clinical*, 1st ed. Norwood, MA: Artech House; 2008. p. 59-91.
2. Uehlinger P, Zellweger M, Wagnieres G, Juillerat-Jeanneret L, van den Bergh H, Lange N. 5-Aminolevulinic acid and its derivatives: physical chemical properties and protoporphyrin IX formation in cultured cells. *J Photochem Photobiol B* 2000; 54:72-80.
3. Peng Q, Moan J, Warloe T, Iani V, Steen HB, Bjørseth A, et al. Build-up of esterified aminolevulinic-acid-derivative-induced porphyrin fluorescence in normal mouse skin. *J Photochem Photobiol B* 1996;34:95-6.
4. Whitaker CJ, Battah SH, Forsyth MJ, Edwards C, Boyle RW, Matthews EK. Photosensitization of pancreatic tumour cells by delta-aminolaevulinic acid esters. *Anticancer Drug Des* 2000; 15:161-70.
5. Döring F, Walter J, Will J, Föcking M, Boll M, Amasheh S, et al. Delta-aminolevulinic acid transport by intestinal and renal peptide transporters and its physiological and clinical implications. *J Clin Invest* 1998;101:2761-7.
6. Rud E, Gederaas O, Hogset A, Berg K. 5-aminolevulinic acid, but not 5-aminolevulinic acid esters, is transported into adenocarcinoma cells by system BETA transporters. *Photochem Photobiol* 2000;71:640-7.
7. Rodriguez L, Batlle A, Di Venosa G, Battah S, Dobbin P, MacRobert AJ, et al. Mechanisms of 5-aminolevulinic acid ester uptake in mammalian cells. *Br J Pharmacol* 2006;147:825-33.
8. Gaullier JM, Berg K, Peng Q, Anholt H, Selbo PK, Ma LW, et al. Use of 5-aminolevulinic acid esters to improve photodynamic therapy on cells in culture. *Cancer Res* 1997;57:1481-6.
9. Gederaas OA, Holroyd A, Brown SB, Vernon D, Moan J, Berg K. 5-Aminolaevulinic acid methyl ester transport on amino acid carriers in a human colon adenocarcinoma cell line. *Photochem Photobiol* 2001;73:164-9.
10. Perotti C, Fukuda H, DiVenosa G, MacRobert AJ, Batlle A, Casas A. Porphyrin synthesis from ALA derivatives for photodynamic therapy. In vitro and in vivo studies. *Br J Cancer* 2004;90:1660-5.
11. Fritsch C, Homey B, Stahl W, Lehmann P, Ruzicka T, Sies H. Preferential relative porphyrin enrichment in solar keratoses upon topical application of delta-aminolevulinic acid methyl-ester. *Photochem Photobiol* 1998;68:218-21.
12. Wiegell SR, Wulf HC. Photodynamic therapy of acne vulgaris using methyl aminolaevulinate: a blinded, randomized, controlled trial. *Br J Dermatol* 2006;154:969-76.
13. Wiegell SR, Wulf HC. Photodynamic therapy of acne vulgaris using 5-aminolevulinic acid versus methyl aminolevulinate. *J Am Acad Dermatol* 2006;54:647-51.
14. Hörfelt C, Funk J, Frohm-Nilsson M, Wiegand Edström D, Wennberg AM. Topical methyl aminolaevulinate photodynamic therapy for treatment of facial acne vulgaris: results of a randomized, controlled study. *Br J Dermatol* 2006;155:608-13.
15. Kimura M, Itoh Y, Tokuoka Y, Kawashima N. Delta-aminolevulinic acid-based photodynamic therapy for acne on the body. *J Dermatol* 2004;31:956-60.
16. Bickers DR, Frank J. The porphyrias. In: Wolff K, Goldsmith LA, Katz SI, Gilchrist BA, Paller A, Leffell DJ, editors. *Fitzpatrick's dermatology in general medicine*, 7th ed. Vol II. New York: McGraw-Hill; 2007. p. 1228-1256.
17. Webber J, Kessel D, Fromm D. Side effects and photosensitization of human tissues after aminolevulinic acid. *J Surg Res* 1997;68:31-7.
18. Hongcharu W, Taylor CR, Chang Y, Aghassi D, Suthamjariya K, Anderson RR. Topical ALA-photodynamic therapy for the treatment of acne vulgaris. *J Invest Dermatol* 2000;115:183-92.
19. Anderson RR, Parrish JA. The optics of human skin. *J Invest Dermatol* 1981;77:13-9.

20. Sakamoto FH, Wall T, Avram MM, Anderson RR. Lasers and flashlamps in dermatology. In: Wolff K, Goldsmith LA, Katz SI, Gilchrist BA, Paller A, Leffell DJ, editors. *Fitzpatrick's dermatology in general medicine*, 7th ed. Vol II. New York: McGraw-Hill; 2007. p. 2263-79.
21. Sakamoto FH, Tannous Z, Doukas AG, Farinelli WA, Smith NA, Zurakowski D, et al. Porphyrin distribution after topical aminolevulinic acid in a novel porcine model of sebaceous skin. *Lasers Med Surg* 2009;41:154-60.
22. Sitnik TM, Hampton JA, Henderson BW. Reduction of tumour oxygenation during and after photodynamic therapy in vivo: effects of fluence rate. *Br J Cancer* 1998;77:1386-94.
23. Itoh Y, Ninomiya Y, Tajima S, Ishibashi A. Photodynamic therapy of acne vulgaris with topical delta-aminolaevulinic acid and incoherent light in Japanese patients. *Br J Dermatol* 2001;144:575-9.
24. Karrer S, Baumler W, Abels C, Hohenleutner U, Landthaler M, Szeimies RM. Long-pulse dye laser for photodynamic therapy: investigations in vitro and in vivo. *Lasers Surg Med* 1999;25: 51-9.
25. Strasswimmer J, Grande DJ. Do pulsed lasers produce an effective photodynamic therapy response? *Lasers Surg Med* 2006;38:22-5.
26. Gold MH, Bradshaw VL, Boring MM, Bridges TM, Biron JA, Carter LN. The use of a novel intense pulsed light and heat source and ALA-PDT in the treatment of moderate to severe inflammatory acne vulgaris. *J Drugs Dermatol* 2004;3(6 suppl): S15-9.
27. Taub AF. Photodynamic therapy for the treatment of acne: a pilot study. *J Drugs Dermatol* 2004;3(6 suppl):S10-4.
28. Alexiades-Armenakas M. Long-pulsed dye laser-mediated photodynamic therapy combined with topical therapy for mild to severe comedonal, inflammatory, or cystic acne. *J Drugs Dermatol* 2006;5:45-55.
29. Santos MA, Belo VG, Santos G. Effectiveness of photodynamic therapy with topical 5-aminolevulinic acid and intense pulsed light versus intense pulsed light alone in the treatment of acne vulgaris: comparative study. *Dermatol Surg* 2005;31(8 pt 1):910-5.
30. Rojanamatin J, Choawawanich P. Treatment of inflammatory facial acne vulgaris with intense pulsed light and short contact of topical 5-aminolevulinic acid: a pilot study. *Dermatol Surg* 2006;32:991-6.
31. Yeung CK, Shek SY, Bjerring P, Yu CS, Kono T, Chan HH. A comparative study of intense pulsed light alone and its combination with photodynamic therapy for the treatment of facial acne in Asian skin. *Lasers Surg Med* 2007;39:1-6.
32. Anderson RR, Parrish JA. Selective photothermolysis: precise microsurgery by selective absorption of pulsed radiation. *Science* 1983;220:524-7.
33. Nelson JS. Selective photothermolysis and removal of cutaneous vasculopathies and tattoos by pulsed laser. *Plast Reconstr Surg* 1991;88:723-31.
34. Goldman MP, Boyce SM. A single-center study of aminolevulinic acid and 417 NM photodynamic therapy in the treatment of moderate to severe acne vulgaris. *J Drugs Dermatol* 2003;2:393-6.
35. Kennedy JC, Pottier RH, Pross DC. Photodynamic therapy with endogenous protoporphyrin IX: basic principles and present clinical experience. *J Photochem Photobiol B* 1990;6: 143-8.
36. Oseroff AR, Shieh S, Frawley NP, Cheney R, Blumenson LE, Pivnick EK, et al. Treatment of diffuse basal cell carcinomas and basaloid follicular hamartomas in nevroid basal cell carcinoma syndrome by wide-area 5-aminolevulinic acid photodynamic therapy. *Arch Dermatol* 2005;141:60-7.
37. Cottrell WJ, Paquette AD, Keymel KR, Foster TH, Oseroff AR. Irradiance-dependent photobleaching and pain in delta-aminolevulinic acid-photodynamic therapy of superficial basal cell carcinomas. *Clin Cancer Res* 2008;14:4475-83.
38. Horfelt C, Stenquist B, Larko O, Faergemann J, Wennberg AM. Photodynamic therapy for acne vulgaris: a pilot study of the dose-response and mechanism of action. *Acta Derm Venereol* 2007;87:325-9.
39. Itoh Y, Ninomiya Y, Tajima S, Ishibashi A. Photodynamic therapy for acne vulgaris with topical 5-aminolevulinic acid. *Arch Dermatol* 2000;136:1093-5.
40. Pollock B, Turner D, Stringer MR, Bojar RA, Goulden V, Stables GI, et al. Topical aminolaevulinic acid-photodynamic therapy for the treatment of acne vulgaris: a study of clinical efficacy and mechanism of action. *Br J Dermatol* 2004;151: 616-22.
41. Hong SB, Lee MH. Topical aminolevulinic acid-photodynamic therapy for the treatment of acne vulgaris. *Photodermatol Photoimmunol Photomed* 2005;21:322-5.
42. Akaraphanth R, Kanjanawanitchkul W, Gritiyarangsarn P. Efficacy of ALA-PDT vs blue light in the treatment of acne. *Photodermatol Photoimmunol Photomed* 2007;23:186-90.
43. Harris DR, Papa CM, Stanton R. Percutaneous absorption and the surface area of occluded skin. A scanning electron microscopic study. *Br J Dermatol* 1974;91:27-32.
44. Guillaume JC, De Rigal J, Leveque JL, Galle P, Touraine R, Dubertret L. Study of the correlation between transepidermal water loss and percutaneous penetration of steroid [author's transl]. *Dermatologica* 1981;162:380-90.
45. Rhodes LE, Tsoukas MM, Anderson RR, Kollias N. Iontophoretic delivery of ALA provides a quantitative model for ALA pharmacokinetics and PpIX phototoxicity in human skin. *J Invest Dermatol* 1997;108:87-91.
46. Joe EK, Anderson RR, Ortel BH. Spatial confinement of 5-aminolevulinic acid-based photodynamic therapy by thermal and chemical inhibition. Presented at the Fourth International Investigative Dermatology Meeting, April 30-May 4, 2003, Miami Beach, FL.
47. Sakamoto FH, Doukas A, Farinelli WA, Tannous Z, Anderson RR. Skin temperature can control ALA-Photodynamic therapy. Presented at the 27th Annual Meeting of the American Society for Laser Medicine and Surgery, April 11-15, 2007, Grapevine, TX.
48. Langan SM, Collins P. Randomized, double-blind, placebo-controlled prospective study of the efficacy of topical anaesthesia with a eutetic mixture of lignocaine 2.5% and prilocaine 2.5% for topical 5-aminolaevulinic acid-photodynamic therapy for extensive scalp actinic keratoses. *Br J Dermatol* 2006;154: 146-9.
49. Auletta M, Gange RW, Tan OT, Matzinger E. Effect of cutaneous hypoxia upon erythema and pigment responses to UVA, UVB, and PUVA (8-MOP + UVA) in human skin. *J Invest Dermatol* 1986;86:649-52.
50. Youn JI, Gange RW, Maytum D, Parrish JA. Effect of hypoxia on sunburn cell formation and inflammation induced by ultraviolet radiation. *Photodermatol* 1988;5:252-6.
51. Webber J, Luo Y, Crilly R, Fromm D, Kessel D. An apoptotic response to photodynamic therapy with endogenous protoporphyrin in vivo. *J Photochem Photobiol B* 1996;35:209-11.
52. Bissonnette R, Nigen S, Bolduc C, Mery S, Nocera T. Protection afforded by sunscreens containing inorganic sunscreens agents against blue light sensitivity induced by aminolevulinic acid. *Dermatol Surg* 2008;34:1469-76.
53. Wulf HC, Philipsen P. Allergic contact dermatitis to 5-aminolaevulinic acid methylester but not to 5-aminolaevulinic acid after photodynamic therapy. *Br J Dermatol* 2004;150:143-5.

54. Hohwy T, Andersen KE, Solvsten H, Sommerlund M. Allergic contact dermatitis to methyl aminolevulinate after photodynamic therapy in 9 patients. *Contact Dermatitis* 2007;57:321-3.
55. Harries MJ, Street G, Gilmour E, Rhodes LE, Beck MH. Allergic contact dermatitis to methyl aminolevulinate (Metvix) cream used in photodynamic therapy. *Photodermatol Photoimmunol Photomed* 2007;23:35-6.
56. Jungersted JM, Dam TN, Bryld LE, Agner T. Allergic reactions to Metvix (ALA-ME). *Contact Dermatitis* 2008;58:184-6.
57. Kaae J, Philipsen PA, Haedersdal M, Wulf HC. Immediate whealing urticaria in red light exposed areas during photodynamic therapy. *Acta Derm Venereol* 2008;88:480-3.
58. Gniazdowska B, Rueff F, Hillemanns P, Przybilla B. Allergic contact dermatitis from delta-aminolevulinic acid used for photodynamic therapy. *Contact Dermatitis* 1998;38:348-9.
59. Yokoyama S, Nakano H, Nishizawa A, Kaneko T, Harada K, Hanada K. A case of photocontact urticaria induced by photodynamic therapy with topical 5-aminolaevulinic acid. *J Dermatol* 2005;32:843-7.
60. Kerr AC, Ferguson J, Ibbotson SH. Acute phototoxicity with urticarial features during topical 5-aminolaevulinic acid photodynamic therapy. *Clin Exp Dermatol* 2007;32:201-2.
61. Ruiz-Rodriguez R, Sanz-Sanchez T, Cordoba S. Photodynamic photorejuvenation. *Dermatol Surg* 2002;28:742-4.
62. Pagnoni A, Kligman AM, el Gammal S, Stoudemayer T. Determination of density of follicles on various regions of the face by cyanoacrylate biopsy: correlation with sebum output. *Br J Dermatol* 1994;131:862-5.
63. Pierard GE. Rate and topography of follicular sebum excretion. *Dermatologica* 1987;175:280-3.

Answers to CME examination

Identification No. 810128

August 2010 issue of the Journal of the American Academy of Dermatology.

Questions 1 and 2, Sakamoto FH, Lorezan L, Anderson RR. *J Am Acad Dermatol* 2010;63:195-211.

1. c
2. b