

# Aminolevulinic Acid: Actinic Keratosis and Photorejuvenation

2

Melanie Palm and Mitchel P. Goldman

## Abstract

ALA-PDT is a safe and effective treatment for nonhyperkeratotic lesions. Although FDA-approved for use with a blue light source, other laser and light sources have demonstrated promise in the treatment of actinic keratosis during PDT. Shorter incubation times maintain AK clearance rates but decrease the occurrence of phototoxic adverse events. With careful patient selection, ALA-PDT allows selective field treatment of precancerous skin lesions with improvement in overall photodamage. Patient satisfaction is high and cosmetic results can be excellent.

Aminolevulinic acid (ALA) was the first photosensitizer prodrug to be FDA-approved for use in topical photodynamic therapy (PDT). Since its approval over a decade ago, many aspects of ALA-PDT have been examined. Studies investigating the treatment of nonhyperkeratotic actinic keratosis (AK) with ALA-PDT have led to advances in treatment. Incubation times of ALA have decreased, multiple light sources have been used to elicit the reaction, and cosmetic benefits of treatment have been discovered. In the discussion that follows, background on ALA-PDT is provided. In addition, clinical studies regarding the treatment of AKs and photorejuvenation are summarized. Finally, a practical guide for treatment is provided for the reader to optimize treatment while avoiding common pitfalls of treatment.

## Mechanism of PDT

### PDT Mechanism of Action

PDT involves the activation of a photosensitizer by light in the presence of an oxygen-rich environment. Topical PDT involves the application of ALA or its methylated derivative (MAL) to the skin for varying periods of time. This leads to the conversion of ALA to protoporphyrin IX (PpIX), an endogenous photactivating agent. PpIX accumulates in rapidly proliferating cells of premalignant and malignant lesions [1], as well as in melanin, blood vessels, and sebaceous glands [2]. Upon activation by a light source and in the presence of oxygen, the sensitizer (PpIX) is oxidized, a process called “photobleaching” [3]. During this process, free radical oxygen singlets are generated, leading to selective destruction of tumor cells by apoptosis without collateral damage to surrounding tissues [4, 5]. Selective destruction of malignant cells is due in part to their reduced ferrochetalase activity, leading to

M. Palm (✉)  
Surfside Dermatology, Encinitas, CA, USA  
e-mail: melanie.palm@gmail.com

---

# Aminolevulinic Acid: Actinic Keratosis and Photorejuvenation

2

Melanie Palm and Mitchel P. Goldman

---

## Abstract

ALA-PDT is a safe and effective treatment for nonhyperkeratotic lesions. Although FDA-approved for use with a blue light source, other laser and light sources have demonstrated promise in the treatment of actinic keratosis during PDT. Shorter incubation times maintain AK clearance rates but decrease the occurrence of phototoxic adverse events. With careful patient selection, ALA-PDT allows selective field treatment of precancerous skin lesions with improvement in overall photodamage. Patient satisfaction is high and cosmetic results can be excellent.

Aminolevulinic acid (ALA) was the first photosensitizer prodrug to be FDA-approved for use in topical photodynamic therapy (PDT). Since its approval over a decade ago, many aspects of ALA-PDT have been examined. Studies investigating the treatment of nonhyperkeratotic actinic keratosis (AK) with ALA-PDT have led to advances in treatment. Incubation times of ALA have decreased, multiple light sources have been used to elicit the reaction, and cosmetic benefits of treatment have been discovered. In the discussion that follows, background on ALA-PDT is provided. In addition, clinical studies regarding the treatment of AKs and photorejuvenation are summarized. Finally, a practical guide for treatment is provided for the reader to optimize treatment while avoiding common pitfalls of treatment.

---

## Mechanism of PDT

### PDT Mechanism of Action

PDT involves the activation of a photosensitizer by light in the presence of an oxygen-rich environment. Topical PDT involves the application of ALA or its methylated derivative (MAL) to the skin for varying periods of time. This leads to the conversion of ALA to protoporphyrin IX (PpIX), an endogenous photactivating agent. PpIX accumulates in rapidly proliferating cells of premalignant and malignant lesions [1], as well as in melanin, blood vessels, and sebaceous glands [2]. Upon activation by a light source and in the presence of oxygen, the sensitizer (PpIX) is oxidized, a process called “photobleaching” [3]. During this process, free radical oxygen singlets are generated, leading to selective destruction of tumor cells by apoptosis without collateral damage to surrounding tissues [4, 5]. Selective destruction of malignant cells is due in part to their reduced ferrochetalase activity, leading to

---

M. Palm (✉)  
Surfside Dermatology, Encinitas, CA, USA  
e-mail: melanie.palm@gmail.com

excessive accumulation of intracellular PpIX [6]. Recent *in vitro* research suggests that any remaining malignant cells following PDT have reduced survival [7]. A detailed explanation of the mechanism of action in PDT is found in Chap. 1.

## ALA

$\delta$ -5-ALA is a hydrophilic, low molecular weight molecule within the heme biosynthesis pathway [1, 8]. ALA is considered a prodrug [9]. *In vivo*, it is converted to PpIX, a photosensitizer in the PDT reaction. In the United States, ALA is available as a 20% topical solution manufactured under the name Levulan Kerastick (DUSA Pharmaceuticals, Inc., Wilmington, MA). FDA-approved since 1999, Levulan is used for the treatment of nonhyperkeratotic AKs in conjunction with a blue light source, such as the Blu-U (DUSA, Wilmington, MA) [10]. It is supplied as a cardboard tube housing two sealed glass ampules, one containing 354 mg of  $\delta$ -ALA hydrochloride powder and the other 1.5 mL of solvent [6]. The separate components are mixed within the cardboard sleeve just prior to use.

Esters of ALA are lipophilic derivatives of the parent molecule. Their chemical structure provides increased lipophilicity, allowing superior penetration through cellular lipid bilayers compared to ALA [2, 11]. MAL may offer better tumor selectivity [11–14] and less pain [14, 15] during PDT with less patient discomfort [15] compared to ALA.

## Light Irradiation

No standardized guidelines for the “optimal irradiance, wavelength and total dose characteristics for PDT” exist according to the British Dermatology group and the American Society of Photodynamic Therapy Board [9, 16, 17]. However, certain laser and light sources are predictably chosen for PDT activation. Their wavelengths correspond closely with the four absorption peaks along the porphyrin curve. The Soret band (400–410 nm), with a

maximal absorption at 405–409 nm, is the highest peak along this curve for photoactivating PpIX. Smaller peaks designated as the “Q bands” exist at approximately 505–510, 540–545, 580–584, and 630–635 nm [1, 2, 8]. There are advantages and disadvantages to exploiting the wavebands in either the Soret or Q bands for PDT. The Soret band peak is 10 to 20-fold larger than the Q bands, and blue light sources are often used to activate PpIX within this portion of the porphyrin curve, targeting lesions up to 2 mm in depth [14]. Longer wavelengths found within the Q bands produce a red light that penetrates more deeply (5 mm into the skin) but necessitates higher energy requirements [1, 8].

## Light Sources

Light sources used in PDT can be categorized in a variety of ways, including incoherent versus coherent sources, or by color (and wavelengths) emitted. Incoherent light is emitted as noncollimated light and is provided through broadband lamps, light emitting diodes (LEDs), and intense pulsed light (IPL) systems. Noncoherent light sources are easy to use, affordable, easily obtained, and portable due to their compact size [18]. The earliest uses in PDT were filtered slide projectors that emitted white light [1]. Metal halogen lamps such as the Curelight (Photocure, Oslo, Norway, 570–680 nm) are often employed in PDT as they provide an effective light source in a time, power, and cost-effective manner [1, 19]. In Europe, the PDT 1200 lamp (Waldmann Medizintechnik, VS-Schwennigen, Germany) gained in popularity, providing a unit with high power density emitting a circular field of light radiation from 600 to 800 nm [12, 19]. Short arc, tunable xenon lamps have also been used, emitting light radiation from 400 to 1,200 nm [12]. The only widely available fluorescent lamp used in conjunction with PDT is the Blu-U (DUSA, Wilmington, MA) with a peak emittance at  $417 \pm 5$  nm. LEDs provide a narrower spectrum of light irradiation, usually in a 20–50 nm bandwidth via a compact, solid, but powerful

semiconductor [1, 20]. LEDs are simple to operate and are typically small in size, emitting light from the UV to IR portion of the electromagnetic spectrum [20]. However, the diminutive size of most LED panels necessitates multiple rounds of light illumination to treat larger areas. IPL is yet another source of incoherent light, emitting a radiation spectrum from approximately 500 to 1,200 nm [20]. Cutoff filters allow customization of the delivered wavelengths. This light source is particularly useful in photorejuvenation, targeting pigment, blood vessels, and even collagen.

Lasers provide precise doses of light radiation. As collimated light sources, lasers deliver energy to target tissues at specific wavelengths chosen to mimic absorption peaks along the porphyrin curve. Lasers used in PDT include the tunable argon dye laser (blue-green light, 450–530 nm) [12], the copper vapor laser-pumped dye laser (510–578 nm), long-pulse pulsed dye lasers (PDL) (585–595 nm), the Nd:YAG KTP dye laser (532 nm), the gold vapor laser (628 nm), and solid-state diode lasers (630 nm) [19]. Although laser sources allow the physician to deliver light with exact specifications in terms of wavelength and fluence, the fluence rate should be kept in the range of 150–200 mW/cm<sup>2</sup> to avoid hyperthermic effects on tissue [1, 14]. In fact, there is evidence to support that cumulative light dose of greater than 40 J/cm<sup>2</sup> can deplete all available oxygen sources during the oxidation reaction, making higher doses of energy during PDT unnecessary [3].

---

## Clinical Applications

### Actinic Keratoses

#### Background and Epidemiology

Actinic keratoses (AK) are a premalignant skin condition, comprising the third most common reason and 14% of all dermatology office visits [21, 22]. Approximately 4 million Americans are diagnosed with AKs annually [23], and according to one Australian study, 60% of Caucasian Australians aged 40 or older develop

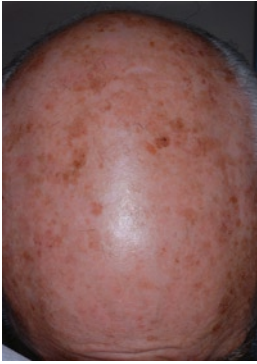this condition [24]. The prevalence of AKs within the US population ranges from 11 to 26% with the highest incidence in southern regions and older Caucasian patients [25].

The concern for untreated AKs is their rate of transformation to cutaneous squamous cell carcinoma (SCC). A small percentage of SCC metastasizes [26], and this is more likely in higher risk areas, such as mucous membranes (e.g., lips) [27]. The reported conversion rate of AK to SCC varies widely, estimated as 0.025–16% per lesion per year [28–32]. AKs may be considered an *in situ* SCC [33, 34], with AK resting on the precancerous end of a spectrum that leads toward invasive SCC. It has been suggested that the AK/SCC continuum be graded as “cutaneous intraepithelial neoplasia,” in a manner analogous to cervical malignancy. Further histopathologic evidence supports the link between AKs and SCC. Both lesions express tumor markers including the tumor suppressor gene p53 [35] and over 90% of biopsied SCCs have adjacent AKs within the examined histopathologic field [36].

#### Clinical Presentation and Diagnosis

AKs typically appear as 1–3 mm slightly scaly plaques on an erythematous base, often on a background of solar damage. They are often detected more easily through palpation than visual detection [37], due to their hyperkeratotic nature. The surrounding skin often shows signs of moderate to severe photodamage, including dyspigmentation, telangiectasias, and sallow coloration due to solar elastosis (Fig. 2.1). Individual AK lesions may converge, creating larger contiguous lesions. Most AKs are subclinical and not readily apparent to visual or palpable examination. The evidence for subclinical AKs is their fluorescence when exposed to ALA+Wood’s lamp or a specialized CCD camera [38].

Although often asymptomatic, AKs may have accompanying burning, pruritus, tenderness, or bleeding [22]. Several variants of AK exist, including nonhyperkeratotic (thin), hyperkeratotic, atrophic, lichenoid, verrucous, horn-like (cutaneous horn), and pigmented variants [25]. AKs on the lip, most often occurring on the lower

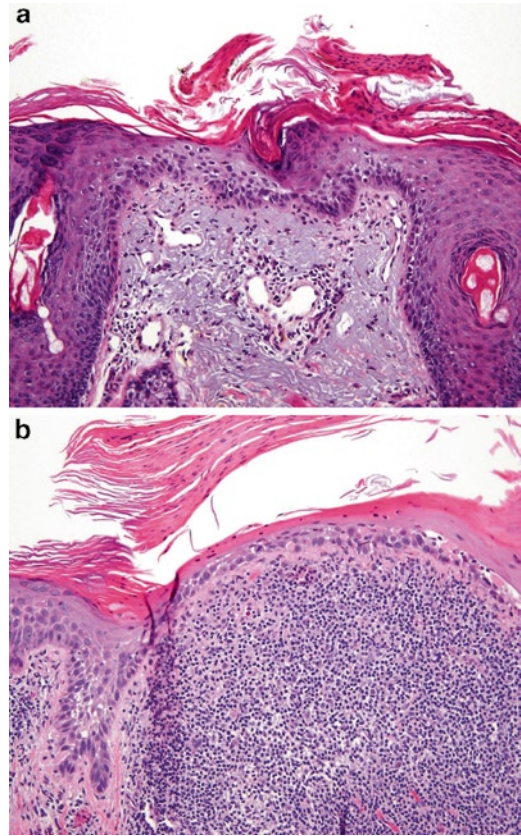


**Fig. 2.1** Frontal scalp of a 71-year-old white male demonstrating moderate to severe photodamage. Numerous actinic keratoses characterized by erythematous scaly slightly elevated plaques are visible on a background of extensive solar lentigines

lip, are designated as actinic cheilitis [27]. As AKs often result from a long history of UV exposure, the lesions usually arise in heavily sun-exposed areas including the scalp, face, ears, lips, chest, dorsal hands, and extensor forearms [39]. Risk factors for AKs include fair skin (Fitzpatrick skin type I–III), history of extensive, cumulative sun exposure, increasing age, elderly males (due to UV exposure), history of arsenic exposure, and immunosuppression [21, 22].

### Histopathology

Histopathologic examination of actinic keratoses is characterized by atypical keratinocytes and architectural disorder [22]. Early lesions demonstrate focal keratinocyte atypia originating at the basal layer of the epidermis and extending variably upward within the epidermis [40]. Hyperchromatic and pleomorphic nuclei and nuclear crowding characterize the cellular findings while architectural disorder is comprised of alternating ortho- and hyperkeratosis, hypogranulosis, and focal areas of downward budding in the basal layer of the epidermis [22, 25]. Solar elastosis is invariably present. Well-developed lesions may have apoptotic cells, mitotic figures, involvement of adnexal structures, lichenoid infiltrates, and a focal tendency toward full-thickness involvement (Fig. 2.2). Full-thickness atypia indicates transformation into SCC-in situ [25].



**Fig. 2.2** (a) Histopathologic section of actinic keratosis stained with hematoxylin and eosin at 20× magnification. Lesion is characterized by alternating ortho- and hyperkeratosis with nuclear atypia and architectural disorder. Keratinocyte atypia approaches full-thickness in middle area of lesion. Note the gray, fragmented nature of the papillary dermis representing extensive solar elastosis. (b) Actinic keratosis, lichenoid variant. A brisk lymphocytic infiltrate in the papillary dermis accompanies cytologic atypia of epidermal keratinocytes and marked architectural disorder. Numerous apoptotic cells are visible within the epidermis (Courtesy of Wenhua Liu, MD, Consolidated Pathology Consultants, Inc., Libertyville, IL)

### Treatment Rationale

*Treatment Options for AKs.* Given the premalignant potential of AKs, and the metastatic potential of SCC, early treatment is paramount to preventing disease progression. Treatment options for AKs depend on a variety of factors including severity of involvement, duration or persistence of lesions, patient tolerability or desire for cosmesis, affordability/insurance coverage, and physician comfort with available treatment modalities [22, 32].



Although AKs can reliably be diagnosed by clinical examination alone [41], a low threshold for biopsy should be exercised on atypical lesions, or lesions not responsive to prior treatment.

While singular or few lesions may be approached with local, surgical treatment such as cryotherapy, curettage, excision, or dermabrasion, field treatment may be more appropriate when numerous lesions are identified. In addition, field therapy will treat subclinical AKs. Chemical peels, laser resurfacing, 5-fluorouracil (5-FU), topical diclofenac, topical retinoids, and topical immunomodulators (imiquimod) are all reasonable treatment options in addition to PDT.

A comparison of PDT to other field treatment options for AKs yields comparable clearance rates [42, 43]. In fact, a comparison of 100% clearance rates from phase III clinical trials reported complete AK clearance with ALA-PDT of 72%, comparable to 5-FU (72%), and superior to imiquimod (49%) and diclofenac (48%) [23]. A direct comparison study by Kurwa et al. [44] found comparable lesion area reduction rates between ALA-PDT (73%) and 5-FU (70%).

### **Advantages/Disadvantages of ALA-PDT for AKs**

Clearance rates of AKs following PDT has ranged from 68 to 98% [45, 46]. Assuming near equivalent or even superior clearance rates of PDT compared to other field treatment options, PDT has several advantages in the treatment of AKs. Improvement of photodamage, superior cosmesis, and better patient satisfaction were documented in two studies by Szeimies et al. [43] and Goldman and Atkin [46]. Other procedures used for the clearance of AKs such as cryotherapy or chemical peels can result in hypopigmentation or even scarring [43, 47]. PDT, perhaps surprisingly to some, is a cost-effective means of treating AKs. Gold found ALA-PDT with a blue light source to be the least expensive treatment option for AKs compared to 5-FU, imiquimod, and diclofenac. In fact, ALA-PDT was approximately one-half the cost of a similar course of imiquimod for field AK treatment [23]. Additionally, PDT accomplished field treatment of precancerous lesions including subclinical ones [47].

Disadvantages of PDT are largely related to minor and expected adverse events following the procedure. Minor pain and erythema may occur during or following the procedure. Mild crusting and edema may occur, lasting up to 1 week. However, other treatment modalities for AKs have similar if not longer recovery periods. There are financial costs associated with the procedure. If PDT is performed for AK treatment and photorejuvenation, there is an associated out-of-pocket cost to the patient. The physician must also make an initial investment in the laser and light devices, although many of the light sources have multiple applications beyond PDT.

### **Treatment Results of ALA-PDT for AKs**

Kennedy et al. [48], in 1990, was the first to exploit the use of topical 5-ALA in the treatment of nonmelanoma skin cancers. Using a 20% ALA compound and a filtered slide projector for a light source, a complete response rate of 90% was achieved in patients with AKs. Since this initial study, a variety of light sources have been investigated for use in PDT for the treatment of AKs. As the PDT reaction is activated from an emission spectra ranging from 400 to 800 nm [49], we have organized clinical studies according to the light source used. Table 2.1 provides a summary of peer-reviewed articles on the use of ALA-PDT in AK treatment.

*Violet Light.* A relatively recent study published by Dijkstra et al. [49] in 2001 investigated the use of violet light in ALA-PDT. The use of this emission spectrum was based on the premise that violet light was ten times more effective than red light in photosensitization with ALA [49]. A study population of 38 patients with varying skin conditions including BCC (2 patients with Gorlin–Goltz syndrome), Bowen’s disease, and actinic keratoses were treated. A 20% ALA gel was applied to lesions for 8 hours under occlusion. Photoactivation followed using a lamp with a cold glass filter, emitting a spectrum of light between 400 and 450 nm. The sample size of AKs in this study was extremely small ( $n=4$ ), making conclusions about violet light in ALA-PDT difficult. A clearance rate for the four AKs treated

**Table 2.1** Published clinical studies on ALA-PDT for AKs

References	ALA preparation	Location of AKs	Incubation period (hours)	# Lesions treated (# patients)	Light source (wave-length in nm)	Response rate	Follow-up (months)
Kennedy et al. [48]	20% Emulsion	Not specified	3–6	10	Tungsten (>600)	90% CR	18
Wolf et al. [5]	20% Emulsion	Face and scalp	4–8	9	Tungsten, unfiltered	100% CR	3–12
Calzavara-Pinton et al. [1]	20% Cream	Face	6–8	50 (From pool of 85 patients with AKs, BCCs, SCCs, Bowen's)	Argon dye laser (630)	100% CR	24–36
Morton et al. [85]	20% Emulsion	Face and scalp	4	4	Xenon (630)	100% CR	12
Fijian et al. [86]	20% Emulsion	Not specified	20, Occluded	43 (9)	Halogen (570–690)	81% CR	3–20
Szeimies et al. [87]	10% Emulsion	Head, hands, arms	6, Occluded	36 (10)	Waldmann red lamp (580–740)	71% CR head	1
Fink-Puches et al. [61]	20% Emulsion	Head, neck, forearms, dorsal hands	4, Occluded	251 (28)	Halogen slide projector (300–800) with cutoff filters at 515, 530, 570, 610	71% CR	36
Fritsch et al. [54]	10% Ointment	Face and scalp	6, Occluded	(6)	Green lamp (543–548) vs. red Waldmann lamp (570–750)	100% CR for both green and red light	15
Jeffes et al. [56]	0–30% Emulsion	Face, scalp, trunk, extremities	3, Occluded	240 (40)	Argon dye laser (630)	91% CR face and scalp; 45% CR trunk and extremities	2
Karrer et al. [57]	20% Emulsion	Scalp, face	6, Occluded	200 (24)	Red light lamp (580–740) or PDL (585)	84% CR (red light) 79% CR (PDL)	1
Kurwa et al. [44]	20% Emulsion	Hands	4, Occluded	(14)	Metal halide lamp (580–740)	73% Lesion area reduction; comparable to 5-fluorouracil (5-FU)	6
Itoh et al. [58]	20% Emulsion, two or more sessions	Face, neck, extremities	4, Occluded	53 (10)	Red lamp (peak 630, range 600–700), excimer dye laser (630)	82% CR face and neck; 56% CR extremities	12
Dijkstra et al. [49]	20% Gel, two sessions	Unspecified	8, Occluded	4	Violet lamp (400–450)	50% CR	3–12
Jeffes et al. [42]	20% Solution	Face, scalp	14–18	70 (36)	Blue light (417)	85% CR	4

Markham and Collins [21]	% Concentration unspecified, cream	Scalp	4, Occluded	(4)	Red light (580–740)	75% CR	6
Varma et al. [59]	20% Ointment	Not specified	4, Occluded	127 (88 Patients with mixed diagnoses)	Waldmann red lamp (580–740)	77% CR after first, 99% after second, RR of 28%	6
Ruiz-Rodriguez et al. [65]	20% Emulsion	Face, scalp	4, Occluded	38	IPL (590–1,200)	76% CR one session; 91% CR two sessions	3
Alexiades-Amenakias and Geronemus [47]	20% Solution	Head, extremities, trunk	3 with Occlusion; 14–18 without occlusion	3,622 (36)	Long-pulsed PDL (595)	90–100% CR	8
Clark et al. [19]	20% Ointment	Not specified	4	23	Metal halide (590–730); Halogen lamp (570–680), diode laser (630)	91% CR	11
Goldman and Atkin [46]	20% Solution	Face, long-incubation PDT	15–20	(32)	Blue light (417)	94% CR of AKs; improved skin texture, pigmentation	3–6
Smith et al. [55]	20% Solution, two sessions	Face, scalp	1	(35)	Blue light (417) or PDL (595)	80% CR for blue light; 60% CR for PDL	1
Dragieva et al. [80]	20% Emulsion; transplant patients	Face, scalp	5, Occluded	32 (20)	Red light (580–740)	94% CR at 4 weeks; 72% at 48 weeks	12
Piacquadio et al. [52]	20% Solution, one to two sessions	Face, scalp	14–18	1,402 (243)	Blue (417)	91% CR one session; 83% CR two sessions	3
Touma et al. [6]	20% Solution	Face	1–3	(17)	Blue lamp (417)	87–94% CR	5
Gilbert [63]	20% Solution, 5-FU daily × 5 days pre-PDT	Face	0.5–0.75	(15)	IPL (560–1,200)	90% CR with combination therapy	12
Kim et al. [62]	20% Emulsion	Face	4, Occluded	12 (7)	IPL (555–950)	50%	3
Tschen et al. [41]	20% Solution, (one to two treatment sessions)	Face, scalp	14–18	968 (110)	Blue (417)	72–76% CR one session; 86% two sessions	12
Nakano et al. [17]	20% Cream (three treatment sessions)	Face	4, Occluded	(30)	Excimer dye laser (630)	100% CR in lesions <10 mm; 70% CR in lesions >10 mm diameter	12



with two sessions of PDT was 50% [49]. Although other lesions in the study had a more favorable clearance rate, further studies are needed to draw conclusions on the usefulness of violet light in PDT for precancerous skin lesions.

**Blue Light.** Perhaps the most popular emission spectrum used in the United States, blue light remains the only FDA-approved form of light for activating ALA (Fig. 2.3). As a result, numerous published studies exist on the use of blue light in ALA-PDT not only for the treatment of AKs, but also for other skin conditions responsive to this treatment modality. The relatively shorter wavelength of blue light only penetrates 1–2 mm but is potent in its photochemical effect, therefore blue light is often selected for the treatment of superficial lesions such as nonhyperkeratotic AK lesions [50].

In 2001, Jeffes et al. [42] published the results of a multicenter, phase II study of ALA-PDT using blue light (417 nm). A 14- to 18-hours incubation

was used on AK lesions of the face and scalp in 36 patients. A total of 70 lesions were treated. Light exposure duration was 16 minutes and 40 seconds, now considered standard of treatment. At 8 weeks following a single treatment, 88% of lesions cleared. Due to the extended time of incubation, an increased rate of phototoxic-related side effects was observed. These adverse effects included erythema and edema. A second phase II study was conducted with the same protocol, this time in a total of 64 patients [51]. All of the patients had 75% or more clearance of AK lesions following one treatment. However, 14% of patients required reduced power density during blue light irradiation due to intolerable side effects including stinging and burning. A final phase II study was a dose-ranging study of ALA solution from concentrations of 2.5–30% ALA. Clearance of AKs occurred in a dose-dependent manner, and a 20% concentration was selected as the most ideal concentration for use in ALA-PDT with blue light [51].

Piacquadio et al. [52] followed in 2004, publishing the results of a phase III clinical trial. The same long incubation and illumination times were used as in the phase II trial. A total of 243 patients with nonhyperkeratotic AKs were treated. Complete clearance at 12 weeks following one PDT session was 70%. A second treatment resulted in a complete clearance rate of 88%. Facial lesions responded more favorably than scalp lesions, with complete response rates of 78 and 50%, respectively, at week 12 following treatment. In terms of patient feedback, 94% of patients rated their cosmetic outcome following PDT as good or excellent. A recurrence rate analysis for this treatment cohort between 8 and 12 weeks post-treatment was 5% [51].

Several other studies examining the use of blue light in ALA-PDT for the treatment of nonhyperkeratotic AKs followed. In 2002, Gold [53] reported on facial AKs treated with blue light PDT. The response rate was favorable with 83% clearance. A separate study by Goldman and Atkin [46] demonstrated similar results. In both studies, photorejunative effects on the treated areas of the skin were noted.

In 2004, Touma et al. [6] reported on the efficacy of short-contact ALA-PDT. Not only did this allow for PDT to be conducted in a single



**Fig. 2.3** Noncoherent blue lamp is a common choice for photoactivating aminolevulinic acid (ALA) in the United States. The Blu-U (DUSA Pharmaceuticals, Inc., Wilmington, MA) emits light at a bandwidth of approximately  $417 \pm 5$  nm (Courtesy of DUSA Pharmaceuticals, Inc., Wilmington, MA)

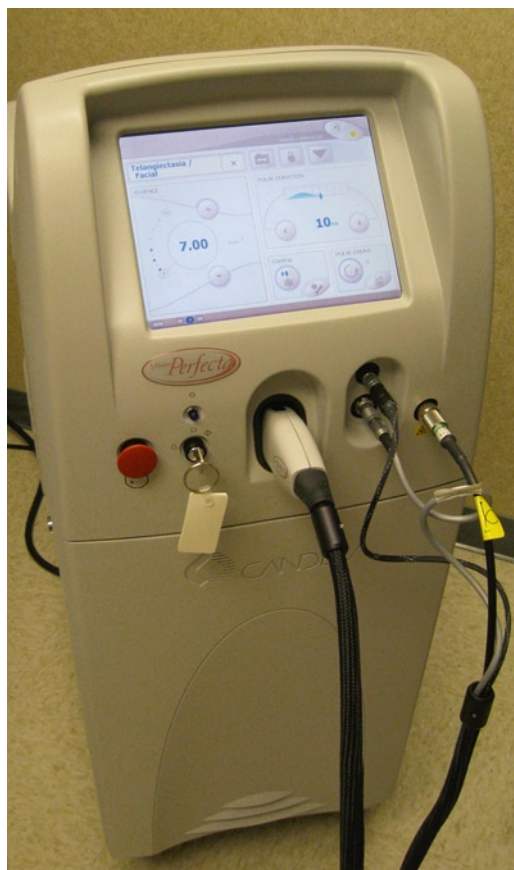clinic visit rather than over 2 days, but side effects related to the longer 14–18 h incubations were reduced. In this study, 17 patients with AKs of the face and scalp were treated with ALA using incubation times of 1, 2, or 3 h. A clearance rate of 93, 84, and 90% were achieved in the 1-, 2-, and 3-hour incubation groups, respectively. Clearance rates were maintained through 5 months of follow-up. In addition, this was the second study with blue light to demonstrate a modest but significant improvement in photoaging.

Work by Tschen et al. [41] confirmed earlier findings. This phase IV study of 101 patients with 6–12 AKs used a 14–18 hour ALA incubation time. After the first PDT, a complete clearance of 72–76% was observed, which increased to 86% with a second treatment.

**Green Light.** One study by Fritsch et al. [54] used a green light source for the treatment of AKs with ALA-PDT. The focus of this study was on patient discomfort. Compared to a red light source, light irradiation with a green light source (543–548 nm) was less painful in the treatment of facial AKs during PDT.

**Yellow-Orange Light: PDL.** Long-PDL (585–595 nm) (Fig. 2.4) target the chromophore oxy-hemoglobin, allowing selective destruction of blood vessels. As actinic keratoses often appear as erythematous scaly plaques, the inflammatory nature of these lesions can be targeted with this vascular laser. Alexiades-Amenakas and Geronemus [47] were the first to report on its use in ALA-PDT. Thirty-six patients and a total of 3,622 lesions were treated. Location of lesions included the face and scalp (2,620 lesions), extremities (949), and trunk (53). ALA was applied with either a 3 hour, unoccluded incubation versus a 14–18 hour incubation. No difference in clearance was observed between the two incubation time groups. Clearance rates were highest for head lesions at 100%. According to this large cohort study, it appeared that PDL at subpurpuric doses allows an efficient and less painful means of accomplishing PDT.

In 2003, Smith et al. [55] published a three-arm study on 36 patients with AKs. One arm received treatment with low concentration 5-FU, the other



**Fig. 2.4** Pulsed dye lasers (PDL) may be used as a light source for ALA-PDT to target individual lesions including AKs, sebaceous hyperplasia, and solar lentigines (Vbeam Perfecta [595 nm] laser image printed courtesy of Candela Corporation, Wayland, MA)

two arms received ALA-PDT – using either a PDL or blue light for photoactivation. A short, 1 hour unoccluded incubation was used. Clearance rates at 4 weeks follow-up were similar for 5-FU and ALA-PDL (79% vs. 80%). Clearance rates of PDT using a blue light source were lower (60%). Additionally, improvements in global photodamage, hyperpigmentation, and tactile roughness were observed [55].

**Red Light Sources.** The longer wavelength of red light allows deeper tissue penetration. Red light is used frequently during PDT with MAL. Red light may also be used for photoactivation of PpIX during ALA-PDT. Several laser and light sources emit wavelengths in the red light spectrum, usually targeted around 630 nm. These include the argon

pumped dye laser, excimer laser, metal halide lamps, and red LED lamps.

*Red Light from Laser Sources.* One of the earliest studies reporting on ALA-PDT was completed by Calzavara-Pinton et al. [1] using an argon pumped dye laser (630 nm). In the treatment of 50 facial AK lesions, 20% ALA cream was applied topically for 6–8 hours. The study's patient population also included a mixed pool of 85 total patients with diagnoses of Bowen's disease, SCCs, BCCs, and AKs. In terms of AK outcomes, a clearance rate of 100% was achieved at 24–36 months posttreatment.

The initial phase I clinical study for FDA-approval of ALA in PDT also utilized an argon pumped dye laser. Thirty-nine of the forty enrolled patients completed the dose-ranging study. Jeffes et al. [56] used 0–30% ALA topically with an extended incubation time of 14–18 hours. Ninety-one percent clearance was obtained in thin to well-developed AKs on the face and scalp that were treated with 30% ALA. Extremity treatment was not as successful with only 45% clearance of AKs on the limbs. Hyperkeratotic AKs did not respond well to therapy, and the small number of treated hyperkeratotic lesions precluded statistical analysis.

Recently, Nakano et al. [17] reported on the use of an excimer laser (630 nm) in patients of darker skin types. Thirty Japanese patients with AKs were divided into two groups based on lesion appearance. The first group included subjects with AK lesions 10 mm or less in diameter with the second group including larger lesions greater than 10 mm in diameter. Patients received three ALA-PDT sessions weekly for 3 weeks. A clinical and histological clearance of 100% was obtained in the small AK lesions group during the 1-year follow-up period. In the cohort with larger AK lesions, 6 of the 20 patients experienced residual lesions or recurrence. These findings are consistent with the poor penetration of ALA through thicker, hyperkeratotic lesions and resulting lower AK clearance rates.

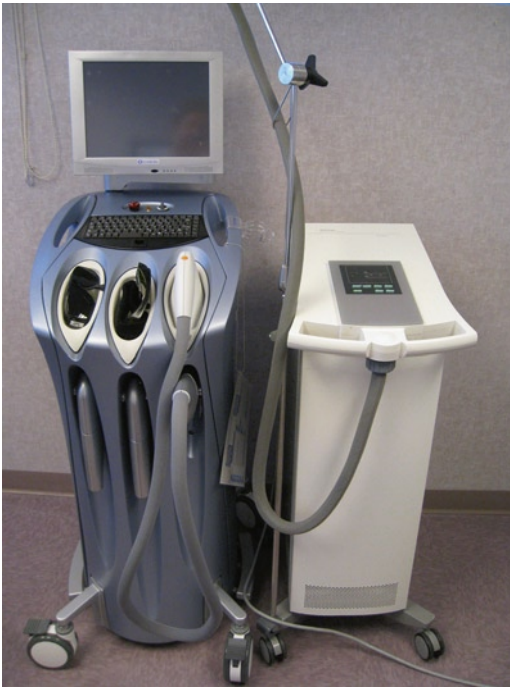*Incoherent Red Light Sources.* Metal halide lamps emitting a spectrum of light from 580 to

740 nm have been used in numerous ALA-PDT studies. Using the Waldmann/PDT 1200 lamp, 36 lesions in 10 patients were treated topically with ALA for 6 hours under occlusion followed by red light irradiation. On 28th day following treatment, the clearance of face and scalp lesions was 71%. Patient experienced pain and burning and mild postprocedure erythema.

Several studies followed shortly thereafter reporting clearance rates of facial AKs between 77 and 99%. Karrer et al. [57] treated 24 patients and 200 scalp and facial lesions with a clearance rate of 84% at 1 month following PDT. Kurwa et al. [44] used a metal halide lamp for ALA-PDT to treat the dorsal hands, resulting in a 79.5% decrease in AKs lesions. Itoh et al. [58] treated Japanese patients with AKs on the face, neck, and extremities. With two or more treatments, clearance rates at 12 months were higher for lesions on the head and neck (81.8%) compared with the extremities (55.6%). No serious adverse effects were reported in these patients with darker skin types. Markham and Collins [21] treated four patients with topical ALA under occlusion for 4 hours for scalp AKs. Three patients cleared following treatment, and the remaining patient had significant improvement at 6 months. Varma et al. [59] treated 88 patients with ALA-PDT using a red lamp for a variety of diagnoses including AKs (127 lesions), Bowen's disease (50), and superficial BCC (62). Complete clearance rate for AKs after one and two treatments were 77 and 99%, respectively. However, the recurrence rate at 12 months was 28%. Mild stinging, tingling, or burning was reported by most patients. Another study also treated patients of mixed diagnoses. AKs, BCC, and SCC-in situ in 762 patients were treated by Moseley et al. [60]. Ninety-two percent of AKs cleared after two treatments, with 100% clearance after three PDT sessions. Finally, Clark et al. [19], using a topical 20% ointment, treated 207 patients with 483 lesions. An impressive 91% clearance was observed clinically at a median of 48 weeks following treatment.

*Broad Band/Visible Light Sources.* The earliest light sources used for the treatment of AKs during the modern PDT era produced

unfiltered, noncollimated light for photoactivation. Following the work by Kennedy et al. [48], Wolf et al. [5] in 1993 reported on the complete clearance of nine AKs after one round of treatment using a slide projector for a light source. Fink-Puches et al. [61] used a modified halogen slide projector with four filter cutoffs at 515, 530, 570, and 610 nm. AK lesions of the head, neck, forearms, and dorsal hand lesions were treated with 20% ALA for 4 hours under occlusion prior to light irradiation. Overall complete response after one treatment was 64%, increasing to 85% with a second treatment. Head and neck lesions responded better than extremity lesions. Head and neck complete response rates varied from 93 to 100% depending on the spectrum of light used for treatment. Forearms and hands had a lower response rate ranging from 33 to 53%. Overall complete response rate at 36 months was 23% for filtered light and 71% for full spectrum light.



**Fig. 2.5** Intense pulsed light (IPL) devices are particularly effective in ALA-PDT for photorejuvenation. Cooled conductive gel and forced air cooling units minimize discomfort during treatment (Lumenis One IPL device courtesy of Lumenis, Inc., Santa Clara, CA)

IPL devices (Fig. 2.5) are powerful tools for treating the signs of photoaging. Their use in photorejuvenation with ALA-PDT is discussed in a separate section of this chapter. However, a small study by Kim et al. [62] documented the use of ALA-IPL for the treatment of AKs exclusively. Twelve facial AK lesions in seven patients were treated with one session of ALA-PDT. At 12 weeks follow-up, 50% of lesions cleared. This clearance rate is markedly lower than reported averages, but it is difficult to formulate sound conclusions based on the small sample size.

### Combination Therapy for AK Treatment

Several small case studies have demonstrated a possible synergistic effect of ALA-PDT with other treatment options for AKs. Combination 5-FU cream with PDT was tested in a study by Gilbert [63]. Fifteen patients with multiple AKs completed a 5-day course of nightly 5-FU cream to the face followed by short-contact PDT activated by an IPL light source. A clearance rate of 90% was observed at 1 year follow-up. Shaffelburg [64] conducted a split-face study of 24 patients with multiple AKs, in which ALA-PDT was performed on the entire face. One-half of the face was also randomized to receive additional subsequent treatment with a 12-week regimen of imiquimod. Clearance rates at 12 months were superior on the combination treatment side, with 89.9% complete lesion clearance compared with 74.5% on the ALA-PDT treatment side alone.

## Photorejuvenation

### Definition of Photoaging

Photodamage is a marker of cumulative ultraviolet exposure and senescent changes to the skin. Not only can the appearance be of concern to the patient, but it can also lead to pre-cancerous conditions with the development of actinic keratoses [65]. The characteristic appearance of photodamaged skin includes sallowness, discoloration, inelasticity, rhytid formation, pigmentary alteration, ectatic vessels/telangiectasias, and textural alterations [18]. Global photodamage scales have been developed for scoring the severity of skin involvement. Dover used a



5-point scale in evaluating several categories of photodamage including fine surface lines, mottled pigmentation, sallowness, tactile roughness, coarse wrinkling, and global photodamage [66]. Working from this initial scale, others have added facial erythema, telangiectasias, sebaceous gland hyperplasia, and facial AKs as separate categories in the evaluation of photodamage [67, 68].

### **Light Sources in ALA-PDT Photorejuvenation**

Many of the same lasers and light sources effective in ALA-PDT for the treatment of AKs have the added benefit of inducing photorejuvenative effects on the skin. Chromophores targeted during PDT treatment may include vessels, melanin, and even collagen [67]. Blue light only allows for a photochemical effect in PDT with less tissue penetration than other light sources such as IPL and PDL. The latter sources penetrate deeply enough to target vessels, pigment, and collagen [69]. The choice of which light source to use for ALA-PDT ultimately depends on such factors as the condition being treated, efficacy, cost of use, and availability of equipment.

### **Treatment Results of ALA-PDT in Photorejuvenation**

Studies relating to the treatment of photodamage with ALA-PDT are organized in the section below according to the light source employed. A summary of these studies is provided in Table 2.2.

*PDT with Blue Light.* Despite the shallow penetration of blue light, it still appears to improve the signs of photoaging following ALA-PDT. The first indication that blue light had photorejuvenative effects in PDT was with the phase II/III clinical trials for FDA-approval of Levulan for nonhyperkeratotic AKs. In these studies, significant improvement in the signs of photoaging was noted after treatment [42, 52, 70].

Photorejuvenation studies using the blue light source have also been conducted by Goldman and Atkin [46], where a blue light source was used to illuminate the face after the topical application of ALA. Thirty-two patients with photodamage and AKs were treated with one session

of ALA-PDT using a 1-h ALA incubation followed by Blu-U activation. AKs showed a 90% improvement in terms of photorejuvenation parameters, a 72% improvement in skin texture, and a 59% improvement in skin pigmentation. Gold [53] reported on the dual use of blue light ALA-PDT for AKs and photoaging. The treatment of nonhyperkeratotic facial AKs also resulted in an improvement of skin elasticity and texture in patients with photodamaged skin.

Touma et al. [6] studied the effectiveness of ALA and blue light illumination in the treatment of AKs and diffuse photodamage. Eighteen patients with facial non-hypertrophic AKs and mild to moderate facial photodamage were evaluated. Short-contact ALA was applied from 1 to 3 hours with subsequent exposure to blue light. At 1 and 5 month follow-up intervals, there was a significant reduction in AKs. In addition, marked improvement in photodamage parameters such as skin quality, fine wrinkling, and sallowness were observed. Other markers of photodamage, such as pigmentary changes and coarse wrinkling showed little to no improvement. Patients were also satisfied with the procedure, with 80% of patients rating their results as good to excellent. Other findings make this an intriguing study. This clinical study was pivotal in shifting treatment of AKs from long, 14–18 hour incubation times to shorter contact times. In addition, study patients were pretreated with microdermabrasion prior to topical ALA application, leading to more uniform and rapid penetration of ALA.

A final study by Smith et al. [55] examined the use of blue light ALA-PDT in diffuse photodamage. As discussed in the section “Actinic Keratoses (AK)” of this chapter, this study was a three-arm study comparing topical, low concentration 5-FU to two forms of short-contact ALA-PDT – one arm with activation from a blue light source, the other with a PDL. While one patient in the 5-FU group discontinued due to a confluent erythematous reaction, all patients in the ALA-PDT group completed the study. In both ALA-PDT groups, patients experienced improvement in global photodamage, hyperpigmentation, and tactile roughness. The ALA-PDL was more successful in treating pigmentation, while blue light had lower response

**Table 2.2** Published clinical studies on ALA-PDT for photorejuvenation

References	ALA preparation	Location of photodamage/study design	Incubation period (hours)	# Patients	Light source (emission $\lambda$ , nm)	Response	Follow-up (months)
Ruiz-Rodriguez et al. [65]	20% Emulsion	Face and scalp, more than or equal to one AK and chronic photodamage; two PDT sessions	4, Occluded	17 (38 AKs)	IPL (590–1,200)	87% CR of AKs; excellent cosmesis	3
Goldman and Atkin [46]	20% Solution	Face, long-incubation PDT	15–20	32	Blue light (417)	94% CR of AKs; improved skin texture, pigmentation	3–6
Smith et al. [55]	20% Solution, two sessions	Face, scalp	1	35	Blue light (417) or PDL (595)	80% CR for AKs with blue light; 60% CR for PDL; both demonstrated improvement in global photodamage, tactile roughness, and hyperpigmentation	1
Touma et al. [6]	20% Solution	Facial AK and mild–moderate photodamage	1–3	17	Blue light (417)	Improvement in photodamage markers, including skin quality, fine rhytides, and sallowness	1–5
Avram and Goldman [74]	20% Solution	Facial photodamage (with AKs) treated with one ALA-IPL session	1	17	IPL	69% CR of AKs; improvement in telangiectasias, dyspigmentation, skin texture	3
Alster et al. [75]	20% Solution	Split-face comparison, IPL vs. ALA-IPL	1–3	10	IPL (500–1,200)	ALA-IPL treated side showed greater improvement	6
Dover et al. [66]	20% Solution	Split-face comparison, IPL vs. ALA-IPL (five treatment sessions)	0.5–1	20	IPL (515–1,200)	Greater improvement in ALA-IPL over IPL only for global photoaging, pigmentation, and fine lines only	1

(continued)



Table 2.2 (continued)

References	ALA preparation	Location of photodamage/study design	Incubation period (hours)	# Patients	Light source (emission $\lambda$ , nm)	Response	Follow-up (months)
Key [78]	20% Solution	Face, subpurpuric doses of PDL	1	12	PDL (585)	Improvement in majority of photodamage parameters with ALA-PDL; no improvement with PDL alone	1
Lowe and Lowe [72]	5–20% Cream	Forearm, periorbital	0.5–2	6	Red light (633)	Mild improvement noted in photoaging	0.25
Marmur et al. [76]	20% Solution	Split-face comparison, IPL vs. ALA-IPL (1 treatment)	1	7	IPL	Microscopic changes demonstrated greater type I collagen on ALA-IPL side	N/A
Gold et al. [68]	20% Solution	Split-face comparison, IPL vs. ALA-IPL (three treatment sessions)	0.5–1	16	IPL (550/570 cutoff filters-1,200)	ALA-IPL results superior to IPL alone	1–3
Serrano et al. [77]	1–2% Gel	Multiple application, low concentration ALA-PDT to face, neck, hands (three treatment sessions)	0.5–1	8/26 Patients with photoaging; 18/26 treated for acne, vitiligo	IPL (530–1,200) or yellow-red lamp (550–630)	90% of cases with hyperpigmentation improvement; erythema (85%), skin texture (100%)	6

rates to global photoaging. Interestingly, the blue light ALA-PDT was the only treatment arm to have photoaging completely resolve in one patient.

**PDT with Red Light.** Two of the three studies regarding red light PDT for the treatment of photoaging used MAL rather than ALA. These studies by Szeimies et al. [43] and Pariser et al. [71] demonstrated excellent cosmetic results and are discussed in Chap. 16.

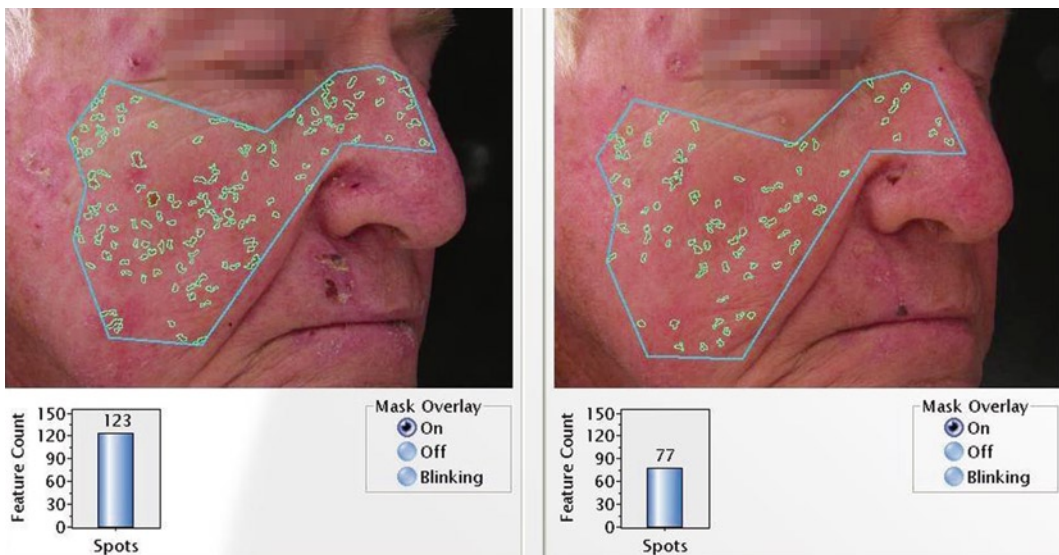
One small pilot study conducted by Lowe and Lowe [72] investigated the use of ALA-PDT for the treatment of photoaging on the forearm and periorbital region. Escalating concentrations of ALA (5–20%) and increasing incubation times (30–120 min) were used prior to light irradiation with a red light source (633 nm). Mild improvement in signs of photoaging was noted at 7 days following treatment.

**PDT with IPL.** IPL is a light source that emits noncollimated, noncoherent light with wavelengths in the range of 515–1,200 nm, which corresponds to the visible light and near-infrared spectrum [20]. Various filters can be used to block certain wavelengths below the cut-off point of the desired filter. IPL treatments improve

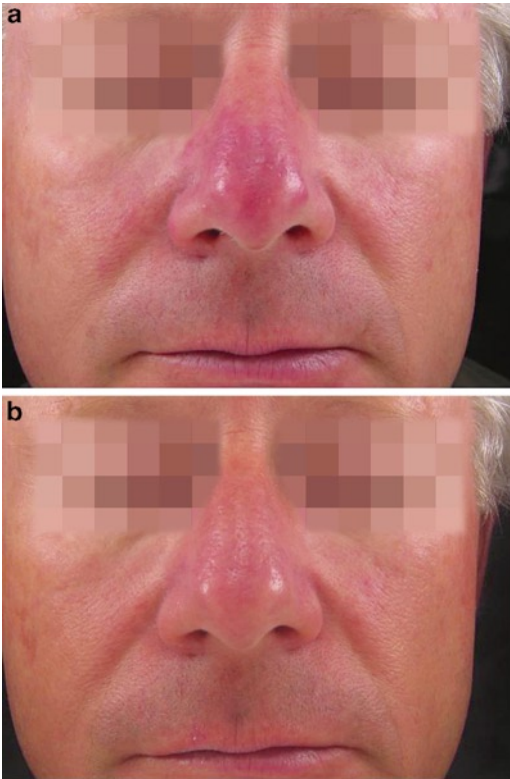
many of the signs of photoaging, including pigmentation in the form of solar lentigines, erythema, and telangiectasias due to vascular ectasia/damage, as well as fine wrinkling [20]. Like the PDL, IPL treatments also promotes neocollagenesis [73]. Although IPL alone has been proven effective in the treatment of photodamage, the addition of ALA to IPL treatment (ALA-IPL) appears to be more effective in treating photodamaged skin. Clinical examples of ALA-IPL treatment for photorejuvenation are illustrated in Figs. 2.6 and 2.7.

In 2002, Ruiz-Rodriguez et al. [65] investigated the treatment of photodamage and AKs using ALA-PDT with IPL as the light source for photorejuvenation. Seventeen patients with various degrees of photodamage and AKs (38 AKs total) underwent therapy with ALA-IPL. A total of two treatments were performed 1 month apart. Treatments were well-tolerated. At 3 months follow-up, 87% of AKs disappeared and marked cosmetic improvement was noted in wrinkling, coarse skin texture, pigmentary changes, and telangiectasias.

Multiple studies followed the initial results of Ruiz-Rodriguez and coworkers. Avram and Goldman [74] evaluated the combined use of ALA-IPL for the treatment of photorejuvenation with



**Fig. 2.6** Complexion analysis of the right cheek of a white male before and after one ALA-PDT session for photorejuvenation. A 47% decrease in *brown spots* (solar lentigines) was quantified using the computer software system



**Fig. 2.7** (a) White male with moderate erythema and telangiectasias concentrated over the nose on a background of mild/moderate photodamage. The patient had received a single treatment of IPL without significant clearance. (b) Significant improvement after one treatment of ALA-PDT

one treatment session. Sixty-nine percent of the AKs responded to the use of ALA-IPL. Additionally, a 55% improvement in telangiectasias, 48% improvement in pigment irregularities, and 25% improvement in skin texture were observed.

Alster et al. [75] also examined the use of IPL in ALA-PDT. Ten patients with mild to moderate photodamage underwent two sessions of split-face treatment. Patients received treatment with ALA-IPL on one side and IPL alone on the contralateral side at 4-week intervals. Clinical improvement scores were noted to be higher on the side of the face treated with the combination of ALA-IPL. They concluded that the combination of topical 5-ALA + IPL is safe and more effective than IPL alone for the treatment of facial rejuvenation.

Another split face study on ALA-IPL versus IPL alone was performed by Dover et al. [66]. In this study, 20 subjects had 3 split-face treatments 3 weeks apart. Half of the face was treated with ALA followed by IPL treatment and the other half was treated with IPL alone. A blinded investigator was used to evaluate global photodamage, fine lines, mottled pigmentation, tactile roughness, and sallowness during the study. They concluded that pretreatment with ALA followed by IPL resulted in greater improvement in global photoaging (80% vs. 50%) and mottled pigmentation (95% vs. 65%). Successful results were also noted for fine lines for the ALA-IPL side compared with the IPL side alone (55% vs. 20%). Although tactile roughness and sallowness were noticeably better, pretreatment with ALA did not enhance the results of using IPL alone. It was important to note that both modes of treatment were well tolerated and that no significant differences in the side effect profiles were observed. This study was important not only for its demonstration and safety of IPL in the use of ALA-PDT, but for the development of a photo-damage rating scale.

A final split-face comparative study for photo-rejuvenation using ALA-IPL versus IPL alone was performed by Gold et al. [68]. Thirteen patients received short-contact ALA-IPL on one side of the face and IPL alone on the contralateral side. Photoaging categories including fine wrinkling (crow's feet), tactile skin roughness, mottled pigmentation, telangiectasias, and AKs were evaluated. All demonstrated a better response on the side of the face treated with ALA-PDT. This study demonstrated the enhancing effects of ALA-PDT in IPL photorejuvenation.

Marmur et al. [76] conducted a pilot study to assess the ultrastructural changes seen after ALA-IPL photorejuvenation. Seven adult subjects were treated with a full-face IPL treatment. Half of the face in the study subjects received pretreatment with topical ALA before the IPL treatment. Pre- and posttreatment biopsies were reviewed by electron microscope for changes in collagen. A greater increase in type I collagen was noted in the subjects that were pretreated with ALA-IPL as opposed to the group treated with IPL alone.

They concluded that the addition of ALA-PDT using IPL could be superior to IPL alone.

A more recent study by Serrano et al. [77] in 2009 examined the use of ALA-IPL for the treatment of acne, vitiligo, and photoaging. Twenty-six patients in total completed the study, eight of which were in the photoaging treatment arm. Low concentration ALA (1–2%) was used for incubation prior to light exposure. Improvement in several photoaging parameters were noted in the majority of patients. One hundred percent of cases had skin texture improvement; erythema/telangiectasia, and hyperpigmentation were improved in 85 and 90% of cases, respectively. Eighty-eight percent of patients were satisfied with the results after three sessions of ALA-PDT.

**PDT with PDL.** PDL have also been studied as a light source for photorejuvenation in ALA-PDT. PDL targets oxyhemoglobin as a chromophore according to the theory of selective photothermolysis. But thermal energy generated in the surrounding areas adjacent to targeted blood vessels may also result in photorejuvenative effects. Subpurpuric doses from the PDL alter dermal collagen and may improve skin texture [20].

Alexiades-Amenakas and Geronemus [47] found ALA-PDT with the 595 nm PDL was successful in treating face and scalp AKs. Additionally, in this large study of 2,561 lesions, areas treated showed signs of photorejuvenation.

Key [78] treated 14 patients with long-incubation ALA (12 h) followed by photoactivation using a PDL. Improvement was noted following ALA-PDL in terms of skin texture, tactile quality, and brown spots, although the degree of vascularity and seborrheic keratoses were unaffected by treatment. The lack of improvement in blood vessel lesions is curious given that PDL targets the vasculature.

*Summary of Findings for ALA-PDT in AK Treatment and Photorejuvenation.* These results show the potential usefulness of a variety of lasers and light sources in the treatment of actinic keratoses and in the improvement of photodamage and photorejuvenation utilizing 5-ALA based PDT treatments. Beyond the treatment of

AKs, ALA-PDT offers beneficial cosmetic outcomes in photorejuvenation.

---

## Patient Selection for ALA-PDT

Thoughtful selection of eligible patients for ALA-PDT benefits both physician and patient. Patients should be carefully screened at an initial clinical consultation for inclusion and exclusion criteria for PDT. Physicians should gauge whether a patient has an accurate understanding and realistic expectations of the procedure. This will maximize patient's results, reduce patient's anxiety, and ensure the PDT is conducted smoothly on the day of the procedure. A comprehensive consent that explains the risks, benefits, and complications of therapy as well as treatment alternatives should be reviewed with patients carefully prior to treatment.

## Exclusion Criteria

Patients should be screened for important exclusion criteria prior to undergoing PDT. A history of photosensitivity including porphyria, photodermatoses, and photosensitizing medication use should preclude treatment [46, 56, 67]. Many studies have excluded patients from treatment if they have undergone treatment with systemic retinoids, chemotherapeutic agents, or immunotherapy in the past 6 months [42, 56, 72]. Pregnant or nursing women and individuals with an active infection should not undergo treatment [41, 42]. Patients should refrain from topical retinoids, alpha hydroxy acids, and chemical peels approximately 1 month prior to treatment [56].

## Unique Patient Populations

Solid organ transplant recipients (OTR) suffer from a 10 to 250-fold increase in AKs due to their ongoing immunosuppressive therapy [79]. In addition, the precancerous and cancerous lesions developing in the OTR population are often more aggressive [79], requiring frequent

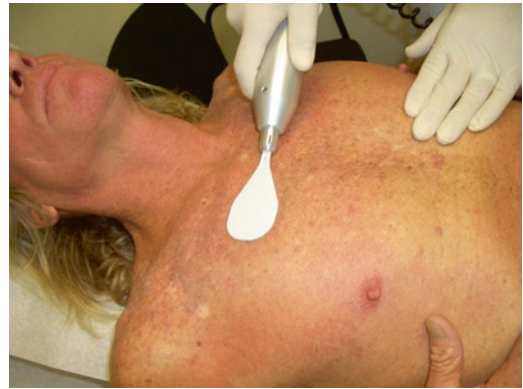and ongoing cancer surveillance. PDT, a safe and effective treatment option for precancerous and malignant lesions, offered a new treatment modality for controlling AKs and nonmelanoma skin cancers in the OTR population. Although initial response rates of AKs following PDT were comparable in the OTR patient population compared with normal controls [80], longer-term follow-up demonstrated statistically significant decreases in clearance rates in the OTR population. In addition, SCC of the dorsal hands and forearms were not prevented in OTRs in a 2-year follow-up study, although there was a trend toward decreased keratotic regions in the areas treated [81]. PDT may still be a viable treatment option in this population, but it may require adjustments to typical treatment protocols including increased frequency of PDT sessions [80] and use of longer wavelengths (red light) for deeper skin penetration [81].

## Treatment Protocol

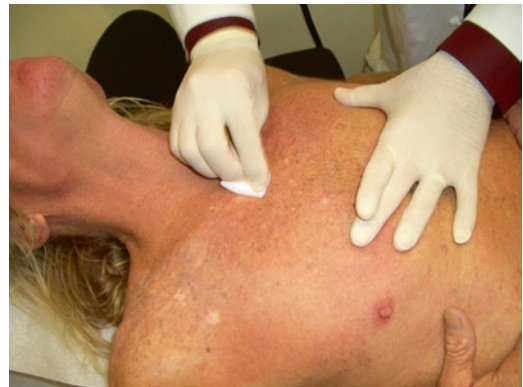### Skin Preparation

Optimal results following ALA-PDT can be achieved with proper preparation prior to the procedure itself. The stratum corneum is a major barrier to the penetration of 5-ALA [22, 51]. Hyperkeratotic lesions must be treated with light curettage prior to 5-ALA application. Otherwise, ALA is preferentially absorbed by the hyperkeratotic scale rather than the lesion intended for treatment [21]. Some physicians use occlusion to improve delivery of 5-ALA through thicker lesions. Tegaderm™, opaque Mepore®, or Glad Press-N-Seal® may be used for these purposes.

Methods of proper skin preparation to reduce stratum corneum thickness also include light chemical peels, tape stripping, microdermabrasion, and degreasing of the skin with acetone [16, 69, 82, 83]. All the above measures can improve the absorption of ALA by the skin [22]. We routinely use a vibrating microdermabrasion system (Vibraderm, Great Plains, TX) (Fig. 2.8) with subsequent acetone degreasing to prepare the skin for 5-ALA application (Fig. 2.9).



**Fig. 2.8** Proper skin preparation prior to ALA application removes excess layers of the stratum corneum and improves ALA penetration. We use a vibrating microdermabrasion device for 5 min prior to acetone degreasing

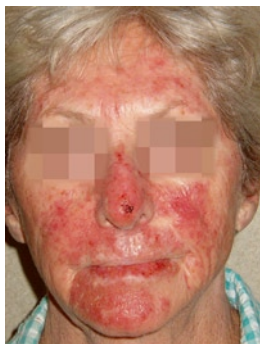

**Fig. 2.9** Acetone-soaked gauze following microdermabrasion enhances ALA delivery. Firm pressure should be used during scrubbing to remove excess skin lipids and keratinocytes

### Incubation Time

5-ALA is FDA-approved for use with a 14–18 hour incubation and subsequent photoactivation with blue light [10]. However, longer incubation times often results in an increased severity of adverse effects following ALA-PDT (Fig. 2.10) [42], and furthermore, shorter incubation times (1–3 h) have demonstrated similar efficacy in AK clearance [6, 55]. We routinely use a 60-minute incubation time in the treatment of AKs or for photorejuvenation. When treating thicker, larger, or more invasive lesions, we extend the incubation time to 3 hours and occlude the treated area with Glad Press ‘N Seal®.





**Fig. 2.10** Moderate/severe phototoxic reaction due to extended ALA incubation period. This woman had ALA-PDT with a 3-hour, unoccluded incubation. The patient denied UV exposure for the 36 h following photodynamic therapy (PDT)

## Light Sources

Blue, red, green, and broad-band light sources may be used to activate PpIX during ALA-PDT for AKs or photorejuvenation. There is some evidence that blue light may be more effective for superficial AKs due to the shorter wavelength and increased potency during PDT of blue light [69]. Green light was found to cause less pain than red light in the treatment of AKs [54]. Red light has a deeper depth of penetration, but is often used with MAL rather than ALA. Broad band light sources including IPL have the advantage of improving signs of photodamage. It is our practice, both in the treatment of AKs and photorejuvenation, to use multiple light sources during ALA-PDT. With a typical treatment, we treat individual lesions first with subpurpuric doses of a PDL, followed by full-face treatment by an IPL, and lastly illumination with a blue and/or red light source. It should be noted that the IPL also results in hair reduction, so judicious use should be exercised in hair-bearing areas such as the scalp and beard area.

## Patient Comfort and Photoprotection and Follow-Up

We do not routinely use topical or intralesional anesthesia prior to ALA-PDT. With a 1-hour incubation time, our clinical experience is that the procedure is well-tolerated by the overwhelming majority of patients. We use forced air cooling (see Fig. 2.5) and

refrigerated conductive gel during the IPL portion of photoactivation, and a cooling fan with aerosolized water during blue light exposure. For longer incubation periods, the use of oral analgesics, topical lidocaine preparations, and ice packs in conjunction with PDT may increase patient's comfort [46].

Immediately following treatment, we apply an aloe vera-based gel to the treated skin to calm erythema and irritation. A sunblock (physical blocker) containing zinc oxide and titanium dioxide is applied to the treated skin. To avoid phototoxicity during daylight hours, our patients are scheduled for treatment in the late afternoon, so they may depart the clinic during twilight hours. Patients are given a protective visor if the face was treated, and patients are asked to wear sunglasses and protective clothing during their ride home.

We instruct patients to avoid sunlight and bright indoor light sources for 36 hours following treatment. We request patients return to clinic at 1 week and 2 months following PDT for routine follow-up. We perform subsequent rounds of ALA-PDT at 1–2 months intervals. We counsel patients to anticipate two ALA-PDT sessions for the treatment of AKs, while photorejuvenation, especially when sebaceous hyperplasia is present, usually requires three to four sessions. These recommendations are consistent with consensus guidelines from the American Society of Photodynamic Therapy [9].

## Clinical Technique

Summarized below is our treatment protocol for ALA-PDT [2]. This is supplied as an example, but is by no means the only way to successfully perform PDT. This may be used as a general guideline and practitioners must decide for themselves the most effective and efficient use of ALA-PDT in their office.

## Aminolevulinic Acid-Photodynamic Therapy for Actinic Keratoses and Photorejuvenation

1. Cleanse the patient's skin with mild soap and water (Cetaphil cleanser or Neutrogena Foaming Facial Wash).
2. Perform microdermabrasion with the Vibraderm over the treated area (Fig. 2.8).



3. Scrub the skin virgorously using a 4×4 in. acetone-soaked gauze (Fig. 2.9).
4. Break the two glass ampules in the Levulan Kerastick as per the package insert [10]. Shake the stick for about 2 min.
5. Apply the ALA solution to the treatment area. This is best accomplished by painting the Levulan on using the application stick. At least two coats of the solution are recommended, and the entire contents of the Kerastick should be used. It is important to get close to the eyes, otherwise it will be apparent that the periorbital skin was not treated.
6. Allow the Levulan to incubate for 60 minutes on the skin. The patient should remain indoors during the incubation period.
7. Remove the Levulan prior to any light treatment by requesting the patient to wash his or her face with a gentle soap and water.
8. Activate the Levulan with the appropriate light source(s):
  - AKs: PDL is used to target individual lesions at subpurpuric settings, followed by 16 minutes and 40 seconds of treatment with blue light. The Blu-U should be positioned approximately 2 inches from the treatment area.
  - Photorejuvenation +/- AKs: PDL is used to target individual lesions at subpurpuric settings including AKs, sebaceous hyperplasia, solar lentigines, and telangiectasias. IPL treatment follows, using a double pulse and 560 nm cut-off filter for Fitzpatrick skin types I–III. Fluence, pulse duration, and pulse delay settings are determined according to skin type and type of photodamage. Lastly, the patient is treated with the Blu-U and/or red-light in a similar manner to the AK protocol (Fig. 2.11).
9. Wash the patient's face again to remove any residual Levulan on the skin's surface.
10. Apply soothing gel or lotion (we recommend an aloe vera-based gel) to the treated area after the illumination period.
11. Apply a physical sunblock containing zinc oxide and titanium dioxide to the treated area. Instruct the patient on strict photoprotection for the following 36 hours. The patient is to remain indoors, out of direct sunlight.
12. Patients are given Avene Thermal Spring Water spray to apply to their skin four to six times a day.
13. Repeat the treatment in 4–8 weeks. If there was little reaction, increase the incubation time or reevaluate your skin preparation technique.

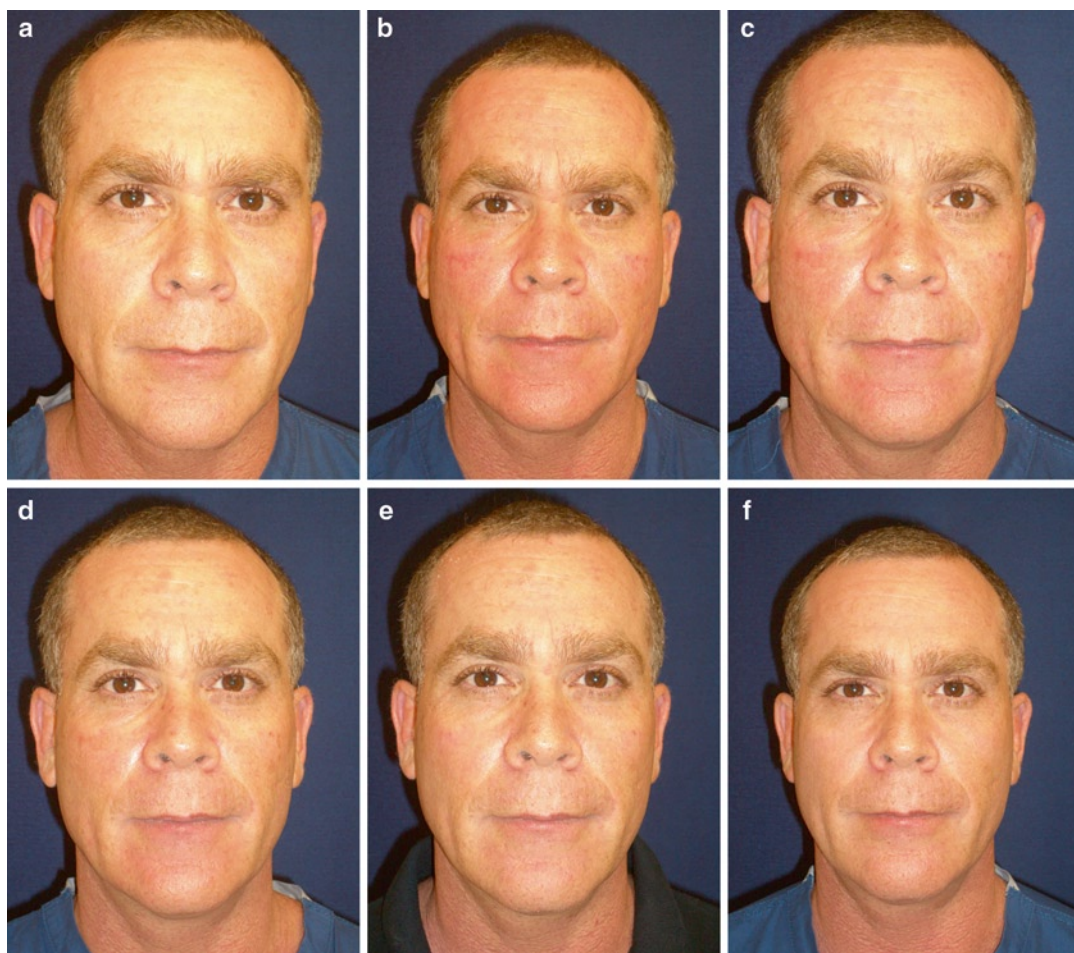---

## Safety, Adverse Effects, and Complications

Expected side effects following ALA-PDT are related to the phototoxic nature of treatment and are usually mild in nature. Pain and burning may be experienced during light irradiation. Shorter incubation times decrease the severity of side effects. Expected phototoxic side effects include erythema, edema, stinging/burning, pruritus, and crusting. Pigmentary changes, whealing, and vesiculation may also occur [12, 41, 43]. Erythema and mild crusting occur in most patients following treatment, usually resolving in 1–2 weeks [60]. Hypopigmentation is rare, and hyperpigmentation, with an incidence as high as 27% following ALA-PDT [41], is usually mild in nature. More pronounced reactions are correlated with disease burden. Typically, repeat treatments are less painful than previous ones.

In patients with extensive phototoxic reactions (Fig. 2.12), especially in cases when patients are exposed to UV radiation in the 24–36 hours following treatment, topical therapy may be necessary to address erythema, edema, and crusting. Topical steroid creams and ice packs may be used on the treated area until the symptoms subside. All patients should be screened for a history of cold sores and appropriate HSV prophylaxis begun prior to treatment in such cases [2].

Pain management, especially with shorter incubation times (e.g., 1 hour), is usually a nonissue. Reassurance to the patient and “talk-anesthesia” by a caring member of the clinical staff is usually more than adequate to comfort any patient's anxiety and pain. However, the use of cooling fans, Avene Thermal Water Spray, forced air cooling systems, Xylocaine spray, and even oral non-narcotic pain medication have been used successfully to mitigate pain during ALA-PDT [6, 41, 60].



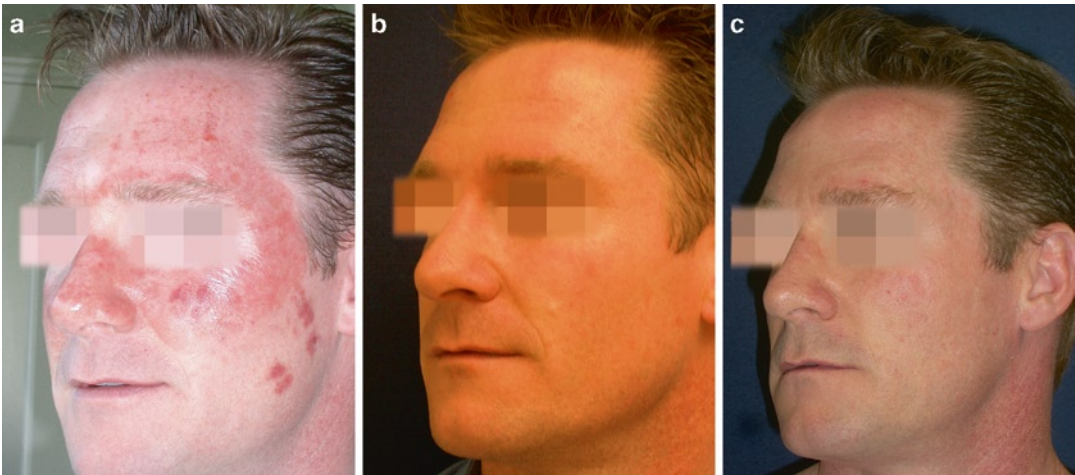
**Fig. 2.11** (a) Frontal view of a 51-year-old male with photodamage consisting of numerous solar lentigines. (b) One day after ALA-PDT treatment. Levulan ALA was applied to entire treatment area for 1 h, unoccluded. IPL treatment with Lumenis One using a 560 nm cut-off filter, double pulse of 4 and 4 ms with a 10 ms delay at a fluence of 18 J/cm<sup>2</sup> followed by a 10-min exposure with the Blu-U. Note the erythema and crusting of all actinically damaged skin. (c) Two days after PDT treatment,

further increase in erythema is seen in areas of actinically damaged skin. (d) Three days after PDT treatment, resolution of erythema begins. (e) Four days after PDT treatment, further resolution of erythema. (f) Seven days after PDT treatment, complete resolution of erythema (This figure was published in Goldman MP, Dover JS, Alam M, editors. *Procedures in cosmetic surgery: photodynamic therapy*. 2nd ed. Philadelphia, PA: Elsevier; 2007, Copyright Elsevier 2007 [38])

Patients should be counseled to practice strict photoprotection for 24–36 hours following treatment. Titanium dioxide and zinc oxide-containing sunblocks are preferred, in addition to protective clothing and sunglasses. Excessive UV radiation from sunlight, as well as intense spotlights, photocopy machines, photographic flashlights, and medical examining lights/lamps should be avoided during the period of photosensitivity. Indoor light is

usually not a concern, but patients should avoid bright sources of light, even while indoors [12].

Not unexpectedly, if patients require a second treatment, the adverse effects as well as treatment pain are usually much less than those experienced with the initial treatment. We believe that the decrease is due to the resolution of most of the clinical and subclinical photodamage which occurs during the initial treatment.



**Fig. 2.12** (a) Mild to moderate phototoxic reaction due to sunlight exposure in the 24 hours following an ALA-PDT session. (b) Six months post-procedure, the patient

demonstrated marked improvement in photodamage without postinflammatory hyperpigmentation. (c) Four year follow-up with durable photorejuvenative effects

## Expected Benefits

Many of the benefits of ALA-PDT treatment have been addressed in the discussion of clinical studies regarding the treatment of AKs and photorejuvenation. ALA-PDT is a safe, efficacious, and well-tolerated treatment for AKs, with the added benefit of addressing photoaging. Clearance of AK lesions with PDT is superior from a cosmetic standpoint compared to conventional treatments such as liquid nitrogen [46]. A few studies have evaluated patient satisfaction with PDT. A study by Tierney et al. [45] followed patient satisfaction in 39 patients following ALA-PDT. In this study, patients reported statistically significant better recovery compared with other treatments including cryotherapy or surgical excision. A borderline statistically significant improvement was achieved with PDT for overall cosmetic outcome patient satisfaction compared with other therapies. Morton et al. [84] also found that patients preferred the overall treatment procedure and cosmetic outcome of ALA-PDT compared with cryotherapy. Patient satisfaction was high in the stage III clinical trial by Piacquadio et al. [52]. Ninety-four percent of patients through the cosmetic results following PDT were good to excellent.

## Conclusion

ALA-PDT is a safe and effective treatment for nonhyperkeratotic lesions. Although FDA-approved for use with a blue light source, other laser and light sources have demonstrated promise in the treatment of AKs during PDT. Shorter incubation times maintain AK clearance rates but decrease the occurrence of phototoxic adverse events. With careful patient selection, ALA-PDT allows selective field treatment of precancerous skin lesions with improvement in overall photodamage. Patient satisfaction is high and cosmetic results can be excellent.

## References

1. Calzavara-Pinton PG, Venturini M, Sala R. Photodynamic therapy: update 2006. Part 1: photochemistry and photobiology. *J Eur Acad Dermatol Venereol*. 2007;21:293–302.
2. Nootheti PK, Goldman MP. Aminolevulinic acid-photodynamic therapy for photorejuvenation. *Dermatol Clin*. 2007;25:35–45.
3. Ericson MB, Sandberg C, Stenquist B, Gudmundson F, et al. Photodynamic therapy of actinic keratosis at varying fluence rates: assessment of photobleaching, pain and primary clinical outcome. *Br J Dermatol*. 2004;151:1204–12.

4. Nakaseko H, Kobayashi M, Akita Y, Tamada Y, et al. Histological changes and involvement of apoptosis after photodynamic therapy for actinic keratoses. *Br J Dermatol*. 2003;148:122–7.
5. Wolf P, Rieger E, Kerl H. Topical photodynamic therapy with endogenous porphyrins after application of 5-aminolevulinic acid. *J Am Acad Dermatol*. 1993;28:17–21.
6. Touma D, Yaar M, Whitehead S, Konnikov N, et al. A trial of short incubation, broad-area photodynamic therapy for facial actinic keratoses and diffuse photodamage. *Arch Dermatol*. 2004;140:33–40.
7. Tsai T, Ji HT, Chiang PC, Chou RH, Chang WSW, Chen CT. ALA-PDT results in phenotypic changes and decreased cellular invasion in surviving cancer cells. *Lasers Surg Med*. 2009;41:305–15.
8. MacCormack MA. Photodynamic therapy in dermatology: an update on applications and outcomes. *Semin Cutan Med Surg*. 2008;27:52–62.
9. Nestor MS, Gold MH, Kauvar ANB, Taub AF, et al. The use of photodynamic therapy in dermatology: results of a consensus conference. *J Drugs Dermatol*. 2006;5:140–54.
10. Product information (package insert): Levulan (R) Kerastick (TM) (aminolevulinic acid HCl) for topical solution, 20%. DUSA Pharmaceuticals, Inc., Wilmington, MA, USA; 2009.
11. Fotinos N, Campo MA, Popowycz F, Gurny R, et al. 5-Aminolevulinic acid derivatives in photomedicine: characteristics, application and perspectives. *Photochem Photobiol*. 2006;82:994–1015.
12. Kalka K, Merk H, Mukhtar H. Photodynamic therapy in dermatology. *J Am Acad Dermatol*. 2000;42:389–413.
13. Gaullier JM, Berg K, Peng Q, Anholt H, et al. Use of 5-aminolevulinic acid esters to improve photodynamic therapy on cells in culture. *Cancer Res*. 1997;57:1481–6.
14. Peng Q, Warloe T, Berg K, Moan J, et al. 5-Aminolevulinic acid-based photodynamic therapy. *Cancer*. 1997;79:2282–308.
15. Kasche A, Luderschmidt S, Ring J, Hein R. Photodynamic therapy induces less pain in patients treated with methyl aminolevulinate compared to aminolevulinic acid. *J Drugs Dermatol*. 2006;5:353–6.
16. Goldberg DJ. Photodynamic therapy in skin rejuvenation. *Clin Dermatol*. 2008;26:608–13.
17. Nakano A, Tamada Y, Watanabe D, Ishida N, et al. A pilot study to assess the efficacy of photodynamic therapy for Japanese patients with actinic keratosis in relation to lesion size and histological severity. *Photodermatol Photoimmunol Photomed*. 2009;25:37–40.
18. Zakhary K, Ellis DAF. Applications of aminolevulinic acid-based photodynamic therapy in cosmetic facial plastic practices. *Facial Plast Surg*. 2005;21:110–6.
19. Clark C, Bryden A, Dawe R, Moseley H, et al. Topical 5-aminolevulinic acid photodynamic therapy for cutaneous lesions: outcome and comparison of light sources. *Photodermatol Photoimmunol Photomed*. 2003;19:134–41.
20. DeHoratius DM, Dover JS. Nonablative tissue remodeling and photorejuvenation. *Clin Dermatol*. 2007;25:474–9.
21. Markham T, Collins P. Topical 5-aminolaevulinic acid photodynamic therapy for extensive scalp actinic keratoses. *Br J Dermatol*. 2001;145:502–4.
22. Kalisiak MS, Rao J. Photodynamic therapy for actinic keratoses. *Dermatol Clin*. 2007;25:15–23.
23. Gold MH. Pharmacoeconomic analysis of the treatment of multiple actinic keratoses. *J Drugs Dermatol*. 2008;7:23–5.
24. Drake LA, Ceilley RI, Cornelison RL, et al. Guidelines of care for AKs. *J Am Acad Dermatol*. 1995;32:95–8.
25. Stockfleth E, Kerl H. Guidelines for the management of actinic keratoses. *Eur J Dermatol*. 2006;16:599–606.
26. Lehmann P. Methyl aminolaevulinate-photodynamic therapy: a review of clinical trials in the treatment of actinic keratoses and nonmelanoma skin cancer. *Br J Dermatol*. 2007;156:793–801.
27. Berking C, Herzinger T, Flaig MJ, Brenner M, Borelli C, Degitz K. The efficacy of photodynamic therapy in actinic cheilitis of the lower lip: a prospective study of 15 patients. *Dermatol Surg*. 2007;33:825–30.
28. Marks R. Epidemiology of nonmelanoma skin cancer and solar keratoses in Australia: a tale of self-immolation in Elysian fields. *Australas J Dermatol*. 1997;38:S26–9.
29. Diepgen TL, Mahler V. The epidemiology of skin cancer. *Br J Dermatol*. 2002;146:1–6.
30. Osborne JE. Skin cancer screening and surveillance. *Br J Dermatol*. 2002;146:745–54.
31. Marks R, Rennie G, Selwood TS. Malignant transformation of solar keratoses to squamous cell carcinoma. *Lancet*. 1988;1:795–7.
32. Glogau RG. The risk of progression to invasive disease. *J Am Acad Dermatol*. 2000;42(1 Pt 2):23–4.
33. Czarnecki D, Meehan CJ, Bruce F, Culjak G. The majority of cutaneous squamous cell carcinomas arise in actinic keratoses. *J Cutan Med Surg*. 2002;6:207–9.
34. Cockerell CJ, Wharton JR. New histopathological classification of actinic keratosis (incipient intraepithelial squamous cell carcinoma). *J Drugs Dermatol*. 2005;4:462–7.
35. Ortonne JP. From actinic keratoses to squamous cell carcinoma. *Br J Dermatol*. 2002;146:S20–3.
36. Hurwitz RM, Monger LE. Solar keratosis: an evolving squamous cell carcinoma. Benign or malignant? *Dermatol Surg*. 1995;21:184.
37. Moy RL. Clinical presentation of actinic keratoses and squamous cell carcinoma. *J Am Acad Dermatol*. 2000;42:8–10.
38. Bäuml W, Wetzig T. Clinical application of fluorescence diagnosis. In: Goldman MP, Dover JS, Alam M, editors. *Procedures in cosmetic dermatology: photodynamic therapy*. 2nd ed. Philadelphia, PA: Elsevier; 2008. p. 149–60.
39. Salasche SJ. Epidemiology of actinic keratoses and squamous cell carcinoma. *J Am Acad Dermatol*. 2000;42:4–7.

40. Cockerell CJ. Histopathology of incipient intraepidermal squamous cell carcinoma ("actinic keratosis"). *J Am Acad Dermatol.* 2000;42:11–7.
41. Tschen EH, Wong DS, Pariser DM, Dunlap FE, Houlihan A, Ferdon MB. Photodynamic therapy using aminolaevulinic acid for patients with nonhyperkeratotic actinic keratoses of the face and scalp: phase IV multicentre clinical trial with 12-month follow up. *Br J Dermatol.* 2006;155:1262–9.
42. Jeffes EW, McCullough JL, Weinstein GD, Kaplan R, Glazer SD, Taylor JR. Photodynamic therapy of actinic keratoses with topical aminolevulinic acid hydrochloride and fluorescent blue light. *J Am Acad Dermatol.* 2001;45:96–104.
43. Szeimies RM, Karrer S, Radakovic-Fijan S, Tanew A, Galzavara-Pinton PG, Zane C, et al. Photodynamic therapy using topical methyl 5-aminolevulinate compared with cryotherapy for actinic keratosis: a prospective, randomized study. *J Am Acad Dermatol.* 2002;47:258–62.
44. Kurwa HA, Yong-Gee SA, Seed PT, et al. A randomized paired comparison of photodynamic therapy and topical 5-fluorouracil in the treatment of actinic keratoses. *J Am Acad Dermatol.* 1999;41:414–8.
45. Tierney EP, Eide MJ, Jacobsen G, Ozog D. Photodynamic therapy for actinic keratoses: survey of patient perceptions of treatment satisfaction and outcomes. *J Cosmet Laser Ther.* 2008;10:81–6.
46. Goldman MP, Atkin DH. ALA/PDT in the treatment of actinic keratosis: spot versus confluent therapy. *J Cosmet Laser Ther.* 2003;5:107–10.
47. Alexiades-Amenakas MR, Geronemus RG. Laser-mediated photodynamic therapy of actinic keratoses. *Arch Dermatol.* 2003;139:1313–20.
48. Kennedy JC, Pottier RH, Pross DC. Photodynamic therapy with endogenous protoporphyrin IX: basic principles and present clinical experience. *J Photochem Photobiol B.* 1990;6:143–8.
49. Dijkstra AT, Majoie IML, van Dongen JWF, van Weelden H, et al. Photodynamic therapy with violet light and topical  $\delta$ -aminolaevulinic acid in the treatment of actinic keratosis, Bowen's disease and basal cell carcinoma. *J Eur Acad Dermatol Venereol.* 2001;15:550–4.
50. Ross EV, Anderson RR. Laser-tissue interactions. In: Goldman MP, editor. *Cutaneous and cosmetic laser surgery.* Philadelphia, PA: Elsevier; 2006. p. 1–26.
51. Ormrod D, Jarvis B. Topical aminolevulinic acid HCl photodynamic therapy. *Am J Clin Dermatol.* 2000;2:133–9.
52. Piacquadio DJ, Chen DM, Farber HF, et al. Photodynamic therapy with aminolevulinic acid topical solution and visible blue light in the treatment of multiple actinic keratoses of the face and scalp: investigator-blinded, phase 3, multicenter trials. *Arch Dermatol.* 2004;140:41–6.
53. Gold MH. The evolving role of aminolevulinic acid hydrochloride with photodynamic therapy in photoaging. *Cutis.* 2002;69:8–13.
54. Fritsch C, Stege H, Saalman G, Goerz G, et al. Green light is effective and less painful than red light in photodynamic therapy of facial solar keratoses. *Photodermatol Photoimmunol Photomed.* 1997;13:181–5.
55. Smith S, Piacquadio D, Morhenn V, Atkin D. Short incubation PDT versus 5-FU in treating actinic keratoses. *J Drugs Dermatol.* 2003;2:629–35.
56. Jeffes WJ, McCullagh JL, Weinstein GD, Fergin PE, et al. Photodynamic therapy of actinic keratosis with topical 5-aminolaevulinic acid. *Arch Dermatol.* 1997;133:727–32.
57. Karrer S, Bäumler W, Abels C, Hohenleutner U, et al. Long-pulse dye laser for photodynamic therapy: investigations in vitro and in vivo. *Lasers Surg Med.* 1999;25:51–9.
58. Itoh Y, Nineomiya Y, Henta T, Tajima S, et al. Topical delta-aminolevulinic acid-based photodynamic therapy for Japanese actinic keratoses. *J Dermatol.* 2000;27:513–8.
59. Varma S, Wilson H, Kurwa HA, Gambles B, et al. Bowen's disease, solar keratoses and superficial basal cell carcinomas treated by photodynamic therapy using a large-field incoherent light source. *Br J Dermatol.* 2001;144:56–574.
60. Moseley H, Ibbotson S, Woods J, Brancalion L, Lesar A, Goodman C, et al. Clinical and research applications of photodynamic therapy in dermatology: experience of the Scottish PDT centre. *Lasers Surg Med.* 2006;38:403–16.
61. Fink-Puches R, Hofer A, Smolle J, Kerl H, et al. Primary clinical response and long-term follow-up of solar keratoses treated with topically applied 5-aminolevulinic acid and irradiation by different wave bands of light. *J Photochem Photobiol B.* 1997;41:145–51.
62. Kim HS, Yoo JY, Cho KH, Kwon OS, et al. Topical photodynamic therapy using intense pulsed light for treatment of actinic keratosis: clinical and histopathologic evaluation. *Dermatol Surg.* 2005;31:33–7.
63. Gilbert D. Treatment of actinic keratoses with sequential combination of 5-fluorouracil and photodynamic therapy. *J Drugs Dermatol.* 2005;4:161–3.
64. Shaffelburg M. Treatment of actinic keratoses with sequential use of photodynamic therapy and imiquimod 5% cream. *J Drugs Dermatol.* 2009;8:35–9.
65. Ruiz-Rodriguez R, Sanz-Sánchez T, Córdoba S. Photodynamic photorejuvenation. *Dermatol Surg.* 2002;28:742–4.
66. Dover JS, Bhatia AC, Stewart B, Arndt KA. Topical 5-aminolevulinic acid combined with intense pulsed light in the treatment of photoaging. *Arch Dermatol.* 2005;141:1247–52.
67. Zane C, Capezzer R, Sala R, Venturini M, Calzavara-Pinton P. Clinical and echographic analysis of photodynamic therapy using methylaminolevulinate as sensitizer in the treatment of photodamaged facial skin. *Lasers Surg Med.* 2007;39:203–9.



68. Gold MH, Bradshaw VL, Boring MM, Bridges TM, et al. Split-face comparison of photodynamic therapy with 5-aminolevulinic acid and intense pulsed light versus intense pulsed light alone for photodamage. *Dermatol Surg.* 2006;32:795–803.
69. Uebelhoer NS, Dover J. Photodynamic therapy for cosmetic applications. *Dermatol Ther.* 2005;18:242–52.
70. Jeffes EWB. Levulan: the first approved topical photosensitizer for the treatment of actinic keratosis. *J Dermatol Treat.* 2002;13:S19–23.
71. Pariser DM, Lowe NJ, Stewart DM, Jarratt MT, et al. Photodynamic therapy with topical methyl aminolevulinate for actinic keratosis: results of a prospective randomized multicenter trial. *J Am Acad Dermatol.* 2003;48:227–32.
72. Lowe NJ, Lowe P. Pilot study to determine the efficacy of ALA-PDT photorejuvenation for the treatment of facial ageing. *J Cosmet Laser Ther.* 2005;7:159–62.
73. Goldberg DJ. New collagen formation after dermal remodeling with intense pulsed light sources. *J Cutan Laser Ther.* 2000;2:59–61.
74. Avram DK, Goldman MP. Effectiveness and safety of ALA-IPL in treating actinic keratoses and photodamage. *J Drugs Dermatol.* 2004;3:S36–9.
75. Alster TS, Tanzi EL, Welch EC. Photorejuvenation of facial skin with topical 20% 5-aminolevulinic acid and intense pulsed light treatment: a split-face comparison study. *J Drugs Dermatol.* 2005;4:35–8.
76. Marmur ES, Phelps R, Goldberg DJ. Ultrastructural changes seen after ALA-IPL photorejuvenation: a pilot study. *J Cosmet Laser Ther.* 2005;7:21–4.
77. Serrano G, Lorente M, Reyes M, Millán F, et al. Photodynamic therapy with low-strength ALA, repeated applications and short contact periods (40–60 minutes) in acne, photoaging, and vitiligo. *J Drugs Dermatol.* 2009;8:562–8.
78. Key DJ. Aminolevulinic acid-pulsed dye laser photodynamic therapy for the treatment of photoaging. *Cosmet Dermatol.* 2005;18:31–6.
79. Oseroff A. PDT as a cytotoxic agent and biological response modifier: implications for cancer prevention and treatment in immunosuppressed and immunocompetent patients. *J Invest Dermatol.* 2006;126:542–4.
80. Dragieva G, Hafner J, Dummer R, Schmid-Grendelmeier P, et al. Topical photodynamic therapy in the treatment of actinic keratoses and Bowen's disease in transplant recipients. *Transplantation.* 2004;17:115–21.
81. de Graaf YGL, Kennedy C, Wolterbeek R, Collen AFS, et al. Photodynamic therapy does not prevent cutaneous squamous-cell carcinoma in organ-transplant recipients: results of a randomized-controlled trial. *J Invest Dermatol.* 2006;126:569–74.
82. Lee WR, Tsai RY, Fang CL, Liu CJ, Hu CH, Fang JY. Microdermabrasion as a novel tool to enhance drug delivery via the skin: an animal study. *Dermatol Surg.* 2006;32:1013–22.
83. Katz BE, Truong S, Maiwald DC, Frew KE, George BA. Efficacy of microdermabrasion preceding ALA application in reducing the incubation time of ALA in laser PDT. *J Drugs Dermatol.* 2007;6:140–2.
84. Morton S, Campbell S, Gupta G, Keohane S, Lear J, Zaki I, et al. Intraindividual, right-left comparison of topical methyl aminolaevulinate photodynamic therapy and cryotherapy in subjects with actinic keratoses: a multicentre, randomized controlled study. *Br J Dermatol.* 2006;155:1029–36.
85. Morton CA, Whitehurst C, Moseley H, et al. Development of an alternative light source to lasers for photodynamic therapy: clinical evaluation in the treatment of pre-malignant non-melanoma skin cancer. *Lasers Med Sci.* 1995;10:165–71.
86. Fijan S, Honigsmann H, Ortel B. Photodynamic therapy of epithelial skin tumors with delta-aminolaevulinic acid and desferrioxamine. *Br J Dermatol.* 1995;133:282–8.
87. Szeimies RM, Karrer S, Sauerwald A, Landthaler M. Photodynamic therapy with topical application of 5-aminolevulinic acid in the treatment of actinic keratoses: an initial clinical study. *Dermatology.* 1996;192:246–51.