

Photodynamic Therapy

Robert Bissonnette

- Photodynamic therapy with ALA or MAL is an excellent treatment for multiple actinic keratoses
- Large field photodynamic therapy can eradicate multiple actinic keratoses with a shorter downtime than 5-fluorouracil or imiquimod
- Multiple large field photodynamic therapy sessions can delay the appearance of actinic keratoses
- Photodynamic therapy with MAL is approved in several countries for the treatment of superficial basal cell carcinoma and Bowen's disease
- Photodynamic therapy with ALA or MAL has been successfully used off-label for the treatment of acne vulgaris and to improve photoaging.
- Intense pulsed light and pulsed dye lasers can be used to activate porphyrins after ALA or MAL application

Introduction

- Photodynamic therapy was officially discovered at the turn of the twentieth century
- The use of photodynamic therapy with ALA to treat actinic keratoses and basal cell carcinoma was pioneered in Canada by Kennedy and Pottier
- Both ALA and MAL are transformed into porphyrins which can be activated by blue or red light

Photodynamic therapy (PDT) combines the administration of a photosensitizer or photosensitizer precursor with its activation by light of the appropriate wavelengths. In the presence

of oxygen, this leads to generation of reactive oxygen species and free radicals. Treatment with plants containing photosensitizers followed by sunlight exposure was practiced by several civilizations since antiquity, but PDT was officially discovered at the turn of the twentieth century by Oscar Raab, a medical study working in Germany in the laboratory of Von Tappeiner.¹ The discovery that pre-malignant and malignant skin lesions can be treated with topical aminolevulinic acid (ALA) application followed by light exposure was made in Canada by Kennedy and Pottier in the late 1980s.²

Aminolevulinic acid (ALA) can enter the heme biosynthetic pathway which leads to production of porphyrins and ultimately of heme, as protoporphyrin IX is transformed into heme by the enzyme ferrochelatase. Heme has a negative feedback on ALA synthesis. The addition of exogenous ALA bypasses this negative feedback leading to accumulation of porphyrins which can be activated with visible light (Fig. 1). Blue light is the most efficient waveband for porphyrin activation but red light is also often used as it penetrates deeper than blue light. Following this discovery, researchers experimented with several ALA derivatives including methylaminolevulinate (MAL).³ This ester of ALA also enters the heme biosynthetic pathway where it is transformed into porphyrins.

With the approval of ALA and MAL in several countries, photodynamic therapy is now a well established procedure in

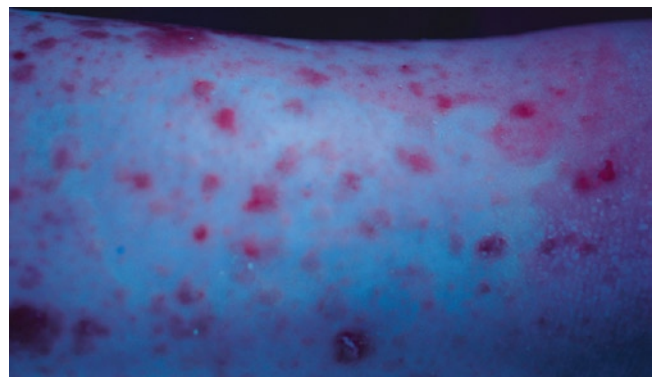


Fig. 1 Accumulation of porphyrins (pink-red) in basal cell carcinomas of a patient with Gorlin's syndrome 3 h after application of ALA.

R. Bissonnette
Innovaderm Research Inc., Montreal, Quebec, Canada
e-mail: rbissonnette@innovaderm.ca

K. Nouri (ed.), *Lasers in Dermatology and Medicine*,
DOI: 10.1007/978-0-85729-281-0_18, © Springer-Verlag London Limited

Biofrontera Exhibit 1018
Biofrontera Inc. et al. v. DUSA Pharmaceuticals, Inc.
IPR2022-00056

Photodynamic Therapy

Robert Bissonnette

- Photodynamic therapy with ALA or MAL is an excellent treatment for multiple actinic keratoses
- Large field photodynamic therapy can eradicate multiple actinic keratoses with a shorter downtime than 5-fluorouracil or imiquimod
- Multiple large field photodynamic therapy sessions can delay the appearance of actinic keratoses
- Photodynamic therapy with MAL is approved in several countries for the treatment of superficial basal cell carcinoma and Bowen's disease
- Photodynamic therapy with ALA or MAL has been successfully used off-label for the treatment of acne vulgaris and to improve photoaging.
- Intense pulsed light and pulsed dye lasers can be used to activate porphyrins after ALA or MAL application

Introduction

- Photodynamic therapy was officially discovered at the turn of the twentieth century
- The use of photodynamic therapy with ALA to treat actinic keratoses and basal cell carcinoma was pioneered in Canada by Kennedy and Pottier
- Both ALA and MAL are transformed into porphyrins which can be activated by blue or red light

Photodynamic therapy (PDT) combines the administration of a photosensitizer or photosensitizer precursor with its activation by light of the appropriate wavelengths. In the presence

of oxygen, this leads to generation of reactive oxygen species and free radicals. Treatment with plants containing photosensitizers followed by sunlight exposure was practiced by several civilizations since antiquity, but PDT was officially discovered at the turn of the twentieth century by Oscar Raab, a medical study working in Germany in the laboratory of Von Tappeiner.¹ The discovery that pre-malignant and malignant skin lesions can be treated with topical aminolevulinic acid (ALA) application followed by light exposure was made in Canada by Kennedy and Pottier in the late 1980s.²

Aminolevulinic acid (ALA) can enter the heme biosynthetic pathway which leads to production of porphyrins and ultimately of heme, as protoporphyrin IX is transformed into heme by the enzyme ferrochelatase. Heme has a negative feedback on ALA synthesis. The addition of exogenous ALA bypasses this negative feedback leading to accumulation of porphyrins which can be activated with visible light (Fig. 1). Blue light is the most efficient waveband for porphyrin activation but red light is also often used as it penetrates deeper than blue light. Following this discovery, researchers experimented with several ALA derivatives including methylaminolevulinate (MAL).³ This ester of ALA also enters the heme biosynthetic pathway where it is transformed into porphyrins.

With the approval of ALA and MAL in several countries, photodynamic therapy is now a well established procedure in

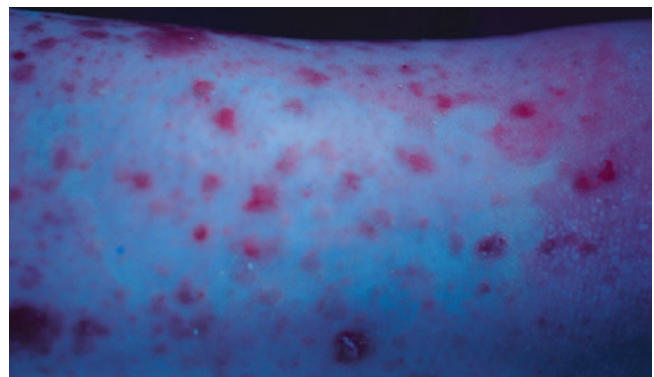


Fig. 1 Accumulation of porphyrins (pink-red) in basal cell carcinomas of a patient with Gorlin's syndrome 3 h after application of ALA. Photograph taken under Wood's lamp

R. Bissonnette
Innovaderm Research Inc., Montreal, Quebec, Canada
e-mail: rbissonnette@innovaderm.ca

Dermatology. Both drugs are approved to treat actinic keratoses (AK). In addition, MAL is approved in several countries, but not in the US, for the treatment of various types of non-melanoma skin cancers. Since the approval of MAL and ALA, physicians have successfully used these two photosensitizer precursors for the treatment of several other skin diseases and have combined them with different lasers, intense pulsed light and other non-coherent light sources for porphyrin activation.

Indications and Contraindications

Indications

Aminolevulinic acid: minimally to moderately thick actinic keratoses of the face and scalp
 Methylaminolevulinate: non hypertrophic actinic keratoses of the face and scalp
 PDT with MAL is approved in several countries, but not in the US, for the treatment of superficial basal cell carcinoma and Bowen's disease

Contraindications

Porphyria and sensitivity to visible light
 Presence of invasive squamous cell carcinoma in the treatment field
 Morpheiform basal cell carcinoma
 Topical or systemic medications inducing visible light sensitivity
 Allergy to MAL
 Warning: MAL contains peanut oil

Indications

Aminolevulinic acid is approved in the US, Canada and Brazil for the treatment of minimally to moderately thick actinic keratosis of the face and scalp in combination with the Blu-U unit (Fig. 2). The original approval was for non-hypertrophic actinic keratoses. This has recently been changed to minimally to moderately thick AK at the FDA's request. In practice, this wording is similar and refers to the fact that PDT is not approved for thick and hypertrophic AKs. There are two issues related to treatment of hypertrophic AKs with PDT. The first is inadequate penetration of ALA through the hyperkeratotic portion of the lesion and the second is the possibility that some of the more hypertrophic

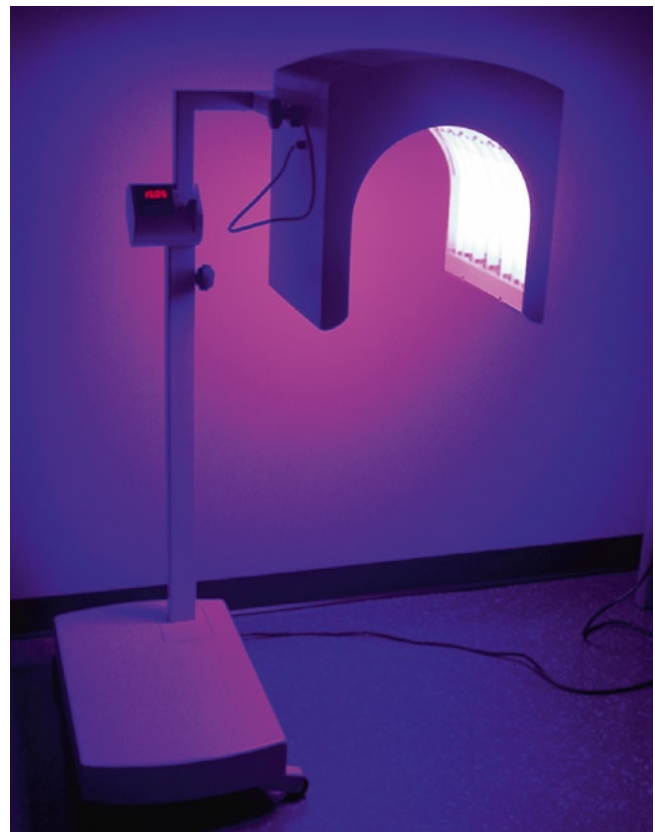

Fig. 2 Blu-U device. This non-coherent light source is approved for the treatment of actinic keratoses with ALA

lesions might be micro-invasive SCCs. The current approval is based on phase III studies where ALA was applied on visible lesions for 14–18 h followed by 10 J/cm² of blue light from a Blu-U unit.⁴ However, in practice very few physicians use ALA-PDT with a 14–18 h incubation. Most will use a shorter incubation of 45 min to 2 h. This off label use is supported by a small pilot study which showed that incubation of 1–3 h in patients with extensive sun exposure leads to AK lesion cure rates that are similar to what has been reported with longer incubations in phase III studies.⁵ Complete responses on BCC have been reported following ALA-PDT,⁶ however the efficacy of ALA-PDT for the treatment of BCC has never been studied in multicenter phase III trials and the long term recurrence rates have not been well studied.

MAL is currently FDA-approved for the treatment of non hypertrophic actinic keratoses of the face and scalp in immunocompetent patients when used in conjunction with lesion preparation and when other therapies are considered medically less appropriate. AK cure rates following either a single MAL-PDT session repeated at 3 months if necessary or 2 MAL-PDT sessions performed 7 days apart have been reported to be around 90%.^{7,8} Studies presented at meetings suggest that multiple large surface ALA or MAL PDT sessions can delay the appearance of new actinic keratoses in

organ transplant patients. This suggests that large surface PDT may be able to prevent skin cancer.

Several countries have also granted approval of MAL-PDT for the treatment of various non-melanoma skin cancers. The indications vary from one country to another but in general most countries approved MAL-PDT for the treatment of Bowen's disease and superficial BCC when other therapies such as surgery are considered inappropriate.⁹⁻¹¹ The complete response rate of superficial BCC following MAL-PDT has been shown to be 97% and the 48-month long-term recurrence rate 22%.^{12,13} The main advantage of PDT for the treatment of sBCC and Bowen's disease is the excellent cosmetic outcome as compared to surgery, cryotherapy or electrodesiccation and curettage.^{6,9} Some countries have also approved MAL-PDT for thin nodular BCC, but because the cure rate is lower than with sBCC many countries have restricted their approval to sBCC. Recurrences for superficial BCCs, nodular BCCs and Bowen's disease usually occur during the first 2–3 years after therapy with no increase in recurrence between the third and the fifth year.

At the time this text was written, MAL was not yet commercially available in the US because the FDA approved MAL only in combination with the Curelight device, an

earlier LED light source that is rather cumbersome. In most countries MAL is approved with the Aktelite (Fig. 3), a smaller and more convenient device. Studies comparing the efficacy of Curelight and Aktelite in the treatment of AK are currently being completed in the US. These studies should lead to FDA approval of MAL-PDT performed with the Aktelite device.

Initial studies conducted with PDT for skin diseases often used lasers. However, the current off-label trend with ALA-PDT is to use broad area application ALA or MAL in order to treat non-visible lesions, improve photoaging and eventually prevent the appearance of new lesions. This trend combined with the cost and limited availability of lasers in the 400–450 nm and 630–640 nm ranges has limited the use of lasers for PDT in Dermatology. When physicians are using ALA with a non-approved light source, they tend to favor LEDs or intense pulsed light. However, the pulsed dye laser at 595 nm has also been used for the treatment of actinic keratoses and acne.¹⁴

ALA and MAL have been reported to successfully treat various non oncologic skin conditions in small pilot studies or in single case reports. These include acne, sebaceous hyperplasia, hidradenitis suppurativa and photoaging.¹⁴⁻¹⁹ MAL and ALA are both in phase II for the treatment of acne. A number of small controlled studies have shown that MAL and ALA can improve acne.^{14,15,20,21} This is related in part to the intense accumulation of porphyrin in sebaceous glands following topical application of ALA and MAL (Fig. 4). Light exposure could induce partial necrosis of sebaceous glands and reduce sebum excretion thus reducing acne lesions. Preliminary findings with ALA suggest that this is one of the mechanisms of ALA-PDT when used for the treatment of acne.²² Studies performed with PDT in acne are complicated by the fact that blue or red light alone can improve acne by elimination of propionibacterium acnes as these bacteria naturally accumulate porphyrins.²³ The best treatment parameters for acne are currently unknown. Most controlled studies which have shown good efficacy report a strong post PDT phototoxic reaction. Clinical photographs published in some of the articles which used MAL under occlusion for 3 h show moderate to severe erythema with crusting 1 day post-PDT. These publications report severe pain in many patients during light exposure.^{15,21} Such a strong phototoxic reaction is probably not needed to see improvement in acne. However, it is possible that prolonged remission requires a certain degree of phototoxic reaction as necrosis of sebaceous gland tissue might be necessary. The current literature suggests that PDT for acne is more efficacious for patients with moderate to severe inflammatory acne.

Touma and colleagues have demonstrated that the use of ALA-PDT with a 1–3 h incubation followed by blue light exposure in patients with multiple actinic keratoses can improve photoaging.⁵ Small wrinkles, pigmentation and



Fig. 3 Aktelite device. This LED light source is approved in several countries for the treatment of AK and/or Bowen's disease and/or superficial basal cell carcinoma with MAL

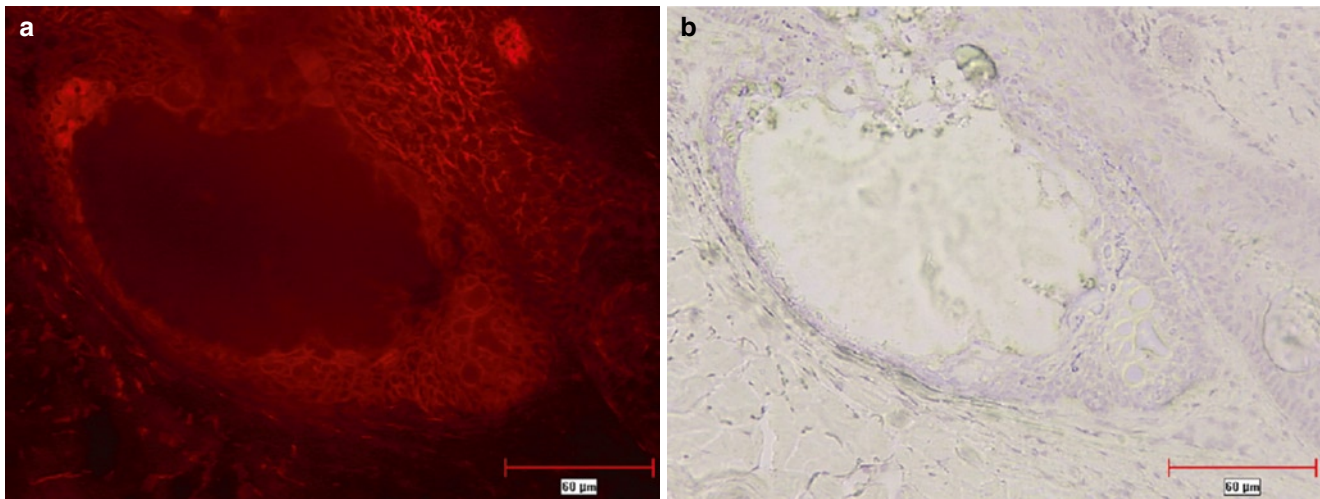


Fig. 4 (a) Porphyrin fluorescence in sebaceous glands 3 h after application of MAL. (b) Same section stained with hematoxylin

sallowness were the parameters best improved with ALA-PDT. ALA-PDT performed with IPL has also been shown to improve photoaging.^{18,24} Small studies have also shown complete response in AKs treated with ALA and IPL.^{24,25} There are currently a very wide variety of devices approved and used for the treatment of photoaging. Most physicians using ALA or MAL-PDT for photoaging either combine PDT with other devices and treatments or favor ALA or MAL-PDT for patients with actinic keratoses who would also like to have improvement in photoaging.

Contraindications

ALA and MAL are contraindicated in patients sensitive to visible light corresponding to the spectral output of the light source used (400–450 nm for Blu-U and 630–640 nm for Aktelite). Patients with porphyria and some patients with solar urticaria are also sensitive to visible light. ALA and MAL-PDT performed on patients using concomitant photosensitizing drugs such as phenothiazines, tetracyclines, thiazides and sulphonamide have not been thoroughly studied and could theoretically increase the phototoxic reaction seen after PDT. Current use of topical or systemic retinoids such as tretinoin, adapalene, acitretin or isotretinoin could also increase the phototoxic reaction. MAL contains peanut oil. It should not contain the protein allergen present in peanuts, but many physicians refrain from using MAL-PDT in patients allergic to peanuts.

Histological variants of BCCs that are at high risk of recurrence such as morpheiform BCC are a contraindication to PDT with MAL. Pigmented basal cell carcinoma is usually considered a contraindication to PDT as pigment limits light penetration. However several physicians have reported complete responses of pigmented BCCs with PDT.

Techniques

Pre-operative management

- Informed consent with emphasis on difficulty to predict phototoxic response
- Thorough examination of skin areas to be exposed to detect malignant lesions
- Consider herpes simplex prophylaxis

Description of the technique

- Skin preparation to enhance penetration (mandatory for MAL)
- Photosensitizer application
- Interval to allow porphyrin build-up
- Light exposure

Post operative management

- Sun avoidance
- Ferrous oxide containing sunscreen
- Moisturizer

Pre-operative Management

A complete skin examination of the areas to be treated is necessary. This is of the utmost importance when performing large surface PDT. This examination should focus on the identification of malignancies such as basal cell carcinoma, squamous cell carcinoma and melanoma. Sub-optimal treatment of these malignant lesions could lead to later, deeper recurrences. Any suspicious lesion should be biopsied. If PDT is performed to treat a malignant lesion such as BCC or Bowen's disease, a

pre-treatment biopsy is recommended. A complete medical history including the existence of visible light sensitivity diseases such as porphyria or solar urticaria should be recorded. Patients should be asked about current use of any topical product on the areas to be treated. Products that can alter the stratum corneum such as topical retinoids can increase ALA and MAL penetration and create a more severe phototoxic reaction following PDT. The use of systemic treatments that increase visible light sensitivity such as St-John's wort should be avoided.

Patients should be well informed about the procedure including difficulty in predicting the phototoxic reaction generated by PDT. If only a few AKs or a single BCC are treated, the phototoxic reaction is usually not a problem. However a full face treatment can lead to erythema associated with tenderness and sometimes with focal areas of crusting. It is suggested to obtain a written informed consent which should mention this information as well as potential complications such as hyperpigmentation, hypopigmentation, scarring (mostly when treating basal cell carcinoma), sun and visible light sensitivity and prolonged erythema. Patients should be advised to bring a hat (when treating the face) or other pieces of clothing to cover the area to be treated.

The risks of triggering light sensitive recurrences of herpes labialis following PDT are currently unknown. For patients who experience recurrences following sun exposure, antiviral prophylaxis should be discussed.

Light exposure during PDT sometimes leads to an urticarial reaction immediately after PDT. This is more intense when red light is used and when large surfaces are exposed. This phenomenon has recently been attributed to histamine release by mastocytes and could be prevented by pre-treatment with antihistamines such as cetirizine.²⁶

Description of the Technique

Treatment of Actinic Keratoses with ALA

A gentle curettage of keratotic AKs should be performed prior to ALA application. This is not included in the current product monograph but the author finds that this increases the clinical response of individual lesions, probably by increasing drug

penetration. Skin preparation is suggested when performing short ALA incubations. The face can be washed vigorously with acetone or treated with microdermabrasion. These techniques are believed to increase ALA penetration through degreasing and/or partial removal of the stratum corneum.

Microdermabrasion can significantly reduce ALA incubation time.²⁷ Care should be taken to use the same technique with the same pre-treatment method and performed by the same person when treating a patient at different sessions as differences in skin preparation can have a dramatic impact on porphyrin buildup and therefore on the extent of the post-PDT phototoxic reaction.

ALA (Levulan) is available in the form of two glass vials inserted in a plastic tube that is covered by cardboard (Fig. 5). The two vials should be crushed with fingers and the stick shaken for about 3 min to ensure proper mixing of ALA powder and hydroalcoholic vehicle. ALA should be applied on all AKs present in the treatment area. Most physicians will also apply ALA on the entire face in order to treat non visible lesions and prevent new AKs. Broad area ALA application also has the advantage of improving signs of photoaging.⁵ Care should be taken to avoid applying ALA too close to the eyes as inadvertently gets the hydroalcoholic solution will sting if it inadvertently gets into the eyes. Facial zones with more sebaceous glands, such as the nose and chin, often display a more important phototoxic reaction than the rest of the face when performing PDT. This is probably due to more intense accumulation of porphyrins in sebaceous glands. If ALA or MAL is applied on these zones during a full face treatment, patients should be told to expect a strong phototoxic reaction the day following light exposure. A delay of 45 min to 2 h is suggested between ALA application and light exposure when ALA-PDT is used on large skin surfaces for the treatment of AK. The intensity of the phototoxic reaction generated by ALA-PDT varies greatly from one patient to another and is highly dependent on the type of pre-treatment used. For patients with extensive photodamage and numerous ill defined AKs, a 45–60 min incubation is usually enough and will even sometimes lead to a severe phototoxic reaction post PDT. Some physicians prefer to perform the first treatment with a 30–45 min incubation time in these patients. The incubation time can be adjusted at subsequent treatments based on the phototoxic reaction and the clinical response observed.

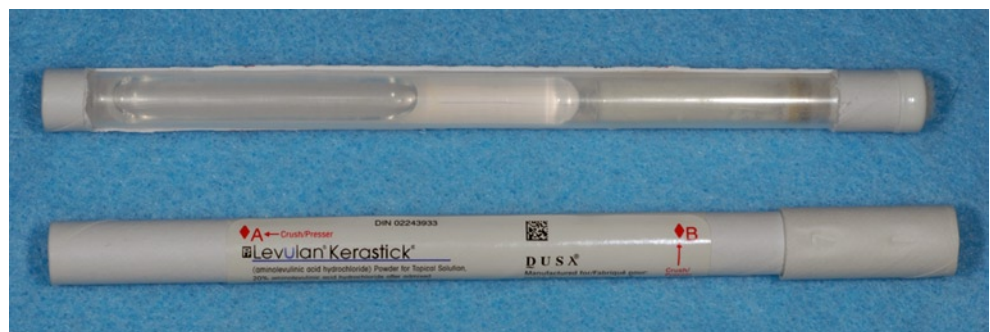

Fig. 5 ALA (Levulan Kerastick). The cardboard has been removed to show the 2 glass vials. Areas where pressure needs to be applied to crush the two glass vials are identified in *red*

After a proper incubation time, patients are placed inside the Blue-U device with their eyes protected with appropriate eyeshields as the blue light is very intense. As the U-shaped unit rotates, treatments can be performed with the patients sitting or lying down. The current product monograph recommends a light dose of 10 J/cm^2 of blue light which corresponds to an incubation time of 16 min 40 s. This was the fluence used in phase III, but a lower fluence is probably enough in most patients to completely photobleach porphyrins present in lesions. Many physicians use a shorter incubation time, but the efficacy of shorter incubation times has not been thoroughly studied in clinical trials.

Blue light exposure after ALA application generates a burning sensation that gradually increases to reach a plateau around 3–8 min and is followed by a gradual decrease. This decrease in burning sensation intensity corresponds to photoinactivation of porphyrins present in skin lesions. Blue light exposure is usually well tolerated by most patients if they have been properly warned about the sensation to expect during light exposure. An assistant should be present in the room during PDT, especially for the first PDT session, to reassure patients and to monitor the burning sensation. The assistant can use cool air, spray cool water or even temporarily interrupt light exposure if pain is too intense.

Treatment of BCC with MAL

A biopsy is suggested before treating a BCC with MAL-PDT. The purpose of the biopsy is to confirm the diagnosis and exclude histological subtypes, such as morpheiform BCCs, for which PDT is contraindicated. Gentle curettage of the lesion is mandatory before MAL application as 5 year cure rates for MAL-PDT have been established with pre-treatment curettage. Figure 6 shows a patient with multiple BCCs before and immediately after lesion preparation. MAL is provided in

2g tubes. Once opened the cream must be used within 7 days. This allows for treatment of more than one patient with the same tube or treatment of the same patient 7 days later with the same tube. MAL should be applied on the entire lesion to be treated plus a margin of 1 cm and should be occluded (with Opsite). Three hours later the occlusion is removed, the cream wiped out of the treatment field and the device (Aktilite) positioned at 5–8 cm from the skin. There is a risk of under treatment if the device is positioned beyond 8 cm as the head is flat and the irradiance varies according to the distance between skin and light source. The area where MAL has been applied should be exposed to 37 J/cm^2 (Aktilite device) of red light which corresponds to approximately 7 min and 30 s.

Post-operative Management

Excess ALA and MAL should be removed by thorough washing with tap water to prevent further porphyrin synthesis which would make the patient more sensitive to visible light. This is especially important when ALA or MAL has been applied to large areas such as the entire face. As patients are mostly sensitive to the visible part of the electromagnetic spectrum, the use of high SPF sunscreens does not provide adequate sun protection in the days following PDT. Patients can use a sunscreen containing inorganic suncreening agents such as Avene 50 Compact which provides some (but not complete) protection.²⁸ Patients should avoid sun exposure or exposure to intense visible light such as surgical lighting or a high power dentist lamp for 2 days after PDT. Patients should avoid driving or walking under the sun on the day PDT is performed. They should also be reminded that there is significant visible light exposure even on cloudy days and through window glass. There is no visible light sensitivity beyond 2 days after PDT with ALA or MAL. However, patients should

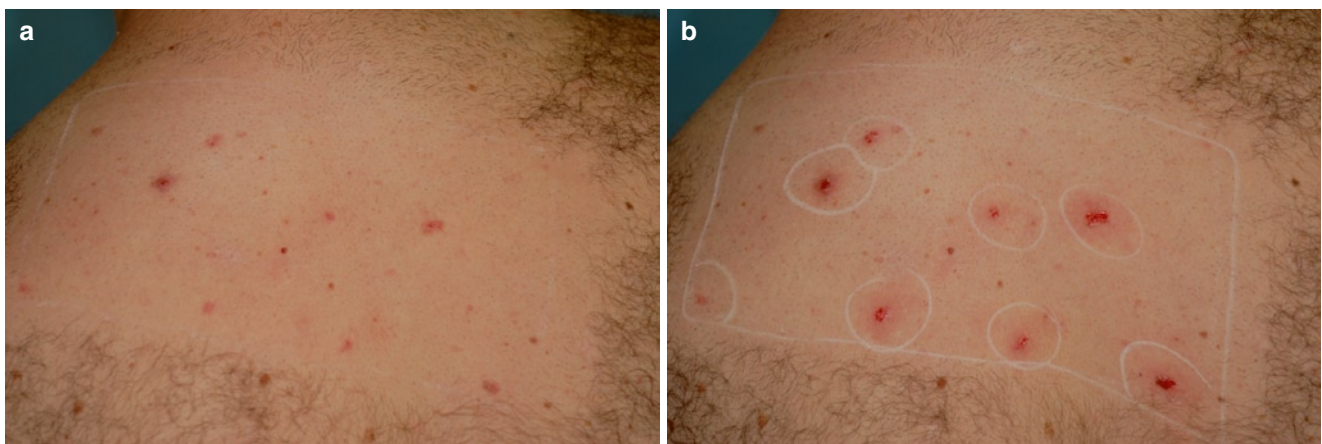


Fig. 6 Patient with multiple BCCs (Gorlin's syndrome) on the back before lesion preparation (a) and immediately after lesion preparation but before MAL application (b)

use a high SPF sunscreen providing adequate UVA protection to prevent hyperpigmentation. The use of Avene thermal water, a low mineral content water, after PDT has been shown to be superior to a higher mineral content water comparatively for decreasing post treatment pruritus.²⁹

Crusting and erosions over AK and BCC is expected and desirable when treating malignant or pre-malignant lesions with PDT. Simple occlusion combined with the use of petrolatum jelly or an antibiotic ointment is usually all that is required to promote healing and to decrease pain. Regular use of a bland moisturizer is recommended. Patients should avoid any topical products containing urea, retinoic acid or other alpha hydroxyl acids, alcohol or propylene glycol in the days and weeks following PDT. Patients should be advised to call if the reaction increases beyond 2 days as this may be suggestive of bacterial infection or reactivation of extensive herpes simplex.

Adverse Events

Expected

- Erythema
- Burning sensation during light exposure
- Crusting on AKs and BCCs

Possible

- Pain after light exposure
- Hyperpigmentation
- Hypopigmentation
- Scarring by loss of substance (e.g., nodular basal cell carcinoma)
- Urticarial reaction on exposed area
- Prolonged erythema
- Cellulitis, impetigo
- Reactivation of herpes simplex

Side Effects/Complications

Most patients will report a burning sensation, pain or pruritus during light exposure. This is usually well tolerated. When large surfaces are treated with MAL or ALA, the use of water spray, fan or cold air (such as from a Zimmer device) can alleviate this sensation. Temporary interruption of light exposure is another alternative as the burning sensation subsides rapidly when the light device is turned off.

All patients should expect a phototoxic reaction after PDT. The absence of a phototoxic reaction on pre-malignant

or malignant lesions following PDT is usually a sign that the treatment will not be efficacious. The phototoxic reaction manifests itself primarily by erythema on exposed sites that can vary from mild to severe. This is usually associated with crusting on areas where AKs were present and sometimes associated with vesicles, pustules and/or erosions. Erythema and edema are often more severe when the lesion to be treated is located on the nose. This is probably related to the abundance of sebaceous glands on the nose. Tenderness is usually present for a few days after PDT. Whole face treatments are often associated with pain and tenderness that are exacerbated with pressure (contact with pillow when sleeping for example) and followed by desquamation.

Bacterial infections such as impetigo and/or cellulitis or reactivation of herpes simplex are possible but very rarely seen with ALA and MAL-PDT. PDT can induce hyperpigmentation on treated areas. This is rarely seen in patients with phototype I or II. Hypopigmentation is possible but rare. Scarring by loss of substance can be seen after treatment of lesions that invade the dermis such as nodular basal cell carcinoma.

A few cases of prolonged erythema have been reported following PDT on the face.³⁰ This phenomenon can sometimes last many months. In the author's experience, this is more frequent in patients with rosacea and usually fades over time.

Allergy to MAL has been reported and documented by patch testing.³¹ Clinicians should think about this possibility in patients who have undergone several MAL-PDT treatments and present with a dermatitis type of reaction that was not present at previous treatments.

Prevention and Treatment of Side Effects/Complications

As discussed in the post operative management section, application of petrolatum jelly, a bland moisturizer or an antibiotic ointment will make the phototoxic reaction more tolerable.

Removal of MAL and ALA after PDT is important in order to reduce the continuous synthesis of porphyrin which increases post-treatment sensitivity to visible light. Patients should thoroughly wash their face with soap and water after light exposure. In a small pilot study where MAL was applied for 3 h under occlusion, porphyrin fluorescence was maximum at 1 h after cream removal but there was enough porphyrin present in the skin at 24 h after MAL application to induce a phototoxic reaction following light exposure in 6 out of 16 subjects.³²

Patients must be warned to avoid sun exposure for 2 days after PDT. The use of a sunscreen containing the physical suncreening agent iron oxide such as Avene Compact 50 is recommended during the first 2 days. Sun protection with a

high SPF sunscreen with good UVA protection is also important during the weeks following PDT in order to prevent hyperpigmentation.

Future Directions

- Treatment of acne
- Treatment of sebaceous hyperplasia
- Treatment of hidradenitis suppurativa
- Prevention of skin cancer with larger surface PDT
- Development of new photosensitizers

PDT with ALA and/or MAL is now a well established treatment modality for actinic keratoses, basal cell carcinoma and/or Bowen's disease. Some studies have suggested that large surface ALA or MAL PDT could prevent AK and maybe even SCC. Further prevention studies are needed in patients with multiple AKs, SCCs and BCCs. There is evidence that PDT performed with these photosensitizers has good efficacy in the treatment of acne vulgaris and both are currently in phase II for this indication. Future studies should determine the best treatment parameters to obtain improvement in acne vulgaris while limiting the phototoxic reaction. Other areas where MAL and/or ALA PDT has shown promising efficacy include sebaceous hyperplasia and hidradenitis suppurativa.

New photosensitizers are also currently being studied in phase I/II for various skin diseases including acne and hair removal. This should lead to more dermatological applications for PDT in the coming years.

Conclusion

Photodynamic therapy with ALA and MAL is currently widely used for the treatment of actinic keratoses, superficial basal cell carcinoma and Bowen's disease. One of the main advantages of PDT for sBCC and Bowen's disease as compared to surgical interventions is the superior cosmetic outcome observed with PDT. For most indications, the use of a non-coherent light source is more convenient. For multiple AKs, a full face or large surface PDT treatment is associated with less downtime than topical 5-fluorouracil or imiquimod. Preliminary studies also suggest that large surface PDT can prevent actinic keratoses. Preventive treatments and treatment of non neoplastic skin diseases probably represents the future of PDT in Dermatology.

References

1. Taub AF. Photodynamic therapy for the treatment of acne: a pilot study. *J Drugs Dermatol*. 2004;3(6 Suppl):S10-S14.
2. Kennedy JC, Pottier RH, Pross DC. Photodynamic therapy with endogenous protoporphyrin IX: basic principles and present clinical experience. *J Photochem Photobiol B*. 1990;6(1-2):143-148.
3. Kloek J, Akkermans W, van Beijersbergen Henegouwen GM. Derivatives of 5-aminolevulinic acid for photodynamic therapy: enzymatic conversion into protoporphyrin. *Photochem Photobiol*. 1998;67(1):150-154.
4. Piacquadro DJ, Chen DM, Farber HF, et al. Photodynamic therapy with aminolevulinic acid topical solution and visible blue light in the treatment of multiple actinic keratoses of the face and scalp: investigator-blinded, phase 3, multicenter trials. *Arch Dermatol*. 2004;140(1):41-46.
5. Touma D, Yaar M, Whitehead S, et al. A trial of short incubation, broad-area photodynamic therapy for facial actinic keratoses and diffuse photodamage. *Arch Dermatol*. 2004;140(1):33-40.
6. Wang I, Bendsoe N, Klinteberg CA, et al. Photodynamic therapy vs. cryosurgery of basal cell carcinomas: results of a phase III clinical trial. *Br J Dermatol*. 2001;144(4):832-840.
7. Pariser DM, Lowe NJ, Stewart DM, et al. Photodynamic therapy with topical methyl aminolevulinate for actinic keratosis: results of a prospective randomized multicenter trial. *J Am Acad Dermatol*. 2003;48(2):227-232.
8. Tarstedt M, Rosdahl I, Berne B, et al. A randomized multicenter study to compare two treatment regimes of topical methyl aminolevulinate (Metvix)-PDT in actinic keratosis of the face and scalp. *Acta Derm Venereol*. 2005;85:424-428.
9. Horn M, Wolf P, Wulf HC, et al. Topical methyl aminolaevulinate photodynamic therapy in patients with basal cell carcinoma prone to complications and poor cosmetic outcome with conventional treatment. *Br J Dermatol*. 2003;149(6):1242-1249.
10. Rhodes LE, de Rie M, Enstrom Y, et al. Photodynamic therapy using topical methyl aminolevulinate vs surgery for nodular basal cell carcinoma: results of a multicenter randomized prospective trial. *Arch Dermatol*. 2004;140(1):17-23.
11. Vinciullo C, Elliott T, Francis D, et al. Photodynamic therapy with topical methyl aminolaevulinate for 'difficult-to-treat' basal cell carcinoma. *Br J Dermatol*. 2005;152(4):765-772.
12. Basset-Seguin N, Ibbotson SH, Emtestam L, et al. MAL-PDT versus cryotherapy in primary sBCC: results of 48-month follow up. *J Eur Acad Dermatol Venereol*. 2005;19(Suppl 2):237.
13. Basset-Seguin N, Ibbotson SH, Emtestam L, et al. MAL-PDT versus cryotherapy in primary sBCC: results of 36 months follow-up. *J Eur Acad Dermatol Venereol*. 2004;18(Suppl 2):412.
14. Alexiades-Armenakas M. Long-pulsed dye laser-mediated photodynamic therapy combined with topical therapy for mild to severe comedonal, inflammatory, or cystic acne. *J Drugs Dermatol*. 2006;5(1):45-55.
15. Wiegell SR, Wulf HC. Photodynamic therapy of acne vulgaris using methyl aminolaevulinate: a blinded, randomized, controlled trial. *Br J Dermatol*. 2006;154(5):969-976.
16. Gold M, Bridges TM, Bradshaw VL, et al. ALA-PDT and blue light therapy for hidradenitis suppurativa. *J Drugs Dermatol*. 2004;3(1 Suppl):S32-S35.
17. Dover JS, Bhatia AC, Stewart B, et al. Topical 5-aminolevulinic acid combined with intense pulsed light in the treatment of photoaging. *Arch Dermatol*. 2005;141(10):1247-1252.
18. Alster TS, Tanzi EL, Welsh EC. Photorejuvenation of facial skin with topical 20% 5-aminolevulinic acid and intense pulsed light treatment: a split-face comparison study. *J Drugs Dermatol*. 2005;4(1):35-38.
19. Alster TS, Tanzi EL. Photodynamic therapy with topical aminolevulinic acid and pulsed dye laser irradiation for sebaceous hyperplasia. *J Drugs Dermatol*. 2003;2(5):501-504.

20. Horfelt C, Funk J, Frohm-Nilsson M, et al. Topical methyl aminolaevulinate photodynamic therapy for treatment of facial acne vulgaris: results of a randomized, controlled study. *Br J Dermatol*. 2006;155(3):608-613.
21. Wiegell SR, Wulf HC. Photodynamic therapy of acne vulgaris using 5-aminolevulinic acid versus methyl aminolevulinate. *J Am Acad Dermatol*. 2006;54(4):647-651.
22. Hongcharu W, Taylor CR, Chang Y, et al. Topical ALA-photodynamic therapy for the treatment of acne vulgaris. *J Investig Dermatol*. 2000;115(2):183-192.
23. Borelli C, Merk K, Schaller M, et al. In vivo porphyrin production by *P. acnes* in untreated acne patients and its modulation by acne treatment. *Acta Derm Venereol*. 2006;86(4):316-319.
24. Avram DK, Goldman MP. Effectiveness and safety of ALA-IPL in treating actinic keratoses and photodamage. *J Drugs Dermatol*. 2004;3(1 Suppl):S36-S39.
25. Gold MH, Bradshaw VL, Boring MM, et al. Split-face comparison of photodynamic therapy with 5-aminolevulinic acid and intense pulsed light versus intense pulsed light alone for photodamage. *Dermatol Surg*. 2006;32(6):795-801. Discussion 801-803.
26. Brooke RC, Sinha A, Sidhu MK, et al. Histamine is released following aminolevulinic acid-photodynamic therapy of human skin and mediates an aminolevulinic acid dose-related immediate inflammatory response. *J Invest Dermatol*. 2006;126(10):2296-2301.
27. Katz BE, Truong S, Maiwald DC, et al. Efficacy of microdermabrasion preceding ALA application in reducing the incubation time of ALA in laser PDT. *J Drugs Dermatol*. 2007;6(2):140-142.
28. Bissonnette R, Nigen S, Bolduc C, et al. Protection afforded by sunscreens containing inorganic sunscreens agents against blue light sensitivity induced by aminolevulinic acid. *Dermatol Surg*. 2008;34(11):1469-1476.
29. Goldman MP, Merial-Kieny C, Nocera T, et al. Comparative benefit of two thermal spring waters after photodynamic therapy procedure. *J Cosmet Dermatol*. 2007;6(1):31-35.
30. Misra A, Maybury K, Eltigani TA. Late erythema after photodynamic therapy to the face. *Plast Reconstr Surg*. 2006;117(7):2522-2523.
31. Harries MJ, Street G, Gilmour E, et al. Allergic contact dermatitis to methyl aminolevulinate (Metvix) cream used in photodynamic therapy. *Photodermatol Photoimmunol Photomed*. 2007;23(1):35-36.
32. Angell-Petersen E, Christensen C, Muller CR, et al. Phototoxic reaction and porphyrin fluorescence in skin after topical application of methyl aminolaevulinate. *Br J Dermatol*. 2007;156(2):301-307.