

Photodynamic Therapy of Cancer: An Update

Patrizia Agostinis, PhD¹; Kristian Berg, PhD²; Keith A. Cengel, MD, PhD³; Thomas H. Foster, PhD⁴; Albert W. Girotti, PhD⁵; Sandra O. Gollnick, PhD⁶; Stephen M. Hahn, MD, PhD⁷; Michael R. Hamblin, PhD^{8,9,10}; Asta Juzeniene, PhD¹¹; David Kessel, PhD¹²; Mladen Korbelik, PhD¹³; Johan Moan, PhD^{14,15}; Pawel Mroz, MD, PhD^{16,17}; Dominika Nowis, MD, PhD¹⁸; Jacques Piette, PhD¹⁹; Brian C. Wilson, PhD²⁰; Jakub Golab, MD, PhD^{21,22}

Abstract

Photodynamic therapy (PDT) is a clinically approved, minimally invasive therapeutic procedure that can exert a selective cytotoxic activity toward malignant cells. The procedure involves administration of a photosensitizing agent followed by irradiation at a wavelength corresponding to an absorbance band of the sensitizer. In the presence of oxygen, a series of events lead to direct tumor cell death, damage to the microvasculature, and induction of a local inflammatory reaction. Clinical studies revealed that PDT can be curative, particularly in early stage tumors. It can prolong survival in patients with inoperable cancers and significantly improve quality of life. Minimal normal tissue toxicity, negligible systemic effects, greatly reduced long-term morbidity, lack of intrinsic or acquired resistance mechanisms, and excellent cosmetic as well as organ function-sparing effects of this treatment make it a valuable therapeutic option for combination treatments. With a number of recent technological improvements, PDT has the potential to become integrated into the mainstream of cancer treatment. *CA Cancer J Clin* 2011;61:250-281. © 2011 American Cancer Society, Inc.

Introduction

Despite progress in basic research that has given us a better understanding of tumor biology and led to the design of new generations of targeted drugs, recent large clinical trials for cancer, with some notable exceptions, have been able to detect only small differences in treatment outcomes.^{1,2} Moreover, the number of

¹Professor and Head of the Department of Molecular Cell Biology, Cell Death Research and Therapy Laboratory, Catholic University of Leuven, Leuven, Belgium;

²Professor and Head of the Department of Radiation Biology, Institute for Cancer Research, The Norwegian Radium Hospital, Oslo University Hospital, Oslo, Norway; ³Assistant Professor of Radiation Oncology at the Department of Radiation Oncology, University of Pennsylvania, Philadelphia, PA; ⁴Professor of Imaging Sciences, Department of Imaging Sciences, University of Rochester, Rochester, NY; ⁵Professor of Biochemistry at the Department of Biochemistry, Medical College of Wisconsin, Milwaukee, WI; ⁶Professor of Oncology, Department of Cell Stress Biology, Roswell Park Cancer Institute, Buffalo, NY; ⁷Henry K. Pancoast Professor and Chairman of the Department of Radiation Oncology, University of Pennsylvania, Philadelphia, PA; ⁸Principal Investigator, Wellman Center for Photomedicine, Massachusetts General Hospital, Boston, MA; ⁹Associate Professor of Dermatology, Department of Dermatology, Harvard Medical School, Boston, MA; ¹⁰Associate Member of the Affiliated Faculty, Harvard-Massachusetts Institute of Technology Division of Health Sciences and Technology, Cambridge, MA; ¹¹Postdoctoral Fellow at the Department of Radiation Biology, Institute for Cancer Research, The Norwegian Radium Hospital, Oslo University Hospital, Oslo, Norway; ¹²Professor of Pharmacology, Department of Pharmacology, Wayne State University School of Medicine, Detroit, MI; ¹³Distinguished Scientist, Integrative Oncology Department, British Columbia Cancer Agency, Vancouver, British Columbia, Canada; ¹⁴Senior Researcher at the Department of Radiation Biology, Institute for Cancer Research, The Norwegian Radium Hospital, Oslo University Hospital, Oslo, Norway; ¹⁵Professor of Physics, Group of Plasma and Space Physics, Institute of Physics, University of Oslo, Oslo, Norway; ¹⁶Assistant in Immunology, Wellman Center for Photomedicine, Massachusetts General Hospital, Boston, MA; ¹⁷Instructor in Dermatology, Department of Dermatology, Harvard Medical School, Boston, MA; ¹⁸Assistant Professor at the Department of Immunology, Center of Biostructure Research, Medical University of Warsaw, Warsaw, Poland; ¹⁹Director of GIGA-Research, Laboratory of Virology and Immunology, Professor at the University of Liège, Liège, Belgium; ²⁰Head of the Division of Biophysics and Imaging, Ontario Cancer Institute, University of Toronto, Toronto, Ontario, Canada; ²¹Professor of Immunology and Head of the Department of Immunology, Center of Biostructure Research, Medical University of Warsaw, Warsaw, Poland; ²²Professor of Immunology, Institute of Physical Chemistry, Polish Academy of Sciences, Warsaw, Poland.

Corresponding author: Jakub Golab, MD, PhD, Department of Immunology, Center of Biostructure Research, Medical University of Warsaw, 1a Banacha St, F Building, 02-097 Warsaw, Poland; jakub.golab@wum.edu.pl

Some of the figures were produced with the help of Abhishek Garg using Servier Medical Art (available at www.servier.com) for which we would like to acknowledge Servier.

DISCLOSURES: Supported by the Fund for Scientific Research (FWO)-Flanders (Belgium) (grant numbers G.0661.09 and G.0728.10), the Interuniversity Attraction Pole IAP6/18 of the Belgian Federal Government, and the Catholic University of Leuven (OT/06/49 and GOA/11/009) (to P.A.); National Institutes of Health (NIH) grant CA-087971 (to K.A.C. and S.M.H.); NIH grants CA72630, CA70823, and HL85677 (to A.W.G.); NIH grants CA55791 and CA98156 (to S.O.G.); NIH grants CA68409 and CA122093 (to T.H.F.); NIH grants AI050875 and CA083882 (to M.R.H.); and the European Regional Development Fund through Innovative Economy grant POIG.01.01.02-00-008/08 (to J.G.). Dr. Kessel's research has been supported by NIH grants since 1980, predominantly by CA23378. Dr. Juzeniene's research has been supported by the Norwegian Cancer Society. Dr. Mroz was partly supported by a Genzyme-Partners Translational Research Grant. Dr. Golab is a recipient of the Mistrz Award from the Foundation for Polish Science and a member of the TEAM Programme cofinanced by the Foundation for Polish Science and the European Union European Regional Development Fund.

© 2011 American Cancer Society, Inc. doi:10.3322/caac.20114.

Available online at <http://cacancerjournal.org>

Biofrontera Exhibit 1023
Biofrontera Inc. et al. v. DUSA Pharmaceuticals, Inc.
IPR2022-00056

TABLE 1. Glossary of Specialty Terms

SPECIALTY TERM	DEFINITION
Chaperone	A protein that participates in the folding of newly synthesized or unfolded proteins into a particular 3-dimensional conformation.
Damage-associated molecular patterns (DAMPs)	Intracellular proteins that, when released outside the cell after its injury, can initiate or sustain an immune response in the noninfectious inflammatory response.
Fluence rate	The number of particles that intersect a unit area in a given amount of time (typically measured in watts per m ²).
Fluorescence-guided resection	A technique to enhance contrast of viable tumor borders that uses fluorescence emission from tissue. Fluorescence can be enhanced by the addition of exogenous chromophores (such as photosensitizers) with specific absorption and fluorescence properties.
Ground state	A state of elementary particles with the least possible energy in a physical system. This is the usual (singlet) state of most molecules. One of the exceptions includes oxygen, which in its ground state is a triplet and can be converted to a higher energy state of singlet oxygen during photodynamic therapy.
Immunocompromised mice	Animals having an immune system that has been impaired by genetic modification, disease, or treatment.
Immunocompetent mice	Animals having an intact (ie, normally functioning) immune system.
Intersystem crossing	A radiationless process in which a singlet excited electronic state makes a transition to a triplet excited state.
Macromolecular therapeutics	Proteins such as antibodies and growth factors for cell surface targeting, peptides and mRNA for cancer vaccination, and nucleotides for gene delivery and silencing as well as drug moieties such as polymers and nanoparticles for the delivery of therapeutics.
Major histocompatibility complex class I molecules	Transmembrane glycoproteins that bind short 8-11 amino acid long peptides recognized by T-cell receptors.
Naïve mice	Nonimmunized animals (ie, those that were not previously exposed to a particular antigen [such as tumor-associated antigen]).
Pathogen-associated molecular patterns (PAMPs)	Evolutionary conserved microbial molecules that are not normally produced by mammalian cells and are often common to whole classes of micro-organisms. PAMPs are recognized by pattern-recognition receptors.
Pattern-recognition receptors	Receptors for detection of DAMPs and PAMPs, initiating signaling cascades that trigger innate immune response.
Photosensitizer	A light-absorbing compound that initiates a photochemical or photophysical reaction.
Singlet oxygen (¹ O ₂)	An excited or energized form of molecular oxygen characterized by the opposite spin of a pair of electrons that is less stable and more reactive than the normal triplet oxygen (O ₂).
Triplet state	A state of a molecule or a free radical in which there are 2 unpaired electrons.
Ubiquitin-proteasome system	The major intracellular pathway for protein degradation.

new clinically approved drugs is disappointingly low.³ These sobering facts indicate that to make further progress, it is necessary to put an emphasis on other existing but still underappreciated therapeutic approaches. Photodynamic therapy (PDT) has the potential to meet many currently unmet medical needs. Although still emerging, it is already a successful and clinically approved therapeutic modality used for the management of neoplastic and nonmalignant diseases. PDT was the first drug-device combination approved by the US Food and Drug Administration (FDA) almost 2 decades ago, but even so remains underutilized clinically.

PDT consists of 3 essential components: photosensitizer (PS) (see Table 1 for the definitions of specialty terms), light, and oxygen.^{4,5} None of these is individually toxic, but together they initiate a photochemical reaction that culminates in the generation of a highly reactive product termed singlet oxygen (¹O₂) (Table 1). The latter can rapidly cause significant toxicity leading to cell death via apoptosis or necrosis. Antitumor effects of PDT derive from 3 inter-related mechanisms: direct cytotoxic effects on tumor cells, damage to the tumor vasculature, and induction of a robust inflammatory reaction that can lead to the development of systemic immunity. The relative contribution of these mechanisms depends to

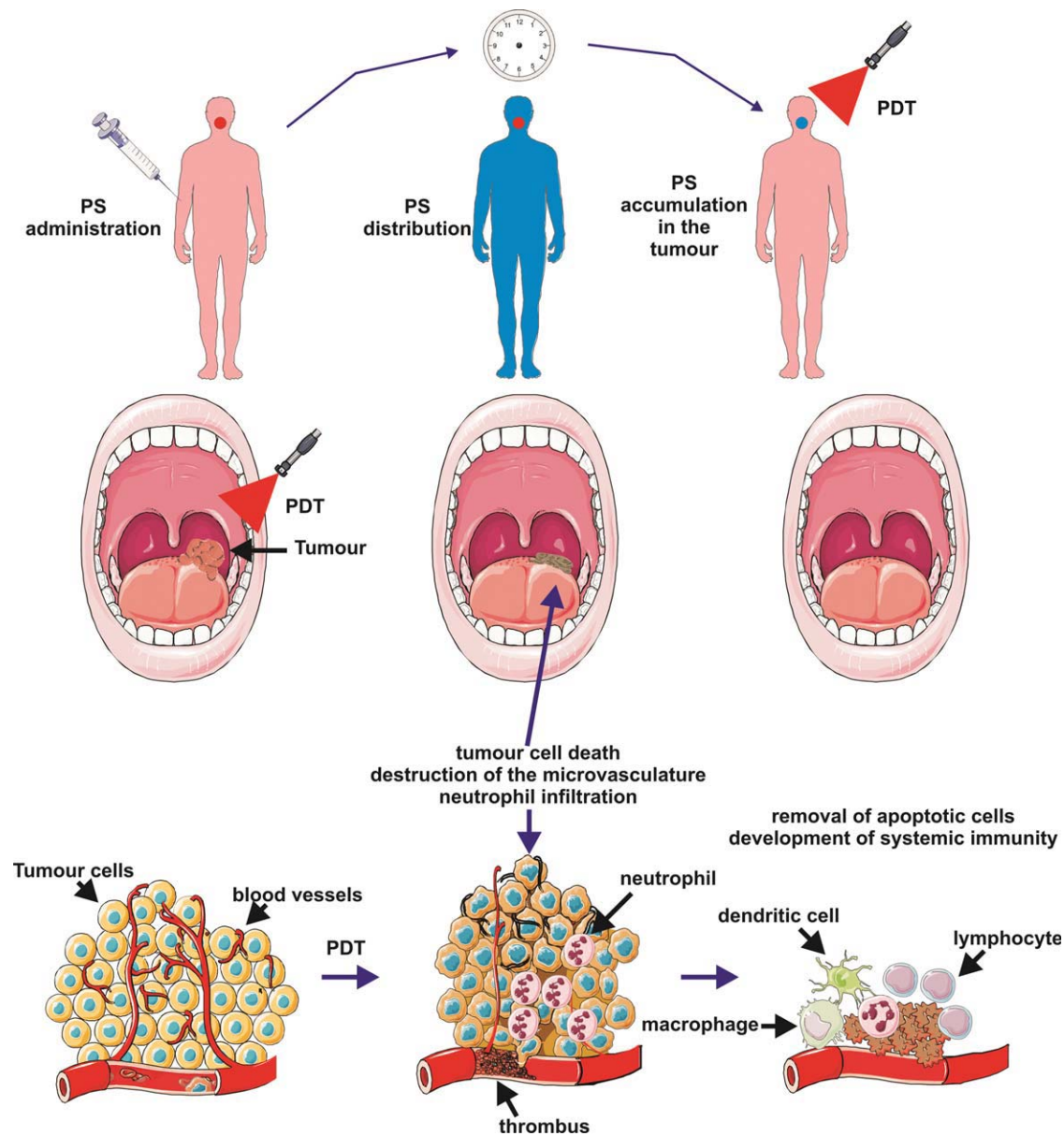


FIGURE 1. The Principles of Photodynamic Therapy (PDT). A photosensitizer (PS) is administered systemically or topically. After a period of systemic PS distribution it selectively accumulates in the tumor. Irradiation activates the PS and in the presence of molecular oxygen triggers a photochemical reaction that culminates in the production of singlet oxygen ($^1\text{O}_2$). Irreparable damage to cellular macromolecules leads to tumor cell death via an apoptotic, necrotic, or autophagic mechanism, accompanied by induction of an acute local inflammatory reaction that participates in the removal of dead cells, restoration of normal tissue homeostasis, and, sometimes, in the development of systemic immunity.

a large extent on the type and dose of PS used, the time between PS administration and light exposure, total light dose and its fluence rate (Table 1), tumor oxygen concentration, and perhaps other still poorly recognized variables. Therefore, determination of optimal conditions for using PDT requires a coordinated interdisciplinary effort. This review will address the most important biological and physico-chemical aspects of PDT, summarize its clinical status, and provide an outlook for its potential future development.

Basic Components of PDT

PDT is a 2-stage procedure. After the administration of a light-sensitive PS, tumor loci are irradiated with a light of appropriate wavelength. The latter can be delivered to virtually any organ in the body by means of flexible fiber-optic devices (Fig. 1). Selectivity is derived from both the ability of useful PSs to localize in neoplastic lesions and the precise delivery of light to the treated sites. Paradoxically, the highly localized nature of PDT is one of its current

limitations, because the treatment is ineffective against metastatic lesions, which are the most frequent cause of death in cancer patients. Ongoing research is focused on finding optimal PDT conditions to induce systemic immunity that might, at least to some extent, obviate this limitation in the future. PDT can be used either before or after chemotherapy, radiotherapy, or surgery without compromising these therapeutic modalities. None of the clinically approved PSs accumulate in cell nuclei, limiting DNA damage that could be carcinogenic or lead to the development of resistant clones. Moreover, the adverse effects of chemotherapy or radiation are absent. Radioresistance or chemoresistance do not affect sensitivity to PDT. Excellent cosmetic outcomes make PDT suitable for patients with skin cancers. There are no significant changes in tissue temperature, and the preservation of connective tissue leads to minimal fibrosis, allowing retention of functional anatomy and mechanical integrity of hollow organs undergoing PDT. Selected patients with inoperable tumors, who have exhausted other treatment options, can also achieve improvement in quality of life with PDT. Finally, many PDT procedures can be performed in an outpatient or ambulatory setting, thereby not only alleviating costs, but also making the treatment patient-friendly. The only adverse effects of PDT relate to pain during some treatment protocols and a persistent skin photosensitization that has been circumvented by the newer agents.

Photosensitizers

Most of the PSs used in cancer therapy are based on a tetrapyrrole structure, similar to that of the protoporphyrin contained in hemoglobin. An ideal PS agent should be a single pure compound to allow quality control analysis with low manufacturing costs and good stability in storage. It should have a high absorption peak between 600 and 800 nanometers (nm) (red to deep red), because absorption of photons with wavelengths longer than 800 nm does not provide enough energy to excite oxygen to its singlet state and to form a substantial yield of reactive oxygen species. Because the penetration of light into tissue increases with its wavelength, agents with strong absorbance in the deep red such as chlorins, bacteriochlorins, and phthalocyanines offer improvement in tumor control. It should have no dark

toxicity and relatively rapid clearance from normal tissues, thereby minimizing phototoxic side effects. Other pertinent desirable properties of PS agents have been summarized elsewhere.⁶ Although the interval between drug administration and irradiation is usually long, so that the sensitizer is given sufficient time to diffuse from normal tissues, reports now suggest that the tumor response may be sometimes better when light is delivered at a shorter drug-light interval when PS is still present in the blood vessels, thus producing marked vascular damage.⁷ Some reports suggest that a pronounced inflammatory response and necrotic cell death after illumination are important in the immune-stimulating function of PDT, whereas others suggest that PSs that produce more apoptosis and less inflammation are suitable for applications such as brain tumors, where swelling is undesirable. Recent findings show that certain PDT-induced apoptotic cell death mechanisms are highly immunogenic and capable of driving antitumor immunity as well.⁸ Finally, the light-mediated destruction of the PS known as photobleaching was previously thought to be undesirable, but some reports suggest that this property may make light dosimetry less critical because overtreatment is avoided when the PS is destroyed during the illumination.⁹

The first PS to be clinically employed for cancer therapy was a water-soluble mixture of porphyrins called hematoporphyrin derivative (HPD), a purified form of which, porfimer sodium, later became known as Photofrin. Although porfimer sodium is still the most widely employed PS, the product has some disadvantages, including a long-lasting skin photosensitivity and a relatively low absorbance at 630 nm. Although a photodynamic effect can be produced with porfimer sodium, efficacy would be improved by red-shifting the red absorbance band and increasing the absorbance at the longer wavelengths. There has been a major effort among medicinal chemists to discover second-generation PSs, and several hundred compounds have been proposed as potentially useful for anticancer PDT. Table 2 displays the most promising PSs that have been used clinically for cancer PDT (whether approved or in trials). The discovery that 5-aminolevulinic acid (ALA) was a biosynthetic precursor of the PS protoporphyrin IX¹⁰ has led to many applications in which ALA or ALA esters can be topically applied or administered orally. These are considered to be "prodrugs," needing to be converted to protoporphyrin

TABLE 2. Clinically Applied Photosensitizers

PHOTOSENSITIZER	STRUCTURE	WAVELENGTH, nm	APPROVED	TRIALS	CANCER TYPES
Porfimer sodium (Photofrin) (HPD)	Porphyrin	630	Worldwide		Lung, esophagus, bile duct, bladder, brain, ovarian
ALA	Porphyrin precursor	635	Worldwide		Skin, bladder, brain, esophagus
ALA esters	Porphyrin precursor	635	Europe		Skin, bladder
Temoporfin (Foscan) (mTHPC)	Chlorine	652	Europe	United States	Head and neck, lung, brain, skin, bile duct
Verteporfin	Chlorine	690	Worldwide (AMD)	United Kingdom	Ophthalmic, pancreatic, skin
HPPH	Chlorin	665		United States	Head and neck, esophagus, lung
SnEt2 (Purlytin)	Chlorin	660		United States	Skin, breast
Talaporfin (LS11, MACE, NPe6)	Chlorin	660		United States	Liver, colon, brain
Ce6-PVP (Fotolon), Ce6 derivatives (Radachlorin, Photodithazine)	Chlorin	660		Belarus, Russia	Nasopharyngeal, sarcoma, brain
Silicon phthalocyanine (Pc4)	Phthalocyanine	675		United States	Cutaneous T-cell lymphoma
Padoporfin (TOOKAD)	Bacteriochlorin	762		United States	Prostate
Motexafin lutetium (Lutex)	Texaphyrin	732		United States	Breast

Abbreviations: ALA, 5-aminolevulinic acid; AMD, age-related macular degeneration; Ce6-PVP, chlorin e6-polyvinylpyrrolidone; HPD, hematoporphyrin derivative; HPPH, 2-(1-hexyloxyethyl)-2-devinyl pyropheophorbide-a; MACE, mono-(L)-aspartylchlorin-e6; mTHPC, m-tetrahydroxyphenylchlorin; nm indicates nanometers; SnEt2, tin ethyl etiopurpurin.

to be active PSs. Many hypotheses have been proposed to account for the tumor-localizing properties in PDT.¹¹ These include the preponderance of leaky and tortuous tumor blood vessels due to neovascularization and the absence of lymphatic drainage known as the enhanced permeability and retention effect.¹² Some of the most effective compounds bind preferentially to low-density lipoprotein (LDL), suggesting that upregulated LDL receptors found on tumor cells could be important.¹³

There have been targeting studies in which PSs are covalently attached to various molecules that have some affinity for neoplasia or to receptors expressed on specific tumors.¹⁴ The intention is to rely on the ability of the targeting vehicle to control localization factors so that the PS can be chosen based on its photochemical properties. These vehicles include monoclonal antibodies, antibody fragments, peptides, proteins (such as transferrin, epidermal growth factor and insulin), LDL, various carbohydrates, somatostatin, folic acid, and many others.

Light Sources

Blue light penetrates least efficiently through tissue, whereas red and infrared radiations penetrate more deeply (Fig. 2). The region between 600 and 1200 nm

is often called the optical window of tissue. However, light up to only approximately 800 nm can generate $^1\text{O}_2$, because longer wavelengths have insufficient energy to initiate a photodynamic reaction.¹⁵ No single light source is ideal for all PDT indications, even with the same PS. The choice of light source should therefore be based on PS absorption (fluorescence excitation and action spectra), disease (location, size of lesions, accessibility, and tissue characteristics), cost, and size. The clinical efficacy of PDT is dependent on complex dosimetry: total light dose, light exposure time, and light delivery mode (single vs fractionated or even metronomic). The fluence rate also affects PDT response.¹⁶ Integrated systems that measure the light distribution and fluence rate either interstitially or on the surface of the tissues being treated are so far used only in experimental studies.

Both lasers and incandescent light sources have been used for PDT and show similar efficacies.¹⁷ Unlike the large and inefficient pumped dye lasers, diode lasers are small and cost-effective, are simple to install, and have automated dosimetry and calibration features and a longer operational life. Such lasers are now being specifically designed for PDT. Light-emitting diodes (LEDs) are alternative light

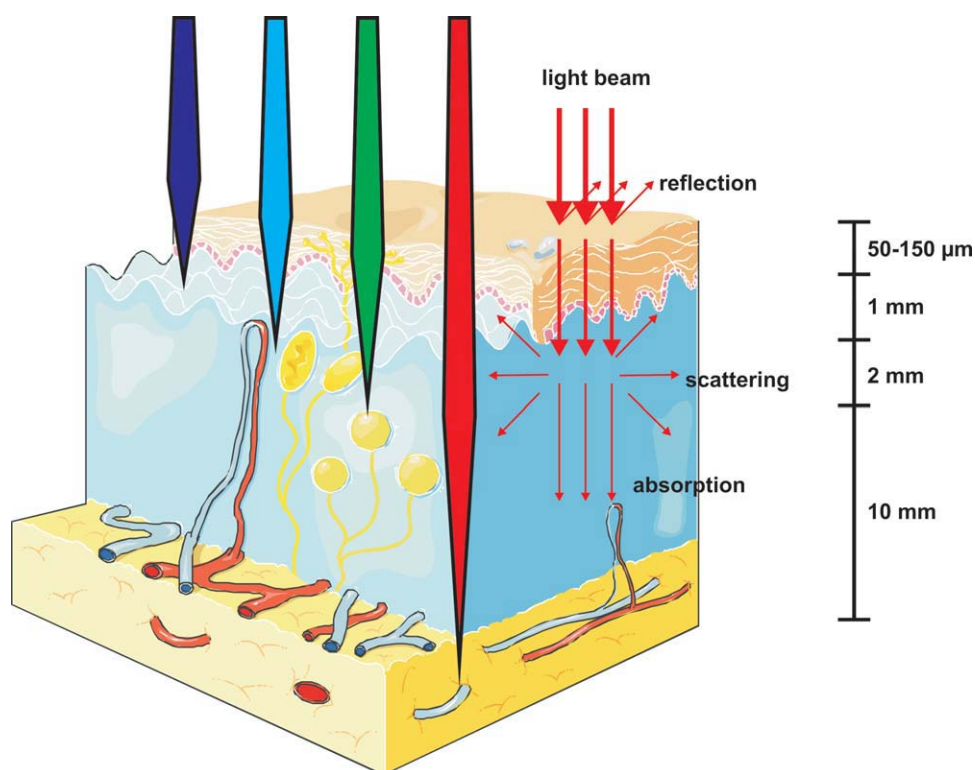


FIGURE 2. Light Propagation Through the Tissues.

sources with relatively narrow spectral bandwidths and high fluence rates.^{18,19} Lasers can be coupled into fibers with diffusing tips to treat tumors in the urinary bladder and the digestive tract. Inflatable balloons, covered on the inside with a strongly scattering material and formed to fit an organ, are also commercially available.²⁰ It is quite feasible to implant a light source in solid organs deep in the body under image guidance. The choice of optimal combinations of PSs, light sources, and treatment parameters is crucial for successful PDT.^{21,22}

Photophysics and Photochemistry

Most PSs in their ground (ie, singlet) state (Table 1) have 2 electrons with opposite spins located in an energetically most favorable molecular orbital. Absorption of light leads to a transfer of one electron to a higher energy orbital (Fig. 3). This excited PS is very unstable and emits this excess energy as fluorescence and/or heat. Alternatively, an excited PS may undergo an intersystem crossing (Table 1) to form a more stable triplet state (Table 1) with inverted spin of one electron. The PS in triplet state can either decay radiationlessly to the ground state or transfer its energy to molecular oxygen (O_2), which is unique

to a powerful and virtually indiscriminate oxidant hydroxyl radical (HO^\bullet). Reactive oxygen species (ROS) generation via Type II chemistry is mechanistically much simpler than via Type I, and most PSs are believed to operate via a Type II rather than Type I mechanism.

Mechanisms of PDT-Mediated Cytotoxicity

The lifetime of 1O_2 is very short (approximately 10-320 nanoseconds), limiting its diffusion to only approximately 10 nm to 55 nm in cells.²⁴ Thus, photodynamic damage will occur very close to the intracellular location of the PS.²⁵ Porphimer sodium is a complex mixture of porphyrin ethers with variable localization patterns mostly associated with lipid membranes. Of the other PS agents in current use, the mono-L-aspartyl chlorin e6 (NPe6, talaporfin) targets lysosomes; the benzoporphyrin derivative (BPD) targets mitochondria; m-tetrahydroxyphenylchlorin (mTHPC, temeporfin) has been reported to target mitochondria, endoplasmic reticulum (ER), or both; and the phthalocyanine Pc4 has a broad spectrum of affinity, although mitochondria are reported to be a primary target.⁶ Other agents that have been

in being a triplet in its ground state. This step leads to the formation of 1O_2 , and the reaction is referred to as a Type II process.²³ A Type I process can also occur whereby the PS reacts directly with an organic molecule in a cellular microenvironment, acquiring a hydrogen atom or electron to form a radical. Subsequent autoxidation of the reduced PS produces a superoxide anion radical ($O_2^{\bullet-}$). Dismutation or one-electron reduction of $O_2^{\bullet-}$ gives hydrogen peroxide (H_2O_2), which in turn can undergo one-electron reduction

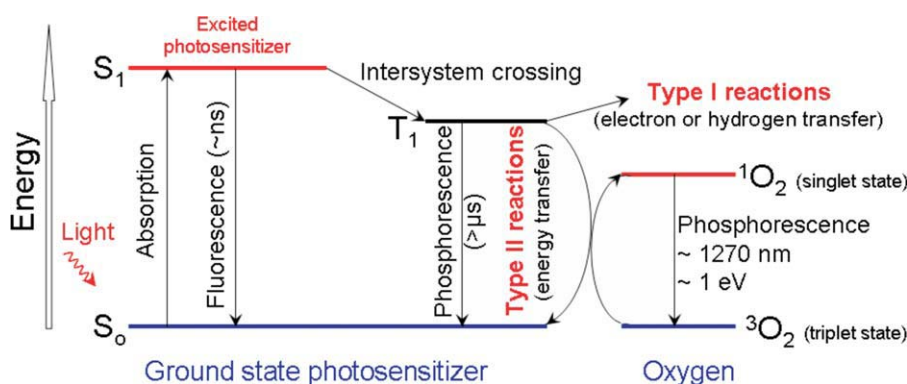


FIGURE 3. Photosensitization Processes Illustrated by a Modified Jablonski Diagram. Light exposure takes a photosensitizer molecule from the ground singlet state (S_0) to an excited singlet state (S_1). The molecule in S_1 may undergo intersystem crossing to an excited triplet state (T_1) and then either form radicals via a Type I reaction or, more likely, transfer its energy to molecular oxygen (3O_2) and form singlet oxygen (1O_2), which is the major cytotoxic agent involved in photodynamic therapy. ns indicates nanoseconds; μ s, microseconds; nm, nanometers; eV, electron volts.

developed can have multiple targets. Specific patterns of localization may vary also among different cell types.

PDT can evoke the 3 main cell death pathways: apoptotic, necrotic, and autophagy-associated cell death (Fig. 4). Apoptosis is a generally major cell death modality in cells responding to PDT. Mitochondria outer membrane permeabilization (MOMP) after photodynamic injury is controlled by Bcl-2 family members and thought to be largely p53-independent.²⁶ With mitochondria-associated PSs, photodamage to membrane-bound Bcl-2²⁷⁻²⁹ can be a permissive signal for MOMP and the subsequent release of caspase activators such as cytochrome c and Smac/DIABLO, or other proapoptotic molecules, including apoptosis-inducing factor (AIF).²⁶ Lysosomal membrane rupture and leakage of cathepsins from photo-oxidized lysosomes^{30,31} induces Bid cleavage and MOMP.³¹

Phototoxicity is not propagated only through caspase signaling but involves other proteases, such as calpains, as well as nonapoptotic pathways.²⁶ Typically, inhibition or genetic deficiency of caspases only delays phototoxicity or shifts the cell death modality toward necrotic cell death.³² Recent evidence suggests indeed that certain forms of necrosis can be propagated through signal transduction pathways.³³ The molecular mechanisms underlying programmed necrosis are still elusive, but certain events including activation of receptor interacting protein 1 (RIP1) kinase, excessive mitochondrial ROS production, lysosomal damage, and intracellular Ca^{2+} overload are recurrently involved.^{33,34} Severe inner mitochondria membrane photodamage or intracellular

Ca^{2+} overload could promote mitochondrial permeability transition, an event that may favor necrotic rather than apoptotic phototoxicity.^{26,35}

Photodamage of cells can also lead to the stimulation of macroautophagy (hereafter referred to as autophagy).^{36,37} This is a lysosomal pathway for the degradation and recycling of intracellular proteins and organelles. Autophagy can

be stimulated by various stress signals including oxidative stress.³⁸ This process can have both a cytoprotective and a prodeath role after cancer chemotherapies, including those involving ROS as primary damaging agents.³⁸ Recent studies delineate autophagy as a mechanism to preserve cell viability after photodynamic injury.³⁷ PSs that photodamage the lysosomal compartment may compromise completion of the autophagic process, causing incomplete clearance of the autophagic cargo. Accumulation of ROS-damaged cytoplasmic components may then potentiate phototoxicity in apoptosis-competent cells.³⁷ A better understanding of the interplay between autophagy, apoptosis, and necrosis and how these processes lead to improved tumor response will be a requisite to devise better therapeutic strategies in PDT.

Cytoprotective Mechanisms

Numerous publications have reported cytoprotective mechanisms that cancer cells exploit to avoid the cytotoxic effects of PDT.²⁶ The first mechanism identified was based on the large variation observed in the level of antioxidant molecules expressed in cancer cells.³⁹ Both water-soluble antioxidants (eg, some amino acids, glutathione [GSH], or vitamin C) and lipid-soluble antioxidants (eg, vitamin E) are present at variable levels in many cancer cell types, explaining the large variation in PDT sensitivity.⁴⁰ A second mechanism is associated with expression in cancer cells of enzymes that can detoxify ROS. Although there is no specific cellular enzyme that can directly detoxify 1O_2 , enzymes involved in other ROS metabolism can influence the cytotoxic effect

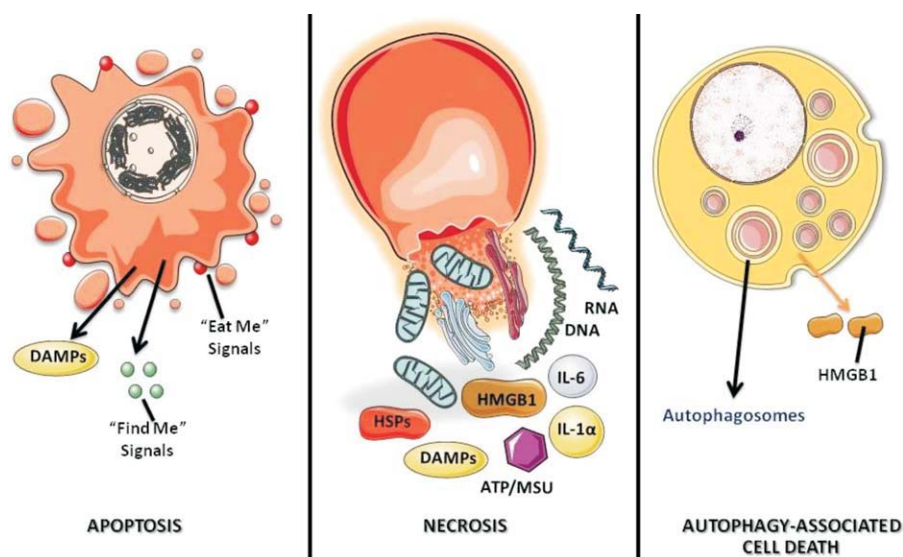


FIGURE 4. Three Major Cell Death Morphotypes and Their Immunological Profiles. Apoptosis is morphologically characterized by chromatin condensation, cleavage of chromosomal DNA into internucleosomal fragments, cell shrinkage, membrane blebbing, and the formation of apoptotic bodies without plasma membrane breakdown. Typically, apoptotic cells release “find me” and “eat me” signals required for the clearance of the remaining corpses by phagocytic cells. At the biochemical level, apoptosis entails the activation of caspases, a highly conserved family of cysteine-dependent, aspartate-specific proteases. Necrosis is morphologically characterized by vacuolization of the cytoplasm and swelling and breakdown of the plasma membrane, resulting in an inflammatory reaction due to the release of cellular contents and proinflammatory molecules. Classically, necrosis is thought to be the result of pathological insults or to be caused by a bioenergetic catastrophe, adenosine triphosphate (ATP) depletion to a level incompatible with cell survival. The biochemistry of necrosis is characterized mostly in negative terms by the absence of caspase activation, cytochrome c release, and DNA oligonucleosomal fragmentation. Autophagy is characterized by a massive vacuolization of the cytoplasm. Autophagic cytoplasmic degradation requires the formation of a double-membrane structure called the autophagosome, which sequesters cytoplasmic components as well as organelles and traffics them to the lysosomes. Autophagosome-lysosome fusion results in the degradation of the cytoplasmic components by the lysosomal hydrolases. In adult organisms, autophagy functions as a self-digestion pathway promoting cell survival in an adverse environment and as a quality control mechanism by removing damaged organelles, toxic metabolites, or intracellular pathogens. DAMPs indicates damage-associated molecular patterns; HSPs, heat shock proteins; HMGB1, high-mobility group protein B1; IL, interleukin; ATP/MSU, adenosine triphosphate/monosodium urate.

of PDT. For example, superoxide dismutase (SOD) overexpression or treatment with SOD mimetics have been shown to counteract the cytotoxic effect of PDT.⁴¹ An increase in SOD activity has also been observed in various cancer cell types after PDT, and this is associated with a decrease in GSH peroxidase and catalase activities.⁴² The third cytoprotective mechanism involves proteins whose encoding genes are themselves induced by PDT. Many categories can be specified but most of them are part of signaling pathways that can regulate PDT-induced apoptosis⁴³ or participate in the repair of lesions induced by oxidative stress. NF- κ B inhibition by overexpression of the I κ B α super-repressor or by the use of pharmacological inhibitors strongly sensitizes cancer cells to apoptosis induced by PDT.⁴⁴ Other stress-related transcription factors induced by PDT include activator protein 1 (AP-1), hypoxia-inducible factor (HIF), or nuclear factor-like 2 (Nrf2). PDT was shown to upregulate heme oxygenase-1

(HO-1) expression, and the mechanism is dependent on Nrf2 nuclear accumulation and on p38 mitogen-activated protein kinase (p38^{MAPK}) and phosphoinositide 3-kinase (PI3K) activities. Because of the antioxidant activity of HO-1, it can be envisioned that Nrf2-dependent signal transduction can control cellular protection against PDT-mediated cytotoxic effects.

PDT was found to induce expression of various heat shock proteins (HSPs) for which a protective role in PDT has been described. For example, transfection of tumor cells with the HSP27 gene increased the survival of tumor cells after PDT.⁴⁵ Similarly, increased HSP60 and HSP70 levels are inversely correlated with sensitivity to the photodynamic treatment.^{46,47} The simplest

explanation for these observations is the ability of HSPs to bind to oxidatively damaged proteins. Moreover, the intracellular function of HSPs is not only restricted to protein refolding. Many HSPs “client” proteins play a critical role in the regulation of prosurvival pathways. PDT also leads to increased ubiquitination of carbonylated proteins, thereby tagging them for degradation in proteasomes, which prevents the formation of toxic protein aggregates.⁴⁸

Antivascular Effects of PDT

Photodynamic perturbation of tissue microcirculation was first reported in 1963.⁴⁹ A study by Star et al⁵⁰ utilized a window chamber to make direct observations of implanted mammary tumor and adjacent normal tissue microcirculation in rats before, during, and at various times after PDT sensitized with HPD. An initial blanching and vasoconstriction of the tumor vessels was followed by heterogeneous

responses including eventual complete blood flow stasis, hemorrhage, and, in some larger vessels, the formation of platelet aggregates. Observations performed on excised tissues from murine models demonstrated a wide range of vascular responses, including disruption of blood flow to subcutaneous urothelial tumors and to normal rat jejunum, breakdown of the blood-brain barrier in the normal brain of mice, and endothelial cell and organelle damage in subcutaneous tumors and normal tissue.^{51,52}

Other studies demonstrated that tumor cells treated with a potentially curative photodynamic dose *in vivo* were clonogenic if removed immediately from the host.^{53,54} Progressive loss in clonogenicity was seen when tumors were left in the host for increasing durations; this corresponded to progression of PDT-induced hypoxia as determined radiobiologically. Hypoxia sufficient to preclude direct tumor cell killing was identified at subcurative PDT doses. These studies suggested a central role for vascular damage in governing the tumor response to PDT in mouse models.

Many reports cited above directly implicate the endothelium as a primary target for PDT *in vivo*; this stimulated research into the relative sensitivity of endothelial cells to PDT and the responses of endothelial cells that could initiate the various phenomena at the vessel level. Gomer et al⁵⁵ showed that bovine endothelial cells were significantly more sensitive to PDT with porfimer sodium than smooth muscle cells or fibroblasts from the same species. This increased sensitivity, assessed by clonogenic assay, was not a result of increased porfimer sodium accumulation. Sensitivity to HPD-mediated PDT of bovine aorta endothelial cells and human colon adenocarcinoma cells was investigated by West et al.⁵⁶ Exponentially growing endothelial cells were significantly more sensitive than similarly proliferating tumor cells, and the difference in sensitivity was accompanied by greater PS accumulation in the endothelial cells. Endothelial cell responses to sublethal doses of PDT may also contribute to vascular changes observed in tissue.

Increased vessel permeability to albumin in the rat cremaster muscle during and after PDT with porfimer sodium was reported by Fingar et al.⁵⁷ More recently, intravital fluorescence imaging has been used to demonstrate treatment-induced increases in tumor vessel permeability for PDT with verteporfin and talaporfin.^{58,59} In a pioneering study, Synder

et al⁶⁰ showed that 2-(1-hexyloxyethyl)-2-devinyl pyropheophorbide-a (HPPH) PDT induction of increased tumor vascular permeability resulted in enhanced accumulation of Doxil (Centocor Ortho Biotech Products, Horsham, Penn), a liposome-encapsulated formulation of doxorubicin. When Doxil was administered immediately after PDT, tumor control and selectivity were potentiated significantly relative to either modality alone. In a study motivated by the need to deliver chemotherapeutic agents to the brain adjacent to a tumor, PDT with ALA was used successfully to transiently disrupt the blood-brain barrier in normal rat brain *in vivo*.⁶¹ These and other aspects of vascular-targeted PDT represent important current research directions.

PDT and the Immune Response

Inflammation and Innate Immunity

PDT frequently provokes a strong acute inflammatory reaction observed as localized edema at the targeted site.⁴ This reaction is a consequence of PDT-induced oxidative stress. Thus, PDT can be ranked among cancer therapies (including cryotherapy, hyperthermia, and focused ultrasound ablation) producing chemical/physical insult in tumor tissue perceived by the host as localized acute trauma. This prompts the host to launch protective actions evolved for dealing with a threat to tissue integrity and homeostasis at the affected site.⁶² The acute inflammatory response is the principal protective effector process engaged in this context. Its main task is containing the disruption of homeostasis and ensuring removal of damaged cells, and then promoting local healing with restoration of normal tissue function.

The inflammation elicited by PDT is a tumor antigen nonspecific process orchestrated by the innate immune system.⁶² The recognition arm of this system, in particular pattern recognition receptors (Table 1), is responsible for detecting the presence of a PDT-inflicted, tumor-localized insult revealed to its sensors as the appearance of “altered self.”⁶² PDT appears particularly effective in rapidly generating an abundance of alarm/danger signals, also called damage-associated molecular patterns (DAMPs) (Table 1) or cell death-associated molecular patterns (CDAMPs), at the treated site that can be detected by the innate immunity alert elements.⁶²

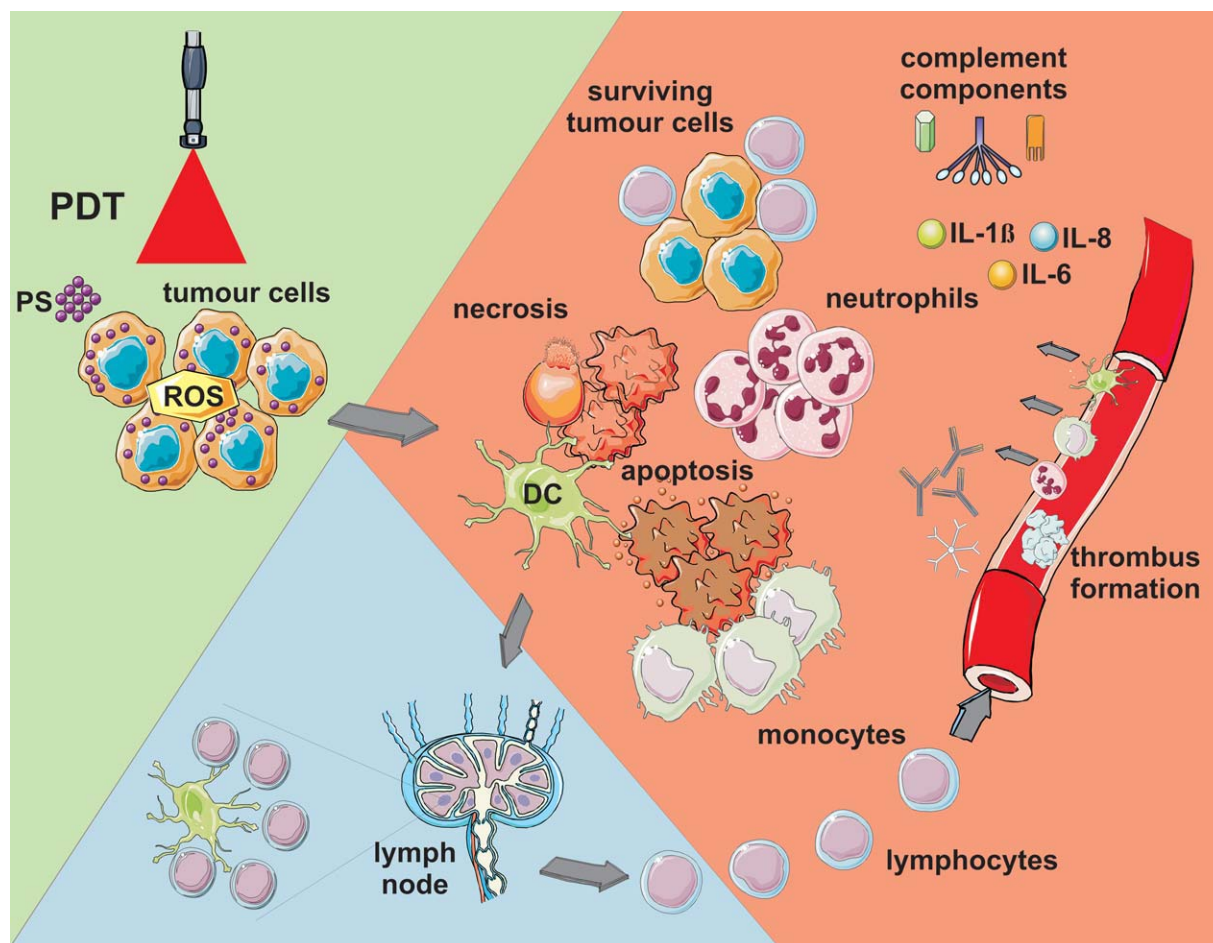


FIGURE 5. Photodynamic Therapy (PDT)-Induced Effects. Light-mediated excitation of photosensitizer (PS)-loaded tumor cells leads to the production of reactive oxygen species (ROS) within these cells, leading to cell death (predominantly apoptotic and necrotic). Tumor cell kill is further potentiated by damage to the microvasculature (not shown), which further restricts oxygen and nutrient supply. Tumor cell death is accompanied by activation of the complement cascade; secretion of proinflammatory cytokines; and rapid recruitment of neutrophils, macrophages, and dendritic cells (DCs). Dying tumor cells and tumor cell debris are phagocytosed by phagocytic cells, including DCs, which migrate to the local lymph nodes and differentiate into professional antigen-presenting cells. Tumor antigen presentation within the lymph nodes is followed by clonal expansion of tumor-sensitized lymphocytes that home to the tumor and eliminate residual tumor cells. IL indicates interleukin.

The onset of PDT-induced inflammation is marked by dramatic changes in the tumor vasculature, which becomes permeable for blood proteins and proadhesive for inflammatory cells.⁶² This occurs even with those PSs that mainly target tumor rather than vascular cells, where the inflammatory process is predominantly initiated by signals originating from photo-oxidative damage produced in perivascular regions with chemotactic gradients reaching the vascular endothelium. The inflammatory cells, led by neutrophils and followed by mast cells and monocytes/macrophages, rapidly and massively invade tumors undergoing PDT (Fig. 5).^{4,63} Their primary task is to neutralize the source of DAMPs/CDAMPs by eliminating debris containing compromised tissue elements, including injured and dead cells.

Damage and dysfunction of photodynamically treated tumor vasculature frequently results in vascular occlusion that serves to “wall off” the damaged tumor tissue until it is removed by phagocytosis, thereby preventing the spread of the disrupted homeostasis.⁶² Depletion of these inflammatory cells or inhibition of their activity after PDT was shown to diminish therapeutic effect.⁶⁴⁻⁶⁷ Among cytokines involved in the regulation of the inflammatory process, the most critical role in tumor PDT response is played by interleukin (IL)-1 β and IL-6.^{68,69} Blocking the function of various adhesion molecules was proven also to be detrimental to PDT response.^{68,69} Conversely, blocking anti-inflammatory cytokines such as IL-10 and transforming growth factor- β can markedly improve the cure rates after PDT.⁶²

PDT and Adaptive Immunity

Numerous preclinical and clinical studies have demonstrated that PDT can influence the adaptive immune response in disparate ways; some regimens result in potentiation of adaptive immunity, whereas others lead to immunosuppression. The precise mechanism leading to potentiation versus suppression is unclear; however, it appears as though the effect of PDT on the immune system is dependent upon the treatment regimen, the area treated, and the photosensitizer type.^{66,70} PDT-induced immune suppression is largely confined to cutaneous and transdermal PDT regimens involving large surface areas.^{70,71}

PDT efficacy appears to be dependent upon the induction of antitumor immunity. Long-term tumor response is diminished or absent in immunocompromised mice (Table 1).^{64,72} Reconstitution of these animals with bone marrow or T cells from immunocompetent mice (Table 1) results in increased PDT efficacy. Clinical PDT efficacy also appears to depend on antitumor immunity. Patients with vulval intraepithelial neoplasia (VIN) who did not respond to PDT with ALA were more likely to have tumors that lacked major histocompatibility complex class I molecules (MHC-I) (Table 1) than patients who responded to PDT with ALA.⁷³ MHC-I recognition is critical for activation of CD8⁺ T cells and tumors that lack MHC-I are resistant to cell-mediated antitumor immune reactions.⁷⁴ VIN patients who responded to PDT had increased CD8⁺ T-cell infiltration into the treated tumors compared with nonresponders. Immunosuppressed and immunocompetent patients with actinic keratoses and Bowen disease had similar initial response rates to PDT; however, immunosuppressed patients exhibited greater persistence of disease or the appearance of new lesions.⁷⁵

Canti et al⁷⁶ were the first to show PDT-induced immune potentiation, demonstrating that cells isolated from tumor-draining lymph nodes of PDT-treated mice were able to confer tumor resistance to naïve mice (Table 1). Subsequent studies demonstrated that PDT directed against murine tumors resulted in the generation of immune memory.⁷⁷ Recent reports have shown that clinical antitumor PDT also increases antitumor immunity. PDT of multifocal angiosarcoma of the head and neck

resulted in increased immune cell infiltration into distant untreated tumors that was accompanied by tumor regression.⁷⁸ PDT of basal cell carcinoma (BCC) increased immune cell reactivity against a BCC-associated antigen.⁷⁹

The mechanism whereby PDT enhances antitumor immunity has been examined for the past several decades. PDT activates both humoral and cell-mediated antitumor immunity, although the importance of the humoral response is unclear. PDT efficacy in mice and humans is reduced in the absence of CD8⁺ T-cell activation and/or tumor infiltration.^{64,73,80} Therefore, most mechanistic studies have focused on the means by which PDT potentiates CD8⁺ T-cell activation. It is clear that induction of antitumor immunity after PDT is dependent upon induction of inflammation.⁸¹ PDT-induced acute local and systemic inflammation is postulated to culminate in the maturation and activation of dendritic cells (DCs). Mature DCs are critical for activation of tumor-specific CD8⁺ T cells and the induction of antitumor immunity.⁸² DCs are activated in response to PDT⁶⁹ and migrate to tumor-draining lymph nodes, where they are thought to stimulate T-cell activation.^{69,83} Generation of CD8⁺ effector and memory T cells is frequently, but not always, dependent upon the presence and activation of CD4⁺ T cells.⁸⁴ PDT-induced antitumor immunity may⁶⁴ or may not depend on CD4⁺ T cells⁸⁰ and may be augmented by natural killer cells.⁸⁰

PDT-mediated enhancement of antitumor immunity is believed to be due, at least in part, to stimulation of DCs by dead and dying tumor cells, suggesting that in vitro PDT-treated tumor cells may act as effective antitumor vaccines.⁸⁵ This hypothesis has been proven by several studies using a wide variety of PSs and tumor models in both preventive and therapeutic settings.^{67,85-87}

Mechanistic studies showed that incubation of immature DCs with PDT-treated tumor cells leads to enhanced DC maturation and activation and an increased ability to stimulate T cells.^{85,88} PDT of tumor cells causes both cell death and cell stress,^{4,89,90} and it is hypothesized that the activation of DCs by PDT-treated cells is the result of recognition of DAMPs/CDAMPs that are released/secreted/exposed by PDT from dying cells.⁹¹⁻⁹³ HSP70 is a well-characterized DAMP that interacts with the

danger signal receptors, Toll-like receptors 2 and 4,⁹⁴ and is induced by PDT.⁹⁵ The level of expression of HSP70 in PDT-treated tumor cells appears to correlate with an ability to stimulate DC maturation⁹⁶ and the initiation of inflammation.^{92,97} Furthermore, opsonization of photodynamically treated tumor cells by complement proteins increases the efficacy of PDT-generated vaccines.⁸⁶ PDT therefore induces multiple danger signals capable of triggering antigen-presenting cell activation and antitumor immunity.

The implications of PDT-induced antitumor immunity and efficacious PDT-generated vaccines are significant and provide an exciting possibility for using PDT in the treatment of metastatic disease and as an adjuvant in combination with other cancer modalities. Several preclinical studies demonstrated that PDT is able to control the growth of tumors present outside the treatment field,^{80,98} although others have failed to demonstrate control of distant disease after PDT.^{99,100} PDT was also shown to be an effective surgical adjuvant in patients with non-small cell lung cancer with pleural spread.¹⁰¹

Combinations of PDT With Other Therapies

Combinations of various therapeutic modalities with nonoverlapping toxicities are among the commonly used strategies to improve the therapeutic index of treatments in modern oncology. Two general approaches may increase the antitumor effectiveness of PDT: 1) sensitization of tumor cells to PDT and 2) interference with cytoprotective molecular responses triggered by PDT in surviving tumor or stromal cells. Any interactions between PDT and PDT-sensitizing agents will be confined to the illuminated area. Therefore, the potentiated toxicity of the combinations is not systemic. This should be of special importance in elderly or debilitated patients who tolerate more intensive therapeutic regimes poorly. Moreover, considering its unique ¹O₂-dependent cytotoxic effects, PDT can be safely combined with other antitumor treatments without the risk of inducing cross-resistance.¹⁰²

There have been few studies on combinations of PDT with standard antitumor regimens published to date. PDT can be used in combination with surgery as a neoadjuvant, adjuvant, or repetitive

adjuvant treatment, preferably fluorescence image-guided to confine illumination to the most suspicious lesions. PDT has also been successfully combined with radiotherapy and chemotherapy (Table 3).^{41,48,103-144}

Another approach to promote PDT efficacy involves increased PS delivery or impaired loss from tumor cells. The first approach involves conjugation of PSs to various tumor-targeting molecules as is described above. This may be important in the treatment of tumors where large surface areas are illuminated and hence increased tumor selectivity is desired (eg, superficial spreading bladder cancer or metastases to the peritoneum and pleural cavity).¹⁴ The use of compounds that impair PS efflux has also been demonstrated to effectively sensitize tumor cells to PDT, although such approaches seem to be limited to those PSs that are the substrates of outward transport systems such as ABCG2.¹¹⁵ Another approach involves increased conversion of ALA or its esters into protoporphyrin IX by iron-chelating agents.¹⁴⁵

The development of novel target-specific antitumor drugs has enabled examination of a number of concept-based combinations that in various molecular mechanisms sensitize tumor cells to the cytotoxic effects of PDT. Proteins are major targets for oxidative reactions because they constitute nearly 70% of the dry weight of cells. Oxidized proteins can be refolded by molecular chaperones (Table 1) such as HSPs. Inefficient restoration of their structure leads to accumulation of misfolded proteins and their aggregation, which precipitates cell death. Accumulation of damaged or misfolded proteins within ER triggers a process called ER stress, which can be ameliorated by unfolded protein response or can lead to cell death.¹⁴⁶ Therapeutic approaches that interfere with refolding or removal of oxidized proteins can be used to sensitize tumor cells to PDT. For example, modulation of HSP function with geldanamycin, a HSP90 inhibitor, sensitizes tumor cells to PDT.¹²⁸ Bortezomib, a proteasome inhibitor successfully used in the treatment of hematological disorders, potentiates the cytotoxic effects of PDT by aggravation of ER stress.⁴⁸ Moreover, several apoptosis-modulating factors such as rapamycin, Bcl-2 antagonists, ursodeoxycholic acid, or ceramide analogues have been shown to increase PDT-mediated cancer cell death (Table 3).

TABLE 3. Combinations of PDT and Various Therapeutic Modalities in Cancer Treatment: A Comprehensive Summary

DRUG OR TREATMENT MODALITY	OUTCOME/RESULTS
CHEMOTHERAPEUTICS AND NOVEL ANTICANCER DRUGS	
Anthracyclines	Doxorubicin improves PDT-mediated tumor growth control in mice ¹⁰³
Platinum compounds	Cisplatin potentiates antitumor activity of PDT in mice ¹⁰³
Antimetabolites	Methotrexate enhances in vitro cytotoxicity of PDT with ALA by upregulation of protoporphyrin IX production ¹⁰⁴
Microtubule inhibitors	Vincristine administered prior to or immediately after PDT improves its antitumor activity in mice ¹⁰⁵
DNA methyltransferase inhibitors	5-azadeoxycytidine prolongs survival of PDT-treated animals and improves tumor growth control ¹⁰⁶
Proteasome inhibitors	Bortezomib enhances PDT-mediated ER stress in cancer cells in vitro and significantly delays post-PDT tumor regrowth in mice ⁴⁸
RADIOTHERAPY	
Two-way enhancement of antitumor effects: PDT sensitizes cancer cells to radiotherapy ¹⁰⁷ and radiotherapy increases anticancer efficacy of PDT, ¹⁰⁸ prolonged tumor growth control induced by combined treatment ¹⁰⁹	
DRUGS MODULATING ARACHIDONIC ACID CASCADE	
COX-2 inhibitors	COX-2 inhibitors (such as NS-398, ¹¹⁰ nimesulide, ¹¹¹ or celecoxib ¹¹²) potentiate antitumor effects of PDT, possibly through indirect antiangiogenic effects
LOX inhibitors	MK-886, which also serves as a FLAP inhibitor, sensitizes tumor cells to PDT-mediated killing ¹¹³
AGENTS INCREASING PS ACCUMULATION IN TUMOR CELLS	
Vitamin D	Increases ALA-induced protoporphyrin IX accumulation and thus potentiates PDT cytotoxicity in vitro ¹¹⁴
Imatinib	Increases intracellular accumulation of second-generation PSs and thus potentiates PDT cytotoxicity in vitro and in vivo ¹¹⁵
Lipid-lowering drugs	Lovastatin, a HMG-CoA reductase inhibitor, improves in vitro LDL binding and porfimer sodium uptake by cancer cells ¹¹⁶
Salicylate and related drugs	Enhancement of PDT efficacy in vitro via increased PS uptake by tumor cells ¹¹⁷
APPROACHES INCREASING OXYGEN DELIVERY TO TUMOR CELLS	
EPO	EPO improves chemotherapy-induced anemia and restores antitumor efficacy of PDT in mice ¹¹⁸ ; however, EPO might also inhibit direct PDT-mediated cytotoxicity toward certain cancer cells ¹¹⁹
Hyperbaric oxygen	Increased antitumor effects of PDT in mice ¹²⁰ and in advanced pleural tumors in humans ¹²¹
Hyperthermia	In various treatment regimens, hyperthermia potentiates antitumor efficacy of PDT in vitro and in animal models ¹²² ; the short time interval between these 2 treatment modalities might increase normal tissue injury via vascular effects ¹²³
TARGETING CYTOPROTECTIVE MECHANISMS AND INCREASING OF RADICAL FORMATION IN CANCER CELLS	
Disruption of heme degradation pathway	Targeting of HO-1 with selective inhibitors ¹²⁴ and siRNA ¹²⁵ as well as an siRNA-mediated knockdown of ferrochelatase ¹²⁵ or chelation of iron ions ¹²⁶ potentiate antitumor effects of PDT
Inhibition of SOD	2-methoxyestradiol, a natural SOD inhibitor, enhances PDT cytotoxicity in vitro and improves antitumor effects of PDT in mice ⁴¹
NO synthase inhibition	Improved tumor response to PDT in mice ¹²⁷
HSP90 modulation	Interference with HSP90 client proteins binding using a geldanamycin derivative improves responsiveness to PDT both in vitro and in vivo ¹²⁸
Lowering cellular GSH content	Depleting GSH levels in tumor cells using buthionine sulfoximine significantly enhances PDT efficacy in vitro and in vivo ¹²⁹
Vitamin E and its analogues	α -tocopherol-mediated radical production enhances PDT toxicity in vitro and in vivo ¹³⁰
TARGETING OF TUMOR VASCULATURE	
Antiangiogenic treatment	Anti-VEGF ¹³¹ or anti-VEGFR ¹³² monoclonal antibodies, matrix metalloproteinase inhibitor (prinomastat), ¹³³ TNP-470, ¹³⁴ and other antiangiogenic agents ^{135,136} as well as adenovirus-driven IL-12 expression ¹³⁷ potentiate antitumor effects of PDT in mice
APOPTOSIS PROMOTION OR G1 CELL CYCLE INHIBITION IN PDT-TREATED CELLS	
Bcl-2 antagonist synergizes with PDT in in vitro cytotoxicity ¹³⁸	
Ursodeoxycholic acid sensitizes mitochondrial membranes in tumor cells to PDT-mediated damage ¹³⁹	
A ceramide analogue delays tumor regrowth after PDT in mice ¹⁴⁰	
Rapamycin (an mTOR inhibitor) delivered after PDT enhances its in vitro cytotoxicity ¹⁴¹	

TABLE 3. Continued

OTHER APPROACHES	
Combinations of 2 different photosensitizers	PDT with 5-ALA and low-dose porfimer sodium demonstrates enhanced antitumor efficacy in vitro and in vivo with no risk of prolonged skin photosensitivity ¹⁴²
	PDT with BPD and benzothiazine synergizes in antitumor activity in vitro and in vivo ¹⁴³
Hypoxia-activated bioreductive drugs	Improved tumor response to PDT in mice exposed to mitomycin C ¹⁴⁴

Abbreviations: ALA, 5-aminolevulinic acid; BPD, benzoporphyrin derivative; COX-2, cyclooxygenase-2; EPO, erythropoietin; ER, estrogen receptor; FLAP, 5-lipoxygenase-activating protein; GSH, glutathione; HMG-CoA, 3-hydroxy-3-methylglutaryl coenzyme A; HO-1, heme oxygenase-1; HSP90, heat shock protein 90; IL-12, interleukin-12; LDL, low-density lipoprotein; LOX, lipoxygenase; mTOR, mammalian target of rapamycin; NO, nitric oxide; PDT indicates photodynamic therapy; PS, photosensitizer; siRNA, small interfering RNA; SOD, superoxide dismutase; VEGF, vascular endothelial growth factor; VEGFR, vascular endothelial growth factor receptor.

Transformed cells deeply seated within the tumor mass receive suboptimal light doses and survive due to induction of numerous cytoprotective mechanisms. Targeting enzymes participating in ROS scavenging (such as superoxide dismutase, HO-1, or nitric oxide synthase) with selective inhibitors has been shown to improve the antitumor activity of PDT.^{41,124,127} Antivascular effects of PDT can be further potentiated by cyclooxygenase (COX) inhibitors,¹¹⁰ antiangiogenic or antivascular drugs,¹³⁵ or monoclonal antibodies targeting factors promoting neovascularization (such as vascular endothelial growth factor),¹⁴⁷ significantly improving tumor growth control after PDT. Finally, combining PDT with agents that target signal transduction pathways such as the anti-epidermal growth factor receptor agent cetuximab may also improve the efficacy of PDT.¹⁴⁸ Moreover, combining 2 different PSs in one treatment regimen leads to simultaneous targeting of tumor as well as vascular cells.¹⁴² The use of agents that enhance the efficacy without increasing the normal tissue effects of PDT, thereby improving the therapeutic index, will represent a major focus of clinical research going forward.

Clinical PDT

The clinical use of PDT for cancer dates to the late 1970s, when there was a study published on the effects of HPD plus light in 5 patients with bladder cancer.¹⁴⁹ In 1978, Dougherty et al reported the first large series of patients successfully treated with PDT using HPD.¹⁵⁰ Complete or partial responses were observed in 111 of 113 malignant lesions. Of the large variety of tumors examined, none was found to be unresponsive. Since this early work, there have been over 200 clinical trials for PDT.

Recent systematic reviews^{151,152} revealed that PDT can be considered a reasonable option in the treatment of malignant and premalignant nonmelanoma skin lesions. It is also useful in the treatment of Barrett esophagus and unresectable cholangiocarcinoma (CC). However, its effectiveness in the management of other types of tumors has not yet been unequivocally proven. The major reason for this is that only a few adequately powered randomized controlled trials have been performed to date. Systematic analysis of the literature is limited due to lack of optimal PDT parameters (illumination conditions or PS dose) that could be comparable among these studies.

PDT produces mostly superficial effects. Due to a limited light penetration through tissues, the depth of tumor destruction ranges from a few millimeters to up to 1 centimeter. This apparent disadvantage can be favorably exploited in the treatment of superficial diseases, such as premalignant conditions (mucous dysplasia, actinic keratosis), carcinoma in situ (CIS), or superficial tumors (such as malignant pleural mesothelioma¹⁵³ or intraperitoneal disseminated carcinomatosis^{154,155}). Moreover, PDT can be used supplemental to surgery, to irradiate the tumor bed, and to increase the probability of long-term local disease control.

Skin Tumors

PDT using porfimer sodium and ALA and its derivatives has been extensively studied in the treatment of both premalignant and malignant skin tumors.^{156,157} In the definitive setting, PDT is currently approved in the United States, Canada, and the European Union (EU) for the treatment of actinic keratosis (AK) and approved in the EU and Canada for the treatment of BCC. PDT has demonstrated efficacy in treating squamous cell carcinoma

(SCC) in situ/Bowen disease and has also been used with some success to treat extramammary Paget disease. However, the results of PDT for SCC of the skin using topical PSs have been disappointing, with recurrence rates of greater than 50%.^{156,157}

PDT for AK and PDT for SCC In Situ/Bowen Disease

Successful results for PDT of nonhyperkeratotic AK have been achieved with systemically administered porfimer sodium as well as topically applied ALA and methyl-ALA (MAL). Twenty randomized controlled trials that reported the use of PDT in the treatment of AK have been identified. Kennedy et al¹⁵⁸ introduced topically applied ALA for the treatment of nonhyperkeratotic AK with complete response rates for AK lesions exceeding 75%. In a placebo-controlled trial, PDT with ALA showed a significantly superior complete response rate compared with placebo PDT using vehicle plus light (89% vs 13%; $P < .001$).¹⁵⁹ Similar results were obtained using PDT with MAL.^{160,161} Other studies have compared PDT for AK with cryotherapy or topical fluorouracil (5-FU) cream. In one study, 119 subjects with 1501 AK lesions of the scalp and face were randomly assigned to receive PDT with MAL to either the left- or right-sided lesions with cryotherapy used to treat the contralateral side.¹⁶² Twenty-four weeks after therapy, both treatment groups showed a high response rate (89% for PDT with MAL vs 86% for cryotherapy; $P = .2$), but PDT with MAL showed superior cosmesis and patient preference. Similar results have been found in other large randomized trials of PDT with MAL versus cryotherapy, with complete response rates for both ranging from 68% to 81% for cryotherapy and 69% to 92% for PDT with MAL.^{19,160,161,163} In conclusion, multiple trials have demonstrated complete response rates of 70% to 90% with good to excellent cosmetic outcomes in greater than 90% of patients for PDT of AK. In a randomized study comparing 5-FU cream with PDT using either ALA or MAL in the treatment of AK, equivalent complete response rates were found with comparable or superior tolerability for PDT.^{164,165} Current studies have focused on novel PS drugs and reformulations of ALA, such as nanoemulsion or patch-based applicators, that may increase the complete response rate for AK at 12 months to greater than 95%.¹⁶⁶

The results of PDT with ALA in the treatment of patients with Bowen disease (SCC in situ) have been equally positive and to date were reported in 6 randomized clinical trials. Randomized controlled trials comparing PDT with ALA or MAL with cryotherapy or 5-FU cream reveal complete response rates of 82% to 100% for PDT versus 67% to 100% for cryotherapy or 79% to 94% for 5-FU at 12 to 24 months.¹⁶⁷⁻¹⁶⁹

PDT for BCC

Other indications for PDT with ALA include superficial and nodular BCC.¹⁷⁰⁻¹⁷² Six randomized clinical trials have reported the results of PDT for nodular BCC; 5 evaluated PDT efficacy in the treatment of superficial BCC, and 2 were performed in patients with mixed superficial and nodular BCC. In the largest single institution experience with 1440 nodular and superficial BCCs, PDT using systemically administered porfimer sodium showed an initial (6-month) complete response rate of 92%, with a recurrence rate of less than 10% at 4 years.¹⁷³ At this same institution, a 92% complete response rate was achieved with PDT with topical ALA in 330 patients with superficial BCC, but the response rate dropped to 71% in 75 patients with nodular BCC.¹⁷³ In a multicenter randomized trial of PDT with MAL versus cryotherapy for superficial BCC, complete response rates at 3 months were 97% and 95%, respectively, with 5-year recurrence rates of 22% and 20% for PDT with MAL and cryotherapy, respectively.¹⁷⁴ In this study, the excellent-to-good cosmetic outcome was 89% for PDT with MAL and 50% for cryotherapy. However, when topical PDT is compared with surgery for BCC, topical PDT with ALA or MAL consistently shows an increase in the recurrence rate compared with surgery for both superficial and nodular BCC. A randomized controlled trial of PDT with MAL versus surgical excision in 196 patients with superficial BCC showed a 9.3% recurrence rate for PDT versus a 0% recurrence rate for surgery at 12 months.¹⁷⁵ However, the good-to-excellent cosmetic outcome was 94% and 60% for patients treated with PDT and surgical excision, respectively. Similarly, in trials of PDT versus surgery for nodular BCC, recurrence rates are less than 5% for surgery versus 14% to 30% for PDT with ALA.¹⁷⁶⁻¹⁷⁹ As with superficial BCC, cosmetic effects are consistently shown to be more favorable

with PDT with ALA. In summary, PDT can be an appropriate and effective treatment alternative to cryosurgery or surgical excision for selected patients with BCC.

Head and Neck Tumors

PDT has been successfully employed to treat early carcinomas of the oral cavity, pharynx, and larynx, preserving normal tissue and vital functions of speech and swallowing.¹⁸⁰ Multiple institutions have published small series of results demonstrating the efficacy of PDT for head and neck cancer.¹⁸¹ Only one small clinical trial was randomized and compared PDT with porfimer sodium with chemotherapy (5-FU and cisplatin) in the treatment of nasopharyngeal carcinoma.¹⁸² Although no details on randomization procedures or blinding were provided, the clinical response was better with PDT ($P=.001$), and there was improvement in the Karnofsky performance score. Biel reported the largest series of over 300 patients accrued over a 15-year clinical time period and treated with porfimer sodium-mediated PDT.¹⁸³ Among the treated lesions, there were predominantly SCCs of the oral cavity, pharynx, or larynx, but also Kaposi sarcoma, melanoma, and SCC in the head and neck area. The treatment protocol most commonly involved the administration of 2.0 mg/kg of porfimer sodium 48 hours prior to irradiation with 630 nm of light from an neodymium yttrium aluminum garnet (Nd:YAG) pumped dye laser. The light fluences delivered ranged between 50 and 75 joules per square centimeter (J/cm^2) for oral cavity, nasopharyngeal, and skin lesions and 80 J/cm^2 for laryngeal tumors.¹⁸⁴

Among the reported group, 133 patients presented with recurrent or primary CIS, T1N0, and T2N0 laryngeal carcinomas and were treated with PDT with curative intent. After a single PDT procedure, the patients were followed on average for 96 months and at 5 years demonstrated a 90% cure rate. The second group of patients who underwent PDT consisted of 138 patients with CIS and T1N0 SCCs of the oral cavity. Similarly, one PDT treatment was delivered and the patients were followed for up to 211 months. All patients were reported to achieve complete pathological and clinical responses and the cure rate at 5 years remained at 100%. PDT was also used for patients with more advanced stages of oral cavity lesions. Fifty-two patients with T2N0 as well

as T3N0 SCC also received a single PDT treatment that led to complete pathological and clinical response, affording a 100% cure rate at 3 years.

Overall, over 500 patients with early stage oral cavity, larynx, pharynx, and nasopharynx lesions were treated with porfimer sodium-based PDT worldwide with similar success.¹⁸⁴⁻¹⁸⁷ The small number of patients experiencing recurrences were usually salvaged with either repeated PDT or surgical resection. Complications observed in these series were limited to cutaneous photosensitivity, and local pain after therapy was usually controlled by oral analgesics.

The intense development of a second generation of PSs has led to their entering clinical application in head and neck lesions as well. Several series have reported on the use of the second-generation PSs such as ALA and temeporfin.^{188,189} The large multicenter phase 2 trials evaluated the application of temeporfin-mediated PDT in the treatment of primary oropharyngeal cancers. The study by Hopper et al¹⁸⁸ of patients with early oral cancer, in whom the tumors measured up to 2.5 cm in diameter, reported a complete response rate of 85% (97 of 114 patients) at 12 weeks and a disease-free survival rate of 75% at 2 years. In another study by Copper et al,¹⁹⁰ PDT was used in the treatment of a total of 27 patients with 42 second or multiple primary head and neck tumors. Cure rates for stage I or in situ disease were 85% versus 38% for stage II/III disease.

Perhaps the most interesting study reported the application of temeporfin-mediated PDT for advanced disease. A total of 128 patients with advanced head and neck cancer were treated with a single PDT session.¹⁹¹ The patients included in this study had failed conventional therapy or were unsuitable for such treatment. PDT delivered 96 hours after temeporfin administration allowed for 100% tumor mass reduction in 43% of lesions and the remaining lesions were reduced by at least 50%. In this trial, tumor mass reduction was measured for each lesion by multiplying the lesion's length by its width. The 100% tumor mass reduction represented a complete local tumor clearance. Greater than one-half of the treated patients also achieved substantial quality-of-life benefit. Overall, the complete response rates as determined for every patient according to the World Health Organization criteria were 13%, but interestingly, this figure rose to 30%

when the total surface area of the tumor could be illuminated and the depth estimate was less than 1 cm. A relatively limited study that has been conducted with ALA for head and neck lesions reported results that were slightly inferior to those observed with porfimer sodium and temeporfin.^{189,192,193}

Taken together, the data from phase 1/2 trials strongly suggest that PDT could be an effective primary and alternative treatment modality for patients presenting with early head and neck tumors and that further research in this area, including randomized trials, is needed.

Digestive System Tumors

The application of PDT in the gastrointestinal (GI) tract has been divided into 2 groups: PDT of the esophagus and beyond. Barrett esophagus and various grades of dysplasia and early esophageal cancer are the best-studied PDT applications in the GI tract.^{194,195} Premalignant conditions such as Barrett esophagus with high-grade dysplasia are theoretically ideal for PDT.¹⁹⁶ These are superficial and large mucosal areas that are easily accessible for light. Barrett esophagus is the development of an intestinal-type metaplasia in the esophagus and is associated with gastroesophageal reflux disease. Dysplasia may arise in the setting of Barrett esophagus and can lead to the development of adenocarcinoma. Although historically the standard treatment was distal esophagectomy, this treatment is associated with significant morbidity and a 3% to 5% mortality rate. Therefore, endoscopic ablative therapies have become attractive alternatives for patients with Barrett esophagus, including argon plasma coagulation and PDT.

Seven randomized clinical trials have been reported to evaluate PDT in patients with Barrett esophagus with high-grade dysplasia or superficial carcinoma. Most were relatively small, included fewer than 50 patients, and did not clearly report on study methods. Therefore, it is premature to state whether PDT is superior, equivalent, or inferior to other ablative treatments. The most frequent adverse effects included prolonged skin photosensitivity and esophageal strictures, especially when using porfimer sodium. However, the frequency of the latter does not appear to be higher compared with argon plasma coagulation. There is insufficient information on the clinical factors that might be useful in predicting the likelihood of strictures after PDT.

A total of 102 patients with Barrett esophagus and high-grade dysplasia (69 patients) or mucosal adenocarcinoma (33 patients) were treated with PDT using porfimer sodium as an alternative to esophagectomy (median series follow-up time of 1.6 years). After treatment with PDT, there was complete ablation of glandular epithelium with one course of PDT in 56% of patients. Strictures requiring dilation occurred in 20 patients (20%) and were the most common serious adverse events. PDT failed to ablate dysplasia or carcinoma in 4 patients, and subsequent esophagectomy was curative in 3 of these patients. The authors concluded that PDT is a highly effective, safe, and minimally invasive first-line treatment for patients with Barrett dysplasia and mucosal adenocarcinoma.¹⁹⁷ Corti et al followed 62 patients with esophageal cancer who were treated with HPD-mediated PDT.¹⁹⁸ Eighteen of these patients had CIS (Tis), 30 had T1 tumors, 7 had T2 tumors, and 7 had recurrence of tumors at the anastomotic site from prior surgery. Radiation was delivered to selected patients. The complete response rate after PDT alone was 37% (23 of 62 patients) and was 82% (51 of 62 patients) after PDT and radiation. The complete response rate to PDT alone was the highest in Tis/T1 patients (44%) compared with T2 patients (28%). Patients with recurrence at the anastomotic site did not respond to PDT. The median local progression-free survival was 49 months for patients with Tis/T1 lesions, 30 months for patients with T2 lesions, and 14 months for patients with recurrent tumors. Of those who had a complete response, 48% remained disease free through the follow-up period (range, 3 months–90 months). Three cases (5%) of esophageal stricture and 1 case (<2%) of tracheoesophageal fistula were reported. Based upon these data, the authors concluded that PDT was effective for early stage esophageal cancer and also demonstrated that radiotherapy could be used in those patients who did not respond completely to PDT. What is also clear from these studies is that in tumors with a greater depth of penetration (T2 or greater), PDT is not an optimal treatment option. A randomized, phase 3 trial of porfimer sodium-mediated PDT for Barrett esophagus and high-grade dysplasia has been performed by the International Photodynamic Group for High-Grade Dysplasia in Barrett's Esophagus.¹⁹⁹ Patients were randomized to treatment with

omeprazole (37 patients) or omeprazole with PDT (128 patients). At 5 years, PDT was significantly more effective than omeprazole alone in eliminating high-grade dysplasia (77% [106 of 138 patients] vs 39% [27 of 70 patients]; $P < .0001$). A secondary endpoint of preventing progression to cancer showed a significant difference ($P = .027$) with approximately one-half the likelihood of cancer occurring in the PDT arm (21 of 138 patients [15%] vs 20 of 70 patients [29%]). There was also a significantly ($P = .004$) longer time to progression to cancer favoring PDT. It is based upon these data that the US FDA approved porfimer sodium-mediated PDT for patients with Barrett esophagus and high-grade dysplasia who do not undergo surgery. It should be noted that a recent Cochrane review concluded that radiofrequency ablation has significantly fewer complications than PDT and is efficacious at eradicating both dysplasia and Barrett esophagus. Long-term follow-up data are still needed before radiofrequency ablation should be used in routine clinical care.²⁰⁰ These phase 2 and 3 trials of PDT for high-grade dysplasia demonstrate that this therapy prevents the development of invasive carcinoma and is a safe and reliable treatment option.²⁰¹⁻²⁰³ Despite this positive assessment, there are certain challenges. Stricture formation, potential skin phototoxicity, severe chest pain, and nausea are quite problematic. It is believed, however, that with improved dosimetry and new PSs those limitations could be overcome.

PDT has been applied to a variety of tumor types in the GI tract beyond the esophagus.²⁰⁴ Early clinical studies from Japan of PDT in the stomach suggested great promise,^{205,206} but regrettably have not been followed by randomized clinical trials to date. PDT for early duodenal and ampullary cancers and advanced adenomas has also been investigated in pilot studies that indicated promising results, but further work is required to optimize the treatment conditions.^{207,208} The most promising results have been achieved in CC. Case reports of PDT for CC began to emerge in the 1990s,²⁰⁹ and in 1998, Ortner et al published an uncontrolled, observational pilot study of 9 patients with inoperable CC treated with porfimer sodium-mediated PDT.²¹⁰ In a follow-up study, 70 patients were treated, including 20 who were randomized to PDT followed by bilateral plastic stenting.²¹¹ The median survival in the PDT plus stenting group was a remarkable 493 days

compared with only 98 days in the group treated with stenting alone. Patients' quality of life also improved significantly. Other studies have shown similar results.²¹²⁻²¹⁴ Although only 2 clinical trials for CC^{211,213} were randomized, both reached a similar conclusion, namely that PDT has a therapeutic effect on nonresectable CC. The most common complication was cholangitis, which developed in every fourth patient undergoing PDT plus stenting, which was higher than the rates observed in control patients treated with stenting alone. Other rare adverse effects reported include cholecystitis, abscess formation, pancreatitis, biliary leakage, and biloma. Consequently, a multicenter clinical trial has been recently initiated to obtain regulatory approval in the United States and Canada.²⁰⁴

Among other applications for PDT in the GI tract, there are studies of PDT for unresectable pancreatic cancers²¹⁵ and numerous reports that have examined using PDT to eradicate colon polyps as well as to palliate bulky colon and rectal cancers.²¹⁶⁻²¹⁹ The use of PDT in these tumors is still considered experimental because there are not high-level data to support the routine use of PDT for these indications at this time. In addition, PDT may have efficacy in treating hepatocellular carcinoma, which remains one of the most common forms of cancer worldwide. Early results from clinical trials have been quite promising, and a phase 3 study is currently underway to evaluate the efficacy of talaporfin-mediated PDT using interstitial LEDs compared with institution-specific standard treatment.²²⁰

PDT for Intraperitoneal Malignancies

As with pleurally disseminated malignancies, the treatment of patients with peritoneal carcinomatosis or sarcomatosis is typically palliative in nature. PDT has the potential to combine the selective destruction of cancerous tissue compared with normal tissue with the ability to treat and conform to relatively large surface areas. Moreover, the intrinsic physical limitation in the depth of visible light penetration through tissue limits PDT damage to deeper structures, thereby providing additional potential for tumor cell selectivity. This is especially true after surgical debulking (cytoreduction), where the residual tumor is microscopic or less than 5 mm in depth.

A phase 1 trial of intraoperative PDT after maximal surgical debulking that was performed with 70 patients, mostly with recurrent ovarian cancer carcinomatosis or peritoneal sarcomatosis, resulted in a 76% complete cytologic response rate with tolerable toxicity.²²¹ In the follow-up phase 2 study, patients were enrolled, stratified according to cancer type (ovarian, GI, or sarcoma), and given doses of porfimer sodium and light at the maximally tolerated dose that was defined in the phase 1 trial.^{154,222} As in the phase 1 trial, intraperitoneal PDT was associated with a postoperative capillary leak syndrome that necessitated fluid resuscitation in the immediate postoperative period that was in excess of the typical fluid needs of patients who receive surgery alone.²²³ Other than the capillary leak syndrome²²³ and the skin photosensitivity, the complication rates were similar to the complication rates typically observed after similarly extensive surgery in the absence of PDT. With a 51-month median follow-up, the median failure-free survival and overall survivals for the patients who received PDT were 3 months and 22 months, respectively, in ovarian cancer patients; 3.3 months and 13.2 months, respectively, in GI cancer patients; and 4 months and 21.9 months, respectively, in sarcoma patients. Six months after therapy, the pathologic complete response rate was 9.1% (3 of 33 patients), 5.4% (2 of 37 patients), and 13.3% (4 of 30 patients) for the patients with ovarian cancer, GI cancer, and sarcoma, respectively. The median survival of almost 2 years in the patients with ovarian cancer and over 1 year in the patients with GI cancer suggested some benefit from this treatment compared with historical controls. In the patients with sarcoma, the prolonged overall survival was primarily due to patients with sarcomatosis from GI stromal tumors who were treated with imatinib when it became available. Given the narrow therapeutic index of PDT in the treatment of peritoneal carcinomatosis, this therapy has the potential to benefit patients but requires further study.

Urinary System Tumors

Prostate Cancer

Patients with prostate cancer who elect to undergo definitive radiotherapy have limited options for salvage therapy for isolated local failure. Moreover, first-line, definitive management of early stage

prostate cancer with either surgery or ionizing radiotherapy has significant associated morbidities due to the proximity of normal structures such as nerves, bladder, and rectum. The intrinsic limitation in the range of PDT-mediated damage imposed by visible light has the potential to selectively treat the prostate while sparing the surrounding normal tissues. By adapting the techniques developed for interstitial brachytherapy with radioactive seeds, light can be delivered to the entire prostate gland using interstitial, cylindrically diffusing optical fibers. Unlike chemotherapy or radiotherapy, the mechanism of cell killing by PDT is not dependent on DNA damage or cell cycle effects, decreasing the chances of therapy cross-resistance and eliminating late normal tissue effects such as second malignancy. All of these factors combine to make prostate cancer an attractive target for clinical trial development.

Several groups have published clinical trial results for prostate PDT using second-generation PSs. In a pilot study of temoporfin-mediated PDT, 14 patients who experienced biopsy confirmed local failure after definitive radiotherapy for early stage prostate cancer were treated using up to 8 implanted, interstitial, cylindrically diffusing optical fibers.²²⁴ Of these patients, 13 were considered to have received a high light dose (≥ 50 J/cm²). Response of prostate-specific antigen to therapy was observed in 9 patients and a complete pathologic response was observed in 5 patients. One patient developed a urorectal fistula after a rectal biopsy was performed 1 month after PDT. Four patients developed stress incontinence and 4 patients developed decreased erectile function. In a follow-up report of definitive temoporfin-mediated PDT as first-line therapy, 6 patients with organ-confined, Gleason score 6 prostate cancer were treated with 4 to 8 interstitial fibers with implants designed to cover only the areas of the prostate with biopsy proven disease.²²⁵ Four of these patients had a second PDT session due to biopsy confirmed persistent disease at 3 months of follow-up. Although the treatment was relatively well tolerated, and all patients showed evidence of necrosis on postprocedure imaging or biopsy, all 6 patients had biopsy confirmed residual disease after PDT.

Another group has studied motexafin lutetium (MLu) as a PS for PDT of the prostate.^{226,227} In the phase 1 trial, 17 patients with biopsy confirmed,

locally recurrent prostate cancer after definitive radiotherapy were treated with increasing doses of 732 nm (red) light using interstitial fibers. The primary goal of this trial was to determine the maximally tolerated dose and dose-limiting toxicities of MLu-mediated prostate PDT, and one important secondary goal was to begin to develop the capability to perform real-time measurements of tissue optical properties, tissue levels of oxygen, and PS to eventually allow real-time light fluence modulation that would provide a more homogeneous dose of PDT to the entire prostate gland. As in the temeporfin study, one patient developed a urorectal fistula that was attributed to inhomogeneity of the light dose. The remainder of toxicities observed in these patients were mild to moderate and consisted of urinary toxicities, including stress incontinence. Although not designed to measure efficacy, a significant difference was found in time to biochemical failure (prostate-specific antigen recurrence) between the low and high PDT dose cohorts, providing some evidence of biochemical and pathologic disease response to PDT.

Another group has investigated vascular-targeted PDT using palladium (Pd)-bacteriopheophorbide (padoporfin)-mediated PDT and a short drug-light interval. In the phase 1 trial, 24 patients with biopsy confirmed local failure after definitive radiotherapy for prostate adenocarcinoma were treated with padoporfin-mediated PDT using 2 interstitial fibers.^{228,229} This study demonstrated that vascular-targeted PDT could be safely performed in this patient population. In the follow-up phase 2 study, 28 patients were treated with increasing light doses.²³⁰ After 6 months of follow-up, less residual cancer was noted on biopsy as the light dose increased. All had negative biopsies at follow-up if greater than 60% of the prostate was determined to be avascular by post-PDT magnetic resonance imaging (MRI). Toxicities were significant, with 2 patients developing urethrorectal fistulas. This study demonstrated the potential for pathologic complete response over a short-term follow-up. Together, these studies suggest that although PDT to the prostate is feasible, comprehensive treatment of the entire gland will be necessary, and improved techniques and dosimetry will be critical in providing an acceptable toxicity profile.

Bladder Cancer

Bladder cancers, which are often superficial and multifocal, can be assessed and debulked endoscopically. In addition, the geometry of the bladder should allow for improved and homogeneous delivery of light. These factors make superficial bladder cancer an attractive target for PDT. In general, early response rates (2 months–3 months) to PDT have been observed in approximately 50% to 80% of patients, with longer term (1 year–2 years) durable responses noted in 20% to 60% of patients. It should be noted that many of the patients treated in these studies had recurrent disease that developed after standard therapies such as bacillus Calmette-Guérin (BCG).

Early studies used HPD-mediated PDT. In one study, focal HPD-mediated PDT was used to treat 50 superficial bladder transitional cell carcinomas (TCCs) in 37 patients and achieved a 74% complete response rate.²³¹ Another study used HPD-mediated PDT to treat the entire bladder wall for 34 patients with refractory CIS of the bladder and achieved a 73.5% complete response rate at 3 months.²³² However, by 2 years, 77.8% of these patients experienced disease recurrence. In these studies, treatment of superficial bladder cancer with PDT is generally well tolerated, with dysuria, hematuria, and skin photosensitivity being the most common acute toxicities. However, bladder wall fibrosis/diminished bladder capacity has been and continues to be a problem in some treated patients. With improved dosimetry and the use of porfimer sodium as a PS, other investigators have achieved durable complete response rates as high as 60% for patients with refractory bladder CIS or superficial TCC.^{233,234} Studies of locally applied (intravesical) ALA demonstrate that similar durable complete response rates of 52% to 60% at 2 years to 3 years can be achieved for patients with treatment-refractory bladder CIS without the prolonged skin photosensitivity experienced when using systemic porfimer sodium.^{235,236}

Although most of the patients treated with bladder PDT are refractory to BCG, one randomized controlled study has compared a single porfimer sodium-mediated PDT with multiple BCG treatments (induction plus maintenance) and found that these therapies are equivalent in durable treatment response.²³⁷ Studies combining intravesical

immunotherapies such as BCG or chemotherapies such as mitomycin C with PDT showed that these therapies may significantly enhance the PDT responsiveness of bladder tumors.^{238,239} Despite these promising results, PDT for bladder cancer remains largely investigational with limited use. PDT for bladder cancer is approved in Canada and in some EU nations but has not been approved by the US FDA.

Non-Small Cell Lung Cancer and Mesothelioma

PDT for non-small cell lung cancer (NSCLC) was first used in 1982 by Hayata et al to achieve tumor necrosis and reopening of the airway.²⁴⁰ PDT for lung cancer is particularly useful for 1) patients with advanced disease in whom PDT is used as a palliation strategy²⁴¹⁻²⁴³ and 2) patients with early central lung cancer when patients are unable to undergo surgery.^{244,245} PDT is considered to be more specific and lesion-oriented compared with other available modalities and produces less collateral damage, and therefore fewer complications. Indeed, a randomized trial of PDT versus Nd:YAG laser therapy for obstructing NSCLC lesions showed equal initial efficacy for these 2 treatments, with a longer duration of response noted for PDT.²⁴³ PDT plus palliative radiation also appears to increase the time to bronchus reocclusion when combined compared with radiation alone.^{109,246}

In patients with early stage lung cancer, PDT has been used to successfully treat patients for whom surgery is not feasible. In one phase 2 study, 54 patients with 64 lung carcinoma lesions underwent porfimer sodium-mediated PDT and showed an 85% complete response rate with a 6.5% local failure rate at 20.2 months.²⁴⁵ Other studies have supported these excellent results, with complete response rates averaging 73% in studies totaling 359 patients.²⁴⁶⁻²⁴⁸ For radiographically occult lung cancers, results are equally good, with one typical study showing a complete response rate of 94% with 80% local control at 5 years.²⁴⁹ Second-generation PSs have also been used in early stage lung cancer treatment. Recently, Usuda et al²⁵⁰ reported a series of 70 cancer lesions measuring 1.0 cm or less in diameter and 21 lesions measuring greater than 1.0 cm in diameter treated with PDT with talaporfin. The complete response rates were 94.3% (66 of 70 patients) and 90.4% (19

of 21 patients), respectively. PDT with talaporfin was capable of destroying the residual cancer lesions observed after the mass of large tumors had been reduced by electrocautery. Another report²⁵¹ described the results of 529 PDT procedures performed on 133 patients who presented with NSCLC (89 patients), metastatic airway lesions (31 patients), small cell lung cancer (4 patients), benign tumors (7 patients), and other (unspecified) lung conditions (2 patients). The lesions were most commonly located in the main stem bronchi (71 patients). Most patients received 2 treatments during a 3-day hospitalization and returned in 2 weeks for 2 additional PDTs. The authors concluded that PDT can be safely and effectively used in the described setting, leading to improved dyspnea in selected patients. The small number of randomized clinical trials in patients with NSCLC and insufficient reporting on study methods and treatment outcomes do not enable us to draw firm conclusions regarding PDT efficacy and safety. PDT remains a very promising therapeutic approach in the treatment of NSCLC.

NSCLC with pleural spread is incurable with standard treatment modalities such as surgery, chemotherapy, or ionizing radiotherapy, and median survival rates in these patients typically range from 6 to 9 months. Surgery alone has been unsuccessful in obtaining local control and does not extend survival beyond palliative chemotherapy, which remains the standard of care for the treatment of this disease. Based on promising phase 1 study results, a pilot phase 2 trial of porfimer sodium-mediated PDT was performed to investigate the efficacy of combined surgery and PDT for patients with either recurrent or primary NSCLC with pleural spread, the majority of whom had N2 lymph node involvement and bulky pleural disease.^{101,252} In this study, local control of pleural disease at 6 months was achieved in 11 of 15 evaluable patients (73%) and the median overall survival for all 22 patients was 21.7 months. These results are highly encouraging in this population of patients and suggest that additional investigation in this area is warranted.

Malignant pleural mesothelioma (MPM) is a cancer of the pleura that, similar to NSCLC with pleural spread, has no currently available curative options. In a phase 2 study of porfimer sodium-mediated PDT after extrapleural pneumonectomy for MPM, patients with stage I and II disease

experienced a median survival of 36 months with a 2-year survival rate of 61%, whereas patients with stage III and IV disease experienced a median survival time of 10 months.²⁵³ Both of these rates were significantly improved compared with historical series of surgery alone. However, in a single randomized phase 3 study of surgery versus surgery with PDT, patients received treatment similar to that described above but did not appear to benefit from the addition of PDT to surgery.²⁵⁴ This trial was potentially underpowered and also involved surgical debulking that could leave disease of up to 5 mm in thickness as opposed to a macroscopically complete resection. Trials of intraoperative PDT using temeporfin showed that temeporfin PDT is feasible and has potentially acceptable toxicity.^{255,256} One important finding in these studies of resection with PDT for MPM is that a lung-sparing, tumor debulking surgery can be combined with PDT to achieve local control rates similar to those observed with extrapleural pneumonectomy. Indeed, a more recent study of macroscopically complete, lung-sparing surgical debulking followed by intraoperative porfimer sodium-mediated PDT for patients with locally advanced MPM found a median survival that had not been reached with a 2.1-year median follow-up in patients after radical pleurectomy with PDT.²⁵⁷ Thus, PDT for MPM needs to be further evaluated in clinical trials of lung-sparing surgery.

Brain Tumors

PDT is currently undergoing intensive clinical investigation as an adjunctive treatment for brain tumors.²⁵⁸ The major tumor lesions particularly suitable for PDT treatment are newly diagnosed and recurrent brain tumors due to their high uptake of PSs. Since the early 1980s, close to 1000 patients worldwide have received PDT for brain lesions. Peria et al²⁵⁹ reported one of the earliest attempts to use PDT to treat the postresection glioma cavity in humans, and Kaye et al²⁶⁰ reported a phase 1/2 trial involving 23 patients with glioblastoma multiforme (GBM) and anaplastic astrocytoma (AA). Other brain lesions treated with PDT included malignant ependymomas,^{261,262} malignant meningiomas,²⁶³ melanoma and lung cancer brain metastasis,^{260,263} and recurrent pituitary adenomas.²⁶⁴ The initial trials provided encouraging results, and the authors concluded that PDT can be used as an adjuvant

therapy in patients with brain tumors. The PSs used to date were various formulations of HPDs (porfimer sodium) and ALA as well as temeporfin. The light sources used to activate those PSs included lamps, dye lasers, gold vapor potassium titanyl phosphate dye lasers, and diode lasers.

Currently, PSs are being evaluated both as intraoperative diagnostic tools by means of photodetection (PD) and fluorescence-guided resection (FGR) (Table 1) as well as during PDT as an adjunctive therapeutic modality.^{263,265-267} All 3 approaches take advantage of the higher uptake of PS by the malignant cells and are used intraoperatively. The most recently published trials that employed PD, FGR, and PDT provided additional encouraging results, but the initial delay in tumor progression did not translate to extended overall survival.²⁶⁸⁻²⁷¹

Stylli et al reported the results of a total of 375 patients treated at the Royal Melbourne Hospital.²⁶⁸ Among the 375 patients, the majority consisted of those with newly diagnosed (138 patients) and recurrent (140 patients) GBMs. Additional histological types included newly diagnosed (41 patients) and recurrent (46 patients) AAs. Patients received 5 mg/kg of HPD 24 hours prior to surgery and the light dose was 70 to 260 J/cm². In the follow-up, the mean survival for both types of GBM was between 14.3 and 14.9 months, and approximately 28% to 41% of patients survived more than 2 years. For AA, the mean survival was between 66.6 and 76.5 months and 57% to 73% of patients survived more than 3 years.

Muller and Wilson reported the results of a prospective randomized controlled trial using adjuvant porfimer sodium-mediated PDT in the study group.²⁷⁰ The 96 patients treated for supratentorial gliomas with PDT with porfimer sodium at St. Michael's Hospital in Toronto, Ontario, Canada were randomized to 2 groups that received either 40 J/cm² or 120 J/cm². The patients who received the higher dose (48 patients) survived on average for 10 months, whereas the 49 patients in the low-dose group survived on average 9 months; the difference between both groups was not statistically significant ($P = .05$).

Stummer et al reported the results of the ALA study group, a multicenter prospective randomized controlled trial in Germany.²⁶⁹ This trial compared the effectiveness of ALA-based FGR with

conventional surgery. The 322 patients with suspected malignant gliomas were followed for 35.4 months. Patients randomized to the FGR group demonstrated much better time to progression (5.1 months) compared with the controls (3.6 months), which translated into a greater survival of 16.7 months versus 11.8 months, respectively. However, the difference in overall survival was not statistically significant.

Eljamel et al reported a single-center, prospective randomized controlled study that employed the techniques of ALA-based FGR, protoporphyrin IX spectroscopy, and fractionated porfimer sodium-mediated PDT in patients with GBM.²⁷¹ The PDT was delivered up to 500 J/cm² in 5 fractions. Among the 27 recruited patients, 13 received FGR and PDT and demonstrated a mean survival of 52.8 weeks compared with 24.6 weeks in the control group. The mean time to tumor progression was 8.6 months in the FGR and PDT group compared with 4.8 months in the control group.

The current standard therapies that include surgery, radiotherapy, and chemotherapy afford a median survival of approximately 15 months and although there are limited data comparing PD, FGR, and photodiagnosis with those standard therapies, the initial results from randomized trials are encouraging. It remains to be seen whether PDT for brain tumors remains a palliative or, at most, an alternative treatment modality. The new classes of PSs, the better understanding of dosimetry, and further improvement in technology may significantly change the currently achieved clinical outcome. In addition, preclinical data indicating that protracted light delivery may increase the therapeutic index of PDT in the brain combined with newer technologies such as implantable LED-based light delivery systems could lead to significant improvements in treatment outcomes.²⁵⁸

Barriers for Adoption of PDT Into Routine Clinical Practice

Despite being first described in the early 1900s,²⁷² the use of PDT to treat cancer patients has been relatively slow to enter mainstream clinical practice. Even when used clinically, PDT for cancer remains in many cases an alternative or palliative treatment or is used within the context of a clinical trial. For the PDT novice, the array of associated technologies such as lasers, applicators/fiber optics, and power

meters along with the need to perform manual calculations for dosimetry can be daunting. When performed with the assistance of a radiation oncologist or medical physicist with some training in optical methods and dosimetry, this difficulty can be overcome more easily. Another potential problem is the scarcity of phase 3 clinical trials that could demonstrate the superiority of PDT over other modalities.¹⁵¹ Although more randomized trials of PDT are needed, other technologies and therapies with a similar deficiency in phase 3 data have been much more readily adopted by clinicians. Finally, the first-generation PSs exhibited a prolonged skin sensitivity to visible light, and this likely limited the use of these drugs in the palliative setting, especially for patients with a life expectancy of fewer than 6 to 12 months. However, better understanding of dosimetry, LED and diode-based laser technologies with simplified user interfaces, and new PSs with a decreased duration of skin photosensitivity, combined with mechanistic studies that may allow patient- or tumor-specific selection of therapy, suggest that PDT has the potential to finally make the transition to obtain widespread clinical use in the oncologic community.

Novel Strategies in PDT

Two-Photon PDT

The standard method in PDT is to use an organic PS, activated by continuous light, administered as an acute, high-dose single treatment. There are several fundamentally different approaches that are currently under preclinical investigation, involving different photophysics, chemistry, and/or photobiological mechanisms. In 2-photon PDT, short (approximately 100 femtosecond) laser pulses with very high peak power are used, so that 2 light photons are absorbed simultaneously by the PS. Because each photon only contributes one-half of the excitation energy, near-infrared light can be used to achieve deeper tissue penetration. The subsequent photochemistry and photobiological effects are the same as in 1-photon PDT. Starkey et al reported 2-cm effective treatment depth in tumor xenografts; this is considerably greater than what would typically be achieved by 1-photon activation.²⁷³ Alternatively, if the laser beam is strongly focused, then the

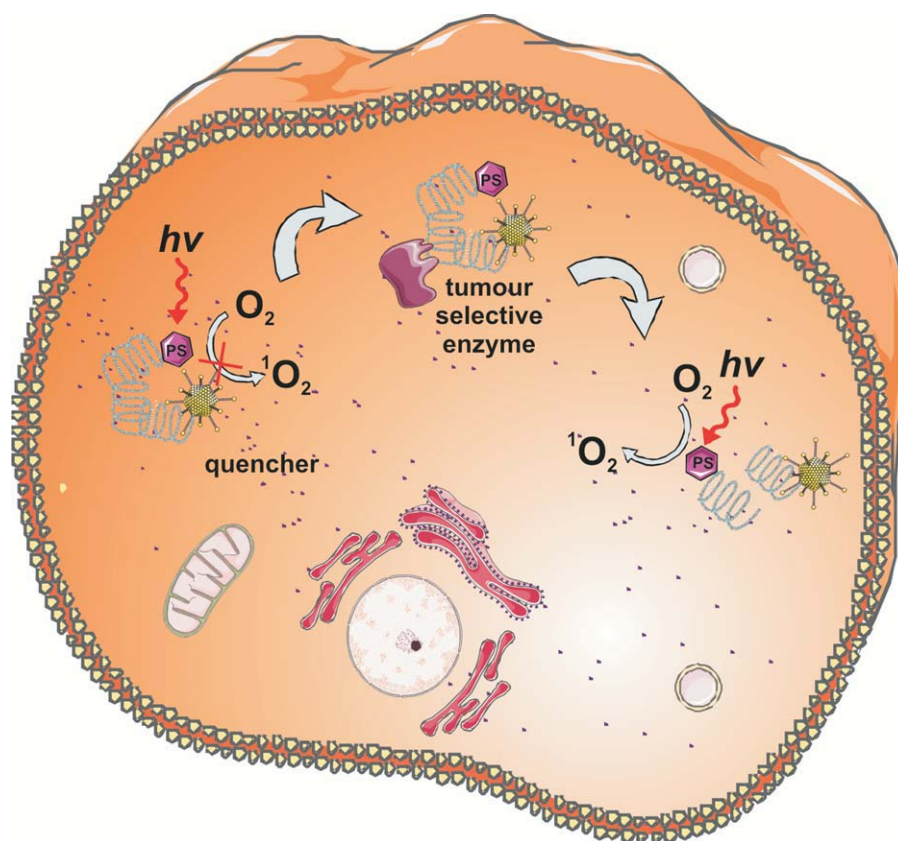


FIGURE 6. Photodynamic Therapy Molecular Beacons. A peptide linker that is a substrate of a cancer-associated enzyme (eg, a protease) is conjugated to a photosensitizer (PS) and a singlet oxygen ($^1\text{O}_2$) quencher. The proximity of the PS and quencher ensures inhibition of $^1\text{O}_2$ generation during irradiation of normal cells. In the presence of an enzyme, the substrate sequence is cleaved and the PS and quencher are separated, thereby enabling photoactivation of the PS. $h\nu$ indicates light; O_2 , molecular oxygen.

activation volume may be extremely small. This may be exploited to target individual blood vessels,²⁷⁴ reducing damage to adjacent tissues. Both approaches have used novel PSs designed to have very high 2-photon cross-sections.^{273,274} Potentially, either strategy could overcome light attenuation limitations, particularly in pigmented tumors such as melanoma.

Metronomic PDT

In metronomic PDT (mPDT) both the drug and light are delivered at very low dose rates over an extended period (hours–days). This can result in tumor cell-specific apoptosis, with minimal tissue necrosis.²⁷⁵ To date, the main focus has been in glioma to minimize direct photodynamic damage to adjacent normal brain and secondary damage from the inflammatory response to PDT-induced tumor necrosis. Dose-dependent tumor responses have been demonstrated in vitro²⁷⁶ and in an intracranial model using ALA and an implanted optical fiber source.²⁷⁷

It is not known if this concept applies to other PSs or organ sites. There is evidence that the molecular pathways in mPDT may be different from those of acute, high-dose PDT.²⁷⁸

PDT Molecular Beacons

The concept of PDT molecular beacons (MBs) derives from the use of MBs as fluorescent probes with high target specificity. The PS is linked to a quenching molecule, so that it is inactive until the linker is cleaved by a target-specific enzyme (Fig. 6). Alternatively, the linker may be an antisense oligonucleotide (hairpin) loop, which is opened by hybridization to complementary mRNA.

PDT MBs were first demonstrated using a caspase-3 linker between pyropheophorbide and a carotenoid quencher, achieving 8-fold and 4-fold quenching and unquenching, respectively, as demonstrated by the $^1\text{O}_2$ yield.²⁷⁹ Subsequently, matrix metalloproteinase (MMP)-based beacons were reported in vitro and in vivo, with high selectivity between MMP-positive and MMP-negative tumors.²⁸⁰ Hairpin-type beacons targeted to *raf-1* mRNA had even higher tumor-to-nontumor specificity and almost complete restoration of the PDT efficacy upon hybridization in human breast cancer cells in vitro.²⁸¹ The most important characteristic of MBs is that tumor selectivity no longer depends solely on the PS delivery, but also on the tumor specificity of the unquenching interaction and the selectivity of the beacon to this interaction. Recently, asymmetric hairpin beacons were described to balance high quenching efficiency with 2-step activation (cleavage and dissociation) to enhance tumor cell uptake.²⁸²

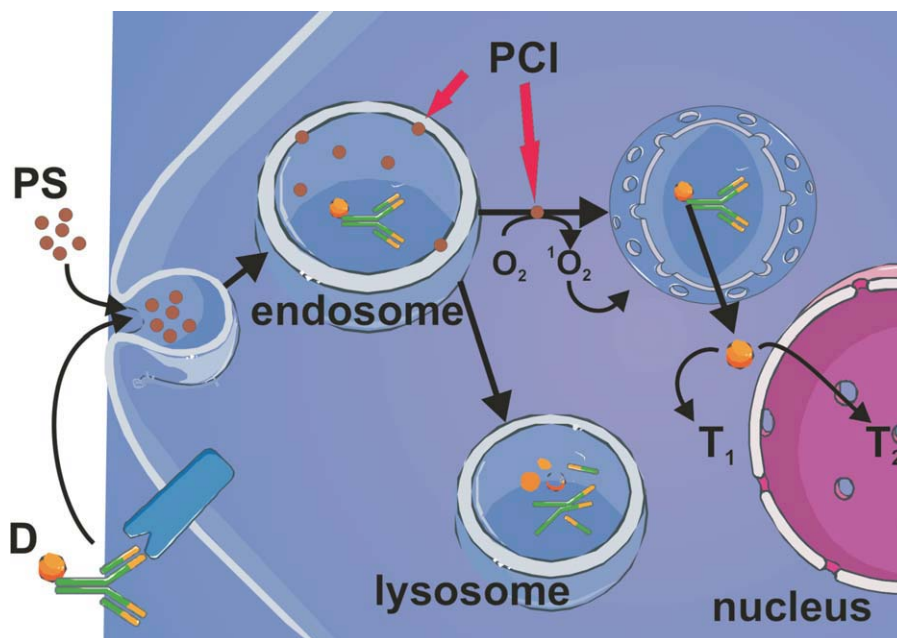


FIGURE 7. The Principles of Photochemical Internalization (PCI) Technology. The photosensitizer (PS) and the therapeutic compound (D) in this example linked to a monoclonal antibody as a targeting moiety are delivered to the target cells. The PS and D are both unable to penetrate the plasma membrane and both are thus endocytosed, initially reaching the endocytic compartments (endosome). The photosensitizers used in PCI are integrated into the membranes of the endocytic vesicles. Upon light exposure, the PS becomes activated and forms singlet oxygen ($^1\text{O}_2$) oxidizing membrane constituents, resulting in rupture of the endocytic membranes, allowing D to reach the cellular compartments where its therapeutic targets are located (T_1 or T_2 [nucleus]). In the absence of light, the therapeutic compound may be degraded in the lysosomes. O_2 indicates molecular oxygen

Nanotechnology in PDT

Nanoparticles (NP) have several potential roles in PDT: for PS delivery, as PSs per se, and as energy transducers.²⁸³ Liposomal NPs are used clinically for delivery of the water-insoluble PS verteporfin.²⁸⁴ The potential advantage of NPs is that a high “payload” can be delivered and they can be “decorated” with multiple targeting moieties such as antibodies or peptides. Other approaches²⁸⁵ include biodegradable polymers and ceramic (silica) and metallic (gold, iron oxide) NPs; magnetic NPs, in which an applied magnetic field enhances localization to the tumor; and hybrid NPs that allow both PDT and either another therapeutic strategy such as hyperthermia or an imaging technique such as MRI. NP delivery of 2-photon PSs has also been reported, because these typically have very poor water solubility.²⁸⁶ Materials that themselves generate $^1\text{O}_2$ upon photoexcitation include silicon NPs and quantum dots. The latter may also be linked to organic PSs, where they absorb the light energy with high efficiency and

transfer it to the PS. Upconverting NPs have been investigated, in which relatively long wavelength light (near infrared) is absorbed and converted to shorter wavelength light that activates the attached PS.²⁸⁵ These concepts illustrate a general advantage of NP-based PDT in that the photophysical and photochemical properties of the PS can be uncoupled from the delivery and activation processes. A final recent approach is the encapsulation of a PS inside polymeric NPs that in turn are incorporated into liposomes containing a second drug such as an antiangiogenic agent (or vice versa).²⁸⁷ This codelivery increases the therapeutic synergy of the 2 modalities.

Photochemical Internalization

A large number of technologies have been developed to enhance translocation of macromolecular therapeutics (Table 1) into the cytosol. These technologies are mainly designed to enhance cellular uptake of macromolecules via endocytosis and stimulate their endosome-to-cytosol translocation. Photochemical internalization (PCI) was specifically designed to enhance the release of endocytosed macromolecules into the cytosol. It is based on the use of PSs located in endocytic vesicles, as shown in Figure 7.³⁰ PDT-generated $^1\text{O}_2$ induces a release of macromolecules from the endocytic vesicles into the cytosol.²⁸⁸ The physicochemical requirements of the PSs utilized in PCI are strong amphiphilicity hindering their penetration through membranes and the presence of a hydrophobic region necessary for sufficiently deep penetration into cell membranes to efficiently produce $^1\text{O}_2$ in a membranous environment.²⁸⁹ The unique properties of the PCI process may be used to activate the therapeutics only in the

light-exposed area while unexposed normal tissues are spared. PCI has been shown to increase the biological activity of several molecules that do not readily penetrate the plasma membrane, including type I ribosome-inactivating proteins (RIPs), immunotoxins, plasmids, adenoviruses, various oligonucleotides, dendrimer-based delivery of chemotherapeutics, and unconjugated chemotherapeutics such as bleomycin and doxorubicin.²⁸⁹ In addition, PCI allows for the use of therapeutics without intrinsic properties for endosome-to-cytosol translocation. An example is the use of the highly toxic RIP diphtheria toxin (DT). In a PCI-based treatment regimen, DT may be replaced with type I RIPs such as gelonin and saporin, which exert low translocation efficiency, thereby reducing the side effects from the toxins.²⁹⁰ The clinical documentation of the therapeutic effects of macromolecular therapeutics for intracellular targets on solid tumors is, however, limited. An ongoing phase 1/2 clinical trial evaluating PCI of bleomycin has been reported to result in encouraging tumor responses. Of 14 patients treated to date (SCC of the head and neck, adenocarcinoma of the breast, chondroblastic osteosarcoma, and skin adnexal tumor), complete clinical regression was observed in all evaluable tumors within a few weeks after treatment, although 2 recurrences were noted at the 3-month follow-up (unpublished data). The treatment has left the healthy tissue underneath the tumor largely unaffected, indicating high specificity for the tumor tissue. These promising properties of PCI technology have the potential to enhance the antitumor efficacy and to exert a high grade of specificity due

to the combination of targeted therapeutics with light-activated cytosolic delivery induced by PSs preferentially accumulating in solid tumors.

Conclusions

PDT is still considered to be a new and promising anti-tumor strategy. Its full potential has yet to be shown, and its range of applications alone or in combination with other approved or experimental therapeutic approaches is definitely not exhausted. The advantages of PDT compared with surgery, chemotherapy, or radiotherapy are reduced long-term morbidity and the fact that PDT does not compromise future treatment options for patients with residual or recurrent disease. Due to a lack of natural mechanisms of $^1\text{O}_2$ elimination and a unique mechanism of cytotoxicity, mutations that confer resistance to radiotherapy or chemotherapy do not compromise antitumor efficacy. Moreover, PDT can be repeated without compromising its efficacy. These are significant limiting factors for chemotherapeutics and radiotherapy. Finally, many conventional antitumor treatments carry a risk of inducing immunosuppression. PDT-induced immunogenic cell death associated with induction of a potent local inflammatory reaction offers the possibility to flourish into a therapeutic procedure with excellent local antitumor activity and the capability of boosting the immune response for effective destruction of metastases. The interdisciplinary uniqueness of PDT inspires specialists in physics, chemistry, biology, and medicine and its further development and novel applications can only be limited by their enormous imagination. ■

References

- Bergh J. Quo vadis with targeted drugs in the 21st century? *J Clin Oncol*. 2009;27:2-5.
- Fojo T, Grady C. How much is life worth: cetuximab, non-small cell lung cancer, and the \$440 billion question. *J Natl Cancer Inst*. 2009;101:1044-1048.
- Hampton T. Targeted cancer therapies lagging: better trial design could boost success rate. *JAMA*. 2006;296:1951-1952.
- Dougherty TJ, Gomer CJ, Henderson BW, et al. Photodynamic therapy. *J Natl Cancer Inst*. 1998;90:889-905.
- Dolmans DE, Fukumura D, Jain RK. Photodynamic therapy for cancer. *Nat Rev Cancer*. 2003;3:380-387.
- Allison RR, Sibata CH. Oncologic photodynamic therapy photosensitizers: a clinical review. *Photodiagnosis Photodyn Ther*. 2010;7:61-75.
- Chen B, Roskams T, de Witte PA. Antivascular tumor eradication by hypericin-mediated photodynamic therapy. *Photochem Photobiol*. 2002;76:509-513.
- Garg AD, Nowis D, Golab J, Vandenabeele P, Krysko DV, Agostinis P. Immunogenic cell death, DAMPs and anticancer therapeutics: an emerging amalgamation. *Biochim Biophys Acta*. 2010;1805:53-71.
- Ascencio M, Collinet P, Farine MO, Mordon S. Protoporphyrin IX fluorescence photobleaching is a useful tool to predict the response of rat ovarian cancer following hexaminolevulinate photodynamic therapy. *Lasers Surg Med*. 2008;40:332-341.
- De Rosa FS, Bentley MV. Photodynamic therapy of skin cancers: sensitizers, clinical studies and future directives. *Pharm Res*. 2000;17:1447-1455.
- Hamblin MR, Newman EL. On the mechanism of the tumour-localising effect in photodynamic therapy. *J Photochem Photobiol B*. 1994;23:3-8.
- Iyer AK, Greish K, Seki T, et al. Polymeric micelles of zinc protoporphyrin for tumor targeted delivery based on EPR effect and singlet oxygen generation. *J Drug Target*. 2007;15:496-506.
- Kessel D. The role of low-density lipoprotein in the biodistribution of photosensi-

- tizing agents. *J Photochem Photobiol B*. 1992;14:261-262.
14. Sibani SA, McCarron PA, Woolfson AD, Donnelly RF. Photosensitizer delivery for photodynamic therapy. Part 2: systemic carrier platforms. *Expert Opin Drug Deliv*. 2008;5:1241-1254.
 15. Juzeniene A, Nielsen KP, Moan J. Biophysical aspects of photodynamic therapy. *J Environ Pathol Toxicol Oncol*. 2006;25:7-28.
 16. Henderson BW, Busch TM, Snyder JW. Fluence rate as a modulator of PDT mechanisms. *Lasers Surg Med*. 2006;38:489-493.
 17. Brancalion L, Moseley H. Laser and non-laser light sources for photodynamic therapy. *Lasers Med Sci*. 2002;17:173-186.
 18. Juzeniene A, Juzenas P, Ma LW, Iani V, Moan J. Effectiveness of different light sources for 5-aminolevulinic acid photodynamic therapy. *Lasers Med Sci*. 2004;19:139-149.
 19. Szeimies RM, Morton CA, Sidoroff A, Braathen LR. Photodynamic therapy for non-melanoma skin cancer. *Acta Derm Venereol*. 2005;85:483-490.
 20. Beyer W. Systems for light application and dosimetry in photodynamic therapy. *J Photochem Photobiol B*. 1996;36:153-156.
 21. Wilson BC, Patterson MS. The physics, biophysics and technology of photodynamic therapy. *Phys Med Biol*. 2008;53:R61-R109.
 22. Plaetzer K, Krammer B, Berlanda J, Berr F, Kiesslich T. Photophysics and photochemistry of photodynamic therapy: fundamental aspects. *Lasers Med Sci*. 2009;24:259-268.
 23. Foote CS. Mechanisms of photosensitized oxidation. There are several different types of photosensitized oxidation which may be important in biological systems. *Science*. 1968;162:963-970.
 24. Dysart JS, Patterson MS. Characterization of Photofrin photobleaching for singlet oxygen dose estimation during photodynamic therapy of MLL cells in vitro. *Phys Med Biol*. 2005;50:2597-2616.
 25. Moan J, Berg K, Kvam E, et al. Intracellular localization of photosensitizers. *Ciba Found Symp*. 1989;146:95-107; discussion 107-111.
 26. Buytaert E, Dewaele M, Agostinis P. Molecular effectors of multiple cell death pathways initiated by photodynamic therapy. *Biochim Biophys Acta*. 2007;1776:86-107.
 27. Kessel D, Castelli M. Evidence that bcl-2 is the target of three photosensitizers that induce a rapid apoptotic response. *Photochem Photobiol*. 2001;74:318-322.
 28. Xue LY, Chiu SM, Oleinick NL. Photochemical destruction of the Bcl-2 oncoprotein during photodynamic therapy with the phthalocyanine photosensitizer Pc 4. *Oncogene*. 2001;20:3420-3427.
 29. Usuda J, Chiu SM, Murphy ES, Lam M, Nieminen AL, Oleinick NL. Domain-dependent photodamage to Bcl-2. A membrane anchorage region is needed to form the target of phthalocyanine photosensitization. *J Biol Chem*. 2003;278:2021-2029.
 30. Berg K, Moan J. Lysosomes as photochemical targets. *Int J Cancer*. 1994;59:814-822.
 31. Reiners JJ Jr, Caruso JA, Mathieu P, Cheladurai B, Yin XM, Kessel D. Release of cytochrome c and activation of procaspase-9 following lysosomal photodamage involves Bid cleavage. *Cell Death Differ*. 2002;9:934-944.
 32. Kessel D. Relocalization of cationic porphyrins during photodynamic therapy. *Photochem Photobiol Sci*. 2002;1:837-840.
 33. Vanlangenakker N, Vanden Berghe T, Krysko DV, Festjens N, Vandenabeele P. Molecular mechanisms and pathophysiology of necrotic cell death. *Curr Mol Med*. 2008;8:207-220.
 34. Zong WX, Thompson CB. Necrotic death as a cell fate. *Genes Dev*. 2006;20:1-15.
 35. Nakagawa T, Shimizu S, Watanabe T, et al. Cyclophilin D-dependent mitochondrial permeability transition regulates some necrotic but not apoptotic cell death. *Nature*. 2005;434:652-658.
 36. Buytaert E, Callewaert G, Vandenheede JR, Agostinis P. Deficiency in apoptotic effectors Bax and Bak reveals an autophagic cell death pathway initiated by photodamage to the endoplasmic reticulum. *Autophagy*. 2006;2:238-240.
 37. Reiners JJ Jr, Agostinis P, Berg K, Oleinick NL, Kessel D. Assessing autophagy in the context of photodynamic therapy. *Autophagy*. 2010;6:7-18.
 38. Dewaele M, Maes H, Agostinis P. ROS-mediated mechanisms of autophagy stimulation and their relevance in cancer therapy. *Autophagy*. 2010;6:838-854.
 39. Sattler UG, Mueller-Klieser W. The antioxidant capacity of tumour glycolysis. *Int J Radiat Biol*. 2009;85:963-971.
 40. Frank J, Flaccus A, Schwarz C, Lambert C, Biesalski HK. Ascorbic acid suppresses cell death in rat DS-sarcoma cancer cells induced by 5-aminolevulinic acid-based photodynamic therapy. *Free Radic Biol Med*. 2006;40:827-836.
 41. Golab J, Nowis D, Skrzycki M, et al. Antitumor effects of photodynamic therapy are potentiated by 2-methoxyestradiol. A superoxide dismutase inhibitor. *J Biol Chem*. 2003;278:407-414.
 42. Hadjur C, Richard MJ, Parat MO, Jardon P, Favier A. Photodynamic effects of hypericin on lipid peroxidation and antioxidant status in melanoma cells. *Photochem Photobiol*. 1996;64:375-381.
 43. Oleinick NL, Morris RL, Belichenko I. The role of apoptosis in response to photodynamic therapy: what, where, why, and how. *Photochem Photobiol Sci*. 2002;1:1-21.
 44. Matroule JY, Bonizzi G, Morliere P, et al. Pyropheophorbide-a methyl ester-mediated photosensitization activates transcription factor NF-kappaB through the interleukin-1 receptor-dependent signaling pathway. *J Biol Chem*. 1999;274:2988-3000.
 45. Wang HP, Hanlon JG, Rainbow AJ, Espiritu M, Singh G. Up-regulation of Hsp27 plays a role in the resistance of human colon carcinoma HT29 cells to photooxidative stress. *Photochem Photobiol*. 2002;76:98-104.
 46. Hanlon JG, Adams K, Rainbow AJ, Gupta RS, Singh G. Induction of Hsp60 by Photofrin-mediated photodynamic therapy. *J Photochem Photobiol B*. 2001;64:55-61.
 47. Nonaka M, Ikeda H, Inokuchi T. Inhibitory effect of heat shock protein 70 on apoptosis induced by photodynamic therapy in vitro. *Photochem Photobiol*. 2004;79:94-98.
 48. Szokalska A, Makowski M, Nowis D, et al. Proteasome inhibition potentiates antitumor effects of photodynamic therapy in mice through induction of endoplasmic reticulum stress and unfolded protein response. *Cancer Res*. 2009;69:4235-4243.
 49. Castellani A, Pace GP, Concioli M. Photodynamic effect of haematoporphyrin on blood microcirculation. *J Pathol Bacteriol*. 1963;86:99-102.
 50. Star WM, Marijnissen HP, van den Berg-Blok AE, Versteeg JA, Franken KA, Reinhold HS. Destruction of rat mammary tumor and normal tissue microcirculation by hematoporphyrin derivative photoradiation observed in vivo in sandwich observation chambers. *Cancer Res*. 1986;46:2532-2540.
 51. Bhuvanewari R, Gan YY, Soo KC, Olivo M. The effect of photodynamic therapy on tumor angiogenesis. *Cell Mol Life Sci*. 2009;66:2275-2283.
 52. Tseng MT, Reed MW, Ackermann DM, Schuschke DA, Wieman TJ, Miller FN. Photodynamic therapy induced ultrastructural alterations in microvasculature of the rat cremaster muscle. *Photochem Photobiol*. 1988;48:675-681.
 53. Henderson BW, Waldow SM, Mang TS, Potter WR, Malone PB, Dougherty TJ. Tumor destruction and kinetics of tumor cell death in two experimental mouse tumors following photodynamic therapy. *Cancer Res*. 1985;45:572-576.
 54. Henderson BW, Fingar VH. Oxygen limitation of direct tumor cell kill during photodynamic treatment of a murine tumor model. *Photochem Photobiol*. 1989;49:299-304.
 55. Gomer CJ, Rucker N, Murphree AL. Differential cell photosensitivity following porphyrin photodynamic therapy. *Cancer Res*. 1988;48:4539-4542.
 56. West CM, West DC, Kumar S, Moore JV. A comparison of the sensitivity to photodynamic treatment of endothelial and tumour cells in different proliferative states. *Int J Radiat Biol*. 1990;58:145-156.
 57. Fingar VH, Wieman TJ, Wiehle SA, Cerreto PB. The role of microvascular damage in photodynamic therapy: the effect of treatment on vessel constriction, permeability, and leukocyte adhesion. *Cancer Res*. 1992;52:4914-4921.
 58. Chen B, Pogue BW, Luna JM, Hardman RL, Hoopes PJ, Hasan T. Tumor vascular permeabilization by vascular-targeting photosensitization: effects, mechanism, and therapeutic implications. *Clin Cancer Res*. 2006;12(3 pt 1):917-923.
 59. Mitra S, Foster TH. In vivo confocal fluorescence imaging of the intratumor distribution of the photosensitizer mono-L-aspartylchlorin-e6. *Neoplasia*. 2008;10:429-438.
 60. Snyder JW, Greco WR, Bellnier DA, Vaughan L, Henderson BW. Photodynamic therapy: a means to enhanced drug delivery to tumors. *Cancer Res*. 2003;63:8126-8131.
 61. Hirschberg H, Uzal FA, Chighvinadze D, Zhang MJ, Peng Q, Madsen SJ. Disruption of the blood-brain barrier following ALA-mediated photodynamic therapy. *Lasers Surg Med*. 2008;40:535-542.
 62. Korbelik M. PDT-associated host response and its role in the therapy outcome. *Lasers Surg Med*. 2006;38:500-508.

63. Krosel G, Korbek M, Dougherty GJ. Induction of immune cell infiltration into murine SCCVII tumour by photofrin-based photodynamic therapy. *Br J Cancer*. 1995; 71:549-555.
64. Korbek M, Cecic I. Contribution of myeloid and lymphoid host cells to the curative outcome of mouse sarcoma treatment by photodynamic therapy. *Cancer Lett*. 1999;137:91-98.
65. de Vree WJ, Essers MC, Koster JF, Sluiter W. Role of interleukin 1 and granulocyte colony-stimulating factor in photofrin-based photodynamic therapy of rat rhabdomyosarcoma tumors. *Cancer Res*. 1997; 57:2555-2558.
66. Kousis PC, Henderson BW, Maier PG, Gollnick SO. Photodynamic therapy enhancement of antitumor immunity is regulated by neutrophils. *Cancer Res*. 2007;67:10501-10510.
67. Korbek M, Cecic I. Mechanism of tumor destruction by photodynamic therapy. In: Nalwa HS, ed. *Handbook of Photochemistry and Photobiology*. Stevenson Ranch, CA: American Scientific Publishers; 2003:39-77.
68. Sun J, Cecic I, Parkins CS, Korbek M. Neutrophils as inflammatory and immune effectors in photodynamic therapy-treated mouse SCCVII tumours. *Photochem Photobiol Sci*. 2002;1:690-695.
69. Gollnick SO, Evans SS, Baumann H, et al. Role of cytokines in photodynamic therapy-induced local and systemic inflammation. *Br J Cancer*. 2003;88:1772-1779.
70. Hunt DW, Levy JG. Immunomodulatory aspects of photodynamic therapy. *Expert Opin Investig Drugs*. 1998;7:57-64.
71. Yusuf N, Katiyar SK, Elmets CA. The immunosuppressive effects of phthalocyanine photodynamic therapy in mice are mediated by CD4+ and CD8+ T cells and can be adoptively transferred to naive recipients. *Photochem Photobiol*. 2008;84: 366-370.
72. Korbek M, Krosel G, Krosel J, Dougherty GJ. The role of host lymphoid populations in the response of mouse EMT6 tumor to photodynamic therapy. *Cancer Res*. 1996; 56:5647-5652.
73. Abdel-Hady ES, Martin-Hirsch P, Duggan-Keen M, et al. Immunological and viral factors associated with the response of vulval intraepithelial neoplasia to photodynamic therapy. *Cancer Res*. 2001;61: 192-196.
74. Maeurer MJ, Gollin SM, Storkus WJ, et al. Tumor escape from immune recognition: loss of HLA-A2 melanoma cell surface expression is associated with a complex rearrangement of the short arm of chromosome 6. *Clin Cancer Res*. 1996;2: 641-652.
75. Dragieva G, Hafner J, Dummer R, et al. Topical photodynamic therapy in the treatment of actinic keratoses and Bowen's disease in transplant recipients. *Transplantation*. 2004;77:115-121.
76. Canti GL, Lattuada D, Nicolin A, Taroni P, Valentini G, Cubeddu R. Immunopharmacology studies on photosensitizers used in photodynamic therapy. *Proc SPIE*. 1994; 2078:268-275.
77. Korbek M, Dougherty GJ. Photodynamic therapy-mediated immune response against subcutaneous mouse tumors. *Cancer Res*. 1999;59:1941-1946.
78. Thong PS, Ong KW, Goh NS, et al. Photodynamic-therapy-activated immune response against distant untreated tumors in recurrent angiosarcoma. *Lancet Oncol*. 2007;8:950-952.
79. Kabingu E, Oseroff AR, Wilding GE, Gollnick SO. Enhanced systemic immune reactivity to a Basal cell carcinoma associated antigen following photodynamic therapy. *Clin Cancer Res*. 2009;15:4460-4466.
80. Kabingu E, Vaughan L, Owczarczak B, Ramsey KD, Gollnick SO. CD8+ T cell-mediated control of distant tumors following local photodynamic therapy is independent of CD4+ T cells and dependent on natural killer cells. *Br J Cancer*. 2007; 96:1839-1848.
81. Henderson BW, Gollnick SO, Snyder JW, et al. Choice of oxygen-conserving treatment regimen determines the inflammatory response and outcome of photodynamic therapy of tumors. *Cancer Res*. 2004;64: 2120-2126.
82. Reis e Sousa C. Activation of dendritic cells: translating innate into adaptive immunity. *Curr Opin Immunol*. 2004;16: 21-25.
83. Sur BW, Nguyen P, Sun CH, Tromberg BJ, Nelson EL. Immunophototherapy using PDT combined with rapid intratumoral dendritic cell injection. *Photochem Photobiol*. 2008;84:1257-1264.
84. Castellino F, Germain RN. Cooperation between CD4+ and CD8+ T cells: when, where, and how. *Annu Rev Immunol*. 2006;24:519-540.
85. Gollnick SO, Vaughan L, Henderson BW. Generation of effective antitumor vaccines using photodynamic therapy. *Cancer Res*. 2002;62:1604-1608.
86. Korbek M, Sun J. Photodynamic therapy-generated vaccine for cancer therapy. *Cancer Immunol Immunother*. 2006;55: 900-909.
87. Korbek M, Merchant S, Huang N. Exploitation of immune response-eliciting properties of hypocrellin photosensitizer SL052-based photodynamic therapy for eradication of malignant tumors. *Photochem Photobiol*. 2009;85:1418-1424.
88. Jalili A, Makowski M, Switaj T, et al. Effective photoimmunotherapy of murine colon carcinoma induced by the combination of photodynamic therapy and dendritic cells. *Clin Cancer Res*. 2004;10: 4498-4508.
89. Henderson BW, Gollnick SO. Mechanistic principles of photodynamic therapy. In: Vo-Dinh T, ed. *Biomedical Photonics Handbook*. Boca Raton, FL: CRC Press; 2003:36.1-36.27.
90. Oleinick NL, Evans HH. The photobiology of photodynamic therapy: cellular targets and mechanisms. *Radiat Res*. 1998;150(5 suppl):S146-S156.
91. Gollnick SO, Owczarczak B, Maier P. Photodynamic therapy and anti-tumor immunity. *Lasers Surg Med*. 2006;38:509-515.
92. Korbek M, Sun J, Cecic I. Photodynamic therapy-induced cell surface expression and release of heat shock proteins: relevance for tumor response. *Cancer Res*. 2005;65:1018-1026.
93. Korbek M, Stott B, Sun J. Photodynamic therapy-generated vaccines: relevance of tumour cell death expression. *Br J Cancer*. 2007;97:1381-1387.
94. Vabulas RM, Wagner H, Schild H. Heat shock proteins as ligands of toll-like receptors. *Curr Top Microbiol Immunol*. 2002; 270:169-184.
95. Gomer CJ, Ryter SW, Ferrario A, Rucker N, Wong S, Fisher AM. Photodynamic therapy-mediated oxidative stress can induce expression of heat shock proteins. *Cancer Res*. 1996;56:2355-2360.
96. Gollnick SO, Kabingu E, Kousis PC, Henderson BW. Stimulation of the host immune response by photodynamic therapy (PDT). *Proc SPIE*. 2004;5319:60-70.
97. Stott B, Korbek M. Activation of complement C3, C5, and C9 genes in tumors treated by photodynamic therapy. *Cancer Immunol Immunother*. 2007;56:649-658.
98. Gomer CJ, Ferrario A, Murphree AL. The effect of localized porphyrin photodynamic therapy on the induction of tumour metastasis. *Br J Cancer*. 1987;56:27-32.
99. van Duijnhoven FH, Aalbers RI, Rovers JP, Terpstra OT, Kuppen PJ. Immunological aspects of photodynamic therapy of liver tumors in a rat model for colorectal cancer. *Photochem Photobiol*. 2003;78: 235-240.
100. Thong PS, Olivo M, Kho KW, et al. Immune response against angiosarcoma following lower fluence rate clinical photodynamic therapy. *J Environ Pathol Toxicol Oncol*. 2008;27:35-42.
101. Friedberg JS, Mick R, Stevenson JP, et al. Phase II trial of pleural photodynamic therapy and surgery for patients with non-small-cell lung cancer with pleural spread. *J Clin Oncol*. 2004;22:2192-2201.
102. Kessel D, Erickson C. Porphyrin photosensitization of multi-drug resistant cell types. *Photochem Photobiol*. 1992;55: 397-399.
103. Nahabedian MY, Cohen RA, Contino MF, et al. Combination cytotoxic chemotherapy with cisplatin or doxorubicin and photodynamic therapy in murine tumors. *J Natl Cancer Inst*. 1988;80:739-743.
104. Sinha AK, Anand S, Ortel BJ, et al. Methotrexate used in combination with aminolaevulinic acid for photodynamic killing of prostate cancer cells. *Br J Cancer*. 2006;95: 485-495.
105. Ma LW, Berg K, Danielsen HE, Kaalhus O, Iani V, Moan J. Enhanced antitumor effect of photodynamic therapy by microtubule inhibitors. *Cancer Lett*. 1996;109: 129-139.
106. Mroz P, Hamblin MR. Combination of PDT and a DNA demethylating agent produces anti-tumor immune response in a mouse tumor model. *Proc SPIE*. 2009; 7380:73801-73809.
107. Pogue BW, O'Hara JA, Demidenko E, et al. Photodynamic therapy with verteporfin in the radiation-induced fibrosarcoma-1 tumor causes enhanced radiation sensitivity. *Cancer Res*. 2003;63: 1025-1033.
108. Luksiene Z, Kalvelyte A, Supino R. On the combination of photodynamic therapy with ionizing radiation. *J Photochem Photobiol B*. 1999;52:35-42.
109. Weinberg BD, Allison RR, Sibata C, Parent T, Downie G. Results of combined photodynamic therapy (PDT) and high dose rate brachytherapy (HDR) in treatment of obstructive endobronchial non-small cell lung cancer (NSCLC). *Photodiagnosis Photodyn Ther*. 2010;7:50-58.
110. Ferrario A, Von Tiehl K, Wong S, Luna M, Gomer CJ. Cyclooxygenase-2 inhibitor treatment enhances photodynamic ther-

- apy-mediated tumor response. *Cancer Res.* 2002;62:3956-3961.
111. Makowski M, Grzela T, Niderla J, et al. Inhibition of cyclooxygenase-2 indirectly potentiates antitumor effects of photodynamic therapy in mice. *Clin Cancer Res.* 2003;9:5417-5422.
 112. Ferrario A, Fisher AM, Rucker N, Gomer CJ. Celecoxib and NS-398 enhance photodynamic therapy by increasing in vitro apoptosis and decreasing in vivo inflammatory and angiogenic factors. *Cancer Res.* 2005;65:9473-9478.
 113. Kleban J, Mikes J, Horvath V, et al. Mechanisms involved in the cell cycle and apoptosis of HT-29 cells pre-treated with MK-886 prior to photodynamic therapy with hypericin. *J Photochem Photobiol B.* 2008;93:108-118.
 114. Sato N, Moore BW, Keevey S, Drazba JA, Hasan T, Maytin EV. Vitamin D enhances ALA-induced protoporphyrin IX production and photodynamic cell death in 3-D organotypic cultures of keratinocytes. *J Invest Dermatol.* 2007;127:925-934.
 115. Liu W, Baer MR, Bowman MJ, et al. The tyrosine kinase inhibitor imatinib mesylate enhances the efficacy of photodynamic therapy by inhibiting ABCG2. *Clin Cancer Res.* 2007;13:2463-2470.
 116. Biade S, Maziere JC, Mora L, et al. Lovastatin potentiates the photocytotoxic effect of photofrin II delivered to HT29 human colonic adenocarcinoma cells by low density lipoprotein. *Photochem Photobiol.* 1993;57:371-375.
 117. Traul DL, Anderson GS, Bilitz JM, Krieg M, Sieber F. Potentiation of merocyanine 540-mediated photodynamic therapy by salicylate and related drugs. *Photochem Photobiol.* 1995;62:790-799.
 118. Golab J, Olszewska D, Mroz P, et al. Erythropoietin restores the antitumor effectiveness of photodynamic therapy in mice with chemotherapy-induced anemia. *Clin Cancer Res.* 2002;8:1265-1270.
 119. Solar P, Koval J, Mikes J, et al. Erythropoietin inhibits apoptosis induced by photodynamic therapy in ovarian cancer cells. *Mol Cancer Ther.* 2008;7:2263-2271.
 120. Huang Z, Chen Q, Shakil A, et al. Hyperoxygenation enhances the tumor cell killing of photofrin-mediated photodynamic therapy. *Photochem Photobiol.* 2003;78:496-502.
 121. Matzi V, Maier A, Sankin O, Lindenmann J, Woltsche M, Smolle J, Smolle-Juttner FM. Photodynamic therapy enhanced by hyperbaric oxygenation in palliation of malignant pleural mesothelioma: clinical experience. *Photodiagnosis Photodyn Ther.* 2004;1:57-64.
 122. Orenstein A, Kostenich G, Kopolovic Y, Babushkina T, Malik Z. Enhancement of ALA-PDT damage by IR-induced hyperthermia on a colon carcinoma model. *Photochem Photobiol.* 1999;69:703-707.
 123. Moore JV, West CM, Haylett AK. Vascular function and tissue injury in murine skin following hyperthermia and photodynamic therapy, alone and in combination. *Br J Cancer.* 1992;66:1037-1043.
 124. Nowis D, Legat M, Grzela T, et al. Heme oxygenase-1 protects tumor cells against photodynamic therapy-mediated cytotoxicity. *Oncogene.* 2006;25:3365-3374.
 125. Miyake M, Ishii M, Kawashima K, et al. siRNA-mediated knockdown of the heme synthesis and degradation pathways: modulation of treatment effect of 5-aminolevulinic acid-based photodynamic therapy in urothelial cancer cell lines. *Photochem Photobiol.* 2009;85:1020-1027.
 126. Curnow A, McIlroy BW, Postle-Hacon MJ, Porter JB, MacRobert AJ, Bown SG. Enhancement of 5-aminolaevulinic acid-induced photodynamic therapy in normal rat colon using hydroxypyridinone iron-chelating agents. *Br J Cancer.* 1998;78:1278-1282.
 127. Henderson BW, Sitnik-Busch TM, Vaughan LA. Potentiation of photodynamic therapy antitumor activity in mice by nitric oxide synthase inhibition is fluorescence rate dependent. *Photochem Photobiol.* 1999;70:64-71.
 128. Ferrario A, Rucker N, Wong S, Luna M, Gomer CJ. Survivin, a member of the inhibitor of apoptosis family, is induced by photodynamic therapy and is a target for improving treatment response. *Cancer Res.* 2007;67:4989-4995.
 129. Jiang F, Robin AM, Katakowski M, et al. Photodynamic therapy with photofrin in combination with Buthionine Sulfoximine (BSO) of human glioma in the nude rat. *Lasers Med Sci.* 2003;18:128-133.
 130. Melnikova VO, Bezdetnaya LN, Brault D, Potapenko AY, Guillemain F. Enhancement of meta-tetrahydroxyphenylchlorin-sensitized photodynamic treatment on human tumor xenografts using a water-soluble vitamin E analogue, Trolox. *Int J Cancer.* 2000;88:798-803.
 131. Ferrario A, Gomer CJ. Avastin enhances photodynamic therapy treatment of Kaposi's sarcoma in a mouse tumor model. *J Environ Pathol Toxicol Oncol.* 2006;25:251-259.
 132. Jiang F, Zhang X, Kalkanis SN, et al. Combination therapy with antiangiogenic treatment and photodynamic therapy for the nude mouse bearing U87 glioblastoma. *Photochem Photobiol.* 2008;84:128-137.
 133. Ferrario A, Chantrain CF, von Tiehl K, et al. The matrix metalloproteinase inhibitor prinomastat enhances photodynamic therapy responsiveness in a mouse tumor model. *Cancer Res.* 2004;64:2328-2332.
 134. Kosharsky B, Solban N, Chang SK, Rizvi I, Chang Y, Hasan T. A mechanism-based combination therapy reduces local tumor growth and metastasis in an orthotopic model of prostate cancer. *Cancer Res.* 2006;66:10953-10958.
 135. Ferrario A, von Tiehl KF, Rucker N, Schwarz MA, Gill PS, Gomer CJ. Antiangiogenic treatment enhances photodynamic therapy responsiveness in a mouse mammary carcinoma. *Cancer Res.* 2000;60:4066-4069.
 136. Zhou Q, Olivo M, Lye KY, Moore S, Sharma A, Chowbay B. Enhancing the therapeutic responsiveness of photodynamic therapy with the antiangiogenic agents SU5416 and SU6668 in murine nasopharyngeal carcinoma models. *Cancer Chemother Pharmacol.* 2005;56:569-577.
 137. Park EK, Bae SM, Kwak SY, et al. Photodynamic therapy with recombinant adenovirus AdmIL-12 enhances anti-tumour therapy efficacy in human papillomavirus 16 (E6/E7) infected tumour model. *Immunology.* 2008;124:461-468.
 138. Kessel D. Promotion of PDT efficacy by a Bcl-2 antagonist. *Photochem Photobiol.* 2008;84:809-814.
 139. Kessel D, Caruso JA, Reiners JJ Jr. Potentiation of photodynamic therapy by ursodeoxycholic acid. *Cancer Res.* 2000;60:6985-6988.
 140. Separovic D, Bielawski J, Pierce JS, et al. Increased tumour dihydroceramide production after Photofrin-PDT alone and improved tumour response after the combination with the ceramide analogue LCL29. Evidence from mouse squamous cell carcinomas. *Br J Cancer.* 2009;100:626-632.
 141. Weyergang A, Berg K, Kaalhus O, Peng Q, Selbo PK. Photodynamic therapy targets the mTOR signaling network in vitro and in vivo. *Mol Pharm.* 2009;6:255-264.
 142. Peng Q, Warloe T, Moan J, et al. Antitumor effect of 5-aminolevulinic acid-mediated photodynamic therapy can be enhanced by the use of a low dose of photofrin in human tumor xenografts. *Cancer Res.* 2001;61:5824-5832.
 143. Cincotta L, Szeto D, Lampros E, Hasan T, Cincotta AH. Benzophenothiazine and benzoporphyrin derivative combination phototherapy effectively eradicates large murine sarcomas. *Photochem Photobiol.* 1996;63:229-237.
 144. van Geel IP, Oppelaar H, Oussoren YG, Schuitmaker JJ, Stewart FA. Mechanisms for optimising photodynamic therapy: second-generation photosensitisers in combination with mitomycin C. *Br J Cancer.* 1995;72:344-350.
 145. Berg K, Anholt H, Bech O, Moan J. The influence of iron chelators on the accumulation of protoporphyrin IX in 5-aminolaevulinic acid-treated cells. *Br J Cancer.* 1996;74:688-697.
 146. Rasheva VI, Domingos PM. Cellular responses to endoplasmic reticulum stress and apoptosis. *Apoptosis.* 2009;14:996-1007.
 147. Bhuvanewari R, Yuen GY, Chee SK, Olivo M. Hypericin-mediated photodynamic therapy in combination with Avastin (bevacizumab) improves tumor response by downregulating angiogenic proteins. *Photochem Photobiol Sci.* 2007;6:1275-1283.
 148. Cengel KA, Hahn SM, Glatstein E. C225 and PDT combination therapy for ovarian cancer: the play's the thing. *J Natl Cancer Inst.* 2005;97:1488-1489.
 149. Kelly JF, Snell ME. Hematoporphyrin derivative: a possible aid in the diagnosis and therapy of carcinoma of the bladder. *J Urol.* 1976;115:150-151.
 150. Dougherty TJ, Kaufman JE, Goldfarb A, Weishaupt KR, Boyle D, Mittleman A. Photoradiation therapy for the treatment of malignant tumors. *Cancer Res.* 1978;38:2628-2635.
 151. Fayer D, Corbett M, Heirs M, Fox D, Eastwood A. A systematic review of photodynamic therapy in the treatment of precancerous skin conditions, Barrett's oesophagus and cancers of the biliary tract, brain, head and neck, lung, oesophagus and skin. *Health Technol Assess.* 2010;14:1-288.
 152. Gao F, Bai Y, Ma SR, Liu F, Li ZS. Systematic review: photodynamic therapy for unresectable cholangiocarcinoma. *J Hepatobiliary Pancreat Sci.* 2010;17:125-131.
 153. Hahn SM, Smith RP, Friedberg J. Photodynamic therapy for mesothelioma. *Curr Treat Options Oncol.* 2001;2:375-383.
 154. Hahn SM, Fraker DL, Mick R, et al. A phase II trial of intraperitoneal photody-

- dynamic therapy for patients with peritoneal carcinomatosis and sarcomatosis. *Clin Cancer Res*. 2006;12:2517-2525.
155. Hendren SK, Hahn SM, Spitz FR, et al. Phase II trial of debulking surgery and photodynamic therapy for disseminated intraperitoneal tumors. *Ann Surg Oncol*. 2001;8:65-71.
 156. Braathen LR, Szeimies RM, Basset-Seguín N, et al. Guidelines on the use of photodynamic therapy for nonmelanoma skin cancer: an international consensus. International Society for Photodynamic Therapy in Dermatology, 2005. *J Am Acad Dermatol*. 2007;56:125-143.
 157. Nestor MS, Gold MH, Kauvar AN, et al. The use of photodynamic therapy in dermatology: results of a consensus conference. *J Drugs Dermatol*. 2006;5:140-154.
 158. Kennedy JC, Pottier RH, Pross DC. Photodynamic therapy with endogenous protoporphyrin IX: basic principles and present clinical experience. *J Photochem Photobiol B*. 1990;6:143-148.
 159. Piacquadio DJ, Chen DM, Farber HF, et al. Photodynamic therapy with aminolevulinic acid topical solution and visible blue light in the treatment of multiple actinic keratoses of the face and scalp: investigator-blinded, phase 3, multicenter trials. *Arch Dermatol*. 2004;140:41-46.
 160. Freeman M, Vinciullo C, Francis D, et al. A comparison of photodynamic therapy using topical methyl aminolevulinate (Metvix) with single cycle cryotherapy in patients with actinic keratosis: a prospective, randomized study. *J Dermatolog Treat*. 2003;14:99-106.
 161. Pariser DM, Lowe NJ, Stewart DM, et al. Photodynamic therapy with topical methyl aminolevulinate for actinic keratosis: results of a prospective randomized multicenter trial. *J Am Acad Dermatol*. 2003;48:227-232.
 162. Morton C, Horn M, Leman J, et al. Comparison of topical methyl aminolevulinate photodynamic therapy with cryotherapy or Fluorouracil for treatment of squamous cell carcinoma in situ: Results of a multicenter randomized trial. *Arch Dermatol*. 2006;142:729-735.
 163. Szeimies RM, Karrer S, Radakovic-Fijan S, et al. Photodynamic therapy using topical methyl 5-aminolevulinate compared with cryotherapy for actinic keratosis: A prospective, randomized study. *J Am Acad Dermatol*. 2002;47:258-262.
 164. Kurwa HA, Yong-Gee SA, Seed PT, Markey AC, Barlow RJ. A randomized paired comparison of photodynamic therapy and topical 5-fluorouracil in the treatment of actinic keratoses. *J Am Acad Dermatol*. 1999;41(3 pt 1):414-418.
 165. Smith S, Piacquadio D, Morhenn V, Atkin D, Fitzpatrick R. Short incubation PDT versus 5-FU in treating actinic keratoses. *J Drugs Dermatol*. 2003;2:629-635.
 166. Szeimies RM, Stockfleth E, Popp G, et al. Long-term follow-up of photodynamic therapy with a self-adhesive 5-aminolevulinic acid patch: 12 months data. *Br J Dermatol*. 2010;162:410-414.
 167. Morton CA, Whitehurst C, Moseley H, McColl JH, Moore JV, Mackie RM. Comparison of photodynamic therapy with cryotherapy in the treatment of Bowen's disease. *Br J Dermatol*. 1996;135:766-771.
 168. Morton CA. Methyl aminolevulinate: actinic keratoses and Bowen's disease. *Dermatol Clin*. 2007;25:81-87.
 169. Salim A, Leman JA, McColl JH, Chapman R, Morton CA. Randomized comparison of photodynamic therapy with topical 5-fluorouracil in Bowen's disease. *Br J Dermatol*. 2003;148:539-543.
 170. Taub AF. Photodynamic therapy: other uses. *Dermatol Clin*. 2007;25:101-109.
 171. Wolf P, Rieger E, Kerl H. Topical photodynamic therapy with endogenous porphyrins after application of 5-aminolevulinic acid. An alternative treatment modality for solar keratoses, superficial squamous cell carcinomas, and basal cell carcinomas? *J Am Acad Dermatol*. 1993;28:17-21.
 172. Cairnduff F, Stringer MR, Hudson EJ, Ash DV, Brown SB. Superficial photodynamic therapy with topical 5-aminolevulinic acid for superficial primary and secondary skin cancer. *Br J Cancer*. 1994;69:605-608.
 173. Zeitouni NC, Shieh S, Oseroff AR. Laser and photodynamic therapy in the management of cutaneous malignancies. *Clin Dermatol*. 2001;19:328-338.
 174. Basset-Seguín N, Ibbotson SH, Emtestam L, et al. Topical methyl aminolevulinate photodynamic therapy versus cryotherapy for superficial basal cell carcinoma: a 5 year randomized trial. *Eur J Dermatol*. 2008;18:547-553.
 175. Szeimies RM, Ibbotson S, Murrell DF, et al. A clinical study comparing methyl aminolevulinate photodynamic therapy and surgery in small superficial basal cell carcinoma (8-20 mm), with a 12-month follow-up. *J Eur Acad Dermatol Venereol*. 2008;22:1302-1311.
 176. Mosterd K, Thissen MR, Nelemans P, et al. Fractionated 5-aminolevulinic acid-photodynamic therapy vs. surgical excision in the treatment of nodular basal cell carcinoma: results of a randomized controlled trial. *Br J Dermatol*. 2008;159:864-870.
 177. Rhodes LE, de Rie M, Enstrom Y, et al. Photodynamic therapy using topical methyl aminolevulinate vs surgery for nodular basal cell carcinoma: results of a multicenter randomized prospective trial. *Arch Dermatol*. 2004;140:17-23.
 178. Rhodes LE, de Rie MA, Leifsdottir R, et al. Five-year follow-up of a randomized, prospective trial of topical methyl aminolevulinate photodynamic therapy vs surgery for nodular basal cell carcinoma. *Arch Dermatol*. 2007;143:1131-1136.
 179. Berroeta L, Clark C, Dawe RS, Ibbotson SH, Fleming CJ. A randomized study of minimal curettage followed by topical photodynamic therapy compared with surgical excision for low-risk nodular basal cell carcinoma. *Br J Dermatol*. 2007;157:401-403.
 180. Jerjes W, Upile T, Akram S, Hopper C. The surgical palliation of advanced head and neck cancer using photodynamic therapy. *Clin Oncol (R Coll Radiol)*. 2010;22:785-791.
 181. Bredell MG, Besic E, Maake C, Walt H. The application and challenges of clinical PD-PDT in the head and neck region: a short review. *J Photochem Photobiol B*. 2010;101:185-190.
 182. Li LB, Luo RC, Liao WJ, Zhang MJ, Luo YL, Miao JX. Clinical study of Photofrin photodynamic therapy for the treatment of relapse nasopharyngeal carcinoma. *Photochem Photobiol Ther*. 2006;3:266-271.
 183. Biel MA. Photodynamic therapy and the treatment of head and neck neoplasia. *Laryngoscope*. 1998;108:1259-1268.
 184. Biel M. Advances in photodynamic therapy for the treatment of head and neck cancers. *Lasers Surg Med*. 2006;38:349-355.
 185. Keller GS, Doiron DR, Fisher GU. Photodynamic therapy in otolaryngology-head and neck surgery. *Arch Otolaryngol*. 1985;111:758-761.
 186. Feyh J, Goetz A, Muller W, Konigsberger R, Kastenbauer E. Photodynamic therapy in head and neck surgery. *J Photochem Photobiol B*. 1990;7:353-358.
 187. Feyh J, Gutmann A, Leunig A. A photodynamic therapy in head and neck surgery. *Laryngol Rhinol Otol*. 1993;72:273-278.
 188. Hopper C, Kubler A, Lewis H, Tan IB, Putnam G. mTHPC-mediated photodynamic therapy for early oral squamous cell carcinoma. *Int J Cancer*. 2004;111:138-146.
 189. Fan KF, Hopper C, Speight PM, Buonacorsi G, MacRobert AJ, Bown SG. Photodynamic therapy using 5-aminolevulinic acid for premalignant and malignant lesions of the oral cavity. *Cancer*. 1996;78:1374-1383.
 190. Copper MP, Triesscheijn M, Tan IB, Ruevekamp MC, Stewart FA. Photodynamic therapy in the treatment of multiple primary tumours in the head and neck, located to the oral cavity and oropharynx. *Clin Otolaryngol*. 2007;32:185-189.
 191. D'Cruz AK, Robinson MH, Biel MA. mTHPC-mediated photodynamic therapy in patients with advanced, incurable head and neck cancer: a multicenter study of 128 patients. *Head Neck*. 2004;26:232-240.
 192. Grant WE, Hopper C, MacRobert AJ, Speight PM, Bown SG. Photodynamic therapy of oral cancer: photosensitisation with systemic aminolevulinic acid. *Lancet*. 1993;342:147-148.
 193. Sieron A, Namyslowski G, Misiolek M, Adamek M, Kawczyk-Krupka A. Photodynamic therapy of premalignant lesions and local recurrence of laryngeal and hypopharyngeal cancers. *Eur Arch Otorhinolaryngol*. 2001;258:349-352.
 194. Wolfen HC. Carpe luz-seize the light: endoprevention of esophageal adenocarcinoma when using photodynamic therapy with porfimer sodium. *Gastrointest Endosc*. 2005;62:499-503.
 195. Wang I, Bendsoe N, Klinteberg CA, et al. Photodynamic therapy vs. cryosurgery of basal cell carcinomas: results of a phase III clinical trial. *Br J Dermatol*. 2001;144:832-840.
 196. Hahn S, Glatstein E. The emergence of photodynamic therapy as a major modality in cancer treatment. *Rev Contemp Pharmacother*. 1999;10:69-74.
 197. Wolfen HC, Hemminger LL, Wallace MB, Devault KR. Clinical experience of patients undergoing photodynamic therapy for Barrett's dysplasia or cancer. *Aliment Pharmacol Ther*. 2004;20:1125-1131.
 198. Corti L, Skarlatos J, Boso C, et al. Outcome of patients receiving photodynamic therapy for early esophageal cancer. *Int J Radiat Oncol Biol Phys*. 2000;47:419-424.
 199. Overholt BF, Wang KK, Burdick JS, et al. Five-year efficacy and safety of photodynamic therapy with Photofrin in Barrett's high-grade dysplasia. *Gastrointest Endosc*. 2007;66:460-468.
 200. Rees JR, Lao-Sirieix P, Wong A, Fitzgerald RC. Treatment for Barrett's oesophagus. *Cochrane Database Syst Rev*. 2010;(1):CD004060.

201. Overholt BF, Lightdale CJ, Wang KK, et al. Photodynamic therapy with porfimer sodium for ablation of high-grade dysplasia in Barrett's esophagus: international, partially blinded, randomized phase III trial. *Gastrointest Endosc*. 2005;62:488-498.
202. Shaheen NJ, Inadomi JM, Overholt BF, Sharma P. What is the best management strategy for high grade dysplasia in Barrett's oesophagus? A cost effectiveness analysis. *Gut*. 2004;53:1736-1744.
203. Mackenzie GD, Jamieson NF, Novelli MR, et al. How light dosimetry influences the efficacy of photodynamic therapy with 5-aminolaevulinic acid for ablation of high-grade dysplasia in Barrett's esophagus. *Lasers Med Sci*. 2008;23:203-210.
204. Wolfsen HC. Uses of photodynamic therapy in premalignant and malignant lesions of the gastrointestinal tract beyond the esophagus. *J Clin Gastroenterol*. 2005;39:653-664.
205. Nakamura H, Yanai H, Nishikawa J, et al. Experience with photodynamic therapy (endoscopic laser therapy) for the treatment of early gastric cancer. *Hepatogastroenterology*. 2001;48:1599-1603.
206. Yanai H, Kuroiwa Y, Shimizu N, et al. The pilot experience of immunotherapy-combined photodynamic therapy for advanced gastric cancer in elderly patients. *Int J Gastrointest Cancer*. 2002;32:139-142.
207. Mlkvy P, Messmann H, Debinski H, et al. Photodynamic therapy for polyps in familial adenomatous polyposis-a pilot study. *Eur J Cancer*. 1995;31A:1160-1165.
208. Abulafi AM, Allardice JT, Williams NS, van Someren N, Swain CP, Ainley C. Photodynamic therapy for malignant tumours of the ampulla of Vater. *Gut*. 1995;36:853-856.
209. McCaughan JS Jr, Mertens BF, Cho C, Barabash RD, Payton HW. Photodynamic therapy to treat tumors of the extrahepatic biliary ducts. A case report. *Arch Surg*. 1991;126:111-113.
210. Ortner MA, Liebetrueth J, Schreiber S, et al. Photodynamic therapy of nonresectable cholangiocarcinoma. *Gastroenterology*. 1998;114:536-542.
211. Ortner ME, Caca K, Berr F, et al. Successful photodynamic therapy for nonresectable cholangiocarcinoma: a randomized prospective study. *Gastroenterology*. 2003;125:1355-1363.
212. Witzigmann H, Berr F, Ringel U, et al. Surgical and palliative management and outcome in 184 patients with hilar cholangiocarcinoma: palliative photodynamic therapy plus stenting is comparable to r1/r2 resection. *Ann Surg*. 2006;244:230-239.
213. Zoepf T, Jakobs R, Arnold JC, Apel D, Riemann JF. Palliation of nonresectable bile duct cancer: improved survival after photodynamic therapy. *Am J Gastroenterol*. 2005;100:2426-2430.
214. Pereira SP, Ayaru L, Rogowska A, Mosse A, Hatfield AR, Bown SG. Photodynamic therapy of malignant biliary strictures using meso-tetrahydroxyphenylchlorin. *Eur J Gastroenterol Hepatol*. 2007;19:479-485.
215. Bown SG, Rogowska AZ, Whitelaw DE, et al. Photodynamic therapy for cancer of the pancreas. *Gut*. 2002;50:549-557.
216. Loh CS, Bliss P, Bown SG, Krasner N. Photodynamic therapy for villous adenomas of the colon and rectum. *Endoscopy*. 1994;26:243-246.
217. Nakamura T, Fukui H, Ishii Y, Ejiri K, Ejiri M. Photodynamic therapy with polyepctomy for rectal cancer. *Gastrointest Endosc*. 2003;57:266-269.
218. Spinelli P, Mancini A, Dal Fante M. Endoscopic treatment of gastrointestinal tumors: indications and results of laser photocoagulation and photodynamic therapy. *Semin Surg Oncol*. 1995;11:307-318.
219. Abulafi AM, Deiode M, Allardice JT, Ansell J, Rogers J, Williams NS. Adjuvant intraoperative photodynamic therapy in experimental colorectal cancer. *Br J Surg*. 1995;82:178-181.
220. Wang S, Bromley E, Xu L, Chen JC, Keltner L. Talaporfin sodium. *Expert Opin Pharmacother*. 2010;11:133-140.
221. Cengel KA, Glatstein E, Hahn SM. Intraperitoneal photodynamic therapy. *Cancer Treat Res*. 2007;134:493-514.
222. Hahn SM, Putt ME, Metz J, et al. Photofrin uptake in the tumor and normal tissues of patients receiving intraperitoneal photodynamic therapy. *Clin Cancer Res*. 2006;12:5464-5470.
223. Wilson JJ, Jones H, Burock M, et al. Patterns of recurrence in patients treated with photodynamic therapy for intraperitoneal carcinomatosis and sarcomatosis. *Int J Oncol*. 2004;24:711-717.
224. Nathan TR, Whitelaw DE, Chang SC, et al. Photodynamic therapy for prostate cancer recurrence after radiotherapy: a phase I study. *J Urol*. 2002;168:1427-1432.
225. Moore CM, Nathan TR, Lees WR, et al. Photodynamic therapy using meso tetra hydroxy phenyl chlorin (mTHPC) in early prostate cancer. *Lasers Surg Med*. 2006;38:356-363.
226. Du KL, Mick R, Busch TM, et al. Preliminary results of interstitial motexafin lutetium-mediated PDT for prostate cancer. *Lasers Surg Med*. 2006;38:427-434.
227. Patel H, Mick R, Finlay J, et al. Motexafin lutetium-photodynamic therapy of prostate cancer: short- and long-term effects on prostate-specific antigen. *Clin Cancer Res*. 2008;14:4869-4876.
228. Weersink RA, Forbes J, Bisland S, et al. Assessment of cutaneous photosensitivity of TOOKAD (WST09) in preclinical animal models and in patients. *Photochem Photobiol*. 2005;81:106-113.
229. Trachtenberg J, Bogaards A, Weersink RA, et al. Vascular targeted photodynamic therapy with palladium-bacteriopheophorbide photosensitizer for recurrent prostate cancer following definitive radiation therapy: assessment of safety and treatment response. *J Urol*. 2007;178:1974-1979; discussion 1979.
230. Trachtenberg J, Weersink RA, Davidson SR, et al. Vascular-targeted photodynamic therapy (padoporfin, WST09) for recurrent prostate cancer after failure of external beam radiotherapy: a study of escalating light doses. *BJU Int*. 2008;102:556-562.
231. Prout GR Jr, Lin CW, Benson R Jr, et al. Photodynamic therapy with hematoporphyrin derivative in the treatment of superficial transitional-cell carcinoma of the bladder. *N Engl J Med*. 1987;317:1251-1255.
232. Uchibayashi T, Koshida K, Kunimi K, Hisazumi H. Whole bladder wall photodynamic therapy for refractory carcinoma in situ of the bladder. *Br J Cancer*. 1995;71:625-628.
233. D'Hallewin MA, Baert L. Long-term results of whole bladder wall photodynamic therapy for carcinoma in situ of the bladder. *Urology*. 1995;45:763-767.
234. Nseyo UO, Shumaker B, Klein EA, Sutherland K. Photodynamic therapy using porfimer sodium as an alternative to cystectomy in patients with refractory transitional cell carcinoma in situ of the bladder. Bladder Photofrin Study Group. *J Urol*. 1998;160:39-44.
235. Berger AP, Steiner H, Stenzl A, Akkad T, Bartsch G, Holtl L. Photodynamic therapy with intravesical instillation of 5-aminolevulinic acid for patients with recurrent superficial bladder cancer: a single-center study. *Urology*. 2003;61:338-341.
236. Waidelich R, Beyer W, Knuchel R, et al. Whole bladder photodynamic therapy with 5-aminolevulinic acid using a white light source. *Urology*. 2003;61:332-337.
237. Jocham D, von Wietersheim J, Pfluger H, et al. BCG versus photodynamic therapy (PDT) for nonmuscle invasive bladder cancer-a multicentre clinical phase III study [in German]. *Aktuelle Urol*. 2009;40:91-99.
238. Pinthus JH, Bogaards A, Weersink R, Wilson BC, Trachtenberg J. Photodynamic therapy for urological malignancies: past to current approaches. *J Urol*. 2006;175:1201-1207.
239. Skyrme RJ, French AJ, Datta SN, Allman R, Mason MD, Matthews PN. A phase-I study of sequential mitomycin C and 5-aminolaevulinic acid-mediated photodynamic therapy in recurrent superficial bladder carcinoma. *BJU Int*. 2005;95:1206-1210.
240. Hayata Y, Kato H, Konaka C, Ono J, Takizawa N. Hematoporphyrin derivative and laser photoradiation in the treatment of lung cancer. *Chest*. 1982;81:269-277.
241. LoCicero J 3rd, Metzdorff M, Almgren C. Photodynamic therapy in the palliation of late stage obstructing non-small cell lung cancer. *Chest*. 1990;98:97-100.
242. Moghissi K, Dixon K, Stringer M, Freeman T, Thorpe A, Brown S. The place of bronchoscopic photodynamic therapy in advanced unresectable lung cancer: experience of 100 cases. *Eur J Cardiothorac Surg*. 1999;15:1-6.
243. Diaz-Jimenez JP, Martinez-Ballarin JE, Llunell A, Farrero E, Rodriguez A, Castro MJ. Efficacy and safety of photodynamic therapy versus Nd-YAG laser resection in NSCLC with airway obstruction. *Eur Respir J*. 1999;14:800-805.
244. McCaughan JS Jr, Williams TE. Photodynamic therapy for endobronchial malignant disease: a prospective fourteen-year study. *J Thorac Cardiovasc Surg*. 1997;114:940-946; discussion 946-947.
245. Furuse K, Fukuoka M, Kato H, et al. A prospective phase II study on photodynamic therapy with photofrin II for centrally located early-stage lung cancer. The Japan Lung Cancer Photodynamic Therapy Study Group. *J Clin Oncol*. 1993;11:1852-1857.
246. Lam S, Muller NL, Miller RR, et al. Laser treatment of obstructive endobronchial tumors: factors which determine response. *Lasers Surg Med*. 1987;7:29-35.
247. Loewen GM, Pandey R, Bellnier D, Henderson B, Dougherty T. Endobronchial

- photodynamic therapy for lung cancer. *Lasers Surg Med*. 2006;38:364-370.
248. Corti L, Toniolo L, Boso C, et al. Long-term survival of patients treated with photodynamic therapy for carcinoma in situ and early non-small-cell lung carcinoma. *Lasers Surg Med*. 2007;39:394-402.
 249. Endo C, Miyamoto A, Sakurada A, et al. Results of long-term follow-up of photodynamic therapy for roentgenographically occult bronchogenic squamous cell carcinoma. *Chest*. 2009;136:369-375.
 250. Usuda J, Ichinose S, Ishizumi T, et al. Outcome of photodynamic therapy using NPe6 for bronchogenic carcinomas in central airways >1.0 cm in diameter. *Clin Cancer Res*. 2010;16:2198-2204.
 251. Minnich DJ, Bryant AS, Dooley A, Cerfolio RJ. Photodynamic laser therapy for lesions in the airway. *Ann Thorac Surg*. 2010;89:1744-1748; discussion 1748-1749.
 252. Friedberg JS. Photodynamic therapy as an innovative treatment for malignant pleural mesothelioma. *Semin Thorac Cardiovasc Surg*. 2009;21:177-187.
 253. Moskal TL, Dougherty TJ, Urschel JD, et al. Operation and photodynamic therapy for pleural mesothelioma: 6-year follow-up. *Ann Thorac Surg*. 1998;66:1128-1133.
 254. Pass HI, Temeck BK, Kranda K, et al. Phase III randomized trial of surgery with or without intraoperative photodynamic therapy and postoperative immunotherapy for malignant pleural mesothelioma. *Ann Surg Oncol*. 1997;4:628-633.
 255. Friedberg JS, Mick R, Stevenson J, et al. A phase I study of Foscan-mediated photodynamic therapy and surgery in patients with mesothelioma. *Ann Thorac Surg*. 2003;75:952-959.
 256. Schouwink H, Rutgers ET, van der Sijp J, et al. Intraoperative photodynamic therapy after pleuropneumectomy in patients with malignant pleural mesothelioma: dose finding and toxicity results. *Chest*. 2001;120:1167-1174.
 257. Friedberg JS, Cengel KA. Pleural malignancies. *Semin Radiat Oncol*. 2010;20:208-214.
 258. Kostron H. Photodynamic diagnosis and therapy and the brain. *Methods Mol Biol*. 2010;635:261-280.
 259. Perria C, Capuzzo T, Cavagnaro G, et al. Fast attempts at the photodynamic treatment of human gliomas. *J Neurosurg Sci*. 1980;24:119-129.
 260. Kaye AH, Morstyn G, Brownbill D. Adjuvant high-dose photoradiation therapy in the treatment of cerebral glioma: a phase 1-2 study. *J Neurosurg*. 1987;67:500-505.
 261. Muller PJ, Wilson BC. Photodynamic therapy for recurrent supratentorial gliomas. *Semin Surg Oncol*. 1995;11:346-354.
 262. Krishnamurthy S, Powers SK, Witmer P, Brown T. Optimal light dose for interstitial photodynamic therapy in treatment for malignant brain tumors. *Lasers Surg Med*. 2000;27:224-234.
 263. Kostron H, Fritsch E, Grunert V. Photodynamic therapy of malignant brain tumours: a phase I/II trial. *Br J Neurosurg*. 1988;2:241-248.
 264. Marks PV, Belchetz PE, Saxena A, et al. Effect of photodynamic therapy on recurrent pituitary adenomas: clinical phase I/II trial-an early report. *Br J Neurosurg*. 2000;14:317-325.
 265. Eljamel S. Photodynamic assisted surgical resection and treatment of malignant brain tumors; technique, technology and clinical application. *Photodiag Photodyn Ther*. 2004;1:93-98.
 266. Muller P, Wilson BC. Photodynamic therapy of brain tumours-post-operative "field fractionation." *J Photochem Photobiol B*. 1991;9:117-119.
 267. Stummer W, Novotny A, Stepp H, Goetz C, Bise K, Reulen HJ. Fluorescence-guided resection of glioblastoma multiforme by using 5-aminolevulinic acid-induced porphyrins: a prospective study in 52 consecutive patients. *J Neurosurg*. 2000;93:1003-1013.
 268. Stylli SS, Kaye AH, MacGregor L, Howes M, Rajendra P. Photodynamic therapy of high grade glioma-long term survival. *J Clin Neurosci*. 2005;12:389-398.
 269. Stummer W, Pichlmeier U, Meinel T, Wiestler OD, Zanella F, Reulen HJ. Fluorescence-guided surgery with 5-aminolevulinic acid for resection of malignant glioma: a randomised controlled multicentre phase III trial. *Lancet Oncol*. 2006;7:392-401.
 270. Muller PJ, Wilson BC. Photodynamic therapy of brain tumors-a work in progress. *Lasers Surg Med*. 2006;38:384-389.
 271. Eljamel MS, Goodman C, Moseley H. ALA and Photofrin fluorescence-guided resection and repetitive PDT in glioblastoma multiforme: a single centre Phase III randomised controlled trial. *Lasers Med Sci*. 2008;23:361-367.
 272. von Tappeiner H, Jesionek A. Therapeutische Versuche mit fluoreszierenden Stoffen. *Munch Med Wochenschr*. 1903;47:2042-2044.
 273. Starkey JR, Rebane AK, Drobizhev MA, et al. New two-photon activated photodynamic therapy sensitizers induce xenograft tumor regressions after near-IR laser treatment through the body of the host mouse. *Clin Cancer Res*. 2008;14:6564-6573.
 274. Collins HA, Khurana M, Moriyama EH, et al. Blood vessel closure using photosensitisers engineered for two-photon excitation. *Nature Photonics*. 2008;2:420-424.
 275. Lilje L, Portnoy M, Wilson BC. Apoptosis induced in vivo by photodynamic therapy in normal brain and intracranial tumour tissue. *Br J Cancer*. 2000;83:1110-1117.
 276. Mathews MS, Angell-Petersen E, Sanchez R, et al. The effects of ultra low fluence rate single and repetitive photodynamic therapy on glioma spheroids. *Lasers Surg Med*. 2009;41:578-584.
 277. Davies N, Wilson BC. Interstitial in vivo ALA-PpIX mediated metronomic photodynamic therapy (mPDT) using the CNS-1 astrocytoma with bioluminescence monitoring. *Photodiag Photodyn Ther*. 2007;4:202-212.
 278. Alqawi O, Espiritu M, Singh G. Molecular mechanisms associated with ALA-PDT of brain tumor cells. *Proc SPIE*. 2009;7380:73806Y.1-73806Y.11.
 279. Chen J, Stefflova K, Niedre MJ, et al. Protease-triggered photosensitizing beacon based on singlet oxygen quenching and activation. *J Am Chem Soc*. 2004;126:11450-11451.
 280. Zheng G, Chen J, Stefflova K, Jarvi M, Li H, Wilson BC. Photodynamic molecular beacon as an activatable photosensitizer based on protease-controlled singlet oxygen quenching and activation. *Proc Natl Acad Sci U S A*. 2007;104:8989-8994.
 281. Chen J, Lovell JF, Lo PC, et al. A tumor mRNA-triggered photodynamic molecular beacon based on oligonucleotide hairpin control of singlet oxygen production. *Photochem Photobiol Sci*. 2008;7:775-781.
 282. Chen J, Liu TWB, Lo P-C, Wilson BC, Zheng G. "Zipper" molecular beacons: A generalized strategy to optimize the performance of activatable protease probes. *Bioconj Chem*. 2009;20:1836-1842.
 283. Wilson BC. Photonic and non-photonic based nanoparticles in cancer imaging and therapeutics. In: Dubowski J, Taney S, eds. *Photon-Based Nanoscience and Nanobiotechnology*. Dordrecht, the Netherlands: Springer; 2006:121-151.
 284. Richter AM, Waterfield E, Jain AK, Canaan AJ, Allison BA, Levy JG. Liposomal delivery of a photosensitizer, benzoporphyrin derivative monoacid ring A (BPD), to tumor tissue in a mouse tumor model. *Photochem Photobiol*. 1993;57:1000-1006.
 285. Chatterjee DK, Fong LS, Zhang Y. Nanoparticles in photodynamic therapy: an emerging paradigm. *Adv Drug Deliv Rev*. 2008;60:1627-1637.
 286. Kim S, Ohulchanskyy TY, Pudavar HE, Pandey RK, Prasad PN. Organically modified silica nanoparticles co-encapsulating photosensitizing drug and aggregation-enhanced two-photon absorbing fluorescent dye aggregates for two-photon photodynamic therapy. *J Am Chem Soc*. 2007;129:2669-2675.
 287. Rai P, Chang SK, Mai Z, Neuman D, Hasan T. Nanotechnology-based combination therapy improves treatment response in cancer models. *Proc SPIE*. 2009;7380:73801-73811.
 288. Berg K, Selbo PK, Prasmickaite L, et al. Photochemical internalization: a novel technology for delivery of macromolecules into cytosol. *Cancer Res*. 1999;59:1180-1183.
 289. Norum OJ, Selbo PK, Weyergang A, Giercksky KE, Berg K. Photochemical internalization (PCI) in cancer therapy: from bench towards bedside medicine. *J Photochem Photobiol B*. 2009;96:83-92.
 290. Selbo PK, Rosenblum MG, Cheung LH, Zhang W, Berg K. Multi-modality therapeutics with potent anti-tumor effects: photochemical internalization enhances delivery of the fusion toxin scFvMEL/rGel. *PLoS One*. 2009;4:e6691.