

Photodynamic Therapy of Actinic Keratosis With Topical 5-Aminolevulinic Acid

A Pilot Dose-Ranging Study

Edward W. Jeffes, MD, PhD; Jerry L. McCullough, PhD; Gerald D. Weinstein, MD; Peter E. Fergin, MD; J. Stuart Nelson, MD, PhD; Toni F. Shull, RN; Karen R. Simpson, MD; Lisa M. Bukaty, MD; Wendy L. Hoffman, MD; Nora L. Fong, MD

Objective: To examine the safety and efficacy of photodynamic therapy using topical 5-aminolevulinic acid (ALA) and red light to treat actinic keratoses (AKs).

Design: Actinic keratoses were treated with topical ALA (concentrations of 0%, 10%, 20%, or 30%) under occlusion for 3 hours. Before photodynamic therapy, sites were examined for fluorescence. Sites were irradiated with an argon pumped dye laser (630 nm) at fluences of 10 to 150 J/cm².

Setting: Academic medical center.

Patients: Forty patients with 6 clinically typical, previously untreated AKs per patient.

Main Outcome Measure: Complete resolution and decrease in lesion area of the AK relative to baseline evaluated at weeks 1, 4, 8, and 16.

Results: Three hours after ALA administration, lesions

showed moderate red fluorescence. Cutaneous phototoxic effects, localized erythema and edema, peaked at 72 hours. Patients experienced mild burning and stinging during light exposure. Eight weeks after a single treatment using 30% ALA, there was total clearing of 91% of lesions on the face and scalp and 45% of lesions on the trunk and extremities. No significant differences were observed in clinical responses with treatment using 10%, 20%, or 30% ALA. All concentrations of ALA were more effective than treating AKs with vehicle and light.

Conclusions: Topical photodynamic therapy with ALA is an effective treatment of typical AKs. Complete clearing of nonhypertrophic AKs can be achieved with 10%, 20%, or 30% ALA that is easily tolerated by the patient. Lesions on the face and scalp are more effectively treated than lesions on the trunk and extremities. Hypertrophic AKs did not respond effectively.

Arch Dermatol. 1997;133:727-732

From the Department of Dermatology (Drs Jeffes, McCullough, Weinstein, Fergin, Nelson, Simpson, Bukaty, Hoffman, and Fong and Ms Shull) and the Beckman Laser Institute (Dr Nelson), University of California, Irvine, and the Veterans Affairs Medical Center, Long Beach, Calif (Dr Jeffes).

THE APPLICATION of 5-aminolevulinic acid (ALA) topically on skin leads to the accumulation of the endogenous photosensitizer protoporphyrin IX (Pp IX) in epidermal cells. Conversion of ALA to Pp IX is accomplished in normal and neoplastic skin cells by enzymes in the heme pathway. Protoporphyrin IX is characterized by a bright orange-red fluorescence and can be visualized in the skin when illuminated with a UV lamp. The tissue-specific phototoxic effects resulting from the topical administration of exogenous ALA provide a basis for using ALA-induced Pp IX for photodynamic therapy (PDT).¹

Photodynamic therapy using topical ALA has been shown efficacious in the treatment of various superficial epithelial cutaneous malignant tumors including basal cell carcinoma

and squamous cell carcinoma in situ (Bowen disease).²⁻⁵ Topical PDT with ALA also has been reported useful for the treatment of actinic keratoses (AKs) (solar keratoses),^{1,3} but these studies have been done in only a small number of patients and have used a fixed concentration of ALA (20%) with filtered or unfiltered visible light from a slide projector. The purpose of this dose-ranging study was to determine the safety and clinical efficacy of topical ALA (10%, 20%, or 30% ALA concentration) vs vehicle control with visible red light delivered by laser for the PDT of AKs.

RESULTS

Thirty-nine of the 40 patients completed

Biofrontera Exhibit 1025
Biofrontera Inc. et al. v. DUSA Pharmaceuticals, Inc.
IPR2022-00056

Photodynamic Therapy of Actinic Keratosis With Topical 5-Aminolevulinic Acid

A Pilot Dose-Ranging Study

Edward W. Jeffes, MD, PhD; Jerry L. McCullough, PhD; Gerald D. Weinstein, MD; Peter E. Fergin, MD; J. Stuart Nelson, MD, PhD; Toni F. Shull, RN; Karen R. Simpson, MD; Lisa M. Bukaty, MD; Wendy L. Hoffman, MD; Nora L. Fong, MD

Objective: To examine the safety and efficacy of photodynamic therapy using topical 5-aminolevulinic acid (ALA) and red light to treat actinic keratoses (AKs).

Design: Actinic keratoses were treated with topical ALA (concentrations of 0%, 10%, 20%, or 30%) under occlusion for 3 hours. Before photodynamic therapy, sites were examined for fluorescence. Sites were irradiated with an argon pumped dye laser (630 nm) at fluences of 10 to 150 J/cm².

Setting: Academic medical center.

Patients: Forty patients with 6 clinically typical, previously untreated AKs per patient.

Main Outcome Measure: Complete resolution and decrease in lesion area of the AK relative to baseline evaluated at weeks 1, 4, 8, and 16.

Results: Three hours after ALA administration, lesions

showed moderate red fluorescence. Cutaneous phototoxic effects, localized erythema and edema, peaked at 72 hours. Patients experienced mild burning and stinging during light exposure. Eight weeks after a single treatment using 30% ALA, there was total clearing of 91% of lesions on the face and scalp and 45% of lesions on the trunk and extremities. No significant differences were observed in clinical responses with treatment using 10%, 20%, or 30% ALA. All concentrations of ALA were more effective than treating AKs with vehicle and light.

Conclusions: Topical photodynamic therapy with ALA is an effective treatment of typical AKs. Complete clearing of nonhypertrophic AKs can be achieved with 10%, 20%, or 30% ALA that is easily tolerated by the patient. Lesions on the face and scalp are more effectively treated than lesions on the trunk and extremities. Hypertrophic AKs did not respond effectively.

Arch Dermatol. 1997;133:727-732

From the Department of Dermatology (Drs Jeffes, McCullough, Weinstein, Fergin, Nelson, Simpson, Bukaty, Hoffman, and Fong and Ms Shull) and the Beckman Laser Institute (Dr Nelson), University of California, Irvine, and the Veterans Affairs Medical Center, Long Beach, Calif (Dr Jeffes).

THE APPLICATION of 5-aminolevulinic acid (ALA) topically on skin leads to the accumulation of the endogenous photosensitizer protoporphyrin IX (Pp IX) in epidermal cells. Conversion of ALA to Pp IX is accomplished in normal and neoplastic skin cells by enzymes in the heme pathway. Protoporphyrin IX is characterized by a bright orange-red fluorescence and can be visualized in the skin when illuminated with a UV lamp. The tissue-specific phototoxic effects resulting from the topical administration of exogenous ALA provide a basis for using ALA-induced Pp IX for photodynamic therapy (PDT).¹

Photodynamic therapy using topical ALA has been shown efficacious in the treatment of various superficial epithelial cutaneous malignant neoplasms, including basal cell carcinoma and

squamous cell carcinoma in situ (Bowen disease).²⁻⁵ Topical PDT with ALA also has been reported useful for the treatment of actinic keratoses (AKs) (solar keratoses),^{1,3} but these studies have been done in only a small number of patients and have used a fixed concentration of ALA (20%) with filtered or unfiltered visible light from a slide projector. The purpose of this dose-ranging study was to determine the safety and clinical efficacy of topical ALA (10%, 20%, or 30% ALA concentration) vs vehicle control with visible red light delivered by laser for the PDT of AKs.

RESULTS

Thirty-nine of the 40 patients completed the 16-week study. One patient voluntarily withdrew after 4 weeks because of a schedule conflict.

PATIENTS AND METHODS

PATIENT POPULATION

Forty patients (3 women and 37 men; median age, 70.5 years [range, 47-83 years]) with 6 AKs per patient were included in the study. A total of 218 lesions (grades 1-3) were evaluable at 8 weeks (grade 1, 78 lesions; grade 2, 118; and grade 3, 22). Of the 196 evaluable grade 1 and 2 lesions, 128 were on the trunk and extremities and 68 were on the face and scalp. Of the 22 grade 3 lesions, 21 were on the trunk and extremities and 1 was on the face or scalp. The largest diameter of the lesions ranged from 2 mm to 2.1 cm (median, 9 mm). Patients were excluded if they had received treatment of target AKs, or if they had used topical corticosteroids (previous 2 weeks); topical α -hydroxy acids or systemic corticosteroids (previous 4 weeks); or systemic retinoids, chemotherapeutic agents, or immunotherapy (previous 6 months). Pregnant or nursing women or patients with a history of cutaneous photosensitivity also were excluded. The study was approved by the University of California, Irvine, Human Subject Research Committee. Each patient received comprehensive information about the nature of the study and written informed consent was obtained before recruitment.

DRUG APPLICATION

Before application, ALA was admixed with a proprietary emollient vehicle (M55A, DUSA Pharmaceuticals Inc, Tarrytown, NY) to produce concentrations of 10%, 20%, and 30%. 5-Aminolevulinic acid test preparations at concentrations of 0%, 10%, 20%, or 30% were assigned to patients on a nonblinded basis. All 6 sites on a patient were treated with the same concentration of ALA. After applying ALA to target lesions and 10 to 20 mm of surrounding normal skin, test sites were covered with an adhesive, skin-colored, aluminized occlusive tape (3M Pharmaceuticals, St Paul, Minn) to prevent exposure to ambient light. Three hours after ALA application, immediately before assessment of fluorescence, the tape was removed and the area wiped to remove excess drug from the skin.

ASSESSMENT OF FLUORESCENCE

Immediately before light treatment, fluorescence of the treated lesions and surrounding normal skin was examined visually using a UV lamp (model B-100 AP, UVP, San Gabriel, Calif) containing a mercury flood lamp (model H-44 JM-100, Sylvania). Fluorescence intensity was scored as 0, none; 1, weak; 2, moderate; or 3, intense.

LIGHT TREATMENT

An argon pumped dye laser (model 920, Coherent Medical, Palo Alto, Calif) tuned to emit radiation at 630 ± 1 nm was used for the light treatments. A remote fiber splitter (model 1025, LaserTherapeutics, Buelton, Calif) permitted simultaneous laser irradiation of treatment sites. Each fiberoptic terminated in a microlens that focused the laser radiation onto a 2-cm-diameter circular field of uniform light intensity. Laser irradiation emanating from the fiber was

monitored with a power meter (model 210, Coherent Medical) before, during, and after treatment. The power density of the laser irradiation was gradually escalated (50, 100, 150 mW/cm²) in the first 10 patients to assess tolerance and safety. Because these patients easily tolerated all the power densities and there was no difference in patient tolerance at low and high power densities, the last 30 patients were treated using 150 mW/cm². Each of the 6 AKs on each patient were treated with 1 of the following fluences: 10, 25, 50, 75, 100, or 150 J/cm².

CLINICAL ASSESSMENT

Safety and clinical assessments were performed at baseline, immediately after PDT, and at 24 and 72 hours and at 1, 4, 8, and 16 weeks after PDT. Clinically typical AKs were selected by trained investigators as scaly erythematous papules and plaques devoid of cystic pores or a papillomatous surface (to exclude seborrheic keratosis and verrucae). Because having 6 lesions was required to enter the study, the patients had severe solar damage and had many AKs, of which only typical, easily evaluable lesions were selected. Lesions were clinically graded using criteria similar to those reported by Olsen et al,⁶ which were used to evaluate AKs treated with masoprocol cream. The criteria for each grade of AK are 1, easily seen, with slightly palpable hyperkeratosis (a thin AK); 2, easily seen and well-developed, easily palpated hyperkeratosis (typical well-developed AK); or 3, thick hyperkeratosis, evidence for thickened epidermis at margin of the AK, or both (hypertrophic or hyperkeratotic AK). The dimensions of the AK were measured and area ($\pi \times \frac{1}{2}$ length $\times \frac{1}{2}$ width) was calculated. Clinical response was defined as the percentage reduction of pretreatment lesion area and rated as complete response (CR), clear of palpable or visible lesion; partial response (PR), between 50% and 100% reduction in lesion area; or no response (NR), less than 50% reduction in lesion area. Lesions that did not have a CR at week 16 were treated with liquid nitrogen. Before and immediately after PDT and at each subsequent visit, treatment sites were evaluated for objective changes, including wheal-flare reactions (0, none; 1, minimal or barely perceptible; 2, moderate; and 3, severe), skin phototoxic effects (0, none; 1, minimal, asymptomatic erythema; 2, moderate erythema with pruritus or edema; 3, severe erythema with moderate to severe edema; and 4, skin ulceration). Subject assessment of patient discomfort from pain, burning and stinging, and itching was graded as 0, none; 1, slight; 2, moderate; 3, severe; or 4, very severe). Standard hematologic and biochemical laboratory values were evaluated at baseline and again at 1 week after PDT. Urine ALA was measured at baseline and at 24 hours after ALA application. Safety of the treatments was assessed by adverse events, the PDT response, and laboratory results.

The Student *t* test was used to compare quantitative variables. Summary statistics are expressed as mean \pm SD. Differences in clinical response between treatment variables were tested using the χ^2 test, or the Fisher test for small sample numbers. The Spearman rank order correlation was used to evaluate the relation between fluorescence, phototoxic effects, discomfort, and clinical response. Linear regression was used to evaluate the relation between response and light fluence administered.

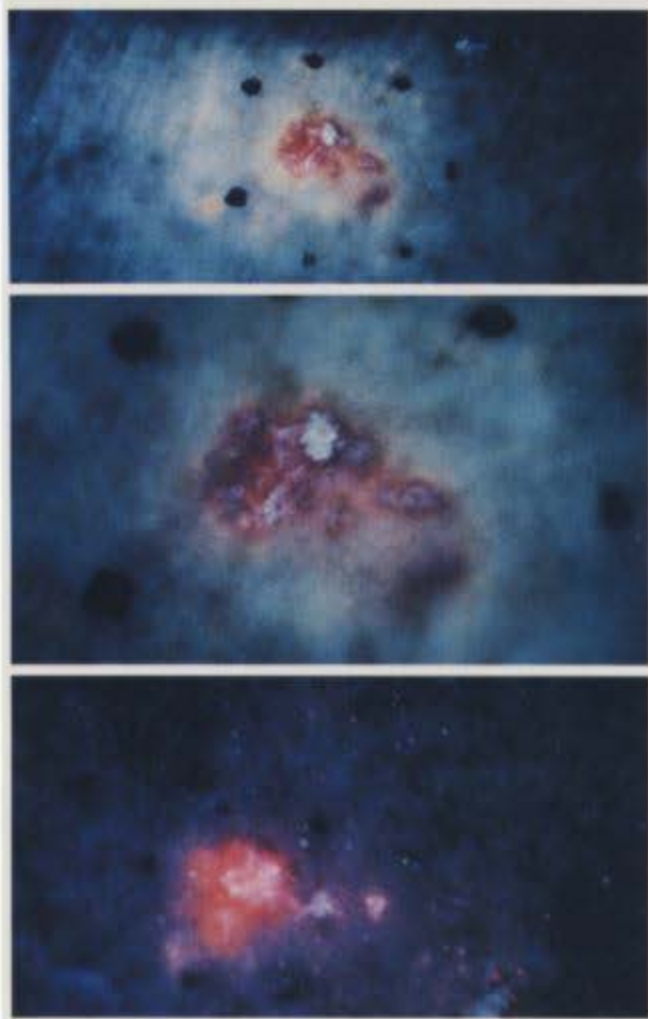


Figure 1. Actinic keratoses (AK) fluorescence after topical 5-aminolevulinic acid treatment. Top and center, Weak fluorescence of AK on extremity, with minimal fluorescence of adjacent normal skin. Bottom, More intense fluorescence of AK on scalp, with significant fluorescence of adjacent normal-appearing sun-damaged skin.

Pp IX FLUORESCENCE

Three hours of occluded application of ALA cream produced weak to moderate red fluorescence of grade 1 to 2 AKs at all concentrations of ALA. There was no significant difference between AKs treated with 10%, 20%, or 30% ALA. Thick, hyperkeratotic grade 3 AKs showed significantly less fluorescence. The surrounding normal-appearing sun-damaged skin treated with ALA showed a lesser degree of fluorescence. This selectivity was less pronounced on areas of the face and scalp, where both lesion and adjacent skin showed moderate fluorescence, with the AKs fluorescing brighter than the surrounding sun-damaged skin (**Figure 1**).

CLINICAL RESPONSE

The clinical response rate of grade 1 and 2 AKs and grade 3 AKs at 4, 8, and 16 weeks after PDT is shown in **Figure 2** and **Figure 3**, respectively. Maximum clinical improvement was obtained with treatment of grade 1 and 2 lesions with 30% ALA (61%, CR; 26%, PR). The clinical response of grade 1 and 2 AKs treated with 10%,

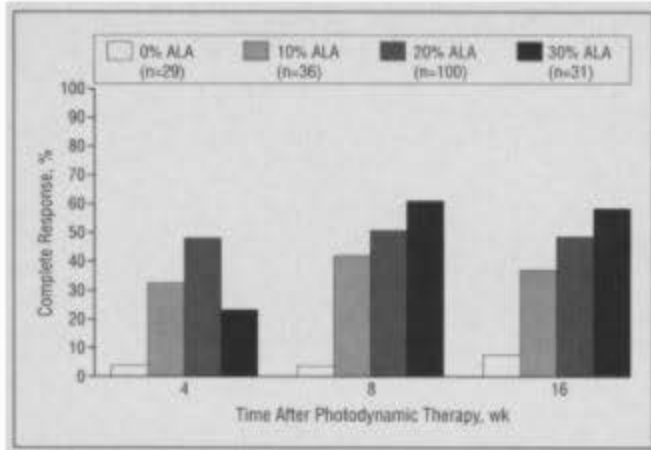


Figure 2. Response rate of all grade 1 and 2 (typical) actinic keratoses treated with 5-aminolevulinic acid (ALA) photodynamic therapy.

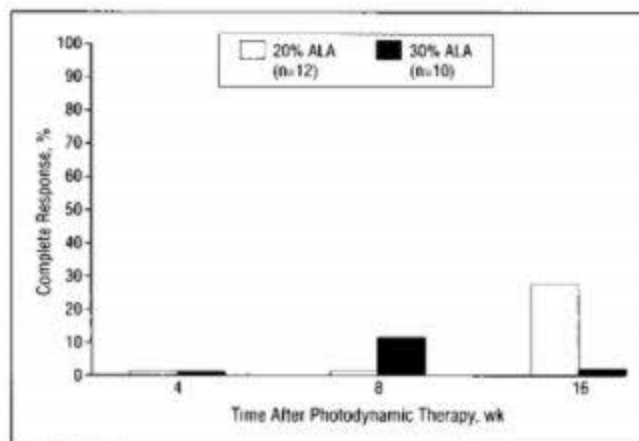


Figure 3. Response rate of all grade 3 (thick hyperkeratotic) actinic keratoses treated with 5-aminolevulinic acid (ALA) photodynamic therapy.

20%, or 30% ALA and light was significantly better than AKs treated with vehicle and light ($P < .001$). Thick, hyperkeratotic grade 3 AKs did not respond effectively to treatment with 20% or 30% ALA.

Actinic keratoses on the face and scalp responded significantly better to treatment with ALA and light compared with AKs treated on the trunk and extremities when 20% or 30% ALA was used to photosensitize the lesions ($P < .05$) (**Table 1**). The percentage of AKs on the face and scalp ($n=11$) treated with 30% ALA and light having a CR was 91%, while 45% of the AKs on the trunk and extremities ($n=20$) had a CR when treated identically ($P < .05$). The response distribution was not significantly different for AKs treated with 10% ALA and light when the face and scalp ($n=13$) was compared with trunk and extremities ($n=23$). The mean percentage improvement as measured by reduction in lesion area of face and scalp AKs was 90% to 99% vs 58% to 62% for trunk and extremity lesions treated with 10% to 30% ALA.

The CR rate of all grade 1 and 2 AKs treated with 20% ALA at fluences of 10 to 150 J/cm² is shown in **Figure 4**. Analysis of these data shows that a maximal CR rate was achieved at 10 J/cm², and this was not statistically different from the CR rate observed at 150 J/cm². Similarly, PDT with 20% ALA produced a maximum decrease in lesional area at 10 J/cm² and there was no in-

Table 1. Clinical Responses of Face and Scalp vs Trunk and Extremities Actinic Keratoses (Grades 1 and 2) at 8 Weeks After Photodynamic Therapy*

% ALA	Face and Scalp			Trunk and Extremities		
	CR	PR	NR	CR	PR	NR
0†	0	6 (46)	7 (54)	1 (6)	3 (19)	12 (75)
10†	8 (61)	4 (31)	1 (8)	7 (30)	8 (35)	8 (35)
20‡	24 (78)	6 (19)	1 (3)	26 (38)	24 (35)	19 (27)
30‡	10 (91)	1 (9)	0	9 (45)	7 (35)	4 (20)

*ALA indicates 5-aminolevulinic acid; CR, complete response; PR, partial response; and NR, no response. Data are presented as total number of actinic keratosis sites treated with designated response, with the percentage of actinic keratosis sites treated with designated response in parentheses.

†Response distribution on face and scalp is not different from trunk and extremities (Fisher exact test, $P > .05$).

‡Response distribution on face and scalp shows a significantly improved response when compared with trunk and extremities (χ^2 , Fisher exact test; $P < .05$).

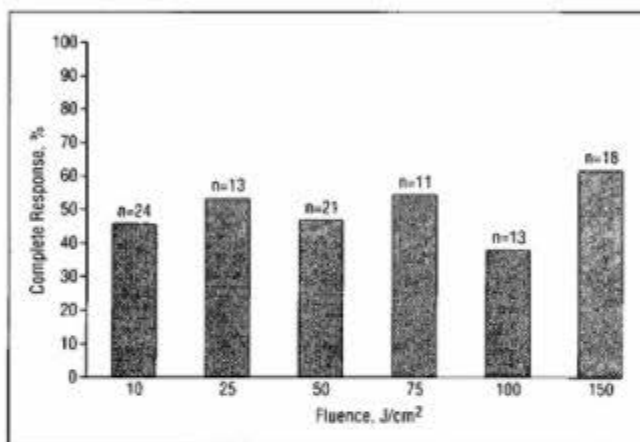


Figure 4. Complete response rate at 8 weeks of all grade 1 and 2 lesions treated with 20% 5-aminolevulinic acid (ALA) at fluences of 10 to 150 J/cm².

crease in effect with treatment at the higher fluences (10-150 J/cm²) (Student t test, $P > .05$). A further linear regression analysis showed a maximum effect on lesional area at 10 J/cm² that did not increase with fluences up to 150 J/cm² ($R^2 = 0.005$; $P = .48$). These data suggest that a maximal response had been reached at 10 J/cm² and that the response did not increase with higher light fluences up to 150 J/cm².

There was a significant correlation of AK fluorescence with improved clinical response (Table 2). There also was a significant correlation of fluorescence with increasing phototoxic effects on the AK and surrounding skin, but no correlation with subjective discomfort reported by the patient during light treatment.

The thicker grade 3 lesions did not respond well to PDT at any concentration of ALA compared with thinner typical grade 1 to 2 AKs. Because most of the grade 3 hypertrophic AKs treated in this study were on the extremities, we compared the response of grade 1 and 2 thin AKs with grade 3 thick AKs, limiting the AKs to the trunk and extremities treated with 20% ALA. Grade 1 and 2 AKs on the trunk and extremities decreased in area by $58\% \pm 62\%$ ($n = 68$), and grade 3 AKs in the same regions

Table 2. Correlation of Fluorescence and Phototoxic Effects With Clinical Variables in Grades 1 and 2 Actinic Keratoses Treated With 20% 5-Aminolevulinic Acid Photodynamic Therapy

Comparison*	Spearman Rank Order Correlation	P
Fluorescence vs clinical response	0.35	<.001
Fluorescence vs phototoxicity	0.28	.005
Fluorescence vs discomfort	-0.02	.78
Phototoxicity vs clinical response	0.24	.02

*See the "Patients and Methods" section for a description of the clinical scales used.

decreased in area by $24\% \pm 24\%$ ($n = 11$), a significant difference ($P < .05$). A similar nonparametric analysis of the same data showed that grade 1 and 2 AKs had 26 CR and 40 PR and NR, and grade 3 AKs had 0 CR and 11 PR and NR, again a significant difference ($P < .02$, Fisher exact test). Thus, thick AKs on the trunk and extremities do not respond as well as typical thinner AKs in the same region of the body. There were not enough thick hypertrophic AKs treated on the face and scalp to do a similar analysis on this site.

CLINICAL EFFECTS OF PDT

There were mild phototoxic effects on the ALA-treated sites, which were manifest by localized erythema and edema that peaked 72 hours to 1 week after PDT and resolved by week 4 (Figure 5). In general, the phototoxic effects on the treated adjacent sun-damaged skin were much less than on the AKs. Photodynamic therapy resulted in superficial erosion of many of the AKs without eroding surrounding normal skin.

All patients experienced mild to moderate discomfort during light treatment (Figure 6), which was manifest by burning and stinging at the treatment site that started and was most severe with the beginning of irradiation, decreased during the irradiation, and stopped immediately when the irradiation was terminated. The treatment was well tolerated by most patients. There was no observable difference in patient discomfort during or after light treatment at power densities ranging from 25 to 150 mW/cm². All patients but 1 were able to complete the light treatments at all fluences. A wheal-and-flare reaction developed immediately after treatment in 14% of the treated lesions (mean intensity, 1.4; scale, 0-3). The cosmetic results of the PDT were excellent, with lesions clearing without persistent pigmentary alterations or scarring (Figure 7). There were no clinically significant abnormalities in laboratory tests and no significant changes from baseline of urine ALA measured at 24 hours.

COMMENT

The results of this study show that PDT with a single treatment using topical ALA and visible red light is highly effective for the treatment of typical AKs (grade 1 and 2 in this study). A single topical application of 30% ALA for 3 hours followed by treatment with red light resulted in

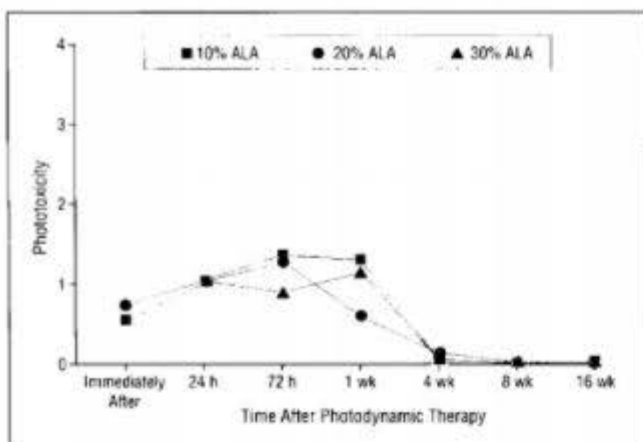


Figure 5. Cutaneous phototoxic effects of photodynamic therapy with 10%, 20%, and 30% 5-aminolevulinic acid (ALA). Phototoxic response was graded as 0, none; 1, mild (erythema); 2, moderate (erythema and edema); 3, severe (erythema and edema); and 4, necrosis of skin.

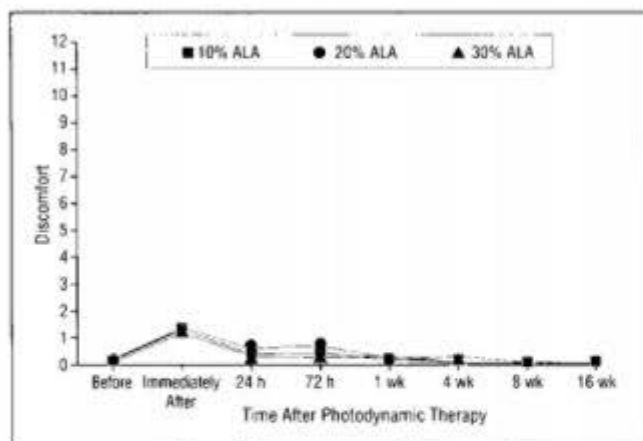


Figure 6. Subjective discomfort from photodynamic therapy with 10%, 20%, and 30% 5-aminolevulinic acid (ALA). The discomfort scale is composed of 3 components (pain, burning and stinging, and itching), each having a score of 0 to 4 (a total maximum score of 12). Discomfort was graded as 0, none; 1, mild; 2, moderate; 3, severe; and 4, very severe.

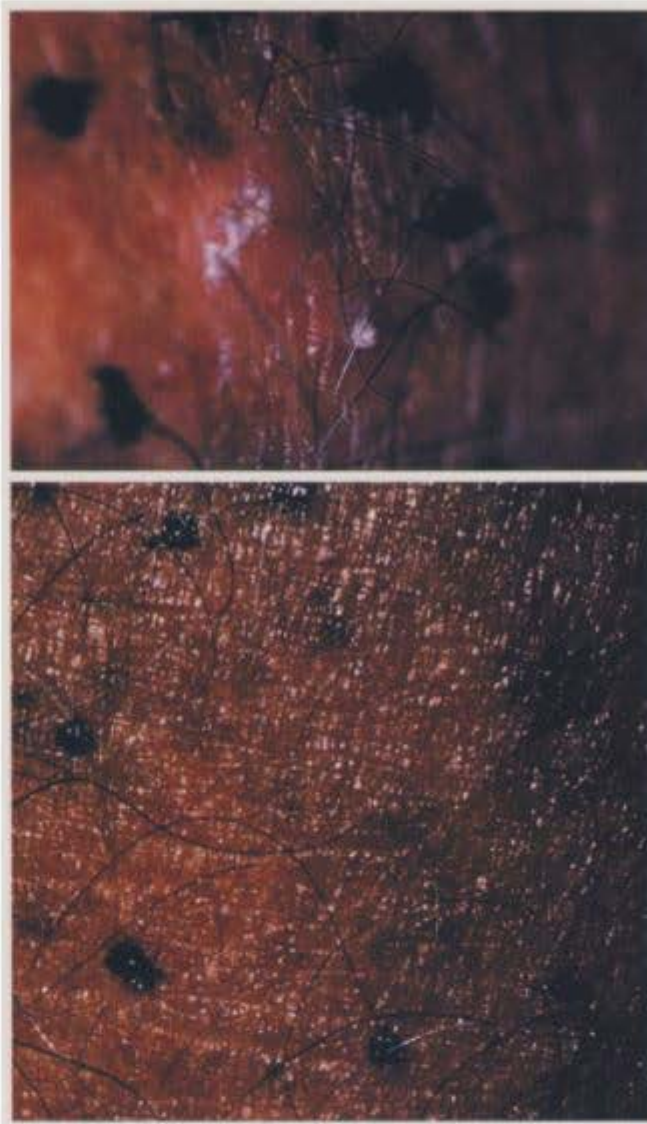

Figure 7. Typical clinical response of actinic keratoses shown before treatment (top) and 8 weeks after photodynamic therapy (bottom).

complete clearing of 61% of typical grade 1 and 2 AKs. The complete clearing response rates of grade 1 and 2 AKs treated with 10%, 20%, or 30% ALA (42%, 50%, and 61%, respectively) were significantly better than the 3% complete clearing of AKs treated with vehicle and red light. The patients' acceptance of the treatment regimen was good, as assessed by subjective measurements of discomfort and completion of all treatments. All patients reported discomfort during the light exposure but did not require local anesthesia, unlike that reported for treatment of deeper cutaneous tumors.^{3,4}

A significantly better response was seen for the treatment of AKs on the face and scalp with 20% or 30% ALA and light, compared with AKs on the trunk and extremities. There was complete resolution in 91% of face and scalp AKs treated with 30% ALA and light, but AKs at other sites (trunk and extremities) had only 45% CR.

Thick, hyperkeratotic lesions did not respond effectively to PDT. Even considering that most of the hypertrophic AKs were on the trunk and extremities, the response of the thick lesions was significantly less than the typical lesions. There was an inverse correlation of

fluorescence (ie, Pp IX production) after topical application of ALA with the grade of the AK. The hypertrophic AKs commonly did not fluoresce. This may be due to ineffective penetration of ALA and the consequent lack of conversion to Pp IX. With less Pp IX produced in the hypertrophic AK, a poor response rate would be expected.

Other topical therapies also are less effective in treating AKs on the extremities and thick hypertrophic AKs.^{7,8} Few studies have evaluated the response rate of AKs at sites other than the head and neck. Bercovitch⁹ reported a clinical trial treating AKs of the upper extremity with fluorouracil and achieved a CR rate of 78%. This response rate is similar to reports of fluorouracil therapy for the head and neck. In our experience (and in other reports), topical fluorouracil therapy of AKs on the extensor arms usually represents a more difficult therapeutic challenge than treating AKs on the head and neck.^{7,8} We also find it routinely necessary to use locally destructive techniques (aggressive use of liquid nitrogen, or curettage and electrodesiccation) to treat effectively hypertrophic AKs on the trunk and extremities.

The results of this study are consistent with previous observations of a good clinical response of typical AKs to PDT with ALA.^{1,3} Most PDT studies with porphyrin for treatment of cutaneous lesions have used red light because of deeper light penetration in human skin. In this study, we used a red laser light source to maximize the activation of the Pp IX at all levels of the skin and superficial dermis in an attempt to induce the greatest response of the AK and to maximize clinical cure rate. The laser light source used in this study supplied a pure light source that could be administered at high fluences. This light source obviously could not be used easily in the clinic. Various other light sources could theoretically be developed that are more clinically relevant. Because Pp IX has a maximum absorption at 410 nm (Soret band), shorter wavelengths may be effective in treating superficial AKs and have the advantage of reducing the light exposure times. Full-spectrum unfiltered visible light (400-700 nm) has been shown effective in the treatment of AK.³

The response rate of face and scalp AKs to topical PDT with ALA is similar to that reported for topical fluorouracil cream, masoprocol cream, chemical peels, or liquid nitrogen therapy. Lawrence et al¹⁰ reported a 75% CR rate of facial AKs treated with fluorouracil cream twice daily and tretinoin daily for 3 weeks. Pearlman¹¹ reported a 98% CR rate of facial AKs treated with fluorouracil cream once or twice weekly for 7 weeks. Masoprocol therapy of head and neck AKs twice daily for up to 28 days resulted in a 71% decrease in total number of treated AKs.⁶ Therapy of facial AKs with a Jessner solution and 35% trichloroacetic acid chemical peel resulted in a 75% CR rate evaluated 1 month after therapy.¹⁰ Lubritz and Smolewski¹² reported in a limited study of aggressive liquid nitrogen therapy of AK, a CR rate of 99% with a 1-year follow-up. In our study, therapy of facial AKs with 30% ALA and light resulted in a 91% CR rate 2 months after PDT.

Photodynamic therapy for the treatment of AKs may offer several advantages over conventional topical chemotherapy, chemical peels, or liquid nitrogen. Daily therapy with fluorouracil and masoprocol typically involves treatment that lasts for several weeks to achieve clinical efficacy. During this treatment interval, these therapies produce a notable amount of local erythema, crusting, and discomfort that may be unacceptable to patients.^{6,13} Weekly "pulse" dosing with topical fluorouracil has decreased the magnitude of erythema and eliminated most of the crusting, but still requires therapy for about 7 weeks.¹¹ Peels with Jessner solution and trichloroacetic acid may be an effective alternative therapy that is administered once and results in about a 2-week healing phase in which the cosmetic appearance may be compromised.¹⁰ Photodynamic therapy with ALA is similar to a peel and liquid nitrogen therapy in that it is accomplished with a single treatment and results in a 2-week healing phase. Photodynamic therapy with ALA may have the advantage of being more selective than chemical peels and liquid nitrogen in directing the maximal injury to the

AKs with relative sparing of the surrounding skin. This selectivity probably reflects more rapid conversion of ALA to Pp IX and a higher concentration of Pp IX in the AK compared with the surrounding skin. Photodynamic therapy with ALA has a similar cure rate to liquid nitrogen therapy. In conclusion, PDT with ALA of AKs may combine the selectivity of topical fluorouracil therapy with the advantage of single treatment of peels and liquid nitrogen therapy, and a cure rate similar to all the modalities discussed.^{6,9,12-14}

Accepted for publication December 5, 1996.

This study was supported in part by a grant from DUSA Pharmaceuticals Inc, and by grants 1R29 AR41638 and 1R01 AR42437 from the National Institutes of Health, Bethesda, Md (Dr Nelson).

Presented at the 55th National Meeting of the Society of Investigative Dermatology, Baltimore, Md, April 28, 1994, and the 15th Annual Meeting of the American Society for Laser Medicine, San Diego, Calif, April 2, 1995.

We acknowledge the consultation of Allyn Golub, PhD, Guidelines Inc, Miramar, Fla, and the assistance of Diane Moudy, Clinical Study Administrator.

Reprints: Edward W. Jeffes, MD, PhD, Department of Dermatology, C340 Medical Sciences, University of California, Irvine, Irvine, CA 92717.

REFERENCES

- Kennedy JC, Pottier RH. Endogenous protoporphyrin IX, a clinically useful photosensitizer for photodynamic therapy. *J Photochem Photobiol B*. 1992;6:275-292.
- Szeimies R-M, Sassy T, Landthaler M. Penetration potency of topical applied 5-aminolevulinic acid for photodynamic therapy of basal cell carcinoma. *Photochem Photobiol B*. 1994;59:73-76.
- Wolf P, Rieger E, Keri H. Topical photodynamic therapy with endogenous porphyrins after application of 5-aminolevulinic acid. *J Am Acad Dermatol*. 1993;28:17-21.
- Cairnduff F, Stringer MR, Hudson EJ, Ash DV, Brown SB. Superficial photodynamic therapy with topical 5-aminolevulinic acid for superficial primary and secondary skin cancer. *Br J Cancer*. 1994;69:605-608.
- Svanberg K, Andersson T, Killander D, et al. Photodynamic therapy of non-melanoma malignant tumours of the skin using topical 5-aminolevulinic acid sensitization and laser irradiation. *Br J Dermatol*. 1994;130:743-751.
- Olsen EA, Abernethy L, Kulp-Shorten C, et al. A double-blind vehicle-controlled study evaluating masoprocol cream in the treatment of actinic keratoses on the head and neck. *J Am Acad Dermatol*. 1991;24:738-743.
- Dillaha CJ, Jansen GT. Further studies with topical 5-fluorouracil. *Arch Dermatol*. 1965;92:410-417.
- Robinson TA, Kligman AM. Treatment of solar keratoses of the extremities with retinoic acid and 5-fluorouracil. *Br J Dermatol*. 1975;92:703-705.
- Bercovitch L. Topical chemotherapy of actinic keratoses of the upper extremity with tretinoin and 5-fluorouracil: a double-blind controlled study. *Br J Dermatol*. 1987;116:549-552.
- Lawrence N, Cox SE, Cockerell CJ, Freeman RG, Cruz PD. A comparison of the efficacy and safety of Jessner's solution and 35% trichloroacetic acid vs 5% fluorouracil in the treatment of widespread facial actinic keratoses. *Arch Dermatol*. 1995;131:176-181.
- Pearlman L. Weekly pulse dosing: effective and comfortable topical 5-fluorouracil treatment of multiple facial actinic keratoses. *J Am Acad Dermatol*. 1991;25:665-667.
- Lubritz RR, Smolewski SS. Cryosurgery cure rate of actinic keratosis. *J Am Acad Dermatol*. 1982;7:631-632.
- Goette DK. Topical chemotherapy with 5-fluorouracil. *J Am Acad Dermatol*. 1981;4:633-639.
- Dillaha CJ, Jansen GT, Bradford AC. Selective cytotoxic effect of topical 5-fluorouracil. *Arch Dermatol*. 1963;88:247-256.