

Topical ALA-Photodynamic Therapy for the Treatment of Acne Vulgaris

Wichai Hongcharu, Charles R. Taylor, Yuchiao Chang,* David Aghassi, Kittisak Suthamjariya, and R. Rox Anderson

Massachusetts General Hospital, Wellman Laboratories of Photomedicine, Departments of Dermatology and *Medicine, Harvard Medical School, Boston, Massachusetts, U.S.A.

Topical aminolevulinic acid is converted into a potent photosensitizer, protoporphyrin, in human hair follicles and sebaceous glands. Photodynamic therapy with topical aminolevulinic acid was tested for the treatment of acne vulgaris, in an open-label prospective human study. Each of 22 subjects with acne on the back was treated in four sites with aminolevulinic acid plus red light, aminolevulinic acid alone, light alone, and untreated control. Half of the subjects were treated once; half were treated four times. Twenty percent topical aminolevulinic acid was applied with 3 h occlusion, and 150 J per cm² broad-band light (550–700 nm) was given. Sebum excretion rate and auto-fluorescence from follicular bacteria were measured before, and 2, 3, 10, and 20 wk after, treatment. Histologic changes and protoporphyrin synthesis in pilosebaceous units were observed from skin biopsies. Aminolevulinic acid plus red light caused a transient acne-like folliculitis. Sebum excretion was eliminated for several weeks, and decreased for 20 wk after photodynamic therapy;

multiple treatments caused greater suppression of sebum. Bacterial porphyrin fluorescence was also suppressed by photodynamic therapy. On histology, sebaceous glands showed acute damage and were smaller 20 wk after photodynamic therapy. There was clinical and statistically significant clearance of inflammatory acne by aminolevulinic acid plus red light, for at least 20 wk after multiple treatments and 10 wk after a single treatment. Transient hyperpigmentation, superficial exfoliation, and crusting were observed, which cleared without scarring. Topical aminolevulinic acid plus red light is an effective treatment of acne vulgaris, associated with significant side-effects. Aminolevulinic acid plus red light causes phototoxicity to sebaceous follicles, prolonged suppression of sebaceous gland function, and apparent decrease in follicular bacteria after photodynamic therapy. Potentially, aminolevulinic acid plus red light may be useful for some patients with acne. *J. Invest Dermatol* 115:183–192, 2000

Acne vulgaris is a skin disease affecting more than 80% of young people. *Propionibacterium acnes* and sebum secretion play major roles in the pathogenesis of acne. Topical and systemic antibiotics are mainstays for treatment of acne, but the success rate varies in part due to the gradual resistance to antibiotics. Sun exposure has a well-known beneficial effect on acne, which is not the case for ultraviolet exposure (Sigurdsson *et al*, 1997). Studies show that the bacteria produce porphyrins as a by-product of their metabolism. Visible light is known to activate the porphyrins, inducing a photodynamic reaction that subsequently kills the pathogenic bacteria (Kjeldstad, 1984). Furthermore, photodynamic reactions can kill all strains of bacteria (Soukos *et al*, 1998).

Photodynamic therapy (PDT) with topical aminolevulinic acid (ALA) has been used to treat nonmelanoma skin cancer, actinic keratoses, and psoriasis (Szeimies *et al*, 1996). Topically applied

ALA is taken up by epithelial cells and metabolized via the porphyrin pathway to protoporphyrin IX (PpIX), the precursor of heme (Kappa *et al*, 1989; Iinuma *et al*, 1994). PpIX is a photosensitizer that accumulates not only in the epidermal cells but also in the pilosebaceous units (Divaris *et al*, 1990; Kennedy and Pottier, 1992). When intense visible light is delivered on the ALA-treated skin, PpIX is excited into a triplet state, which reacts with oxygen to produce singlet oxygen, causing membrane damage and cell destruction. Topical ALA may directly enter hair follicles, where sebaceous glands actively synthesize and retain PpIX. We conducted this pilot study to test the hypothesis that photodynamic destruction of *P. acnes*, sebaceous glands, or both would occur in human skin, improving acne vulgaris.

MATERIALS AND METHODS

Subject selection Twenty-two subjects of both sexes with mild to moderate acne vulgaris (grades 1–4) (Burke and Cunliffe, 1984) on their backs were enrolled between October 1998 and March 1999. People were excluded if they had used any topical acne treatment, systemic antibiotics in the past 2 wk, or systemic retinoids in the past year. People were also excluded who were using medication that may exacerbate or alleviate acne, who were planning to have excessive sunlight exposure, who had a history of keloid or photosensitivity disorder, or who had Fitzpatrick's skin phototype V–VI; pregnant and lactating women were also excluded.

Manuscript received December 15, 2000; revised April 18, 2000; accepted for publication May 8, 2000.

Reprint requests to: Dr. R. Rox Anderson, Wellman Laboratories of Photomedicine, Massachusetts General Hospital, BHX 630, 50 Blossom Street, Boston, MA 02114. Email: andersonr@helix.mgh.harvard.edu

Abbreviations: ALA, aminolevulinic acid; PDT, photodynamic therapy; PpIX, protoporphyrin IX; SO, sebum output.

Table I. Subject characteristics in both groups

	Single-treatment group	Multiple-treatment group
Age (y, mean + SD)	30 + 8.74	27 + 4.56
Gender (M/F)	9/2	8/3
Skin phototype	Type I 9.1%, Type II 27.3% Type III 54.5%, Type IV 9.1%	Type I 18.2%, Type II 36.4% Type III 27.3%, Type IV 18.2%
Disease history (y, mean + SD)	11.45 + 8.38	11.27 + 4.24
Previous systemic antibiotic treatment (number of subjects)	3 (27%)	4 (36%)
Previous topical antibiotic treatment (number of subjects)	3 (27%)	4 (36%)
Previous systemic isotretinoin treatment (number of subjects)	3 (27%)	2 (18%)
Number of baseline comedones (median, range)	3.0, 30	3.5, 34
Number of baseline inflammatory comedones (median, range)	3.0, 41	2.5, 17
Number of baseline papules (median, range)	4.5, 22	6.5, 33
Number of baseline pustules (median, range)	0.0, 3	0.0, 2
Number of baseline nodules (median, range)	0.0, 3	0.5, 13
Number of baseline cysts (median, range)	0.0, 0	0.0, 0

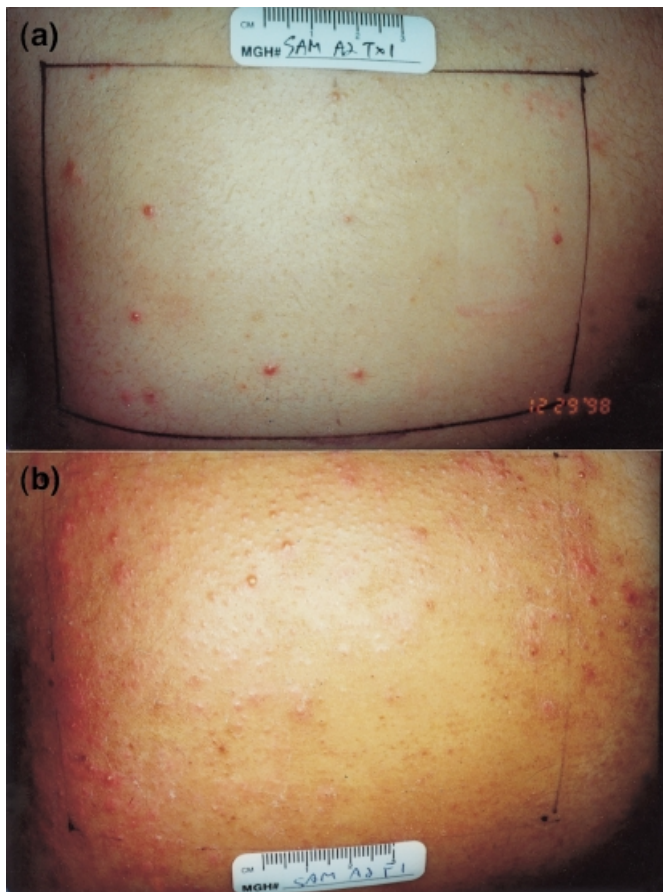


Figure 1. Transient acneiform eruption caused by a single PDT treatment. (a) Baseline; (b) one week post-treatment.

Study design Subjects were randomly divided into single-treatment and multiple-treatment groups. Each patient's back was equally divided into four 7.5×10 cm areas for ALA plus red light (ALA-PDT), ALA alone, light alone, and untreated control. Sites were marked with templates to precisely relocate each test area. At baseline, clinical evaluations, natural bacterial porphyrin fluorescence photography, and sebum output (SO) evaluation were performed. Before application of ALA, the skin was cleaned with 70% isopropyl alcohol. Then, 20% topical ALA in a hydroalcoholic vehicle (Levulan, DUSA Pharmaceuticals) was applied for 3 h under occlusion with plastic film (Saran wrap), and 150 J per cm^2 broadband light (550–700 nm) was given to the ALA-PDT and light alone areas.

In the multiple-treatment group, subjects were treated once a week for four consecutive weeks. In this group, if severe exfoliation, erosions, or purpura occurred, treatment was postponed to the following week. In both groups, subjects returned 1 wk after treatment for clinical evaluation and at weeks 2, 3, 10, and 20 for clinical, fluorescence, and SO evaluations.

Clinical evaluations Each subject's acne was visually assessed using an inflammatory acne score modified from that previously described (Michaelsson *et al*, 1977). The modification we used in this study accounted for both number and size of acne lesions. The numbers of comedones, inflammatory comedones, papules, pustules, nodules, and cysts in each test area were recorded. Each type of lesion was given a severity index as follows: 0.5 for comedo (<1 mm), 0.75 for inflammatory comedo, 1 for papule (1–5 mm), 2 for pustule, 3 for nodule (>5 mm), and 4 for inflammatory cyst.

Clinical improvement was globally assessed by three dermatologists unaware of the status of treatment, who blindly graded changes in acne from fixed-magnification clinical photographs, after being shown a small set of standardized series of training slides not used in the data evaluation. The grading scale was defined as -3 for $>50\%$ exacerbation, -2 for $25\%+$ – 50% exacerbation, -1 for $1\%+$ – 25% exacerbation, 0 if unchanged, 1 for $1\%+$ – 25% improvement, 2 for $25\%+$ – 50% improvement, 3 for $50\%+$ – 75% improvement, 4 for $75\%+$ – 99% improvement, and 5 for 100% improvement, compared with the baseline.

Fluorescence photography A Nikon E2N digital camera body with a Nikon 105 mm macro lens was used. A filter (Corion LL-550S) was placed on the lens to block light below 550 nm. The excitation light source was composed of two synchronized photoflashes with Norman 400 W s lampheads (FT400/FT6), mounted on a stationary tower with angles of incidence of 60° bilaterally. Two 400 nm bandpass filters with 5 nm bandwidth (Corion S40–400S) were placed on the flashes. By this method, the punctate orange-red fluorescence of hair follicles populated with *P. acnes* was seen (Lucchina *et al*, 1996). Fluorescence emission has been attributed to bacterial coproporphyrin III and protoporphyrin IX (Cornelius and Lugwig, 1967; Lucchina *et al*, 1996), and intensity of fluorescence is related to the *P. acnes* population (Cornelius and Lugwig, 1967; Lucchina *et al*, 1996). Fluorescence photography was performed at weeks 0, 2, 3, 10, and 20 in all sites. The number of punctate red fluorescent dots was counted blindly for each test area.

SO measurement Sebum-absorbent tape (Sebutapes, CuDerm, Dallas, TX) is a noninvasive, easy, and reproducible method to evaluate human SO (Pagnoni *et al*, 1994a). The subject's skin was shaved and then cleansed for 15 s with cotton pads soaked in 70% ethanol. When the skin was completely dry, a strip of Sebutape was adhered to each test site for an hour. After removal from the skin, the white tape was placed on a black card for image analysis. Small transparent spots due to sebum excretion from follicles were visualized as a black spot on the white background. A CCD camera and digital frame grabber were used to capture images of the Sebutape, which were then examined using a computer-assisted image analysis (IP-LAB) system. The percentage of Sebutape area covered by sebum spots (black) was calculated. We considered the percentage area covered by the spot as the relevant measure of SO (Pagnoni *et al*, 1994a). The percentage

area correlates directly with the SO (Pierard, 1987). Sebupte assays of SO were done this way, at weeks 0, 2, 3, 10, and 20, in all sites.

Adverse effects Adverse effects were scored by clinical evaluation of erythema, edema, loss of epidermis, hyperpigmentation, hemorrhage, vesiculation, and exfoliation on a visual analog scale from 0 to 3 (0 = absent, 1 = mild, 2 = moderate, 3 = severe) for each finding. Subjective sensation of pain, burning, and itching was generally maximum about 10 min into light exposure, and was ranked at that time and at the end of treatment (1 h) by subjects on a scale from 0 to 3 similar to above.

Histologic examination Punch biopsy specimens (4 mm) were taken immediately after PDT, a few weeks after PDT, and at 20 wk, from both the untreated control and ALA-PDT areas. Specimens were sectioned in either vertical or horizontal fashion and stained with hematoxylin and eosin, Fontana-Masson, and Masson-trichrome stains. Histologic examination was performed. Cross-sectioned areas of sebaceous glands, representative sebocytes, and the sebocyte nuclear area were measured from planimetric analysis of serial sectioned specimens of the skin using a computer-assisted planimetry system (Weissmann *et al*, 1984). To minimize the variation of sebaceous gland and sebocyte areas due to huge differences in cross-section and to provide a representative estimate of sebaceous gland and sebocyte areas, the largest sebaceous area of each follicle and largest sebocytes near the center of follicles from each serial sectioned specimen were measured. The area of sebaceous gland and the cytoplasm/nuclear area ratio in sebocytes were calculated and compared between control and PDT areas at each follow-up. To determine the level of *PpIX* converted from ALA in the pilosebaceous units, punch biopsy specimens were also taken from ALA-treated areas after 3 h occlusion as described above. A series of horizontal cross-sections of fresh-frozen specimens was obtained, and localization of *PpIX* production was noted by fluorescence microscopy.

Histologic examinations were performed to get a qualitative picture of reactions to PDT. A total of 15 specimens were obtained. Eight biopsies of PDT-treated areas were taken with accompanying specimens from the nontreatment area: four from multiple PDT-treated areas at follow-up 5, one from a multiple PDT-treated area at follow-up 3, one from a single PDT-treated area immediately after PDT, one from a single PDT-treated area at follow-up 3, and one from a single PDT-treated area at follow-up 5. Seven biopsies were obtained without an accompanying specimen from control areas, and were analyzed for morphologic changes due to PDT: two from single PDT-treated areas immediately after PDT, one from an acneiform lesion appearing 3 d after PDT, one from a single PDT-treated area at follow-up 2, one from a single PDT-treated area at follow-up 5, and one from a multiple PDT-treated area at follow-up 3.

Statistical analysis Treatment effects were determined based on the following analyses: (1) comparing the scores from each follow-up visit to the baseline scores using paired *t* tests; (2) comparing the change from baseline among the four treatment sites using paired *t* tests; (3) comparing the change from baseline between the single-treatment and multiple-treatment groups using two-sample *t* tests; and (4) comparing the change from baseline between the single-treatment and multiple-treatment groups using a repeated measures analysis to combine data from all follow-up visits. Statistical significance was defined as a *p*-value of less than 0.05.

RESULTS

Of the 23 subjects enrolled, 22 (17 males and five females) completed the study. One was dropped from the study because his asthma necessitated systemic steroid treatment, which is one of the exclusion criteria. The age of patients completing the study ranged from 18 to 44 y. Characteristics of the subjects in both groups are shown in **Table I**.

An impressive, acute eruption of inflammatory acneiform lesions was observed in the ALA-PDT sites only, in all patients (100%) in both groups, starting approximately 3–4 d post-treatment (**Fig 1**). The induced lesions were papules, pustules, and nodules that lasted for 4 d to 3 wk in the single-treatment group. In the multiple-treatment group, subsequent treatments induced progressively less inflammatory acne, such that almost no new acneiform lesions were observed after treatment 4.

Inflammatory acne score (Figs 2a and 3)

Single-treatment group Only the area treated with PDT showed improvement in acne, which was statistically significant starting

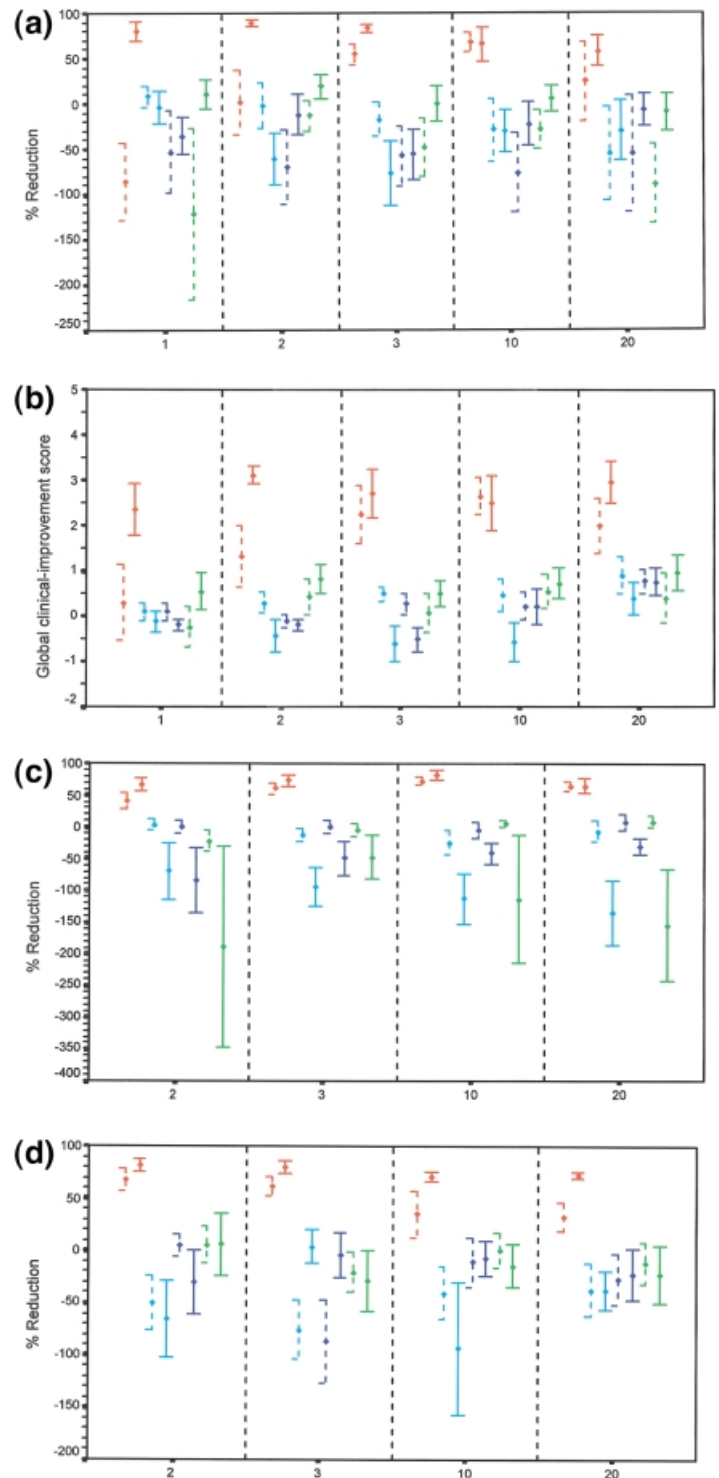


Figure 2. The mean improvement (+SEM) by treatment sites, treatment groups, and follow-up visits. (a) Reduction in inflammatory acne score; (b) global clinical-improvement grading; (c) reduction in autofluorescence of follicles, related to *P. acnes*; (d) reduction in sebum excretion rate. — —, single treatment group; —, multiple treatment group; red, PDT; blue, untreated; deep blue, light alone; green, ALA alone.

3 wk after treatment. The other three areas (ALA alone, light alone, untreated) showed slightly worse acne not significantly different from baseline, for all visits. When comparing the change from baseline between the area treated with single PDT and the other three areas, the differences were statistically significant at 3, 10, and 20 wk.

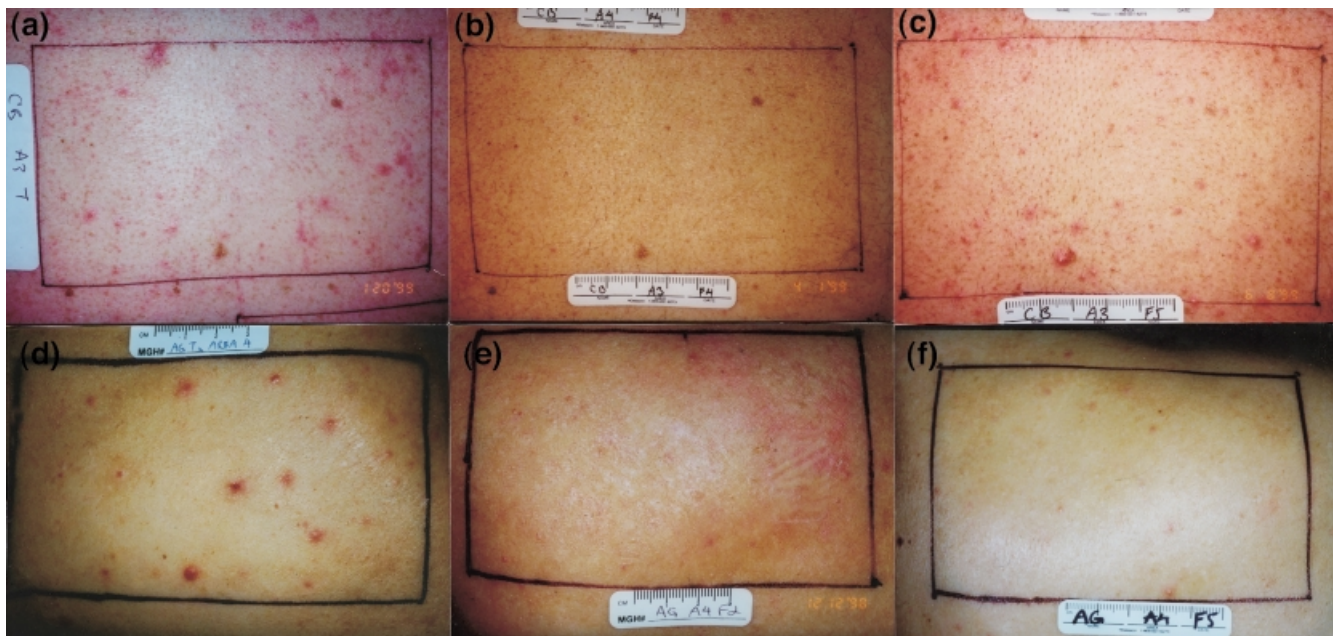


Figure 3. Inflammatory acne improved by a single PDT treatment. (a) Baseline. (b) Ten weeks post-PDT. (c) Acne starts to resume 20 wk after PDT. Long-term remission of acne after multiple PDT treatments. (d) Baseline. (e) Two weeks post-PDT (an irritation reaction to Sebuptape is seen on the right-hand side in this subject). (f) Twenty weeks post-PDT.

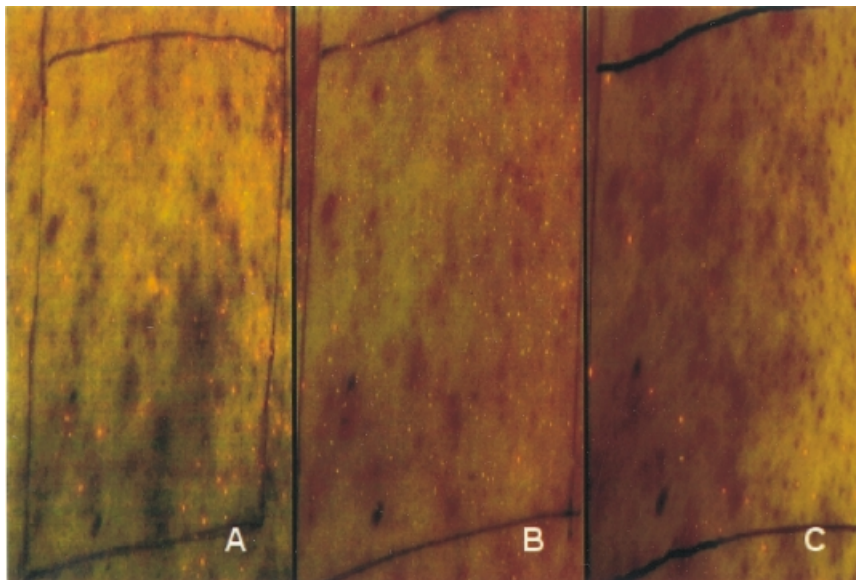


Figure 4. Fluorescence of porphyrin from bacteria in follicles (red dots) decrease after a single PDT. Photographs were taken as described at baseline (A), week 3 (B), and week 20 (C) post-PDT.

Multiple-treatment group There was obvious and statistically significant improvement in acne at all follow-up visits after multiple PDT treatment. There was no improvement in ALA-alone, light alone, or untreated sites. Change from baseline was significantly greater at sites of multiple PDT compared with the other three sites for all visits ($p < 0.05$). At visit 2 only (week 2), there was a barely significant improvement in the area treated with ALA alone compared with the untreated area ($p = 0.046$).

Comparison between single- and multiple-treatment groups The multiple PDT treatment group showed significantly more improvement than the single PDT treatment group at the first three follow-up visits. This difference diminished after week 3. No significant differences between the multiple- and single-treatment groups were observed in the non-PDT sites with respect to each individual visit. When data from all follow-up visits were combined, the

multiple PDT and multiple ALA alone treatment sites showed more improvement than the single-treatment group ($p < 0.001$ and $p = 0.007$, respectively).

Global clinical-improvement score (Fig 2b)

Single-treatment group The PDT site showed significant global improvement starting week 3 and extending through week 20. The area without treatment, and the area treated with light alone, also showed improvement reaching statistical significance at weeks 3 and 20 ($p = 0.017$ and 0.018 , respectively). The difference between PDT and the other three treatment sites was statistically significant at weeks 3 and 10.

Multiple-treatment group Significant improvement for the PDT treated area was observed starting visit 1 (week 1) and this

Figure 5. Sebum excretion is suppressed by a single PDT, then gradually recovers. (A) At baseline, (B) week 2 post-PDT, (C) week 10 post-PDT, (D) week 20 post-PDT.

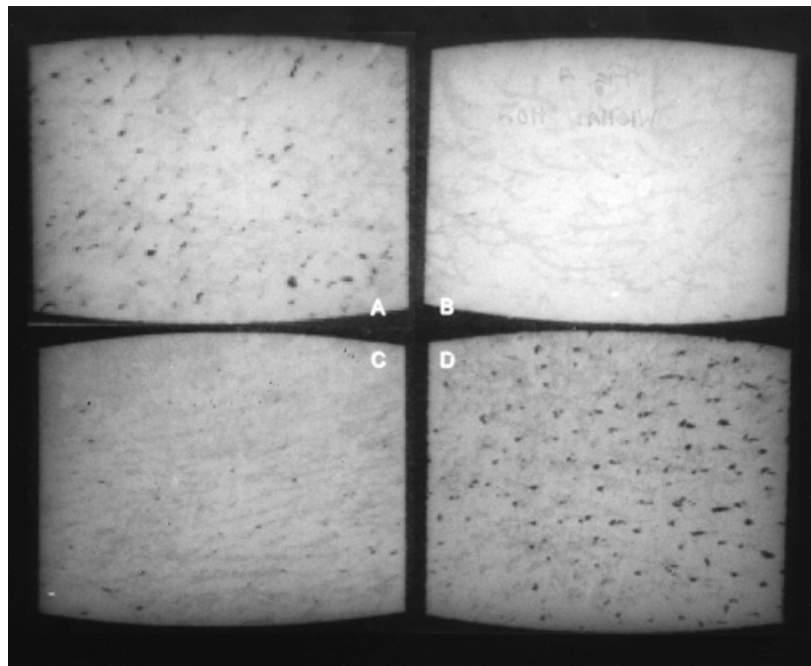
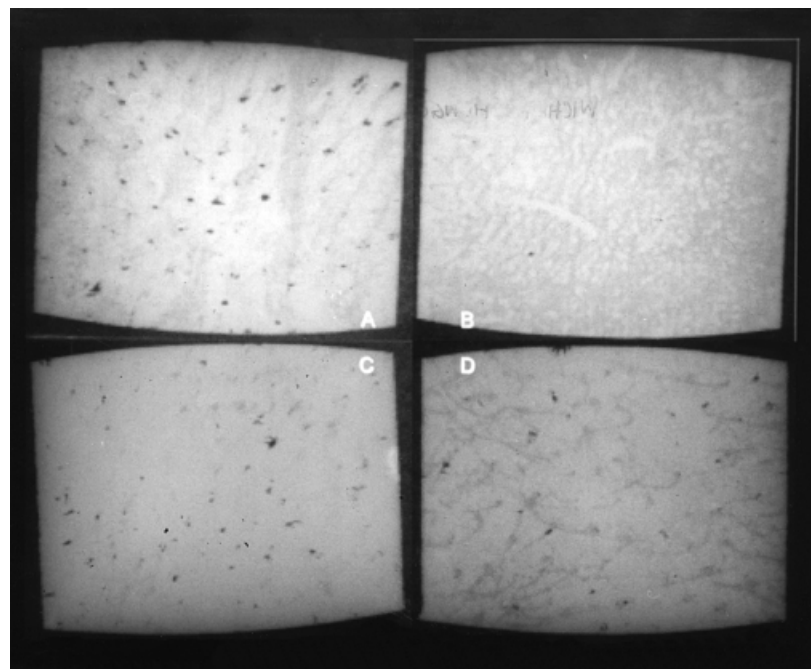


Figure 6. Sebum excretion remains suppressed after multiple PDT treatments, for at least 20 wk. (A)–(D) as in Fig 5 above.



improvement persisted throughout all the four follow-up visits (up to 20 wk at least). The area treated with ALA alone at visit 2 and the area treated with light alone or ALA alone at visit 5 also showed improvement reaching statistical significance. There was significantly more improvement, however, in the PDT treated site than the other three sites, at all follow-up visits.

Comparison between single- and multiple-treatment groups The multiple PDT treatment group showed significantly more improvement than the single PDT treatment group when evaluated at the first two follow-up visits (weeks 1 and 2). The single-treatment group did not have significantly more acne improvement than multiple treatment, at any time. When data from all follow-up visits were combined, the comparison between single PDT and multiple PDT reached statistical significance ($p = 0.008$).

Fluorescence photography evaluation (Figs 2c and 4)

Single-treatment group Only the PDT treated sites showed significant loss of fluorescence related to *P. acnes*, which lasted for all four follow-up visits. The differences between PDT and the other three test sites were also statistically significant for all visits.

Multiple-treatment group Again, only the PDT sites showed significant loss of *P. acnes* fluorescence, starting at follow-up visit 2. The sites treated with ALA alone or untreated had significantly greater fluorescence than baseline, at weeks 10 and 20. The differences between the PDT area and the other three test sites were statistically significant for all visits.

Comparison between single- and multiple-treatment groups The group treated four times with PDT had more, but not significantly more,

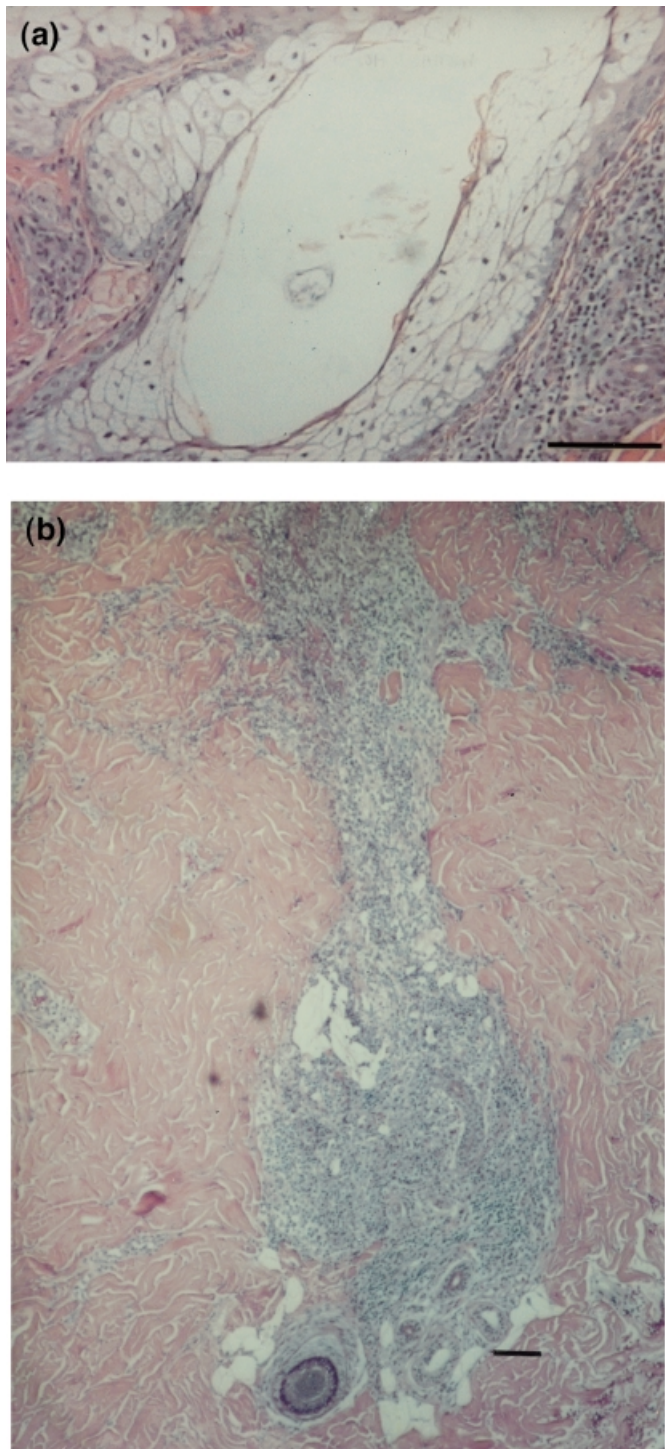


Figure 7. Retiform degeneration of sebocytes and intense mixed neutrophil-predominant infiltrate. (a) Sebocytes; (b) intense mixed neutrophil-predominant infiltrate. The biopsies were taken immediately after a single PDT treatment. Scale bars: 100 μ m.

improvement than that treated with single PDT. Combining data from all visits, the difference in fluorescence related to *P. acnes* between single- and multiple-treatment groups still did not reach statistical significance ($p = 0.081$).

SO (Figs 2d, 5, and 6)

Single-treatment group Only the area treated with PDT showed a significant decrease in SO, which was at weeks 2, 3, and 20. The

SO in the area treated with PDT was also significantly lower than any other test sites, at each follow-up visit.

Multiple-treatment group The PDT sites showed significant decrease in SO, at all follow-up visits. The differences between the area treated with PDT and the other three areas were also statistically significant at all four visits.

Comparison between single- and multiple-treatment groups Multiple PDT suppressed SO more than single PDT; however, the difference was significant only at the longest follow-up time, 20 wk. When data from all follow-up visits were combined, multiple PDT caused far lower SO than single PDT ($p = 0.001$).

Histology Marked focal histologic changes in pilosebaceous glands were observed in all samples treated by PDT. In the control (untreated) biopsy specimens, all subjects had well-developed sebaceous gland with typical round or oval lobules. Immediately after PDT, there was a mixed, neutrophil-predominant infiltrate along pilosebaceous units and perivascular area, and retiform degeneration of sebocytes (Fig 7). There was an apparent reduction of sebaceous gland size, with a mean decrease of 40% immediately after PDT. Epidermal changes were also observed with epidermal necrosis, vacuolization of keratinocytes from the mid stratum spinulosum to the stratum granulosum, and neutrophilic exocytosis. At 3 d after PDT, the acneiform lesions induced by PDT showed large intraepidermal pustules, disruption of hair follicles, and frank sebaceous gland destruction replaced by a mixed, neutrophil-predominant dermal infiltrate (Fig 8).

Reduction of sebaceous gland size compared with the untreated control area was observed 3 wk after both single and multiple PDT (30% vs 55%). Focal vacuolization of sebocytes (Fig 9), granulomatous reaction, and perifollicular fibrosis were also observed, although some of the sebaceous glands had regained a normal morphology with smaller size relative to control. Cytoplasm/nuclear cross-section area ratio in sebocytes was reduced, relative to nontreatment, by 38% and 56% in single and multiple PDT, respectively.

In the multiple-treatment group, improvement continued longer into the follow-up period, such that by the end of the study (20 wk after the last treatment), reduction of sebaceous gland size and sebocyte cytoplasm/nuclear area were 45% (range from 15% to 80%) and 46% (range from 39% to 53%), respectively. At 20 wk after multiple PDT treatments, there was complete destruction or marked atrophy of sebaceous gland lobules, with comparatively few sebocytes present (Fig 10a). Frequently, a granulomatous reaction composed of multinucleated giant cells and histiocytic infiltrates was seen at the remnant of destroyed sebaceous glands (Fig 10b). Perifollicular fibrosis (Fig 10c), inflammation, and spongiosis were seen occasionally, but these findings were not constant. The epidermis appeared completely normal.

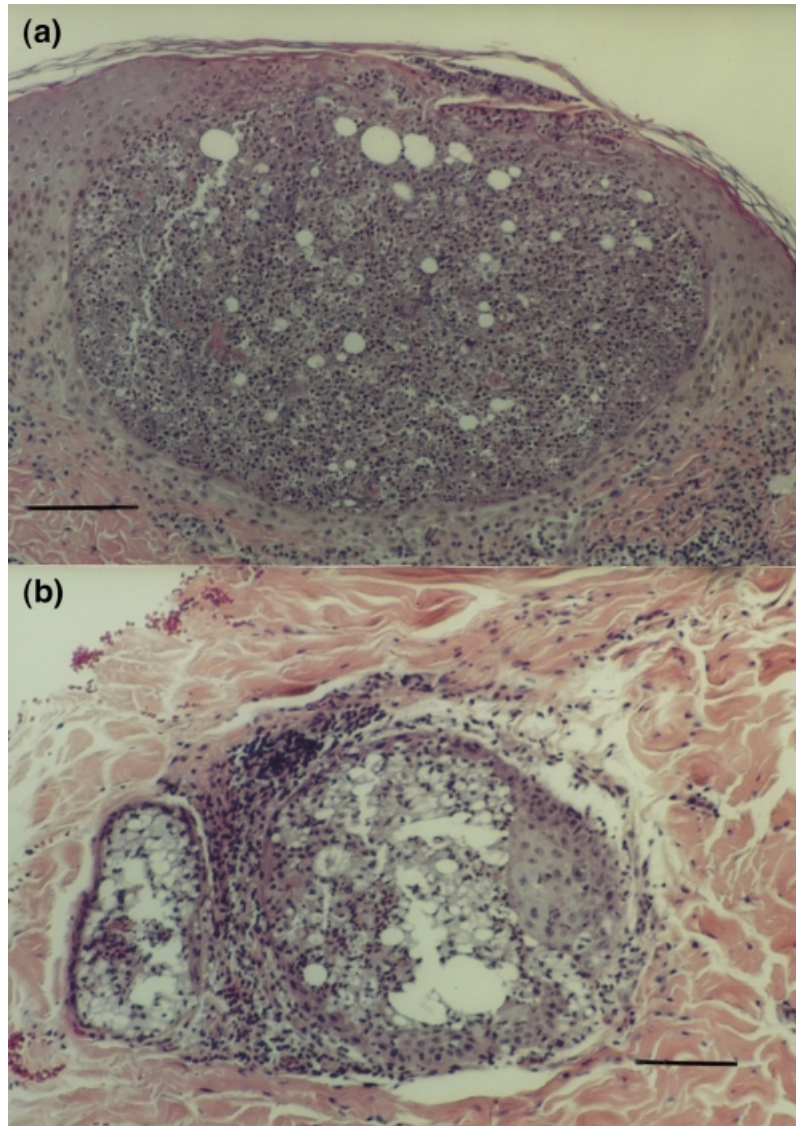
Twenty weeks after a single PDT treatment, there was only a slight reduction of sebaceous gland size (a mean decrease of 17%) without other apparent morphologic changes or infiltrates. The sebocyte cytoplasm/nuclear area ratio was not reduced.

Masson-trichrome stained specimens showed perifollicular fibrosis caused by single or multiple PDT, and mild disarray of collagen bundles in the mid-reticular dermis by multiple PDT. Fontana-Masson stain showed higher epidermal pigmentation after PDT, and slightly more dermal melanophages (pigment incontinence) compared with untreated sites.

Fluorescence microscopy of fresh-frozen sections after ALA application showed bright porphyrin fluorescence in epidermis and pilosebaceous units, compared with untreated skin. There was brighter PpIX fluorescence in sebocytes than in the adjacent follicular epithelial cells (Fig 11).

Adverse effects Erythema and edema were most intense about 10 min after the beginning of PDT and subsided to lesser intensity by the end of the light exposure. There was a substantial decrease in

Figure 8. Neutrophilic pustules are seen 3 d after ALA-PDT, intraepidermally and within pilosebaceous units, associated with the acneiform eruption caused by PDT. (a) Intraepidermally; (b) within pilosebaceous units. The sections were stained with hematoxylin and eosin. Scale bars: 100 μ m.



erythema and edema by 1 h after treatment, in both groups. Subjective reports of pain, burning, and itch were more severe at 10 min after starting PDT than at the end of treatment. A burning sensation became more severe with subsequent treatments and was the main complaint (9%, 67%, 67%, and 73% of subjects at treatments 1, 2, 3, and 4, respectively). Itching was the next frequent subjective side-effect of subsequent treatments (73%, 73%, 55%, and 55% of subjects at treatments 1, 2, 3, and 4). In contrast to multiple PDT, itching was the main discomfort in the single PDT group, and pain was the least.

Erythema, hyperpigmentation, and exfoliation were commonly seen after PDT. Six patients in the multiple-treatment group could not continue the weekly treatment scheme and had to postpone their next treatment: two at treatments 3 and 4, two at treatment 3, and two at treatment 4. Erythema and hyperpigmentation faded away completely at 20 wk in 82% and 91%, respectively, of the single-treatment subjects. No subjects had exfoliation after 3 wk post-treatment. One subject in the single PDT group developed blistering in the PDT site after vigorous aerobic exercise while wearing a tight outfit the day after treatment. This area healed without scarring in 3 wk. In fact, no site in any subject had any scarring. Multiple PDT caused long-lasting hyperpigmentation with 55% of subjects still showing some degree of pigmentation at 20 wk after treatment. In 10% of multiple-treatment subjects, superficial but very prominent exfoliation was seen after four

treatments, with transient purpura (average 1 wk) and partial loss of epidermis.

DISCUSSION

PDT has been used mainly for solid tumor treatment, but in dermatology its potential applications include a host of inflammatory, proliferative, or angiogenic skin lesions such as actinic keratoses (Jeffes *et al*, 1997), psoriasis (Collin *et al*, 1997), verrucae (Ammann *et al*, 1995), and cutaneous T cell lymphoma (Wolf *et al*, 1994). Beginning with Kennedy's pioneering studies (Kennedy *et al*, 1992), topical ALA has been studied in skin because it is a nontoxic, naturally occurring, substance that targets cells expressing porphyrin synthesis. ALA is the first committed precursor of the heme synthesis pathway, which is regulated by inhibition of ALA synthase (Kappa *et al*, 1989). Photosensitizing porphyrins accumulate in skin after ALA is applied, presumably after depletion of intracellular iron stores. In normal skin, the epidermis, hair follicles, and sebaceous glands accumulate *PpIX* in high concentrations after systemic ALA (Divaris *et al*, 1990). In our study fluorescence photography shows ALA-induced *PpIX* fluorescence is greater in acne lesions than in surrounding tissue (Fig 12). *P. acnes* bacteria produce porphyrins to the extent that red fluorescence is easily seen, and is correlated with *P. acnes* colonization of sebaceous follicles. It has been shown that exogenous ALA can cause a

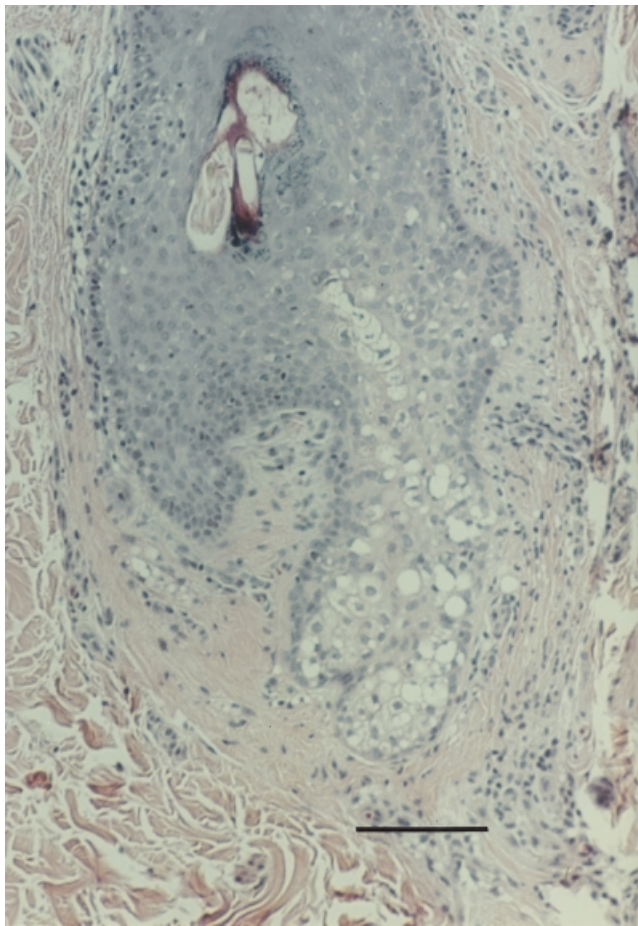


Figure 9. Focal vacuolization of sebocytes and follicular keratinocytes. This biopsy was taken at week 3 from single PDT treated skin. Note the mild perifollicular fibrosis. Scale bar: 100 μ m.

preferential accumulation either of protoporphyrin or of coproporphyrin and/or uroporphyrin in *P. acnes* (Ramstad *et al*, 1997).

Topical ALA-PDT may therefore have several modes of action for acne treatment. Direct photodynamic injury of sebaceous glands could inhibit sebum production; photodynamic killing of *P. acnes* could sterilize sebaceous follicles; follicular obstruction could be reduced by changing keratinocyte shedding and hyperkeratosis.

We found that topical ALA-PDT has potent effects on acne vulgaris. Blinded clinical assessment showed obvious and significant improvement of acne for at least 10 wk after a single PDT treatment, and for at least 20 wk after four treatments. Somewhat to our surprise, even nodular acne responded well and cystic acne induced by PDT resolved quickly and completely. PDT caused acute inflammation followed by partial or complete necrosis of sebaceous glands, producing a monomorphic acneiform eruption that appeared after a few days and then subsided over several days to weeks. A similar eruption often occurs after starting systemic retinoids, which, like ALA-PDT, strongly inhibit sebaceous gland activity. Sebum excretion was inhibited abruptly by PDT, then slowly and only partially recovered by 20 wk after four PDT treatments. Histologically, sebaceous glands were smaller, and remained so long after PDT. Fluorescence of the endogenous porphyrins associated with *P. acnes* was also significantly decreased after both single and multiple PDT, for at least 20 wk. We hypothesize that antibiotic effects on *P. acnes* can be readily achieved by a single PDT treatment although further investigation is necessary for confirmation from direct bacterial culture. Taken together, our results show that topical ALA-PDT inhibits multiple pathogenetic factors of acne. It remains unclear, however, whether

improvement of acne after PDT is due primarily to inhibition of sebum, to killing of *P. acnes*, or to secondary host responses. We note, however, that suppression of sebum production appears to correlate best with clinical improvement.

The acneiform eruption occurring 3–4 d after the first ALA-PDT treatment was a constant finding in this study. The mechanism for this eruption is unknown. We hypothesize that PDT disrupts sebocyte and *P. acnes* membranes, activating complement and neutrophil migration into the perifollicular area. Reactive oxygen species produced by neutrophils play a significant role in disrupting the follicular epithelium, which is responsible for the inflammatory process of acne (Akamatsu and Horio, 1998). In addition, *P. acnes* activates complement and produces C5a, a potent neutrophil chemotactic factor (Webster *et al*, 1986). The bacterial cell wall peptidoglycan-polysaccharide substance may also play a role in stimulating an immune granuloma type reaction (Vowel *et al*, 1995), which was seen in this study following multiple PDT. In the multiple-treatment group, each subsequent PDT treatment produced a progressively less inflammatory and weaker acneiform eruption, which is at least consistent with sterilization of the follicles by the first treatment.

ALA-PDT is not a trivial procedure, and has side-effects. We used an aggressive ALA-PDT treatment dose in order to test the possibility of effects on acne vulgaris. Fortunately, there was no scarring in this study, after a total of about 60 PDT sessions in 23 subjects. Each treatment, however, takes time, is painful or pruritic, causes acute erythema and edema, occasionally causes blistering and purpura, causes an acute acneiform eruption, and usually leads to hyperpigmentation that fades gradually over weeks to months. To most people, these side-effects would be tolerable in practice only if PDT were able to permanently improve acne, which remains a distinct possibility. This situation is not unlike the use of systemic retinoids (Geiger, 1995), which produce both long-lasting benefits and major side-effects. We did nothing in this study to optimize or alleviate the side-effects of ALA-PDT, and it is rather unlikely that we happened to use the best conditions for PDT of acne. Dose-response characteristics for ALA-PDT treatment of acne are unknown. We plan future studies exploring the precise dosimetry. We hypothesize, for example, that killing of *P. acnes* requires much less aggressive treatment than is needed to inhibit sebum production. One might therefore ask what the least aggressive ALA-PDT regimen effective for improving acne is. Many other factors could be optimized. Uptake of ALA into sebaceous follicles might be enhanced or made more selective by the vehicle and application conditions; ALA can be delivered rapidly into skin by iontophoresis (Rhodes *et al*, 1997); using a lower light irradiance and fractionated exposures is known to reduce the pain of PDT; topical anesthesia could be used; drugs that protect patients with endogenous porphyrias, such as beta-carotene or anti-inflammatory agents, might decrease some of the side-effects without decreasing the efficacy of ALA-PDT; a series of less aggressive PDT treatments may be preferable; it may even be possible to combine ALA with sunscreen preparations to allow sunlight treatment over large body areas. These and other ideas may be worth pursuing because it is now clear that acne vulgaris responds to ALA-PDT.

The authors acknowledge William Farinelli, Norm Michaud, Nik Kollias, and Kim Palli for technical assistance and clinical study coordination. Dr. Hongcharu is supported in part by the U.S. Department of Energy, Grant No. DOE-FG02-91ER61228. We thank DUSA Pharmaceuticals Inc. for donating the ALA supply. DUSA did not fund this research, and none of the authors has any financial interest in DUSA or ALA-PDT for acne. The study was performed under FDA, IND #55249.

REFERENCES

- Akamatsu H, Horio T: The possible role of reactive oxygen species generated by neutrophils in mediating acne inflammation. *Dermatology* 196:82–85, 1998

Figure 10. Long-term damaged pilosebaceous unit caused by PDT. Twenty weeks after four ALA-PDT treatments, there are atrophic or partially damaged sebaceous glands (a), a granulomatous reaction in completely destroyed sebaceous glands (b), obliterated hair follicles (c), and perifollicular fibrosis (d). Scale bars: 100 μ m.

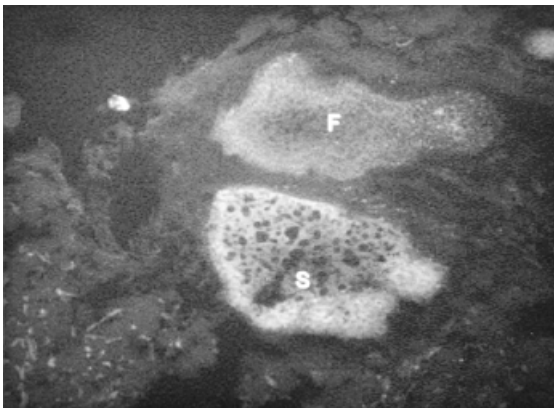
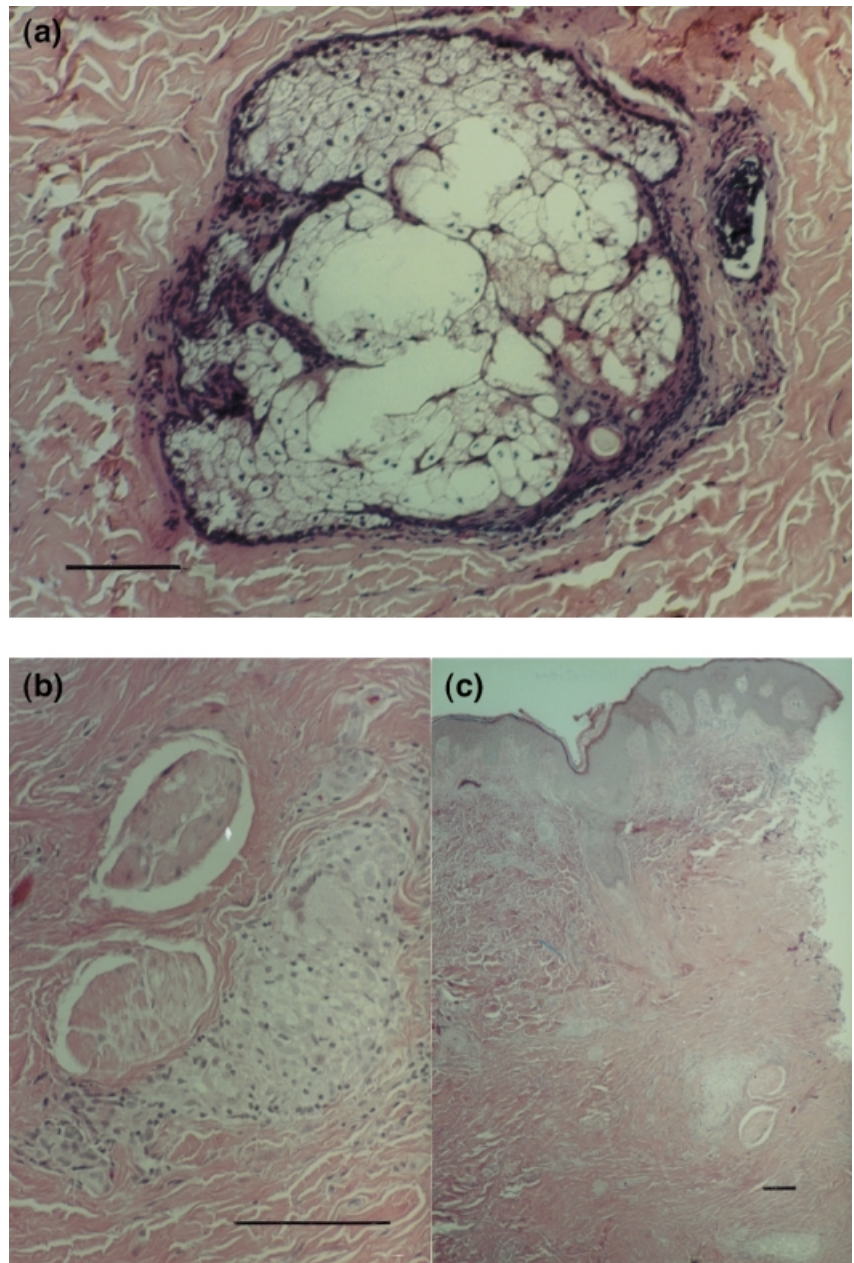


Figure 11. Fluorescence microscopy. Fluorescence microscopy demonstrates that *PpIX* production is mainly located in sebaceous glands (S) and hair follicles (F). Fluorescence is greater in sebaceous glands than in hair follicles.




Figure 12. ALA-induced *PpIX* fluorescence is greater in acne lesions than in surrounding tissue.

- Ammann R, Hunziker T, Braathen LR: Topical photodynamic therapy in verrucae. A pilot study. *Dermatology* 191:346-347, 1995
- Burke BM, Cunliffe WJ: The assessment of acne vulgaris: the Leeds technique. *Br J Dermatol* 111:83-92, 1984
- Collin P, Robinson DJ, Stringer MR, Stables GI, Sheehan-Dare RA: The variable response of plaque psoriasis after a single treatment with topical 5-aminolevulinic acid photodynamic therapy. *Br J Dermatol* 137:743-749, 1997
- Cornelius CE, Lugwig GD: Red fluorescence of comedones: production of porphyrins by *Corynebacterium acnes*. *J Invest Dermatol* 49:368-370, 1967
- Divaris DXG, Kennedy JC, Poittier RH: Phototoxic damage to sebaceous glands and hair follicles of mice after systemic administration of 5-aminolevulinic acid correlates with localized protoporphyrin IX fluorescence. *Am J Pathol* 136:891-897, 1990
- Geiger JM: Retinoids and sebaceous gland activity. *Dermatology* 191:305-310, 1995
- Iinuma S, Farshi SS, Ortel B, Hasan T: A mechanistic study of cellular photodestruction with 5-aminolevulinic acid-induced porphyrin. *Br J Cancer* 79:21-28, 1994
- Jeffes EW, McCullough JL, Weinstein GD, et al: Photodynamic therapy of actinic keratosis with topical 5-aminolevulinic acid. A pilot dose-ranging study. *Arch Dermatol* 133:727-732, 1997
- Kappas A, Sassa S, Galbraith RA, Nordmann Y: The porphyrias, in Scriver CR, Beaudet AL, Sly WS, Valle D: eds. *The Metabolic Basis of Inherited Disease*. McGraw-Hill, New York, 6th edn., 1989:pp 1305-1366
- Kennedy JC, Pottier RH: Endogenous protoporphyrin IX, a clinically useful photosensitizer for photodynamic therapy. *J Photochem Photobiol Biol* 14:275-292, 1992
- Kjeldstad B: Photoinactivation of *Propionibacterium acnes* by near-ultraviolet light. *Z Naturforsch* 39:300-302, 1984
- Lucchina L, Kollias N, Gillies R, et al: Fluorescence photography in the evaluation of acne. *J Am Acad Dermatol* 35:58-63, 1996
- Michaelsson G, Juhlin L, Vahlquist A: Effect of oral zinc and vitamin A in acne. *Arch Dermatol* 113:31-36, 1977
- Pagnoni A, Kligman AM, Gammal S, Popp C, Stoudemayer T: An improved procedure for quantitative analysis of sebum production using Sebutape. *J Soc Cosmet Chem* 45:221-225, 1994a
- Pagnoni A, Kligman AM, Gammal S, Popp C, Stroudemayer T: Determination of density of follicles on various regions of the face by cyanoacrylate biopsy: correlation with sebum output. *Br J Dermatol* 131:862-865, 1994b
- Pierard GE: Rate and topography of follicular sebum excretion. *Dermatologica* 175:280, 1987
- Ramstad S, Futsaether CM, Johnsson A: Porphyrin sensitization and intracellular calcium changes in the prokaryote, *Propionibacterium acnes*. *J Photochem Photobiol B* 40:141-148, 1997
- Rhodes LE, Tsoukas MM, Anderson RR, Kollias N: Iontophoretic delivery of ALA provides a quantitative model for ALA pharmacokinetics and PpIX phototoxicity in human skin. *J Invest Dermatol* 108:87-91, 1997
- Sigurdsson V, Knulst AC, Van Weelden H: Phototherapy of acne vulgaris with visible light. *Dermatology* 194:256-260, 1997
- Soukos NS, Ximenez-Fyvie LA, Hamblin MR, et al: Target anti-microbial photochemotherapy. *Antimicrob Agents Chemother* 42:2595-2601, 1998
- Szeimies RM, Calzavara-Pinton PG, Karrer S, Ortel B, Landthaler M: Topical photodynamic therapy in dermatology. *J Photochem Photobiol B* 36:213-219, 1996
- Vowels B, Yang S, Leyden JJ: Induction of proinflammatory cytokines by a soluble factor of *Propionibacterium acnes*: implications to chronic inflammatory acne. *Infect Immunol* 63:3158-3165, 1995
- Webster GF, Leyden JJ, Tsai CC, Baehni R, McArthur WP: Polymorphonuclear leukocyte liposomal release in response to *Propionibacterium acnes* and its enhancement by sera from inflammatory acne patients. *J Invest Dermatol* 74:398-401, 1986
- Weissmann W, Bowden F, Frank B, Horwitz SN, Frost P: Morphometric studies of the hamster flank organ: an improved model to evaluate pharmacologic effect on sebaceous glands. *J Invest Dermatol* 82:522-525, 1984
- Wolf P, Fink-Puches R, Cerroni L, Kerl H: Photodynamic therapy for mycosis fungoides after topical photosensitization with 5-aminolevulinic acid. *J Am Acad Dermatol* 31:678-680, 1994