

Retinal Biocompatibility of Brilliant Blue G with Deuterated Water for Chromovitrectomy

Emmerson Badaró¹, MD; Milton Moraes-Filho¹, MD; Mauricio Maia¹, MD, PhD
Fernando M. Penha¹, MD, PhD; Eduardo Amorim Novais¹, MD; Rodrigo A. Souza-Lima¹, MD
Flavio Hirai¹, MD, PhD; Carsten H. Meyer², MD
Michel Eid Farah¹, MD, PhD; Eduardo B. Rodrigues¹, MD, PhD

¹Department of Ophthalmology, Vision Institute (IPEPO), Federal University of São Paulo, São Paulo, Brazil

²Department of Ophthalmology, University of Bonn, Bonn, Germany

Purpose: To investigate the retinal biocompatibility of Brilliant Blue G with deuterated water (BBG-D2O) as a vital dye for chromovitrectomy.

Methods: In this animal study, 0.05 mL of 0.25 g/L Brilliant Blue G (BBG) associated with 0.13 mL/mL of deuterium oxide (D2O) was injected intravitreally in the right eye and the same amount of balanced salt solution (BSS) was injected similarly in the left eye of rabbits. Clinical examination and histology with light microscopy were performed after seven days. Retinal cell layers were evaluated for morphologic alterations. Electroretinographic (ERG) changes were also assessed at baseline and 7 days after the injections.

Results: A total of 6 rabbits were included in the study. The gross histopathologic appearance of the retina, choroid, sclera and optic nerve was within normal limits without any sign of severe retinal necrosis or cystic degeneration. Light microscopy showed that BBG-D2O caused no substantial alterations in retinal layers as compared to control eyes. The injection of BBG-D2O did not induce considerable functional ERG alterations.

Conclusion: Intravitreal injection of BBG-D2O 0.25 g/L seems to induce no retinal toxicity as documented by lack of functional and histological changes.

Keywords: Brilliant Blue; Chromovitrectomy; Deuterated Water; Retinal Toxicity

J Ophthalmic Vis Res 2014; 9 (2): 204-209.

Correspondence to: Emmerson Badaro, MD. Department of Ophthalmology, Federal University of São Paulo, Rua Botucatu 821, 1st floor, São Paulo, Brazil; Tel: +55 11 96786 9222; Fax: +55 11 96786 9222; email: ebadaro@me.com

Received: March 26, 2013

Accepted: August 5, 2013

INTRODUCTION

Chromovitrectomy refers to staining of pre-retinal membranes and tissues to facilitate their intraoperative visualization and removal.¹ Indocyanine green (ICG) was initially shown to avidly stain the internal limiting membrane (ILM).² However, numerous articles have raised concerns over retinal toxicity after intravitreal

injection of ICG.³⁻⁵ Later, newer vital dyes emerged as alternatives, such as trypan blue (TB), triamcinolone acetate (TA) and brilliant blue G (BBG).⁶⁻⁸ However, the blue dyes may stain epiretinal membranes (ERMs) rather than ILM elements, while TA deposits substantially in the acellular vitreous.⁹⁻¹³ Furthermore, the exact risk of BBG and TB retinal toxicity is not well defined but under investigation.¹⁴⁻²² Thus, the

best vital dye in terms of retinal compatibility and high affinity for the acellular ILM and ERM is yet to be determined.

BBG is approved for intraocular use and commercially available at a concentration of 0.25%. The dye should be injected into the fluid-filled globe and washed out immediately to prevent ocular damage. However, efforts are made to achieve higher dye concentrations directly on the surface of the ILM and prevent uncontrolled distribution of the dye within the vitreous cavity by adding heavy water (D2O, deuterium oxide) to the solution.

In the current study, BBG-D2O was tested in a rabbit model for retinal toxicity. The goal was to investigate the *in vivo* retinal biocompatibility of this dye injected intravitreally into rabbits eyes by clinical examination, histology using light microscopy (LM) and electroretinography (ERG).

METHODS

Dye Solutions, pH, Osmolarity, and Light Absorption Properties

Portions of 5 mg of BBG, in powder form, were weighed with an analytical balance (Mettler-Toledo Inc., Columbus, USA) and dissolved in 10 mL of the solvent, balanced salt solution (BSS), to obtain a concentration of 0.25 g/L. The mixtures were shaken for 5 minutes and sonicated (Unique Ind., Idaiatuba, Brazil) to obtain a complete solution. The pH was measured with a pH meter (Quimis Inc., Diadema, Brazil), while osmolarity was determined with an osmometer (Advanced Instruments Inc., Norwood, USA). Heavy brilliant blue G was created by adding D2O (water containing a higher-than-normal proportion of the hydrogen isotope deuterium) at a concentration of 0.13 mL/mL. Spectral absorption was measured with a spectrometer between 200 and 1,000 nm immediately after preparation (Spectronic Genesys 5 spectrophotometer, Milton Roy, Warminster, PA, USA).

Dye preparations that were well mixed and sonicated produced complete solutions for injection. The dye was prepared in a solution

with BSS to achieve a concentration of 0.25 g/L associated with 0.13 mL/mL of D2O. The osmolarity of selected dyes for experiments ranged from 267 mOsm to 315 mOsm, while pH values were within 6.84 and 7.33.

Animals and Surgical Technique for Intravitreal Injection

A total of 6 male Dutch-belted rabbits, weighing 1.8 to 2.5 kg, were used in accordance with the ARVO statement, "Principles of Laboratory Animal Care" (NIH publication No. 85-23, revised 1985), the OPRR Public Health Service Policy on the Humane Care and Use of Laboratory Animals (revised 1986) and the US Animal Welfare Act, as well as university and national guidelines for research on animals.

After placing a lid speculum, a drop of 5% povidone-iodine was instilled followed by BSS washout. The vitreous cavity was accessed through the superotemporal sclera 2 mm posterior to the limbus using a 27-gauge needle connected to a 1 mL syringe containing dye or BSS. The animals were given an injection of 0.05 mL of 0.25 g/L BBG associated with 0.13 mL/mL of D2O into the right eye vitreous cavity, while the left eyes were injected with 0.05 mL of BSS (290 mOsm) serving as the control group. Eyes were immediately examined by indirect ophthalmoscopy; one drop of antibiotic-steroid solution (0.5% moxifloxacin and 0.1% dexamethasone) was then instilled in each eye.

Clinical Evaluation

Biomicroscopy and indirect ophthalmoscopy (Keeler Instruments, Broomall, USA) was performed immediately after the injection and at seven days to evaluate corneal transparency, conjunctival reaction, appearance of the lens and retina, and vitreous haze.

In vivo Retinal Functional Toxicity

ERG recordings were taken at baseline and 7 days after the intravitreal injections. The rabbits were kept in a dark room for 30 minutes and anesthetized with an intramuscular injection of

a solution containing 1 mL of ketamine (50 mg/mL) and 0.4 mL of xylazine (10 mg/mL). The pupils were dilated with 1% tropicamide eye drops and the cornea was anesthetized with 1% proparacaine drops. The rabbits were placed on a heating pad during the experiment and unipolar contact lenses with ERG jet electrodes (Universe SA, La Chaux-de-Fons, Switzerland) were placed on both corneas with 2% methylcellulose (Ophthalmos, São Paulo, Brazil).

A reference electrode filled with electrolytic gel was placed at the temporal canthus, while the ground electrode was also filled with gel and placed on the earlobe. They were then presented in a Veris System Ganzfeld stimulator (Electro-Diagnostic Imaging Inc., San Mateo, USA). After 30 minutes of dark adaptation, the procedure was performed according to two types of responses: scotopic rod response and scotopic maximal response. The responses one week after injection were compared to baseline levels and a decrease in post-injection values exceeding 50% was considered as remarkable.

Data were presented as median (range) values. Pre- and postinjection comparisons were performed using the Wilcoxon signed rank test. P-values less than 0.05 were considered as statistically significant. All analyses were performed employing Stata software version 11 (College Station, Texas, USA).

***In-vivo* Morphologic Retinal Toxicity and Light Microscopy**

The rabbits were euthanized with an intravenous injection of 120 mg/kg sodium pentobarbital one week after the intravitreal injections and their eyes were enucleated. The eyes were sectioned in half and fixed at 4°C in a mixture of 2.5% glutaraldehyde and 4% paraformaldehyde in 0.1 M phosphate buffer at pH 7.4. The specimens were stained *en bloc* with lead citrate, washed three times in 0.1 M phosphate buffer and dehydrated with ethyl alcohol. The specimens were embedded and stained with 1% toluidine blue and examined with an Optiphot-2TM (Nikon, Tokyo, Japan) for LM. Samples were obtained from two different areas in all dye-injected eyes in three serial sections: 500 µm

inferior to the optic nerve and 4 mm from the optic nerve in the temporal-inferior quadrant. An area 1100 µm in diameter of the retinal surface was used for detailed analysis of retinal toxicity. For histologic evaluation of the degree of cellular injury, retinal layers were analyzed individually for cellular abnormalities such as vacuolization, edema and necrosis. The results were described as absence of changes, focal abnormalities with less than 12 damaged cells, or diffuse changes with more than 12 damaged cells. Eyes were examined by two masked examiners to avoid bias. The inner (INL) and outer (ONL) nuclear layers were counted for the number of cells with the ImageJ software (National Institutes of Health, Bethesda, MD, USA) within the 1,100 micrometer retinal surface. The eyes of the dye group were compared with the BSS-control group; statistical analysis was performed using analysis of variances (ANOVA) followed by the Newman-Keuls test with a specific software program (GraphPad Software Inc., San Diego, CA, USA).

RESULTS

Clinical Evaluation

Promptly after intravitreal injection, the dye appeared in the vitreous cavity as a blue floating mass. At clinical examination immediately and 7 days after dye injection, all eyes were negative for cataracts, hemorrhage, retinal detachment and intraocular opacities.

Morphologic Retinal Toxicity with Light Microscopy

The histology of both BBG-injected and control eyes showed no major anatomical signs of toxicity. The histopathologic appearance of the retina, choroid and sclera was within normal limits without any sign of severe retinal necrosis or cystic degeneration.

The nerve fibre layer, retinal pigment epithelium (RPE) and choriocapillaris appeared normal after 7 days in both groups; both groups showed vacuolization and edema only in sparse regions of the retina (Figure 1).

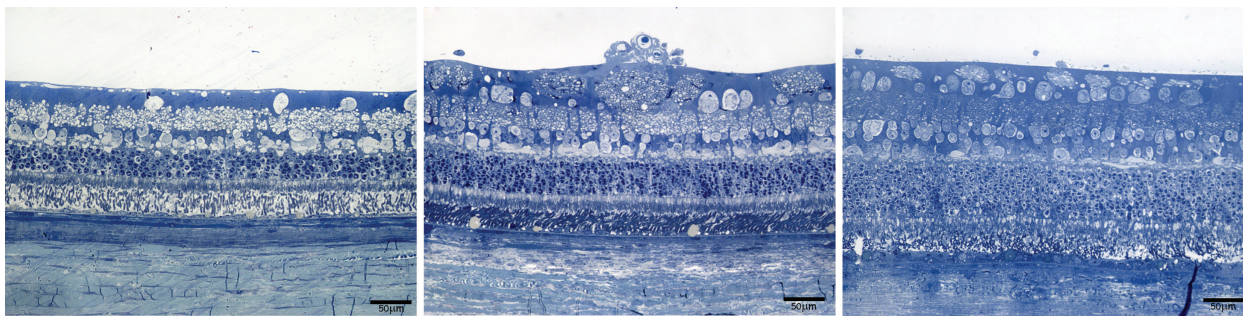


Figure 1. Retinal histologic findings with toluidine blue light microscopy 7 days after intravitreal injection of 0.05 mL of BBG-D2O in the right eye and 0.05 mL of BSS in the left eye.

Eye E1 OD (Left image): Retinal microstructure: normal; vitreous cells or alterations: normal; NFL: focal vacuolization; ganglion cells and IPL: normal; bipolar cells/INL: focal vacuolization and edema; outer plexiform layer, Photoreceptors/ONL, PIS: normal; POS: artifact; RPE, choriocapillaris/choroid: normal

Eye E2 OD (Middle Image): retinal microstructure: hyalocytes in the internal surface of the retina; NFL: focal vacuolization, artifact; ganglion cells, IPL: focal vacuolization; bipolar cells/INL: normal; outer plexiform layer: thinning, between this and ONL an area of swelling; Photoreceptors/ONL, PIS, POS, RPE, choriocapillaris/choroid: normal

Eye E3 OS (Right image): Retinal microstructure: normal; vitreous cells or alterations: normal; NFL and ganglion cells: focal vacuolization; IPL, bipolar cells/INL, outer plexiform layer, photoreceptors/ONL, PIS, POS: normal, just slight distortion due to artifact, but the layer and cells are fine; RPE and choriocapillaris/choroid: normal

BBG, brilliant blue G; D2O, Deuterium; BSS, balanced salt solution; OD, right eye; OS, left eye; NFL, nerve fiber layer; IPL, inner plexiform layer; INL, inner nuclear layer; ONL, outer nuclear layer; PIS, photoreceptor inner segment; POS, photoreceptor outer segment; RPE, retinal pigment epithelium

Evaluation of Retinal Function with Electroretinography

No considerable alterations in ERG were found during the follow-up period. Median B-wave amplitude of the maximal response in the right eyes was 184.25 (range, 162-192.5) μ V at baseline and 168.5 (range, 144.5-263) μ V after 7 days ($P=0.916$). Corresponding values for the left control eyes were 164.25 (145-195.5) μ V and 140.25 (71-176.5) μ V, respectively ($P=0.173$).

DISCUSSION

The use of vital dyes in vitrectomy facilitates intraoperative surgical maneuvers such as ILM or ERM peeling.¹⁻³ Some dyes available for chromovitrectomy such as ICG and TB may cause complications in macular surgery such as migration into the subretinal space and alterations in the RPE, and perimetric and papillary defects.^{4,23,24} In this rabbit model, the retinal biocompatibility of BBG with deuterated water was determined to evaluate the use of this dye as an alternative in chromovitrectomy. Our study showed that BBG-D2O at a dose of 0.25g/L caused no severe functional or morphologic retinal toxicity in this animal model. Another

study using cell culture found that BBG-D2O is safe based on ERG values.²⁵ Therefore, BBG-D2O may be useful and should be considered for application in chromovitrectomy. We used ERG B-wave amplitude as a criterion for evaluating retinal function in rabbits as it is the most relevant parameter for drug toxicity.

Compared to cell culture alone, animal models are usually considered to provide better evidence of pharmacological activity since it better simulates the human ocular and retinal environment. However, our results may not exactly correspond to the results in human chromovitrectomy due to interspecies variations. In our study, we did observe considerable anatomical or functional damage to the retinal layers. Considering the longer duration of dye exposure by the retina in the current study as compared to the shorter time of application during vitrectomy, we may assume that toxicity is even less likely during surgical procedures in humans. However one should consider the possibility of enhanced toxicity due to light exposure.

Drawbacks to our study include: (1) testing only one concentration of the dye in contrast to the large number of concentrations that can be examined in cell culture studies. (2) We did

not evaluate the affinity of the dye for the ILM.
(3) Lack of cell viability analysis.

In summary, intravitreal injection of BBG-D2O did not induce significant anatomical or functional toxicity in the retina in this animal model. However this agent should be studied further to prove its capacity to stain preretinal membranes and the vitreous with tolerable toxicity. Future surgical experience will help improve the use and interpretation of new dyes in chromovitrectomy.

Acknowledgments

This work was supported by Conselho Nacional de Desenvolvimento Científico e Tecnológico (CNPq; English: National Council for Scientific and Technological Development), (CNPq) project number 471326/2011-9; German Academic Exchange Service (DAAD); The Pan-American Association of Ophthalmology – Pan-American Ophthalmological Foundation (PAAO/PAOF); Vision Institute, Federal University of São Paulo (UNIFESP); Fundação de Amparo à Pesquisa do Estado de São Paulo (FAPESP; English: Foundation for Research Support of the State of São Paulo).

Conflicts of Interest

None.

REFERENCES

- Rodrigues EB, Meyer CH, Kroll P. Chromovitrectomy: a new field in vitreoretinal surgery. *Graefes Arch Clin Exp Ophthalmol* 2005;243:291-293.
- Costa Ede P, Rodrigues EB, Farah ME, Dib E, Penha F, Magalhaes O, et al. Vital dyes and light sources for chromovitrectomy: comparative assessment of osmolarity, pH, and spectrophotometry. *Invest Ophthalmol Vis Sci* 2009;50:385-391.
- Gandorfer A, Haritoglou C, Gandorfer A, Kampik A. Retinal damage from indocyanine green in experimental macular surgery. *Invest Ophthalmol Vis Sci* 2003;44:316-323.
- Maia M, Margalit E, Lakhanpal R, Tso MO, Grebe R, Torres G, et al. Effects of intravitreal indocyanine green injection in rabbits. *Retina* 2004;24:69-79.
- Rodrigues EB, Meyer CH, Farah ME, Kroll P. Intravitreal staining of the internal limiting membrane using indocyanine green in the treatment of macular holes. *Ophthalmologica* 2005;219:251-262.
- Teba FA, Mohr A, Eckardt C, Wong D, Kusaka S, Joondeph BC, et al. Trypan blue staining in vitreoretinal surgery. *Ophthalmology* 2003;110:2409-2412.
- Mennel S, Meyer CH, Tietjen A, Rodrigues EB, Schmidt JC. Patent blue: a novel vital dye in vitreoretinal surgery. *Ophthalmologica* 2006;220:190-193.
- Albini TA, Abd-El-Barr MM, Carvounis PE, Iyer MN, Lakhanpal RR, Pennesi ME, et al. Long-term retinal toxicity of intravitreal commercially available preserved triamcinolone acetonide (Kenalog) in rabbit eyes. *Invest Ophthalmol Vis Sci* 2007;48:390-395.
- Kumar A, Prakash G. Differential staining with indocyanine green and trypan blue dye. *Indian J Ophthalmol* 2004;52:339.
- Foster RE, Petersen MR, Da Mata AP, Burk SE, Rosa RH Jr, Riemann CD. Negative indocyanine green staining of epiretinal membranes. *Retina* 2002;22:106-108.
- Perrier M, Sebag M. Epiretinal membrane surgery assisted by trypan blue. *Am J Ophthalmol* 2003;135:909-911.
- Feron EJ, Veckeneer M, Parys-Van Ginderdeuren R, Van Lommel A, Melles GR, Stalmans P. Trypan blue staining of epiretinal membranes in proliferative vitreoretinopathy. *Arch Ophthalmol* 2002;120:141-144.
- Peyman GA, Cheema R, Conway MD, Fang T. Triamcinolone acetonide as an aid to visualization of the vitreous and the posterior hyaloid during pars plana vitrectomy. *Retina* 2000;20:554-555.
- Narayanan R, Mungcal JK, Kenney MC, Seigel GM, Kuppermann BD. Toxicity of triamcinolone acetonide on retinal neurosensory and pigment epithelial cells. *Invest Ophthalmol Vis Sci* 2006;47:722-728.
- Mennel S, Thumann G, Peter S, Meyer CH, Kroll P. [Influence of vital dyes on the function of the outer blood-retinal barrier in vitro]. *Klin Monbl Augenheilkd* 2006;223:568-576. [Article in German]
- Narayanan R, Kenney MC, Kamjoo S, Trinh TH, Seigel GM, Resende GP, et al. Trypan blue: effect on retinal pigment epithelial and neurosensory retinal cells. *Invest Ophthalmol Vis Sci* 2005;46:304-309.
- Schuettauf F, Haritoglou C, May CA, Rejdak R, Mankowska A, Freyer W, et al. Administration of novel dyes for intraocular surgery: an in vivo toxicity animal study. *Invest Ophthalmol Vis Sci*

- 2006;47:3573-3578.
18. Jackson TL, Griffin L, Vote B, Hillenkamp J, Marshall J. An experimental method for testing novel retinal vital stains. *Exp Eye Res* 2005;81:446-454.
19. Haritoglou C, Yu A, Freyer W, Priglinger SG, Alge C, Eibl K, et al. An evaluation of novel vital dyes for intraocular surgery. *Invest Ophthalmol Vis Sci* 2005;46:3315-3322.
20. Enaida H, Hisatomi T, Hata Y, Ueno A, Goto Y, Yamada T, et al. Brilliant blue G selectively stains the internal limiting membrane/brilliant blue G-assisted membrane peeling. *Retina* 2006;26:631-636.
21. Enaida H, Hisatomi T, Goto Y, Hata Y, Ueno A, Miura M, et al. Preclinical investigation of internal limiting membrane staining and peeling using intravitreal brilliant blue G. *Retina* 2006;26:623-630.
22. Ueno A, Hisatomi T, Enaida H, Kagimoto T, Mochizuki Y, Goto Y, et al. Biocompatibility of brilliant blue G in a rat model of subretinal injection. *Retina* 2007;27:499-504.
23. Rodrigues EB, Maia M, Meyer CH, Penha FM, Dib E, Farah ME. Vital dyes for chromovitrectomy. *Curr Opin Ophthalmol* 2007;18:179-187.
24. Penha FM, Maia M, Eid Farah M, Principe AH, Freymuller EH, Maia A, et al. Effects of subretinal injections of indocyanine green, trypan blue, and glucose in rabbit eyes. *Ophthalmology* 2007;114:899-908.
25. Januschowski K, Mueller S, Spitzer MS, Schramm C, Doycheva D, Bartz-Schmidt KU, et al. Evaluating retinal toxicity of a new heavy intraocular dye, using a model of perfused and isolated retinal cultures of bovine and human origin. *Graefes Arch Clin Exp Ophthalmol* 2012;250:1013-1022.